

Review

Inner-Ear Disorders Presenting with Air-Bone Gaps: A Review

Alfonso Scarpa , **Massimo Ralli** , **Claudia Cassandro** , **Federico Maria Gioacchini** ,
Antonio Greco , **Arianna Di Stadio** , **Matteo Cavaliere**, **Donato Troisi**, **Marco de Vincentiis** ,
Ettore Cassandro 

Department of Medicine and Surgery, University of Salerno, Salerno, Italy (AS, DT, EC)

Department of Sense Organs, Sapienza University of Rome, Rome, Italy (MR, AG, MdV)

Department of Surgical Sciences, University of Turin, Turin, Italy (CC)

Department of Clinical and Molecular Sciences, Polytechnic University of Marche, Ancona, Italy (FMG)

Department of Otolaryngology, University of Perugia, Perugia, Italy (ADS)

Department of Otorhinolaryngology, University Hospital 'San Giovanni di Dio e Ruggi d'Aragona', Salerno, Italy (MC)

ORCID iDs of the authors: A.S. 0000-0001-9219-6175; M.R. 0000-0001-8776-0421; C.C. 0000-0003-4179-9181; F.M.G. 0000-0002-1148-4384; A.G. 0000-0002-4824-9871; A.D.S. 0000-0001-5510-3814; M. d.V. 0000-0002-1990-7820; E.C. 0000-0003-1757-6543.

Cite this article as: Scarpa A, Ralli M, Cassandro C, Gioacchini FM, Greco A, Di Stadio A, et al. Inner-Ear Disorders Presenting with Air-Bone Gaps: A Review. J Int Adv Otol 2020; 16(1): 111-6.

Air-bone gaps (ABGs) are commonly found in patients with conductive or mixed hearing loss generally due to outer- and/or middle-ear diseases such as otitis externa, tympanic membrane perforation, interruption or fixation of the ossicular chain, and chronic suppurative otitis media. ABGs can also be found in correlation with inner-ear disorders, such as endolymphatic hydrops, enlarged vestibular aqueduct syndrome, semicircular canal dehiscence, gusher syndrome, cochlear dehiscence, and Paget disease's as well cerebral vascular anomalies including dural arteriovenous fistula. The typical clinical presentation of inner-ear conditions or cerebral vascular anomalies causing ABGs includes audiological and vestibular symptoms like vertigo, oscillopsia, dizziness, imbalance, spinning sensation, pulsatile or continuous tinnitus, hyperacusis, autophony, auricular fullness, Tullio's phenomenon, and Hennebert's sign. Establishing a definitive diagnosis of the underlying condition in patients presenting with an ABG is often challenging to do and, in many patients, the condition may remain undefined. Results from an accurate clinical, audiological, and vestibular evaluation can be suggestive for the underlying condition; however, radiological assessment by computed tomography and/or magnetic resonance imaging is mandatory to confirm any diagnostic suspicion. In this review, we describe and discuss the most recent updates available regarding the clinical presentation and diagnostic workup of inner-ear conditions that may present together with ABGs.

KEYWORDS: Air-bone gap, inner-ear, Ménière's disease, mixed hearing loss

INTRODUCTION

An air-bone gap (ABG) is defined as the difference between air-conduction and bone-conduction audiometric thresholds. ABGs are found in patients with conductive (CHL) or mixed (MHL) hearing loss generally attributed to outer- and/or middle-ear diseases such as otitis externa, tympanic membrane perforation, interruption or fixation of the ossicular chain, and chronic suppurative otitis media.

Air-bone gap can also follow the onset of inner-ear structural anomalies, such as enlarged vestibular aqueduct (EVA) syndrome, semicircular canal dehiscence, gusher syndrome, cochlear dehiscence, and Paget's disease ^[1]. These conditions are mainly characterized by sensorineural hearing loss (SNHL) ^[2, 3]; however, an ABG can also be found due to the so-called "third-window" mechanism ^[4], where the depletion of acoustic energy from the inner-ear into the middle-ear and/or the cranial cavity ^[4, 5] decreases the amount of energy delivered to the round window through a third-window. This mechanism provokes a decrease in the pressure gradient across the basilar membrane, leading to a decreased perception of air-conducted sound that progresses to a low-frequency ABG ^[5]. ABGs have additionally been reported in patients with endolymphatic hydrops (EH); in this context, an ABG can be explained by increased perilymphatic pressure with a consequent decrease in stapes mobility or by saccular dilation leading to a reduc-

tion in stapedial mobility. Cerebral vascular anomalies including dural arteriovenous fistula (DAVF) may also be responsible for an ABG due to communication between the inner-ear and the cranial cavity through the cochlear and vestibular aqueducts and multiple small neurovascular foramina, facilitating contiguity between the perilymphatic and subarachnoid spaces [6].

The typical clinical presentation of inner-ear conditions or cerebral vascular anomalies causing ABGs includes audiological and vestibular symptoms like vertigo, oscillopsia, dizziness, imbalance, spinning sensation, pulsatile or continuous tinnitus, hyperacusis, autophony, auricular fullness, Tullio's phenomenon, and Hennebert's sign [7].

Establishing a definitive diagnosis is often challenging and, in many patients, the underlying condition remains unknown. This review sought to describe and discuss the most recent updates available regarding the clinical presentation and diagnostic workup of inner-ear conditions that may present together with an ABG.

CLINICAL AND RESEARCH CONSEQUENCES

Superior Semicircular Canal Dehiscence (SSCD)

Superior semicircular canal dehiscence (SSCD) is an idiopathic condition characterized by a loss of the bony wall of the superior semicircular canal that promotes communication between the semicircular canal and the middle cranial fossa. The incidence of SSCD in the general population is difficult to estimate; for example, Minor [8] reported 65 cases in a nine-year period. Some risk factors have been reported to correlate with SSCD including direct mechanical trauma, increased cerebrospinal fluid pressure, increased pressure following Valsalva maneuvers, underdevelopment of bone overlying the semicircular canal, and progressive erosion due to vascular pulsations [9].

The clinical presentation of SSCD includes spontaneous or positional dizziness, vertigo following pressure or sound, and vertical nystagmus [10]. In some cases, SSCD can be asymptomatic, making the establishment of a clinical diagnosis harder [11].

The typical audiological feature of SSCD is an ABG in the low and middle frequencies ($\leq 2,000$ Hz); bone-conduction thresholds can be present at supranormal levels [12], which can facilitate a misdiagnosis

of CHL. At frequencies of 2000 Hz or higher, only a limited, or absent gap can be found because less acoustic energy passes through the third window. The degree of ABG may be related to the location, length, or cross-sectional area of the SSCD [13].

Many techniques have been proposed to diagnose SSCD, including audiometry, complete immittance testing with tympanometry and acoustic reflexes, and air-conducted vestibular-evoked myogenic potential (VEMP) testing. The diagnostic confirmation of a true case of dehiscence should involve a high-resolution computed tomography (CT) scan of the temporal bone using multiplanar reconstructions in the planes of Stenver and Pöschl; Pöschl views parallel and Stenver views perpendicular to the plane of the superior semicircular canal have the highest diagnostic specificity [14].

The treatment of SSCD is exclusively surgical and includes capping or plugging of the SSCD or reinforcement of the oval and/or round windows [15].

Posterior Semicircular Canal Dehiscence (PSCD)

Posterior semicircular canal dehiscence (PSCD) is an uncommon canal dehiscence [10] that can be observed alone or in combination with SSCD with frequencies of 0.3% and 4.5%, respectively [5]. The PSCD can extend into the posterior fossa dura through communication with a high-riding jugular bulb or via a bony defect. Often, PSCD results from jugular bulb erosion or fibrous dysplasia [9].

Audiological symptoms associated with PSCD are similar to those in SSCD; a clinical suspicion for PSCD should arise if bone-conduction responses are at 5 dB HL or better, a biphasic complex at VEMP test elicits a lowered threshold at an increased amplitude, and vestibular signs like nystagmus are present in the plane of the posterior semicircular canal. Pure tone audiometry in the half-octave is useful to confirm the characteristic low-frequency ABG correlated with this condition [16].

Lateral Semicircular Canal Dehiscence (LSCD)

Lateral semicircular canal dehiscence (LSCD) is often the result of middle-ear diseases such as otitis media [17], cholesteatoma, and canal-wall-down mastoidectomy [9, 18]; isolated LSCD is extremely unusual [18] and has been reported only in patients with dysplastic bony labyrinths to date. It is very difficult to ascertain whether ABG in LSCD is related to abnormalities of the middle-ear or to a third-window mechanism of the LSCD [19] (Figure 1).

Patients with LSCD can present with an ABG in the low-frequency range. In cases of fistula secondary to cholesteatoma, vertigo and ipsilateral nystagmus may be induced by pressure applied to the external auditory canal [20]. In this scenario, it is controversial as to whether the matrix of cholesteatoma should be completely removed or whether a thin layer should be left in place to prevent possible deafness due to labyrinthine exposure [9]. Previously Chen et al. [21] reported on the complete surgical removal of cholesteatoma in 22 patients with LSCD; two of them experienced postoperative hearing losses of 5 to 15 dB, whereas the others presented with stable or improved hearing.

Enlarged Vestibular Aqueduct (EVA) Syndrome

The vestibular aqueduct have a diameter, on average, of 0.6 mm [22]. If the vestibular aqueduct is dilated to a diameter of greater than

MAIN POINTS

- An air-bone gap, typical of conditions that involve the external and middle ear, can also be found in conditions affecting the inner-ear due to a third-window mechanism or in idiopathic or secondary endolymphatic hydrops
- Typical clinical presentation of inner-ear conditions with air-bone gaps may include several audiovestibular symptoms such as vertigo, oscillopsia, dizziness, imbalance, tinnitus, hyperacusis, autophony, auricular fullness, and Tullio's phenomenon.
- Accurate clinical, audiological, and vestibular evaluations can be suggestive of the underlying condition for hearing loss presenting with an air-bone gap.

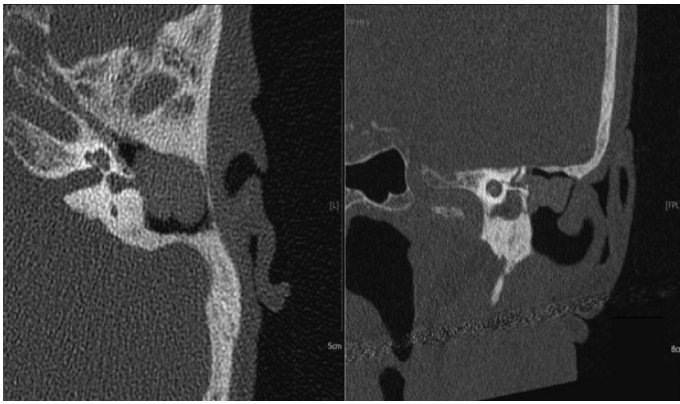


Figure 1. Computed tomography (CT) scan. Lateral semicircular canal dehiscence due to chronic otitis media. The cortical bone of the middle fossa and the tegmen tympani are thinner than expected as a result of the erosive phenomena induced by the reactive tissue.

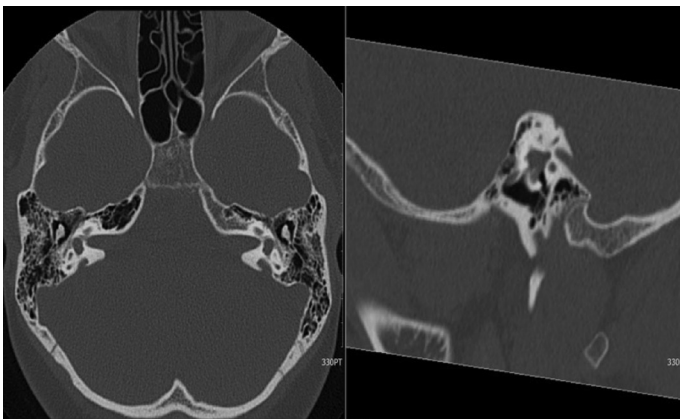


Figure 2. Computed tomography (CT) scan. Presentation of bilateral enlarged vestibular aqueducts in a 11-year old child with an history of bilateral conductive hearing loss. The child did not present any sign of middle-ear disease.

1.5 mm^[23], such can give rise to complex and variable auditory and vestibular symptoms because it may act as a third-window. EVA is a relatively rare condition that often occurs bilaterally alone or in association with various congenital diseases, such as Pendred syndrome, choanal atresia, coloboma, heart defects, retarded development, and branchio-oto-renal syndrome along with a variety of inner-ear anomalies that may be due to the onset of higher inner-ear pressures following a third-window mechanism^[24] (Figure 2). Fluctuating or progressive mixed or sensorineural hearing loss^[25] is a typical audiometric feature of EVA. In patients with EVA, ABG in the low-frequency range is provoked by a third-window mechanism that increases bone-conduction to near-normal levels^[26].

Vestibular symptoms include episodic vertigo and occasional unsteadiness and dizziness; the former is more typical of adult patients, while the latter predominate in children, mimicking other disorders such as otosclerosis and Ménière-like disease or semicircular canal dehiscence^[5].

Vestibular-evoked myogenic potential testing may represent a useful diagnostic test in EVA demonstrating lower thresholds and higher amplitudes despite the presence of ABG on the side of the pathology^[27]. However, the definitive diagnostic technique for EVA is radiological in nature, involving CT and magnetic resonance imaging (MRI).

CT diagnostic criteria are based on the dimension of the vestibular aqueduct following the Valvassori^[23] or the Cincinnati^[28] criteria. MRI, especially involving T2-weighted images, is useful to visualize the membranous labyrinth and show the extraosseous portion of the endolymphatic sac^[29].

To date, there is no evidence of a treatment able to limit the progression of EVA. Significant audiometric benefits have been observed in EVA patients receiving a cochlear implant^[30, 31], while temporary hearing improvements were documented by Grimmer et al.^[32] when treating EVA patients with corticosteroid therapy.

X-Linked Stapes Gusher

Stapes gusher syndrome is a congenital disorder linked to a mutation in the *POU3F4* gene on the X chromosome affecting almost exclusively males. Female carriers can be asymptomatic or present a less severe degree of hearing loss, depending on the type of mutation^[33]. Clinical features include congenital mixed hearing loss that worsens to severe deafness within eight to 10 years due to perilymphatic hydrops^[33]. ABG is typically found in the low-frequency range, reflecting a third-window mechanism due to the absence of the lamina cribrosa and consequent communication between the perilymphatic and subarachnoid spaces; while the stapedial reflex may be preserved^[4].

Computed tomography imaging can reveal abnormalities like cochlear hypoplasia, an enlarged internal auditory canal, absent modiolus and lamina cribrosa, and a labyrinthine facial nerve canal with a classic corkscrew appearance of the cochlea^[34]. Cochlear implantation is indicated in patients with severe or profound SNHL, although careful insertion of the electrode is mandatory. Stapes surgery should be avoided due to the high risk of cerebrospinal fluid leak and meningitis; outcomes are not encouraging relative to those of other inner-ear abnormalities^[35].

Bone Dyscrasias

Bone dyscrasias include a number of metabolic bone diseases such as Paget's disease and osteogenesis imperfecta that show a pathologic bone turnover with involvement of the otic capsule. These conditions incite osteoclastic activation, inducing a third-window effect with a consequent low-frequency ABG at pure tone audiometry^[36].

Osteogenesis imperfecta is caused by mutations in type I collagen synthesis, producing brittle bones and lax joints and ligaments as a result of existing fragile connective tissue^[24]. Afflicted patients present with skeletal abnormalities and fractures due often to mild traumas; otic capsule mineralization can be facilitated with the use of bisphosphonates and dietary supplements^[37]. Surgical options—which are, unfortunately, characterized by poor outcomes—include stapes surgery for fenestral disease^[38] and cochlear implantation for retro-fenestral disease.

Paget's disease is characterized by a dystrophic remodeling of bone tissues and consists of an initial phase of bone resorption followed by a sclerotic phase and a final remodeling phase with, typically, lamellar bone; the bones show a typical mosaic-bone pattern^[39]. Patients with Paget's disease experience progressive bilateral hearing loss; Amilibia Cabeza et al.^[2] reported that subjects affected by Paget's disease showed a more profound and higher incidence of CHL as compared

Table 1. Diagnostic strategy to differentiate middle-ear involvement, third-window lesions, and endolymphatic hydrops conditions

Diagnostic measures	Middle ear involvement	Third-window lesion	Endolymphatic hydrops conditions
Type of hearing loss	Conductive hearing loss	Conductive or mixed hearing loss	Generally mixed or sensorineural hearing loss
Air-bone gap	0–60 dB, may involve all frequencies	0–60 dB, greatest at frequencies <2000 Hz	0–50 dB, greatest at frequencies <1000 Hz
Bone conduction thresholds	Rarely < 0 dB	Sometimes negative (–5 to –25 dB for low frequencies)	Rarely < 0 dB
Tympanometry	Type A or B or C tympanogram	Type A tympanogram	Type A tympanogram
Acoustic reflex	Absent	Present	Generally present
Tullio phenomenon and/or Hennebert sign	Absent	May be present	Absent
Otoacoustic emissions	Absent	May be present	Generally absent
ECochG	Normal	Generally elevated SP/AP ratio	SP/AP ratio generally > 0.37
Cervical VEMP	Absent	Low threshold and large amplitude	Generally absent or lower peak-to-peak amplitude at 500 Hz than 1000 Hz (tuning shift)
CT/MRI scan	Middle ear abnormality	Third-window lesion	Distension of the structures filled with endolymph at MRI

ECochG: Electrocochleography; VEMP: vestibular evoked myogenic potentials; CT: computed tomography; MRI: magnetic resonance imaging; SP: Summating Potentials, AP: Action Potentials.

with among healthy controls^[2]. The pursuit of cochlear implantation is suggested in patients with severe and profound hearing loss^[40].

Cochlear Dehiscence

Cochlear dehiscence refers to a thinning of the bone plate that covers the cochlea, which results in the establishment of direct communication between the inner-ear and the middle-ear cavity or neurovascular structure. When the scala vestibuli of the cochlea is compromised, a third-window mechanism occurs, decreasing cochlear input impedance and reducing the pressure within the scala vestibuli produced by sound^[4]. Kim and Wilson^[41] described the case of a dehiscence between the cochlea and carotid canal with an ABG that persisted after uneventful stapedectomy, while Fang reported a dehiscence that involved the geniculate ganglion, labyrinthine, or tympanic segments of the facial nerve^[42].

Endolymphatic Hydrops (EH)

Endolymphatic hydrops (EH) is an idiopathic condition characterized by the enlargement of endolymphatic volumes in the inner ear with distension of Reissner's membrane into the scala vestibuli of the cochlea and/or the saccule, utricle, and ampullae of the semicircular canals. EH is the pathogenic mechanism that underlies Ménière's disease, a disorder of the inner-ear characterized by fluctuating hearing loss, vertigo attacks, tinnitus, and aural fullness^[43].

EH typically results in SNHL; however, low-frequency ABGs can also be found in the absence of middle-ear pathology^[44]. An ABG in EH can be explained by the onset of increased perilymphatic pressure with a consequent decrease of stapes mobility or by saccular dilation, leading to a reduction in stapedial mobility as found by Okuno and Sando in the temporal bones of patients with Ménière's disease^[45].

Recently, 3-tesla MRI has been used to evaluate for the presence of EH^[44], revealing a direct relationship between vertigo attacks and low-frequency

ABGs due to a worsening of EH. Sugimoto et al.^[46] noted that the average bone-conduction thresholds in patients with EH were higher in those with EH adjacent to the stapes footplate, with more frequent ABGs at 250 Hz. Moreover, these authors found that patients with significant cochlear and vestibular EH adjacent to the stapes footplate had more frequent and longer Ménière's disease crises relative to those with EH nonadjacent to the stapes footplate. Elsewhere, Maheu et al.^[47] found that the mean ABG frequency is clinically higher in patients with Ménière's disease than in EH patients, without noticing a significant correlation between the mean ABG frequency and the summating potential (SP)/action potential (AP) area or amplitude ratio. However, Bess et al.^[1] reported three cases of unexplained CHL suggesting that the cause of secondary EH and subsequent ABGs in these cases could be an anomaly of the inner-ear fluids.

In 1965, Godlowski^[48] first described the causative relation between altered venous drainage of the vestibular and/or the cochlear veins into the venous cerebrospinal system and secondary EH. Cassandro et al.^[49] presented a case of dural arteriovenous fistulas (DAVF) in a 55-year-old female patient with unilateral left ear pulsatile tinnitus and CHL, supposing that type II DAVF provokes subclinical intracranial hypertension with a prolonged parenchymal phase of the venous outflow. This mechanism could be responsible for a disturbance in the stria vascularis circulation, resulting in pulsatile tinnitus, and CHL. To our knowledge, only one case of hearing loss associated with DAVF has been reported in the literature; however, the hearing loss was sensorineural^[50]. An alteration in the venous cerebral circulation can indicate otologic symptoms like pulsatile tinnitus as a result of labyrinth hydromechanics in conditions such as bilateral transverse sinus stenosis or DAVF^[50]. In these conditions, there is a communication between intracranial fluids and the cochlear aqueduct.

Clinical Investigations

The typical conditions presenting with an ABG are pathologies af-

fecting the outer or middle ear. Therefore, the completion of accurate otoscopic, nasal, and rhinopharyngeal examinations is mandatory to assess the external auditory canal, tympanic membrane, and peritubal areas, followed by complete immittance testing. Details about the diagnostic strategy to differentiate middle-ear involvement, third-window lesions, and EH conditions are suggested in Table 1.

Findings of a type A tympanometry curve and normally evoked acoustic reflexes in patients presenting with an ABG generally exclude an alteration of the middle-ear and should suggest a third-window lesion^[12]. Cervical VEMP testing and the measurement of otoacoustic emissions are also helpful in elucidating the ABG condition, as both cervical VEMP and otoacoustic emissions are present in third-window lesions and absent in patients with middle-ear disease^[12,51]. Furthermore, cervical VEMP can be beneficial in evaluating EH, showing a biphasic complex greater in amplitude and lower in threshold for 1,000 Hz tone-burst stimuli relative to 500-Hz ones (tuning shift)^[52]. An elevated SP/AP ratio as measured by electrocochleography has long been considered the electrophysiological correlate of EH-related clinical conditions. Similarly, an SP/AP ratio higher than 0.37 is considered indicative of EH^[52].

Laser Doppler vibrometry can also help in differentiating middle-ear from the inner-ear diseases in patients with ABG when measuring umbo velocity^[12]. Bedside vestibular examination can be useful to evaluate patients affected by third-window lesions given that sound stimulation (Tullio phenomenon), tragal compression (Hennebert sign), or pressure changes in the external ear canal (Valsalva maneuvers) may elicit dizziness and vertical-torsional nystagmus^[53].

Imaging of third-window mechanism-based lesions relies on CT and MRI. High-resolution CT of the temporal bone is recommended to correctly evaluate third-window lesions^[24]. CT has a central role in identifying semicircular canal dehiscence; MRI is equally sensitive in differentiating fluid from bone but should not be used as the preferred tool in the evaluation of third-window lesions^[54]. MRI alongside magnetic resonance angiography may be useful for assessing central vascular abnormalities like DAVF. EH may be evaluated using MRI at 24 hours after the intratympanic administration of gadolinium-based contrast^[54].

CONCLUSION

An ABG is an audiological finding typical of pathologies that involve the external or middle-ear; sometimes, an ABG can be found in conditions affecting the inner-ear due to a third-window mechanism or in idiopathic or secondary EH conditions such as central vascular abnormalities. Although making a definitive diagnosis is often challenging, accurate clinical, audiological, and vestibular evaluations can be suggestive of the underlying condition; however, radiological assessments by CT and/or MRI are mandatory to confirm any diagnostic suspicion.

Peer-review: Externally peer-reviewed.

Author Contributions: Concept - C.C., A.S.; Design - A.S.; Supervision - A.G., E.C.; Data Collection and/or Processing - A.D.S., F.M.G.; Analysis and/or Interpretation - A.D.S., F.M.G.; Literature Search - M.C., D.T.; Writing - M.R.; Critical Reviews - M.d.V., A.G., E.C.

Conflict of Interest: The authors have no conflict of interest to declare.

Financial Disclosure: The authors declared that this study has received no financial support.

REFERENCES

1. Bess FH, Miller GW, Glasscock ME, 3rd, Bratt GW. Unexplained conductive hearing loss. *South Med J* 1980; 73: 335-8. [\[Crossref\]](#)
2. Amilibia Cabeza E, Holgado Perez S, Perez Grau M, Moragues Pastor C, Roca-Ribas Serda F, Quer Agusti M. Hearing in Paget's disease of bone. *Acta Otorrinolaringol Esp* 2019; 70: 89-96. [\[Crossref\]](#)
3. Mancini P, Atturo F, Di Mario A, Portanova G, Ralli M, De Virgilio A, et al. Hearing loss in autoimmune disorders: Prevalence and therapeutic options. *Autoimmun Rev* 2018; 17: 644-52. [\[Crossref\]](#)
4. Merchant SN, Rosowski JJ. Conductive hearing loss caused by third-window lesions of the inner ear. *Otol Neurotol* 2008; 29: 282-9. [\[Crossref\]](#)
5. Ho ML, Moonis G, Halpin CF, Curtin HD. Spectrum of Third Window Abnormalities: Semicircular Canal Dehiscence and Beyond. *AJNR Am J Neuroradiol* 2017; 38: 2-9. [\[Crossref\]](#)
6. Tonndorf J, Tabor JR. Closure of the cochlear windows: its effect upon air- and bone-conduction. *Ann Otol Rhinol Laryngol* 1962; 71: 5-29. [\[Crossref\]](#)
7. Shuman AG, Rizvi SS, Pirouet CW, Heidenreich KD. Hennebert's sign in superior semicircular canal dehiscence syndrome: a video case report. *Laryngoscope* 2012; 122: 412-4. [\[Crossref\]](#)
8. Minor LB. Clinical manifestations of superior semicircular canal dehiscence. *Laryngoscope* 2005; 115: 1717-27. [\[Crossref\]](#)
9. Chien WW, Carey JP, Minor LB. Canal dehiscence. *Curr Opin Neurol* 2011; 24: 25-31. [\[Crossref\]](#)
10. Crovetto M, Whyte J, Rodriguez OM, Lecumberri I, Martinez C, Elexpuru J. Anatomic-radiological study of the Superior Semicircular Canal Dehiscence Radiological considerations of Superior and Posterior Semicircular Canals. *Eur J Radiol* 2010; 76: 167-72. [\[Crossref\]](#)
11. Songer JE, Rosowski JJ. The effect of superior-canal opening on middle-ear input admittance and air-conducted stapes velocity in chinchilla. *J Acoust Soc Am* 2006; 120: 258-69. [\[Crossref\]](#)
12. Mikulec AA, McKenna MJ, Ramsey MJ, Rosowski JJ, Herrmann BS, Rauch SD, et al. Superior semicircular canal dehiscence presenting as conductive hearing loss without vertigo. *Otol Neurotol* 2004; 25: 121-9. [\[Crossref\]](#)
13. Songer JE, Rosowski JJ. A superior semicircular canal dehiscence-induced air-bone gap in chinchilla. *Hear Res* 2010; 269: 70-80. [\[Crossref\]](#)
14. Cloutier JF, Belair M, Saliba I. Superior semicircular canal dehiscence: positive predictive value of high-resolution CT scanning. *Eur Arch Otorhinolaryngol* 2008; 265: 1455-60. [\[Crossref\]](#)
15. Lee GS, Zhou G, Poe D, Kenna M, Amin M, Ohlms L, et al. Clinical experience in diagnosis and management of superior semicircular canal dehiscence in children. *Laryngoscope* 2011; 121: 2256-61. [\[Crossref\]](#)
16. Nomiya S, Cureoglu S, Kariya S, Morita N, Nomiya R, Schachern PA, et al. Posterior semicircular canal dehiscence: a histopathologic human temporal bone study. *Otol Neurotol* 2010; 31: 1122-7. [\[Crossref\]](#)
17. Bassim MK, Patel KG, Buchman CA. Lateral semicircular canal dehiscence. *Otol Neurotol* 2007; 28: 1155-6. [\[Crossref\]](#)
18. Paladin AM, Phillips GS, Raske ME, Sie KC. Labyrinthine dehiscence in a child. *Pediatr Radiol* 2008; 38: 348-50. [\[Crossref\]](#)
19. Bance M. When is a conductive hearing loss not a conductive hearing loss? Causes of a mismatch in air-bone threshold measurements or a "pseudo-conductive" hearing loss. *J Otolaryngol* 2004; 33: 135-8. [\[Crossref\]](#)
20. Chu H, Chung WH. Images in clinical medicine. Perilymph fistula test. *N Engl J Med* 2012; 366: e8. [\[Crossref\]](#)
21. Chen Z, Dongzhen, Wu Y, Shi H, Zhou H, Wang J, et al. Surgical treatment of labyrinthine fistula caused by cholesteatoma with semicircular canal occlusion. *Acta Otolaryngol* 2010; 130: 75-8. [\[Crossref\]](#)
22. Kodama A, Sando I. Postnatal development of the vestibular aqueduct and endolymphatic sac. *Ann Otol Rhinol Laryngol Suppl* 1982; 96: 3-12.
23. Valvassori GE, Clemis JD. The large vestibular aqueduct syndrome. *Laryngoscope* 1978; 88: 723-8. [\[Crossref\]](#)
24. Ho ML. Third Window Lesions. *Neuroimaging Clin N Am* 2019; 29: 57-92. [\[Crossref\]](#)

25. Rah YC, Kim AR, Koo JW, Lee JH, Oh SH, Choi BY. Audiologic presentation of enlargement of the vestibular aqueduct according to the SLC26A4 genotypes. *Laryngoscope* 2015; 125: E216-22. [\[Crossref\]](#)
26. Yang CJ, Lavender V, Meinzen-Derr JK, Cohen AP, Youssif M, Castiglione M, et al. Vestibular pathology in children with enlarged vestibular aqueduct. *Laryngoscope* 2016; 126: 2344-50. [\[Crossref\]](#)
27. Zhou G, Gopen Q. Characteristics of vestibular evoked myogenic potentials in children with enlarged vestibular aqueduct. *Laryngoscope* 2011; 121: 220-5. [\[Crossref\]](#)
28. Boston M, Halsted M, Meinzen-Derr J, Bean J, Vijayasekaran S, Arjmand E, et al. The large vestibular aqueduct: a new definition based on audiologic and computed tomography correlation. *Otolaryngol Head Neck Surg* 2007; 136: 972-7. [\[Crossref\]](#)
29. Sugiura M, Naganawa S, Nakashima T, Misawa H, Nakamura T. Magnetic resonance imaging of endolymphatic sac in acute low-tone sensorineural hearing loss without vertigo. *ORL J Otorhinolaryngol Relat Spec* 2003; 65: 254-60. [\[Crossref\]](#)
30. Patel ND, Ascha MS, Manzoor NF, Gupta A, Semaan M, Megerian C, et al. Morphology and cochlear implantation in enlarged vestibular aqueduct. *Am J Otolaryngol* 2018; 39: 657-63. [\[Crossref\]](#)
31. Bostic K, Lewis RM, Chai B, Manganella JL, Barrett DL, Kawai K, et al. Enlarged Vestibular Aqueduct and Cochlear Implants: The Effect of Early Counseling on the Length of Time Between Candidacy and Implantation. *Otol Neurotol* 2018; 39: e90-e5. [\[Crossref\]](#)
32. Grimmer JF, Hedlund G, Park A. Steroid treatment of hearing loss in enlarged vestibular aqueduct anomaly. *Int J Pediatr Otorhinolaryngol* 2008; 72: 1711-5. [\[Crossref\]](#)
33. Schild C, Prera E, Lublinghoff N, Arndt S, Aschendorff A, Birkenhager R. Novel mutation in the homeobox domain of transcription factor POU3F4 associated with profound sensorineural hearing loss. *Otol Neurotol* 2011; 32: 690-4. [\[Crossref\]](#)
34. Kumar G, Castillo M, Buchman CA. X-linked stapes gusher: CT findings in one patient. *AJNR Am J Neuroradiol* 2003; 24: 1130-2.
35. Sennaroglu L, Bajin MD. Incomplete partition type III: A rare and difficult cochlear implant surgical indication. *Auris Nasus Larynx* 2018; 45: 26-32. [\[Crossref\]](#)
36. Santos F, McCall AA, Chien W, Merchant S. Otopathology in Osteogenesis Imperfecta. *Otol Neurotol* 2012; 33: 1562-6. [\[Crossref\]](#)
37. Ting TH, Zacharin MR. Hearing in bisphosphonate-treated children with osteogenesis imperfecta: our experience in thirty six young patients. *Clin Otolaryngol* 2012; 37: 229-33. [\[Crossref\]](#)
38. Swinnen FK, De Leenheer EM, Coucke PJ, Cremers CW, Dhooge IJ. Stapes surgery in osteogenesis imperfecta: retrospective analysis of 34 operated ears. *Audiol Neurotol* 2012; 17: 198-206. [\[Crossref\]](#)
39. Bahmad F Jr, Merchant SN. Paget disease of the temporal bone. *Otol Neurotol* 2007; 28: 1157-8. [\[Crossref\]](#)
40. Deep NL, Besch-Stokes JG, Lane JI, Driscoll CLW, Carlson ML. Paget's Disease of the Temporal Bone: A Single-Institution Contemporary Review of 27 Patients. *Otol Neurotol* 2017; 38: 907-15. [\[Crossref\]](#)
41. Kim HH, Wilson DF. A third mobile window at the cochlear apex. *Otolaryngol Head Neck Surg* 2006; 135: 965-6. [\[Crossref\]](#)
42. Fang CH, Chung SY, Blake DM, Vazquez A, Li C, Carey JP, et al. Prevalence of Cochlear-Facial Dehiscence in a Study of 1,020 Temporal Bone Specimens. *Otol Neurotol* 2016; 37: 967-72. [\[Crossref\]](#)
43. Scarpa A, Ralli M, Cassandro C, Gioacchini FM, Alicandri-Ciuffelli M, Viola P, et al. Low-dose intratympanic gentamicin administration for unilateral Meniere's Disease using a method based on clinical symptomatology: preliminary results. *Am J Otolaryngol* 2019; 40: 102289. [\[Crossref\]](#)
44. Lee HJ, Jeon JH, Park S, Kim BG, Lee WS, Kim SH. Prevalence and clinical significance of spontaneous low-frequency air-bone gaps in Meniere's disease. *Otol Neurotol* 2014; 35: 489-94. [\[Crossref\]](#)
45. Okuno H, Sando I. Anatomy of the round window. A histopathological study with a graphic reconstruction method. *Acta Otolaryngol* 1988; 106: 55-63. [\[Crossref\]](#)
46. Sugimoto S, Yoshida T, Teranishi M, Okazaki Y, Naganawa S, Sone M. The relationship between endolymphatic hydrops in the vestibule and low-frequency air-bone gaps. *Laryngoscope* 2018; 128: 1658-62. [\[Crossref\]](#)
47. Maheu M, Alhabib SF, Landry SP, Nader ME, Champoux F, Saliba I. Ear Fullness as a Symptom of Endolymphatic Hydrops in non-Meniere's Patient. *J Int Adv Otol* 2017; 13: 379-84. [\[Crossref\]](#)
48. Godlowski Z. Pathogenesis and management of Meniere's syndrome in terms of microcirculation. Pharmacologic decompression of the endolymphatic hydrops. *Angiology* 1965; 16: 644-50. [\[Crossref\]](#)
49. Cassandro E, Cassandro C, Sequino G, Scarpa A, Petrolo C, Chiarella G. Inner Ear Conductive Hearing Loss and Unilateral Pulsatile Tinnitus Associated with a Dural Arteriovenous Fistula: Case Based Review and Analysis of Relationship between Intracranial Vascular Abnormalities and Inner Ear Fluids. *Case Rep Otolaryngol* 2015; 2015: 817313. [\[Crossref\]](#)
50. Kim MS, Oh CW, Han DH, Kwon OK, Jung HW, Han MH. Intraosseous dural arteriovenous fistula of the skull base associated with hearing loss. Case report. *J Neurosurg* 2002; 96: 952-5. [\[Crossref\]](#)
51. Scarpa A, Gioacchini FM, Cassandro E, Tulli M, Ralli M, Re M, et al. Clinical application of cVEMPs and oVEMPs in patients affected by Meniere's disease, vestibular neuritis and benign paroxysmal positional vertigo: a systematic review. *Acta Otorhinolaryngol Ital* 2019; 39: 298-307. [\[Crossref\]](#)
52. Maxwell R, Jerin C, Gurkov R. Utilisation of multi-frequency VEMPs improves diagnostic accuracy for Meniere's disease. *Eur Arch Otorhinolaryngol* 2017; 274: 85-93. [\[Crossref\]](#)
53. Minor LB, Solomon D, Zinreich JS, Zee DS. Sound- and/or pressure-induced vertigo due to bone dehiscence of the superior semicircular canal. *Arch Otolaryngol Head Neck Surg* 1998; 124: 249-58. [\[Crossref\]](#)
54. Giesemann A, Hofmann E. Some Remarks on Imaging of the Inner Ear: Options and Limitations. *Clin Neuroradiol* 2015; 25 Suppl 2: 197-203. [\[Crossref\]](#)