

Case Report

Different Audiologic Outcomes in Twins with Congenital Cytomegalovirus Infection

Cecilia Botti , Silvia Palma, Maria Federica Roversi, Daniele Monzani , Alberto Berardi ,
Elisabetta Genovese 

Department of Otolaryngology - Head and Neck Surgery, University Hospital of Modena, Modena, Italy (CB)

Department of Audiology, Primary Care Unit, University Hospital of Modena, Modena, Italy (SP)

Department of Medical and Surgical Sciences of the Mother, Children and Adults, Neonatal Intensive Care Unit, University of Modena and Reggio Emilia, Modena, Italy (MFR, AB)

Department of Diagnostic, Clinical and Public Health, University of Modena and Reggio Emilia, Modena, Italy (DM, EG)

ORCID iDs of the authors: C.B. 0000-0002-0136-141X; D.M. 0000-0002-8971-3597; A.B. 0000-0001-5225-0982; E.G. 0000-0002-1902-2467.

Cite this article as: Botti C, Palma S, Federica Roversi M, Monzani D, Berardi A, Genovese E. Different Audiologic Outcomes in Twins with Congenital Cytomegalovirus Infection. *J Int Adv Otol* 2020; 16(1): 130-3.

Congenital cytomegalovirus (cCMV) infection is a major cause of hearing loss in children. A few cases of cCMV twin pregnancies are reported in the literature. Twins can react differently to maternal infection, but hearing loss is rarely evaluated. Two couples of twins with cCMV infection and different audiologic outcomes are reported. The first couple of twins was composed by two male twins, both affected by cCMV infection. The first born had normal hearing function, and the second born had sensorineural hearing loss (SNHL). In the second couple, a male and a female twin, only the male twin was affected by cCMV infection, and both had normal hearing function. In this case series, an interesting finding was the association between the presence of viral DNA in liquor and hearing loss in one newborn. Further research is needed to better understand the pathophysiology of SNHL caused by cCMV infection.

KEYWORDS: Congenital cytomegalovirus infection, congenital hearing loss, twins

INTRODUCTION

Sensorineural hearing loss (SNHL) is the most common congenital sensory deficit. At least one child in 1000 is born with bilateral SNHL of at least 40 dB ^[1]. The etiology of hearing loss at birth is related to 50% environmental causes and 50% genetic causes. The most frequent environmental causes are infectious diseases, such as congenital cytomegalovirus (cCMV) infection; other causes are prematurity and asphyxiation. cCMV is the most common congenital infection, and it is the main cause of non-inherited SNHL in children in industrialized countries. It is estimated that 23% of children with cCMV infection will develop an SNHL ^[2], affecting 30%-65% of symptomatic children and 7%-15% of asymptomatic ones ^[1]. The pathophysiology of virus transmission relative to inner ear damage is still debated, and for this purpose, twins can be an interesting model. Some cases of cCMV twin pregnancies are reported in the literature; however, hearing loss is rarely discussed.

Two couples of twins with cCMV are presented in this case study. All newborns underwent audiological screening with otoacoustic emissions (OEs) and auditory brainstem responses (ABRs). Cytomegalovirus (CMV) DNA was searched in blood and cerebrospinal fluid by polymerase chain reaction (PCR) according to the recent guidelines ^[3].

CASE PRESENTATIONS

Case 1

Two male neonates are presented. They were born by a bichorionic diamniotic twin pregnancy at 30w+5 in 2013 because of oligohydramnios and flussimetric alterations in one fetus. Maternal serology for CMV had not been studied. The first born had a birth weight of 1568 g (70°) and cranial circumference of 27 cm (20°), and the second born had a birth weight of 990 g (7°) and cranial circumference of 26.5 cm (12°). They did not present signs of cCMV at birth. Maternal urinary sample was checked for CMV 1 day

after delivery with positive result. CMV serology was suggestive for recent primary infection in both twins (positive IgM and IgG). CMV DNA was searched in newborn blood and cerebrospinal fluid (CSF).

First born: Qualitative blood PCR was positive at birth (43.755/mL) and after 1 month (2.524/mL). CSF PCR was negative at birth. ABR thresholds at 3 and 6 months were normal. Pure tone audiometry (PTA) was 25 dB at 12 months in free field.

Second born: Qualitative blood PCR was positive at birth (28.862/mL) and after 1 month (3.833/mL). CSF PCR was positive at birth (104/mL), and for this reason, he was treated with ganciclovir (6 mg/kg/12 h) for 3 weeks. He presented with altered ABR fluctuating thresholds with 60 dB normal adult hearing level (nHL) bilaterally at 3 months, 45 dB at 6 months, and 60 dB at the right side and 45 dB at the left side at 9 months. He has been using hearing aids since aged 9 months. PTA was 50 dB at 18 months in free field, which was confirmed in the following checkups.

They had hyperbilirubinemia treated with phototherapy and were both treated with positive pressure ventilation and gentamicin administration (2.5 mg/kg/die) for 5 days. Cerebral ultrasonography, echocardiography, and fundus oculi were normal in both twins.

Case 2

A male twin and a female twin were born in July 2017 at 32 weeks of gestation with urgent cesarean delivery because of alterations in cardiotocography in the female fetus. The mother had positive CMV on urine sample at birth.

Male twin: The birth weight of the male twin was 1694 g. He was diagnosed with cCMV as qualitative blood PCR was positive at birth (17.287/mL); CSF PCR was very low at birth but positive (target detected but not measured). He needed non-invasive ventilation for 5 days. Encephalic ultrasonography showed hemorrhage of the germinal matrix, and the first encephalic magnetic resonance imaging (MRI) showed alterations in the subcortical white matter. The child was treated with antiviral systemic therapy with valganciclovir per os at 35 weeks of gestation. The second MRI performed after some months was normal. OEs were passed bilaterally at birth. ABR thresholds at 3 months were 30 dB nHL bilaterally and normal ABR and hearing threshold in free field at aged 12 months.

Female twin: The birth weight of the female twin was 1412 g. She needed non-invasive ventilation for 3 days, had normal encephalic ultrasonography, and was not affected by cCMV. She was dismissed after 4 weeks of recovery. OEs were passed bilaterally at birth, and ABR was normal at aged 12 months.

DISCUSSION

The pathophysiology of cCMV transmission from mother to fetus is still unclear. The virus can be transmitted through placental blood, contact with infected vaginal secretions, or milk. Transmission of the virus results from primary maternal infection during pregnancy, from reactivation of a previous infection, or from reinfection [2]. Twins represent an interesting study model as both are exposed to the same risk factors during pregnancy. Case reports or series of twins with cCMV are described, but the literature lacks systematic studies. cCMV

infection in twins involves only one twin in most of the cases reported [4], and the placenta is suspected to play an important pathogenetic role in virus transmission, as it can be an important barrier. In fact, as reported in a previous study [5], only one twin is usually affected by severe cCMV in bicorial diamniotic pregnancy. However, the placenta is not routinely studied, and data about it are not available in the cases reported.

Neonatal diagnosis of cCMV is obtained by virus isolation in tissue cultures or research of viral DNA (real-time PCR) in urine or saliva during the first 3 weeks of life of a newborn. If positive, CMV DNA (real-time PCR) is searched in the blood and CSF. Urinary sample is checked 1 day after delivery in preterm newborn <35 weeks. The diagnostic-therapeutic management indicated in the Italian Society of Neonatology [6] guidelines is reported in Figure 1.

Most infants are asymptomatic at birth, whereas 10%-15% are symptomatic, with cognitive impairment, retinitis, and cerebral palsy [7]. Hearing loss is the most common sequelae of cCMV infection, and it can be present at birth or with late onset. Auditory thresholds are stable over time in most of the cases and unstable in 30% of the cases, with improvement, worseness, or fluctuation [8, 9]. Therefore, audiological follow-up is necessary to identify children with SNHL, especially in case of late onset.

Universal newborn hearing screening programs have been established in many countries, with the identification of 2-4 children per 1000 with SNHL. The early identification of SNHL improves speech and language in children with SNHL [10]. In our region in Emilia Romagna, Italy, all newborns are tested with OEs and, in case of audiological risk factors, also with ABRs.

Currently, there is no universal screening program for cCMV, and this lack of screening program is still an object of debate. In the absence of a universal screening for cCMV, asymptomatic children can be misdiagnosed, but they are at risk of developing an SNHL. Moreover, a universal newborn screening program could miss children with cCMV who develop late-onset SNHL. Predicting which children with cCMV will develop hearing loss and whether the loss will deteriorate is still a challenge. As consequence, there is an increasing interest in the association of a universal cCMV screening with newborn hearing screening to identify and adequately follow-up children with cCMV. In some countries, a PCR-based assay using a dried umbilical cord is performed to screen newborns for cCMV; if the umbilical cord is preserved, it can also be used to retrospectively detect cCMV in infants affected by SNHL [11].

In *Case 1*, both twins were affected by cCMV, but only the second born had bilateral SNHL. In the *second born*, the viral load was higher, and he had positive CMV PCR in CSF. Both twins presented with hyperbilirubinemia, and they both underwent gentamicin administration and mechanical ventilation, which are risk factors for SNHL in newborns. In *Case 2*, only the male twin was affected by cCMV, with very low levels of virus DNA in liquor. They both had normal hearing function.

The only newborn affected by SNHL was one of the two newborns with positive levels of viral DNA in CSF. In contrast, the two newborns

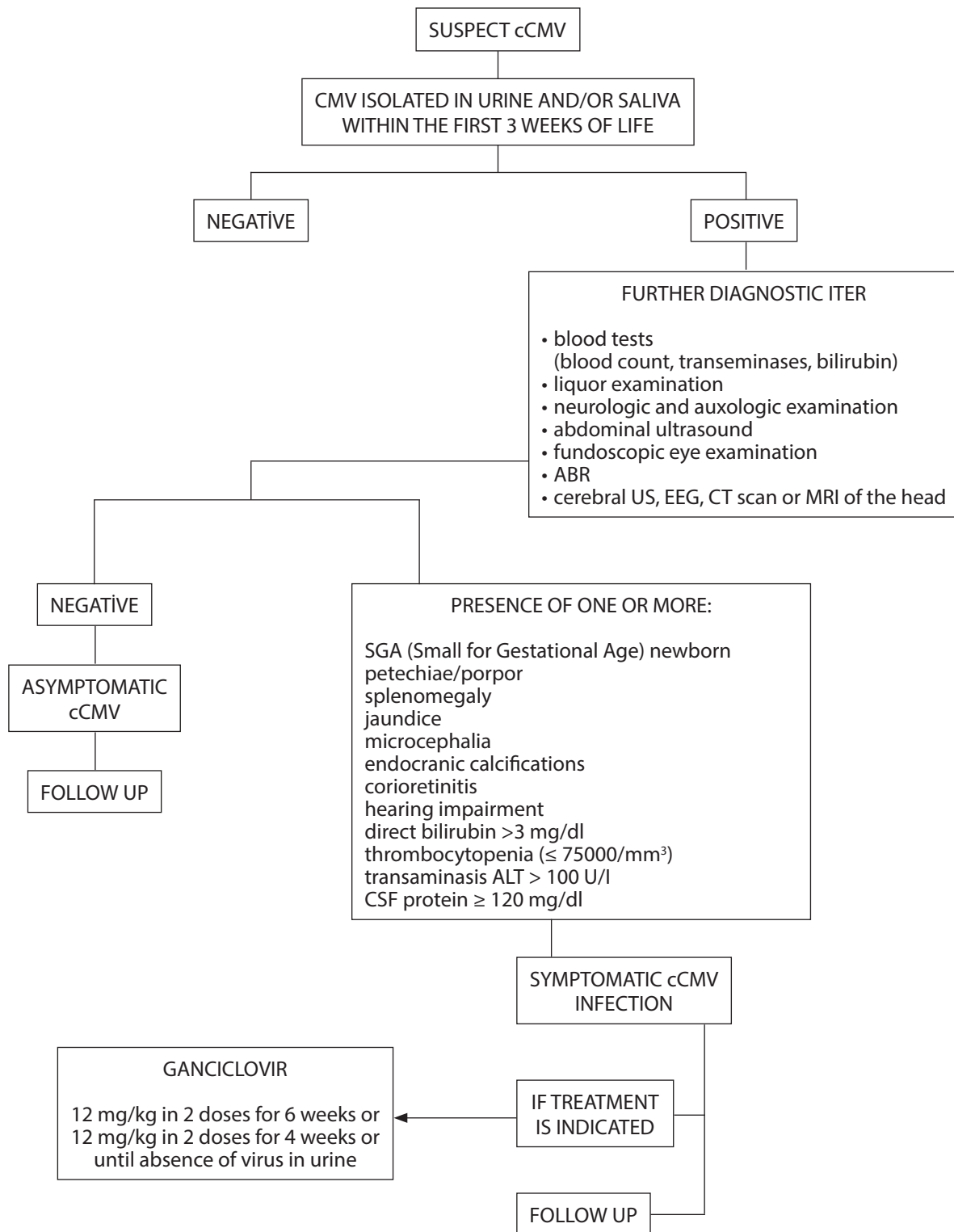


Figure 1. Protocol in use in case of congenital cytomegalovirus infection in the Maternal–Infancy Department of the University Hospital of Modena, as indicated in the Italian Society of Neonatology guidelines.

with negative CSF had normal hearing function. This is an interesting finding in this case series. Therefore, given the intimate relationship between the CFS and endolymph, we can hypothesize that internal ear damage could be related to the presence of viral DNA in liquor.

However, this is only a theoretical hypothesis, since it is based on the findings of a case series. Previous studies ^[12, 13] demonstrated histopathological damage to the marginal layer of the stria vascularis and Reissner’s membrane in human fetuses with high viral load in the

amniotic fluid. This could affect endocochlear potential formation and ion homeostasis, in particular potassium recycling. However, the mechanism of the pathogenesis of cCMV-related SNHL is still unclear. Further studies are needed to better understand the pathogenesis of cCMV-related SNHL.

Antiviral drugs, such as ganciclovir and valganciclovir, are the only therapies available at present. The actual guidelines^[3] suggest that therapy should be performed in the first 30 days of life only in symptomatic cCMV cases with central nervous system diseases or severe organ disease. In *Case 1*, antiviral therapy was not effective in avoiding SNHL. Long-term efficacy of antiviral drugs in cCMV is still not known, and for this reason, long-term follow-up is fundamental^[7].

CONCLUSION

High levels of CMV in CSF could be related to inner ear damage. However, more studies about its pathophysiology are needed, and twins are a good physiopathological model. Newborn screening programs and long-term follow-up are important to individuate children with hearing loss related to cCMV.

Informed Consent: Written informed consent was obtained from the patients who participated in this study.

Peer-review: Externally peer-reviewed.

Author Contributions: Concept – S.P., M.F.R., C.B.; Design – S.P., M.F.R., A.B.; Supervision – A.B., E.G.; Resource – M.F.R., S.P., E.G.; Materials – C.B., M.F.R., S.P.; Data Collection and/or Processing – S.P., M.R.R.; Analysis and/or Interpretation – C.B., S.P.; Literature Search – C.B., M.F.R.; Writing – C.B., S.P., M.F.R.; Critical Reviews – A.B., E.G.

Acknowledgements: The authors thank to Patrizia Cardini and Paola Allegra.

Conflict of Interest: The authors have no conflict of interest to declare.

Financial Disclosure: The authors declared that this study has received no financial support.

REFERENCES

1. Smith RJ, Bale JF Jr, White KR. Sensorineural hearing loss in children. *Lancet* 2005; 365: 879-90. [\[Crossref\]](#)
2. Fowler KB, Boppana SB. Congenital cytomegalovirus (CMV) infection and hearing deficit. *J Clin Virol* 2006; 35: 226-31. [\[Crossref\]](#)
3. Luck SE, Wieringa JW, Blázquez-Gamero D, Henneke P, Schuster K, Butler K, et al. Congenital Cytomegalovirus: A European Expert Consensus Statement on Diagnosis and Management. *Pediatr Infect Dis J* 2017; 36: 1205-13. [\[Crossref\]](#)
4. Lazzarotto T, Gabrielli L, Foschini MP, Lanari M, Guerra B, Eusebi V, et al. Congenital cytomegalovirus infection in twin pregnancies: viral load in the amniotic fluid and pregnancy outcome. *Pediatrics* 2003; 112: e153-7. [\[Crossref\]](#)
5. Yinon Y, Yagel S, Tepperberg-Dikawa M, Feldman B, Schiff E, Lipitz S. Prenatal diagnosis and outcome of congenital cytomegalovirus infection in twin pregnancies. *BJOG* 2006; 113: 295-300. [\[Crossref\]](#)
6. Linee guida SIN. <http://www.simast.it/linee-guida/percorsi-diagnostico-assist/citomegalovirus.pdf>
7. Kadambari S, Williams EJ, Luck S, Griffiths PD, Sharland M. Evidence based management guidelines for the detection and treatment of congenital CMV. *Early Hum Dev* 2011; 87: 723-8. [\[Crossref\]](#)
8. Grosse SD, Ross DS, Dollard SC. Congenital cytomegalovirus (CMV) infection as a cause of permanent bilateral hearing loss: a quantitative assessment. *J Clin Virol* 2008; 41: 57-62. [\[Crossref\]](#)
9. Rosenthal LS, Fowler KB, Boppana SB, Britt WJ, Pass RF, Schmid SD, et al. Cytomegalovirus shedding and delayed sensorineural hearing loss: results from longitudinal follow-up of children with congenital infection. *Pediatr Infect Dis J* 2009; 28: 515-20. [\[Crossref\]](#)
10. American Academy of Pediatrics, Joint Committee on Infant Hearing. Year 2007 position statement: Principles and guidelines for early hearing detection and intervention programs. *Pediatrics* 2007; 120: 898-921. [\[Crossref\]](#)
11. Ogawa H, Matsui T, Baba Y, Yamada N, Suzuki Y, Suzutani T. Presence of cytomegalovirus in the perilymphatic fluid of patients with profound sensorineural hearing loss caused by congenital cytomegalovirus infection. *Acta Otolaryngol* 2016; 136: 132-5. [\[Crossref\]](#)
12. Teissier N, Delezoide AL, Mas AE, Khung-Savatovsky S, Bessières B, Nardelli J, et al. Inner ear lesions in congenital cytomegalovirus infection of human fetuses. *Acta Neuropathol* 2011; 122: 763-74. [\[Crossref\]](#)
13. Gabrielli L, Bonasoni MP, Santini D, Piccirilli G, Chierighin A, Guerra B, et al. Human fetal inner ear involvement in congenital cytomegalovirus infection. *Acta Neuropathol Commun* 2013; 1: 63. [\[Crossref\]](#)