

Original Article

The Effect of Allantoin on Chronic Perforation of Rat Tympanic Membrane

Nuri Ünsal¹, Ali Bayram¹, Ebru Akay², Mehmet Yaşar¹¹Department of ENT, Kayseri City Training and Research Hospital, Kayseri, Turkey²Department of Pathology, Kayseri City Training and Research Hospital, Kayseri, Turkey

ORCID IDs of the authors: N.Ü. 0000-0002-5247-5345; A.B. 0000-0002-0061-1755; E.A. 0000-0003-1190-1800; M.Y. 0000-0002-8246-6853

Cite this article as: Ünsal N, Bayram A, Akay E, Yaşar M. The effect of Allantoin on chronic perforation of rat tympanic membrane. *J Int Adv Otol*. 2021;17(3):251-254.**OBJECTIVES:** This study aimed to investigate the effectiveness of topical allantoin application on wound healing in a rat chronic tympanic membrane perforation (TMP) model.**METHODS:** A chronic TMP model was established with 25 healthy, female, 6-month-old, Sprague Dawley rats with chemical damage (trichloroacetic acid 50%). The rats were randomly assigned into 3 groups as follows: Group 1 (10 rats, 20 ears) was administered intratympanic (IT) 20 µL/day 0.57% allantoin solution 7 times, every other day; Group 2 (5 rats, 10 ears) received no substance; Group 3 (10 rats, 20 ears) received IT 20 µL/day distilled water 7 times, every other day. After tympanic membrane (TM) examination with an otoendoscope, histopathological examination of the TM was performed to evaluate neutrophil activity, chronicity, histiocytes, keratin accumulation, subepithelial edema, congestion, fibroblast proliferation, neovascularization, and tympanic membrane thickness.**RESULTS:** Two TM perforations, 1 in Group 1 and 1 in Group 3, were not healed whereas TM perforations in 48 ears demonstrated closure at the end of the study. According to the histopathological examination, neutrophil activity and fibroblast proliferation were significantly higher in Group 1. There was no significant difference between the groups in terms of other histopathological parameters.**CONCLUSION:** To the best of our knowledge, this is the first study investigating the effect of allantoin in an experimental chronic TMP model. According to the histopathological findings, allantoin may have positive effects on the wound healing process of chronic TMP.**KEYWORDS:** Allantoin, tympanic membrane perforation, chronic, wound healing

INTRODUCTION

Chronic tympanic membrane perforation (TMP) is the presence of an opening in the tympanic membrane (TM) that lasts for over 3 months. Although it is a common condition, its true frequency is not clearly known. The main pathological mechanism for chronic TMP is the absence of spontaneous healing capacity of the TM that causes failure of epithelial growth across the perforation.¹ Normally, TM perforation is repaired in 3 phases—inflammatory, proliferative, and maturation phases—as in classical wound healing. The healing process involves epithelial migration, increased fibroblast reaction, vascular proliferation, and tissue remodeling.² Leukocytes, fibroblasts, and other cellular elements are initially collected in the perforation zone after the occurrence of a TMP, and thickening with mitotic activity is observed at the perforation edges. The increase in fibroblasts accelerates epithelialization through bridges resulting from increased collagen synthesis and causes the perforation to close.³ The remodeling phase initiates with the closure of the perforation, and matrix metalloproteinases released from leukocytes contribute to re-epithelization and remodeling.⁴

Treatment of a chronic perforation is mostly performed with a surgical procedure including myringoplasty or tympanoplasty. However, surgery-associated concerns such as surgical morbidity or the high cost cause clinicians and patients to seek simple and less invasive treatment modalities. To evaluate the beneficial effect of topical substance administration on TM perforations, several agents including hyaluronic acid, dexpanthenol, platelet-rich plasma, hypericum perforatum, epidermal growth factor (EGF), and transforming growth factor-β1 have been investigated in experimental studies.⁵⁻⁹

This study was presented in the 41st Turkish National Congress of Otolaryngology Head and Neck Surgery**Corresponding author:** Nuri Ünsal, e-mail: unsalnuri@gmail.com**Received:** May 30, 2020 • **Accepted:** July 17, 2020Available online at www.advancedotology.orgContent of this journal is licensed under a
Creative Commons Attribution-NonCommercial
4.0 International License.

Allantoin (5-ureidohydantoin) is a heterocyclic derivative of purine that is found in the herbal extract of the comfrey plant and in the urine of most mammals. Allantoin is a well-known, non-toxic, wound-healing substance that stimulates new tissue formation with its keratolytic and astringent effects.¹⁰ Allantoin has also been shown to have anti-inflammatory, anti-hypertensive, anti-nociceptive, anti-ulcerogenic, and anti-asthmatic effects.¹¹⁻¹⁴ In the present study, we hypothesized that topical administration of allantoin may have a beneficial effect on chronic TM perforation due to its tissue-repair properties. To the best of our knowledge, this is the first study investigating the effect of topical allantoin on the healing of TMP in an experimental chronic perforation model.

MATERIALS AND METHODS

Animals and Study Design

The present study was performed at the Experimental Research and Application Center of Erciyes University, Kayseri Turkey after the approval of the Erciyes University Experimental Animal Ethics Committee dated May 9, 2018 and numbered "18/072".

The study was conducted with 25 healthy, female, 6-month-old, Sprague Dawley rats (weight 220-280 g). The animals were housed in a safe cage where the temperature was fixed at 21 degrees (12 h light and 12 h dark) with unlimited access to food (pellet feed + water). All rats were anesthetized by intraperitoneal injection of 80 mg/kg ketamine hydrochloride (Alfamine, Ata Fen, Turkey) and 10 mg/kg xylazine (Alfazyne, Ata Fen, Turkey) for a meticulous otomicroscopic examination. After the exclusion of animals with external and middle ear diseases or TMP, the study included 50 ears of 25 rats. A chronic TMP model, which was initiated by creating a 3 mm perforation on the pars tensa portion of the TM with a dental injector tip, was designed for all animals. The maintenance of TMP was provided by the application of 50% trichloroacetic acid (TCA) to the perforation edges on the 4th, 7th, 10th, and 13th days. After ensuring perforation permanence, the animals were randomly assigned into 3 groups for drug applications on the 15th day.

Group 1 (10 rats-20 ears) received a total of 7 administrations of intratympanic (IT) allantoin (Kale Kimya, Istanbul, Turkey) dissolved in distilled water at a concentration of 0.57% every other day, whereas Group 2 (5 rats, 10 ears) were administered no substance. Group 3 (10 rats, 20 ears) received a total of 7 administrations of IT 20 µl distilled water every other day. A micropipette was used in IT drug applications and the head of the rats was kept stationary for 30 seconds to increase the accessibility of the drug into the TM. On the 28th day,

TMs of all rats were examined with an otoendoscope for the status of TMP. All rats were then sacrificed by the combination of high dose intraperitoneal ketamine hydrochloride-xylazine. The temporal bulla of animals was bilaterally removed by wide resection to spare the TM and surrounding tissues, and stored in 10% formaldehyde solution for histopathological examination.

Histopathological Examination

Tissues were fixed in 10% formalin and embedded in paraffin. For histopathological examination, samples were decalcified in formic acid and sodium citrate solution. The temporal bullae were divided into 2 along the caput breve of the malleus and a cross-section of the TM was formed bilaterally. A paraffin-embedded tissue block was selected from each case and cut into 5 µm sections. Tissue sections were deparaffinized with xylene and washed with ethanol. The sections were stained with hematoxylin and eosin (H&E) and examined under a light microscope. The pathologist was blinded to the histological sections of the groups. TMs were examined for neutrophil activity, chronicity, presence of histiocytes, keratin accumulation, subepithelial edema, congestion, fibroblast proliferation, and neovascularization. Also, TM thickness was quantitatively measured in micrometers from 5 regions of the TM, and the mean value of these measurements was recorded for comparison between the groups. Definition of the scoring system for the histopathological parameters including neutrophil activity, keratin accumulation, subepithelial edema, congestion, fibroblast proliferation, and neovascularization is shown in Table 1.

Chronicity was scored as 0 (-; no activity), 1 (+; few: there are signs of chronicity; few lymphoplasmacytic cells distributed individually in lamina propria), or 2 (++; prominent: the presence of lymphoplasmacytic cell distribution in groups in lamina propria). The presence of histiocytes was classified as follows; 0 (-; none), 1 (+; few: the presence of a small number of histiocytes dispersed individually in lamina propria), or 2 (++; prominent: the presence of cluster-forming histiocytes in the lamina propria).

Statistical Analysis

Statistical analysis was performed using the Statistical Package for the Social Sciences (SPSS) v. 22; (IBM Corp.; Armonk, NY, USA). Data are presented as mean ± SD, and a P value less than .05 was considered significant for all comparisons. The Kolmogorov-Smirnov test was used to determine the distribution pattern of the data. Histopathological variations were compared with the Kruskal-Wallis test. Non-parametric multiple comparison test was performed to identify factors causing a difference.

Table 1. Definition of the Scoring System for the Histopathological Parameters

	0 (-)	1 (+)	2 (++)	3 (+++)
Neutrophil Activity	None	Dispersed Individually in LP	Dispersed in Groups in LP	Form Groups and Include the Epithelium
Neovascularization	None	<3*	3-5*	≥6*
Keratin accumulation	Normal	<3**	3**	≥4**
Subepithelial edema	None	Mild	Moderate	Severe
Congestion	None	1***	2-3***	≥3***
Fibroblast proliferation	None	Mild	Moderate	Severe

LP, lamina propria.

*Vascular structures at x40 magnification; **ratio of keratin/epithelial layer; ***number of the dilated capillaries at x40 magnification.

RESULTS

Two TM perforations, one in Group 1 and one in Group 3, were not healed, whereas TM perforations in 48 ears demonstrated closure at the end of the study. Neutrophil activity was significantly higher in Group 1 than in Group 2 ($P = .031$) and Group 3 ($P = .049$). Also, fibroblast proliferation was significantly higher in Group 1 than in Group 2 ($P = .009$). There was no significant difference between the groups in terms of chronicity, neovascularization, keratin accumulation, subepithelial edema, congestion, the presence of histiocytes, or thickness of the TM (Table 2).

DISCUSSION

To obtain a well-established topical substance for the treatment of chronic TMP, several experimental studies with different topical agents have been reported in the literature.⁵⁻⁹ Since experimental acute perforation models do not strictly represent chronic TMP pathogenesis, various chronic perforation models have been suggested for ensuring the maintenance of the perforation including traumatic, thermal, or chemical damage, topical growth factor inhibitor applications, and folding the perforation edges. In chemical damage, various agents have been suggested including mitomycin-c, 5-fluorouracil, dexamethasone, hydrocortisone and colchicine in the literature.¹⁵ In the present study, we established a chronic TMP model using 50% TCA since it is a well-known agent utilized in the field of otology for many years, including small TMP, granular myringitis, and acute external otitis.^{16,17} Although topical TCA administration was also reported for repairing a small TMP in the literature, the application of TCA with short-term intervals causes the perforation to be permanent due to its strong acid structure.¹⁸ After creating a perforation in the TM, the closure of the perforation was hampered by application of TCA to the perforation edges on the 4th, 7th, 10th and 13th days in the present study.

Closure of a chronic TMP by simpler techniques such as administration of a topical substance attracts clinicians and patients who do not want to face the morbidities of surgery. However, no universally valid agent has been recognized for clinical use to date. Experimental studies conducted with different topical agents have revealed conflicting results. Therefore, providing a topical agent with non-toxic and wound-healing properties that have beneficial

effects on chronic TMP closure is an ongoing research subject. In the present study, we hypothesized that topical allantoin application may ensure the closure of TMP without surgery due to its unique properties demonstrated in previous studies. In an experimental open wound model, Araújo et al. demonstrated that allantoin can ameliorate and promote the reestablishment of normal skin in rats.¹⁹ In addition to its wound-healing effects, allantoin was shown to have a protective effect against asthma due to its potential anti-inflammatory effects in a murine model of asthma.¹³ The gastro-protective activity of allantoin through anti-inflammatory, anti-oxidative, anti-secretory, and cytoprotective effects was also demonstrated in ethanol-, indomethacin-, and stress-induced gastric ulcer models.¹⁴

In the present study, histopathological parameters including neutrophil activity and fibroblast proliferation were significantly higher in rats administrated topical allantoin. Ensari et al.²⁰ investigated the effect of platelet-rich fibrin membrane in the repair of TMP in an experimental study, and the authors demonstrated higher values of fibrosis and neovascularization in the study group. Yaşar et al.⁹ reported that *Hypericum perforatum*, an herbal extract, was found to be effective in a wound-healing model of TMP. The authors demonstrated a significant increase in leukocyte and fibroblast counts of *Hypericum perforatum*-treated rats and concluded that *Hypericum perforatum* can contribute to an acceleration of wound healing. Similarly, in the present study, allantoin provided higher neutrophil activity and fibroblast proliferation in Group 1, which can be attributed to the positive effects of allantoin on the wound-healing process of chronic TMP. Although the difference was not significant, the mean value of neovascularization scores was higher in Group 1 than in Groups 2 and 3.

The present study had some limitations. First, although controversy still exists, a TM patency period ranging from 8 to 12 weeks was reported as the minimum time for perforation to be considered chronic in recent studies.²¹ Hence, despite the multiple TCA

Table 2. Mean scores of the histopathological parameters of the groups.

	Group 1 (Mean ± SD)	Group 2 (Mean ± SD)	Group 3 (Mean ± SD)	P
Neutrophil activity	1.5 ± 0.688	0.9 ± 1.01	0.95 ± 0.826	.048
Chronicity	1.35 ± 0.587	0.9 ± 0.568	1.1 ± 0.718	.177
Presence of histiocytes	0.6 ± 0.681	0.7 ± 0.483	0.9 ± 0.788	.429
Keratin accumulation	1.25 ± 0.639	1.4 ± 0.966	1.2 ± 0.768	.829
Subepithelial edema	0.8 ± 0.951	0.8 ± 1.033	0.75 ± 0.786	.993
Congestion	0.55 ± 0.686	0.8 ± 0.422	0.75 ± 0.716	.395
Fibroblast proliferation	1.35 ± 0.671	0.6 ± 0.699	1.1 ± 0.788	.033
Neovascularization	1.4 ± 0.821	0.8 ± 0.632	0.8 ± 0.768	.051
Thickness of the tympanic membrane	41.94 ± 3.19	33.69 ± 5.89	36.86 ± 3.90	.09

SD, standard deviation.

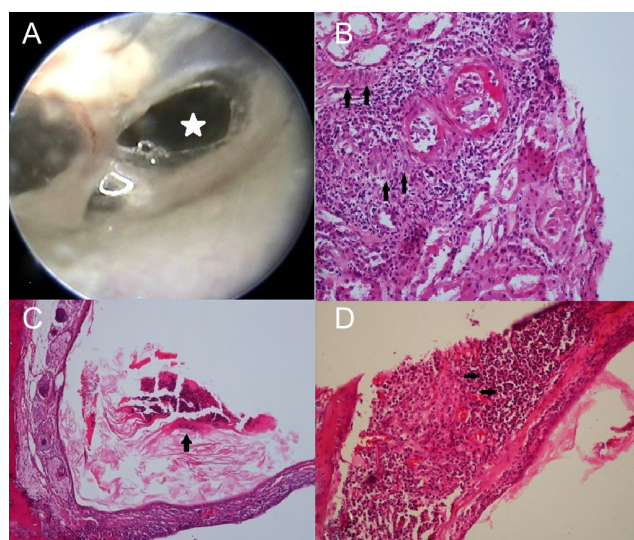


Figure 1. (A) Oto-endoscopic image of a tympanic membrane perforation in pars tensa (white arrow showing the perforation). (B) Neutrophil infiltration (black arrows) in Group 1 (H&E; ×100). (C) The areas of keratin accumulation (black arrows) in Group 1 (H&E; ×40). (D) Black arrows showing the areas of neovascularization (H&E; ×40).

applications to prevent closure of the TM perforation, 2 weeks can be considered as a relatively short period for a chronic perforation model. Second, perforation recovery times could not be detected due to technical shortcomings regarding the video-endoscopic examination. Third, allantoin was dissolved at the maximum concentration in distilled water (0.57%) and no solvent was utilized for acquiring higher allantoin concentrations to demonstrate the pure effect of allantoin. Therefore, any data regarding more beneficial effects on TM repair with higher allantoin concentrations could not be obtained in the present study.

CONCLUSION

To the best of our knowledge, this is the first study investigating the effect of allantoin in an experimental chronic TMP model. According to the histopathological findings, allantoin may have positive effects on the wound-healing process of chronic TMP.

Ethics Committee Approval: The present study was performed at the Experimental Research and Application Center of Erciyes University, Kayseri, Turkey after the approval of the Erciyes University Experimental Animal Ethics Committee dated 09.05.2018 and numbered "18/072".

Informed Consent: N/A.

Peer Review: Externally peer-reviewed.

Author Contributions: Concept - N.Ü., A.B., M.Y.; Design - N.Ü., A.B., M.Y.; Supervision - , A.B., M.Y.; Resource - N.Ü., A.B., M.Y.; Materials - N.Ü., A.B., E.A.; Data Collection and/or Processing - N.Ü., A.B., E.A.; Analysis and/or Interpretation - N.Ü., A.B., E.A.; Literature Search - N.Ü.; Writing - N.Ü., A.B.; Critical Reviews - A.B., E.A.

Conflict of Interest: The authors have no conflict of interest to declare.

Financial Disclosure: This study was funded by the Kayseri City Training and Research Hospital (Grant No: 2018/14).

REFERENCES

- Seonwoo H, Kim SW, Kim J et al. Regeneration of chronic tympanic membrane perforation using an EGF-releasing chitosan patch. *Tissue Eng Part A*. 2013;19(17-18):2097-2107. [\[CrossRef\]](#)
- Mondain M, Ryan A. Histological study of the healing of traumatic tympanic membrane perforation after basic fibroblast growth factor application. *Laryngoscope*. 1993;103(3):312-318. [\[CrossRef\]](#)
- Wang WQ, Wang ZM, Chi FL. Spontaneous healing of various tympanic membrane perforations in the rat. *Acta Otolaryngol*. 2004;124(10):1141-1144. [\[CrossRef\]](#)
- Rennekampff HO, Hansbrough JF, Kiessig V et al. Bioactive interleukin-8 is expressed in wounds and enhances wound healing. *J Surg Res*. 2000;93(1):41-54. [\[CrossRef\]](#)
- Güneri EA, Tekin S, Yilmaz O et al. The effects of hyaluronic acid, epidermal growth factor, and mitomycin in an experimental model of acute traumatic tympanic membrane perforation. *Otol Neurotol*. 2003;24(3):371-376. [\[CrossRef\]](#)
- Demirdelen S, İmamoğlu M, Arslan S, Saygın İ. Topical dexpanthenol application improves healing of acute tympanic membrane perforations: an experimental study. *ENT Updates*. 2016;6(3):116-120. [\[CrossRef\]](#)
- Erkilet E, Koyuncu M, Atmaca S, Yarım M. Platelet-rich plasma improves healing of tympanic membrane perforations: experimental study. *J Laryngol Otol*. 2009;123(5):482-487. [\[CrossRef\]](#)
- Yaşar M, Kaya A, Karaman H et al. Potential curative role of hypericum perforatum in an experimental rat model of tympanic membrane perforation. *J Intadv Otol*. 2016;12:252-256.
- Kaftan H, Herzog M, Miehe B, Hosemann W. Topical application of transforming growth factor-β1 in acute traumatic tympanic membrane perforations: an experimental study in rats. *Wound Repair Regen*. 2006;14(4):453-456. [\[CrossRef\]](#)
- Willital GH, Heine H. Efficacy of contractubex gel in the treatment of fresh scars after thoracic surgery in children and adolescents. *Int J Clin Pharmacol Res*. 1994;14(5-6):193-202.
- Florentino IF, Silva DPB, Galdino PM et al. Antinociceptive and anti-inflammatory effects of Memorandosa and allantoin in mice. *J Ethnopharmacol*. 2016;186:298-304. [\[CrossRef\]](#)
- Chen MF, Tsai JT, Chen LJ et al. Antihypertensive action of allantoin in animals. *BioMed Res Int*. 2014;2014:690135. [\[CrossRef\]](#)
- Lee MY, Lee NH, Jung D et al. Protective effects of allantoin against ovalbumin (OVA)-induced lung inflammation in a murine model of asthma. *Int Immunopharmacol*. 2010;10(4):474-480. [\[CrossRef\]](#)
- Da Silva DM, Martins JLR, de Oliveira DR et al. Effect of allantoin on experimentally induced gastric ulcers: pathways of gastroprotection. *Eur J Pharmacol*. 2018;821:68-78. [\[CrossRef\]](#)
- Wang AY, Shen Y, Wang JT et al. Animal models of chronic tympanic membrane perforation: a 'time-out' to review evidence and standardize design. *Int J Pediatr Otorhinolaryngol*. 2014;78(12):2048-2055. [\[CrossRef\]](#)
- Singh M, Kaur M, Singh B et al. Role of trichloroacetic acid and gelfoam in closure of tympanic membrane perforations. *Niger J Clin Pract*. 2017;20(10):1233-1236. [\[CrossRef\]](#)
- Kantas I, Balatsouras DG, Vafiadis M et al. The use of trichloroacetic acid in the treatment of acute external otitis. *Eur Arch Otorhinolaryngol*. 2007;264(1):9-14. [\[CrossRef\]](#)
- Halle TR, Todd NW, Fainberg J. Iatrogenic trichloroacetic acid injury causing necrotizing otitis media and deafness. *Int J Pediatr Otorhinolaryngol*. 2017;97:139-142. [\[CrossRef\]](#)
- Araújo LU, Grabe-Guimarães A, Mosqueira VC, Carneiro CM, Silva-Barcellos NM. Profile of wound healing process induced by allantoin. *Acta Cir Bras*. 2010;25(5):460-466 doi:[\[CrossRef\]](#)
- Ensari N, Gür ÖE, Öztürk MT et al. The effect of platelet-rich fibrin membrane on the repair of perforated tympanic membrane: an experimental study. *Acta Otolaryngol*. 2017;137(7):695-699. [\[CrossRef\]](#)
- Langston M, Grobman A, Goncalves S, Angeli SI. Animal model of chronic tympanic membrane perforation. *Anat Rec (Hoboken)*. 2020;303(3):619-625. [\[CrossRef\]](#)