

Original Article

Esterified Hyaluronic Acid Placed in the Middle Ear Does Not Improve Outcomes in Cholesteatoma Surgery

Colin Gerald Leonard^{ID}, Florence Mok^{ID}, Adrian L. James^{ID}

Department of Otolaryngology, Head and Neck Surgery, The Hospital for Sick Children, Ontario, Canada

ORCID IDs of the authors: C.G.L. 0000-0001-7687-2989; F.M. 0000-0001-8622-1151; A.L.J. 0000-0002-4125-4053.

Cite this article as: Leonard CG, Mok F, James AL. Esterified hyaluronic acid placed in the middle ear does not improve outcomes in cholesteatoma surgery. *J Int Adv Otol*. 2022;18(1):32-37.

BACKGROUND: The aim of this article is to assess the efficacy of esterified hyaluronic acid as a barrier to formation of adhesions and improvement of tympanomastoid ventilation.

METHODS: A prospective cohort analysis was performed at a tertiary referral centre. 126 ears were analysed in children with cholesteatoma. Esterified hyaluronic acid was placed on the promontory of 63 ears at primary canal wall intact surgery for cholesteatoma. No esterified hyaluronic acid was used in 63 control ears. Cholesteatoma recurrence, histopathological analysis of scar tissue following second-stage procedure, and middle ear pressure were the main outcome measures.

RESULTS: At 5 years, esterified hyaluronic acid (7%) and non-esterified hyaluronic acid (10%) did not differ in cholesteatoma recurrence (Kaplan–Meier log rank analysis, $P = .52$). Esterified hyaluronic acid ($n = 11$) and non-esterified hyaluronic acid ($n = 2$) ears formed scar at the site of packing material ($n = 11$) (Fisher's exact test, $P = .04$). Foamy histiocytes/macrophages were found in esterified hyaluronic acid ($n = 15$) and non-esterified hyaluronic acid ears ($n = 1$) (Fisher's exact test, $P < .001$). Middle ear pressure was measurable in 32/43 (74%) esterified hyaluronic acid ears and 36/52 (69%) non-esterified hyaluronic acid ears ($P = .58$, chi-square test). Median post-operative middle ear pressure in esterified hyaluronic acid (-115.0 daPa) and non-esterified hyaluronic acid ears (-85 daPa) did not differ significantly (Mann–Whitney U-test, -30.0 daPa, $P = .33$). Middle ear pressure was normal (> -125 daPa) in 44% (14/32) esterified hyaluronic acid ears and 42% (15/36) non-esterified hyaluronic acid ears ($P = 1.0$, Fisher's exact test).

CONCLUSIONS: We have discontinued the use of esterified hyaluronic acid in cholesteatoma surgery due to lack of detectable benefit. Esterified hyaluronic acid in the middle ear neither reduces cholesteatoma recurrence nor appears to improve the ventilation of the middle ear. Furthermore, esterified hyaluronic acid alters the inflammatory process within the middle ear, the significance of which remains unclear.

KEYWORDS: Cholesteatoma, esterified hyaluronic acid, middle ear, tympanoplasty

INTRODUCTION

A failure to maintain middle ear gas pressure close to atmospheric pressure leads to tympanic membrane dysfunction: negative pressure is associated with tympanic membrane retraction which can progress to cholesteatoma. Obstruction of the ventilation pathway between the meso- and epitympanum can cause pars flaccida cholesteatoma because net gas absorption across mastoid mucosa cannot be replenished by Eustachian tube opening.^{1,2} Conceivably, mucosal adhesions blocking ventilation between the protympanum and the rest of the middle ear could also cause pars tensa cholesteatoma. Scarification and formation of mucosal adhesions after cholesteatoma surgery can thus obstruct normal tympanomastoid ventilation leading to recurrent cholesteatoma. With adequate Eustachian tube function to compensate tympanomastoid gas absorption, prevention of mucosal adhesions should prevent cholesteatoma recurrence.

Absorbable gelatin sponge (AGS) is commonly placed in the middle ear to provide temporary support to tympanic membrane grafts, but animal model studies and clinical reports have raised concern that this can contribute to adhesion formation.^{3–5} Hyaluronic acid

(HA) is a high-molecular weight polysaccharide involved in wound healing. When used as a temporary middle ear support for tympanoplasty, it provides no beneficial effect on outcome,⁶ possibly because it drains down the Eustachian tube within hours,⁷ but when added to AGS causes fewer adhesions than AGS alone.⁸ Solid derivatives of HA, including an esterified hyaluronate acid (eHA) lamina, intended to disperse more slowly from the middle ear have been shown to cause less scarring in animal models than AGS.⁹⁻¹³ It is not clear from these reports whether eHA causes less scarring than avoidance of any middle ear packing or whether it may be beneficial for outcomes from cholesteatoma surgery. This study investigates the impact of eHA in the middle ear on middle ear pressure (MEP), as a measure of middle ear ventilation, histopathological findings, and recurrent disease rate after surgery for cholesteatoma.

MATERIALS AND METHODS

Ethical approval for this study was granted by the hospital's Research Ethics Board. Patients with cholesteatoma were identified from a prospectively collected consecutive dataset of a single surgeon in a tertiary referral centre. Inclusion criteria were set to maximize focus on the study objectives and minimize the effect of other variables on outcome in this non-randomized controlled study. Ears which underwent primary surgery for cholesteatoma with an intact canal wall approach were selected for consideration of inclusion. Surgeries included were categorized using the International Otology Outcomes Group criteria for mastoid and middle ear surgery; the stage of surgery (S), approach (A), mastoidectomy (M), external ear canal reconstruction (E), obliteration (O). Ears included were S_1 , A_{any} , M_x , M_{1a} , M_{1b} , $M_{2a}+E_2$ or $M_{2b}+E_2$, O_x .¹⁴

Intervention

The intervention group included 63 ears operated between June 2006 and February 2009 at which time eHA sheeting (EpiFilm® Otologic Lamina; Medtronic, Minneapolis, Minn, USA) was placed between the reconstructed tympanic membrane and the promontory with the aim of preventing formation of adhesions (Supplementary Figure 1). On occasion, eHA was also placed to line the tympanic isthmus with the same objective of preventing adhesion formation. For reasons that were not recorded, eHA was not used in 17 cases during this time period. These, and 1 case in which use or non-use was not recorded, are excluded from the study. Esterified hyaluronic acid was used in 3 canal wall down cases during this time period, but these were excluded as having other physiological influences on the principle outcome measures. Use of eHA was discontinued in 2009 when its efficacy was questioned.¹⁵

The control group comprised an equal number of ears in which eHA was not used (non-eHA) from time periods either side of the intervention group. In total, 14 were completed from January 2003 to May 2006 and 49 between June 2009 and September 2010. Subsequent cases were excluded in order to reduce confounding variability that might otherwise be introduced by other uncontrolled variables secondary to evolution of surgical practices (e.g., a tendency to larger atticotomy defects, different methods of scutum reconstruction, use of mastoid obliteration).

In both groups, tympanic membrane defects were repaired with temporalis fascia or tragal cartilage. Scutum defects were repaired

with bone paté or cartilage. A small amount of AGS (Gelfoam, Pfizer, New York, NY, USA) was placed in the middle ear space in 5 eHA cases and 12 non-eHA cases to provide support to the graft or eHA position. Ear canals were packed with bismuth iodoform phosphate paste (BIPP) on ribbon gauze. Antibiotic prophylaxis was not given. Second-stage surgery was performed by the same surgeon to screen for residual cholesteatoma typically 1 year after primary surgery in cases considered at risk (from matrix friability or extent), after detection of recurrent cholesteatoma or for elective ossiculoplasty. This included re-opening of the middle ear and resection of any mucosal adhesions or scar. Any residual or recurrent cholesteatoma was excised and, with mucosal adhesions or scar, sent for histological analysis. Analysis following hematoxylin and eosin staining was performed by a histopathologist blinded to the objective of the study. Clinical reports were scrutinized for data relating to the aims of the study.

Main Outcome Measures and Analysis

The principle outcome measures were cholesteatoma recurrence, histopathological analysis of scar tissue following second-stage procedure, and MEP. The time until recurrence of cholesteatoma (i.e., cholesteatoma formed from new retraction of the tympanic membrane) or time until completion of follow-up without recurrence was recorded for Kaplan–Meier survival analysis. Residual cholesteatoma (i.e., continued growth of remnants left after initial surgery) was not included in this analysis. In ears undergoing a second stage of surgery (either planned or revision for recidivism), the presence of middle ear adhesions was recorded qualitatively. The proportions of ears with adhesions and types of inflammatory cells noted in histopathological analysis were recorded. Middle ear pressure was measured with tympanometry at the clinic visit nearest to 12 months after surgery. This time interval was chosen to allow maximal healing prior to second-stage surgery. In order to include cases with flat tympanograms from middle ear effusion in the analysis, the primary outcome measure was determined *a priori* as the proportion of ears with normal MEP (>-125 daPa). When measurable, MEP was compared between groups with Mann–Whitney rank sum test. Preoperative MEP was not analyzed as in nearly all cases perforation, non-aerated middle ear, or discharge prevented accurate recording. Analysis was performed using R Studio software (R Core Team, 2018).

RESULTS

The eHA (median 10.3 years, range 2.7 to 17.3 years) and non-eHA (median 11 years, range 3.1 to 17.9 years) groups differed neither in median age (Mann–Whitney, $P=.19$) nor in gender distribution, where 42 eHA ears were male and 41 non-eHA ears were male (Fisher's exact test, $P=1.0$). The origin of cholesteatoma (Table 1) and surgical findings at primary surgery (Table 2) were not significantly different between eHA and non-eHA ears. Temporalis fascia was used to reconstruct 46/63 eHA ears and 26/63 non-eHA ears (Fisher's exact test, $P=.007$). Cartilage graft was used in 12/63 eHA ears and 22/63 non-eHA ears (Fisher's exact test, $P=.03$). About 6/37 (16%) eHA and 3/25 (11%) non-eHA ears had a perforation at second-stage surgery (Fisher's exact test, $P=.72$), and 2/26 (8%) eHA ears and 2/38 (5%) non-eHA ears that did not undergo second-stage surgery had perforations at 12 months (Fisher's exact test, $P=1.00$). Pure tone air conduction (AC) threshold audiometry was complete preoperatively and at 12 months post-operatively in 107/126 (86%) ears. Median for tone AC threshold differed neither preoperatively (eHA median 35 dB HL (range 9 to 110 dB HL); non-eHA median 36dB HL (range 3 to 66dB

Table 1. Table Showing Frequency of Different Sites of Cholesteatoma Origin

Group	Origin of Cholesteatoma					
	Congenital	Pars Tensa	Pars Flaccida	Pars Tensa & Flaccida	Implantation	Pre-Cholesteatoma
eHA	10 (16%)	30 (48%)	13 (21%)	1 (2%)	4 (6%)	7 (11%)
Non-eHA	7 (11%)	30 (48%)	15 (24%)	6 (10%)	1 (2%)	5 (24%)

Fisher's exact, $P = .20$. eHA, Esterified hyaluronic acid; non-eHA, non-esterified hyaluronic acid.

Table 2. Surgical Findings and Graft Choice at Primary Surgery

Group	Surgical Findings								
	EAONO/JOS Stage						Normal Mucosa	Graft Material	
	0	1	2	3	4	N/A		Temporalis Fascia	Tragal Cartilage
eHA	0 (0%)	13 (21%)	38 (60%)	6 (9.5%)	0 (0%)	6 (9.5%)	25 (40%)	51 (81%)	12 (19%)
Non-eHA	3 (5%)	12 (19%)	39 (62%)	3 (5%)	2 (3%)	4 (6%)	27 (43%)	35 (56%)	22 (35%)

Fisher's exact European Academy of Otolaryngology and Neurology / Japanese Otolaryngology Society (EAONO/JOS) Stage, $P = .67$; Fisher's exact normal mucosa, $P = .86$; Fisher's exact graft material, $P = .03$. eHA, Esterified hyaluronic acid; non-eHA, non-esterified hyaluronic acid.

HL) Mann–Whitney $P = .88$) nor post-operatively (eHA median 35 dB HL (range 5 to 60 dB HL); non-eHA median 31 dB HL (range 10 to 71 dB HL) Mann–Whitney $P = .79$)).

Middle Ear Aeration

At the clinic visit 12 months post-operatively, tympanometry was completed in 95/126 (75%) ears of which MEP was measurable in 68/95 (72%). Median post-operative MEP in eHA (32/43 (74%)) (–115.0 daPa) and non-eHA (36/52 (69%)) (–85 daPa) ears did not differ significantly (Mann–Whitney U -test –30.0 daPa, $P = .33$). Middle ear pressure was normal (> -125 daPa) in 44% (14/32) eHA and 42% (15/36) non-eHA (NS, Fisher's exact test) ears.

Status of Middle Ear Mucosa

Of those who had a second surgery, scar tissue was found and biopsied in 26/37 eHA ears (70% or 41% of all eHA cases) and 17/28 in the non-eHA group (61% or 27% of all non-eHA cases) (Fisher's exact test, $P = .14$). Scar tissue was found in the middle ear in 11 ears with eHA and 2 ears without eHA (Fisher's exact test, $P = .04$). Scar was found in the mastoid, attic, and promontory in both groups.

Ears in which eHA was placed demonstrated foamy histiocytes or foamy macrophages (Figure 1A), a sub-class of histiocyte, in 15/26

(57%) of cases as opposed to only 1/16 (6%) in the non-eHA group (Figure 1B) (Fisher's exact test, $P < .001$). In 4 cases in the eHA group, foreign body giant cells had been found in the tissue biopsied at primary surgery. When these cases are excluded, significance remained, Fisher's exact test, $P = .02$. Foreign body giant cells or foreign body reaction was seen in 8/17 (47%) of non-eHA ears, but 0/26 eHA ears (Fisher's exact test, $P < .001$). Non-foamy histiocytes, chronic inflammatory cells, fibrous tissue, and dystrophic calcification were found in both groups (Figure 2).

Recurrent Cholesteatoma

Median follow-up for eHA ears was 4.6 years (0.1 to 11.6) and 4.9 years (0.2 to 12.0) for non-eHA ears (Mann–Whitney U -test, $P = 0.77$). In total, 57/126 (45%) of all ears, 28/63 (44%) eHA, and 29/63 (46%) non-eHA ears had been followed up in the outpatient clinic for more than 5 years. At 5 years, there was a 7% recurrence rate in the eHA group and 10% in the non-eHA group (Kaplan–Meier Log Rank Analysis, $P = .52$) (Table 3) (Figure 3).

DISCUSSION

With average follow-up of 5 years, this study failed to find any beneficial effect on recurrence or middle ear ventilation from eHA in cholesteatoma surgery. Indeed, it appeared that scar formation was not reduced by eHA, and that atypical inflammatory cells were present in

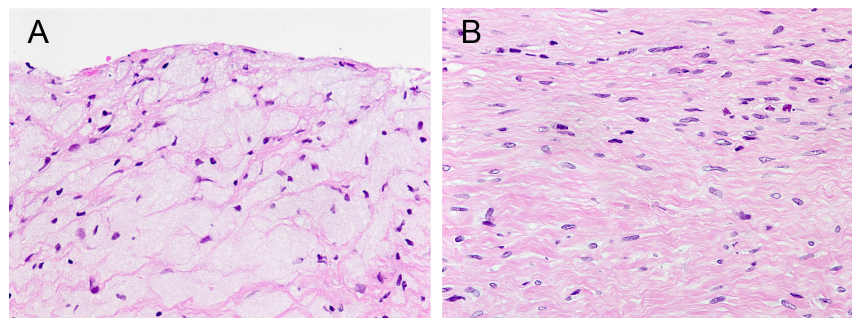


Figure 1. (A) Section through biopsy at the site of previous HA lamina placement. The vacuolated areas of multiple foamy histiocytes are clearly visible (hematoxylin and eosin stain; 200× magnification of objective image). (B) Section through biopsy of mucosal scar tissue from the mastoid at a site where no HA lamina had been placed. Fibrous tissue is evident. No histiocytic reaction is evident (hematoxylin and eosin stain; 200× magnification of objective image). HA, hyaluronic acid.

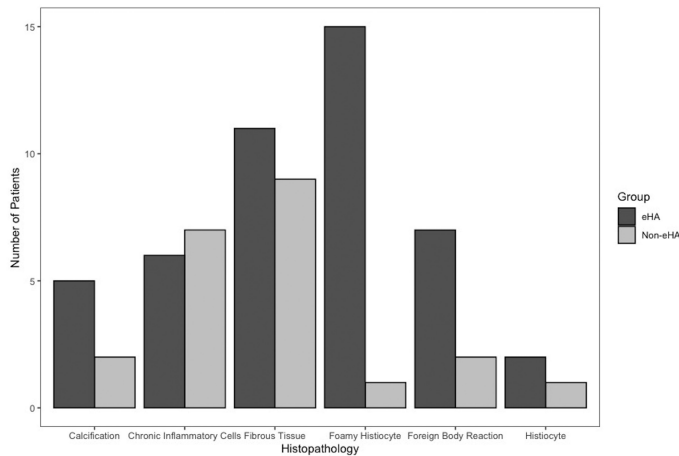


Figure 2. Histogram showing frequency of different histopathological findings in each group.

scar tissue at the site of eHA placement. The finding of these foamy histiocytes is of uncertain significance but has also been reported after placement of eHA in an animal model: in the rat middle ear, a “dense connective tissue, rich in collagen fibers with abundant fibroblasts” and “foamy macrophages undergoing degenerative changes” was found at 9 and 12 months.¹⁶ Biopsy of scar tissue at sites where the HA lamina was not used, such as within the mastoid, did not reveal a histiocytic infiltrate. This leads us to speculate that the HA lamina may not dissolve and be dispersed as expected but contribute to an altered inflammatory response. Application of mineral oil to the middle ear space has also been shown to induce an influx of macrophages in an animal model.¹⁷ Mineral oil is a component of BIPP ear canal packing, but as this was utilized in both eHA and non-eHA groups, we consider it an unlikely cause of the response in this study. Further research would be required to determine whether the vesicles contain breakdown products from ingestion of eHA by macrophages.

Studies relating to HA as a middle ear packing agent in animal models have focused on the safety in the middle and inner ear, effects on healing, and side effects of packing. Healthy middle ear mucosa has only a minimal reaction to HA, and its derivatives have shown less fibrosis in the middle ear than that found in AGS packing.^{9,18,19} The volume of retained product in guinea pig middle ear was also less after the middle ear was packed with eHA than AGS.¹⁹ When ABR recordings are assessed, no ototoxicity has been demonstrated, and ABR recovers to normal more quickly in guinea pigs packed with eHA than AGS.^{9,18} The impact of HA on the healing of traumatized mucosa is less clear. Absorbable gelatin sponge soaked in HA has shown reduced formation of fibrous connective tissue and

Table 3. Number of Ears Requiring Second Look Surgery and Findings at Time of Surgery

Group	Findings at Second-Stage Surgery			
	Not Required	No Recidivism	Residual	Recurrent
eHA	26 (41%)	20 (32%)	15 (24%)	5 (8%)
Non-eHA	35 (56%)	13 (21%)	10 (16%)	8 (13%)

Fisher's exact test, $P = .21$. eHA, Esterified hyaluronic acid; non-eHA, non-esterified hyaluronic acid.

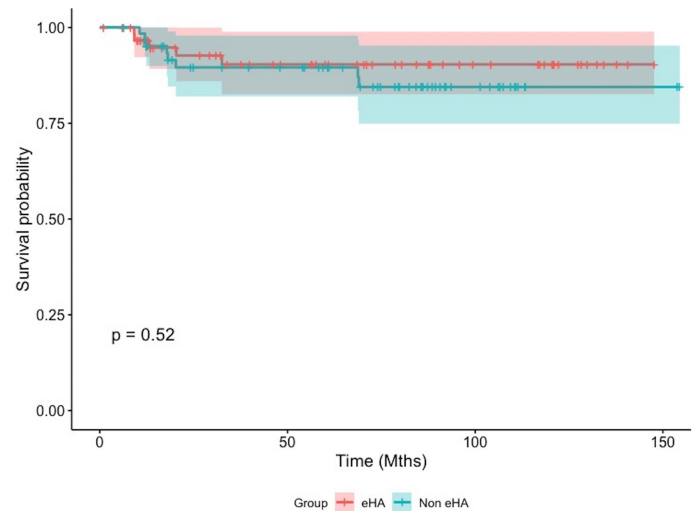


Figure 3. Kaplan-Meier curve showing time to recurrence in eHA and non-eHA ears. eHA, Esterified hyaluronic acid; non-eHA, non-esterified hyaluronic acid.

neo-osteogenesis in 1 study but new bone formation on the promontory in a second.^{8,11} In guinea pigs, eHA has also shown propensity to cause neo-osteogenesis when placed into maxillary sinuses denuded of their mucosal lining.²⁰ It is clear from animal studies that HA and its derivatives pose no risk of ototoxicity, but the long term implications of its presence within the middle ear are unclear. While HA has shown some promise in reducing scarring, the evidence is equivocal for HA derivatives. The longest duration of follow-up is 6 weeks which may or may not be a representative model for second look surgery at 12 months.

Clinical studies relating to the use of eHA and other HA derivatives have been limited and have focused on the use of eHA as a graft material for repairing tympanic membrane perforation, enhancing epithelialisation of a mastoid cavity or use as a middle ear packing material.²¹⁻²⁵ When used as a graft for tympanic membrane perforation repair, eHA alone appears to be ineffective,^{25,26} but a combination of eHA with fat graft results in similar closure rates to temporalis fascia or perichondrium grafts.²⁷⁻²⁹ Hyaluronic acid lamina when placed in varying concentrations into the middle ear of patients undergoing perforation repair with or without ossiculoplasty has not demonstrated a benefit in perforation closure, appearance of the tympanic membrane or hearing outcomes 3 months following surgery.⁶ Esterified hyaluronic acid has been placed into the middle ears of patients undergoing canal wall down mastoidectomy for adhesive otitis media. The middle ear was either packed with eHA, cartilage, or a combination of the 2 packing materials with the eHA and combined packing showing an improvement in both pure tone AC threshold and air bone gap. However, the patients in the trial also underwent ossiculoplasty with either partial or total ossicular reconstruction prosthesis, for which no allowance is made in reporting an improved hearing outcome.²⁴ We have not found previous clinical evaluation of the effect of eHA on middle ear scarring and ventilation.

Study Limitations and Implications

It is conceivable that dissimilarities between the intervention and control groups could have obscured any benefits from placement of eHA in this non-randomized study. Cartilage grafts were

placed more frequently in non-eHA ears, however the recurrence rate remained similar between eHA and non-eHA ears. Allocation to the eHA intervention may have been skewed by not placing it in 21% of potentially eligible cases during the study period. An attempt was made to minimize the effect of uncontrolled variables in this non-randomized study by limiting the control group to an equal number of similar surgeries from a similar time period and performing *per protocol* analysis. On the basis that equipoise is demonstrated in our MEP and recurrence rates, a randomized blinded controlled study could be justified to evaluate the effect of eHA more accurately. Future research would benefit from a systematic grading system for recording the site and extent of post-operative adhesions which was not available for this study. We have elected not to proceed with a further trial on the basis that the absence of any apparent benefit in this study would make it difficult to demonstrate a clinically significant or cost-effective benefit from eHA intervention. The uncertain implications of the atypical scar tissue found after eHA have also discouraged us from further clinical use.

Ethics Committee Approval: Ethical committee approval was received from the Hospital for Sick Children, Toronto (approval ID: REB # 1000067921).

Informed Consent: Written informed consent was obtained from all participants.

Peer Review: Externally peer-reviewed.

Author Contributions: Concept – C.G.L., F.M., A.L.J.; Design – C.G.L., F.M., A.L.J.; Supervision – A.L.J.; Resource – C.G.L., F.M., A.L.J.; Materials – C.G.L., F.M., A.L.J.; Data Collection and/or Processing – C.G.L., F.M.; Analysis and/or Interpretation – C.G.L., F.M.; Literature Search – C.G.L., F.M.; Writing – C.G.L., F.M., A.L.J.; Critical Reviews – A.L.J.

Acknowledgments: The authors thank Dr Glenn Taylor and Dr Gino Somers for providing the histopathology slides and for contributing to histopathological analysis.

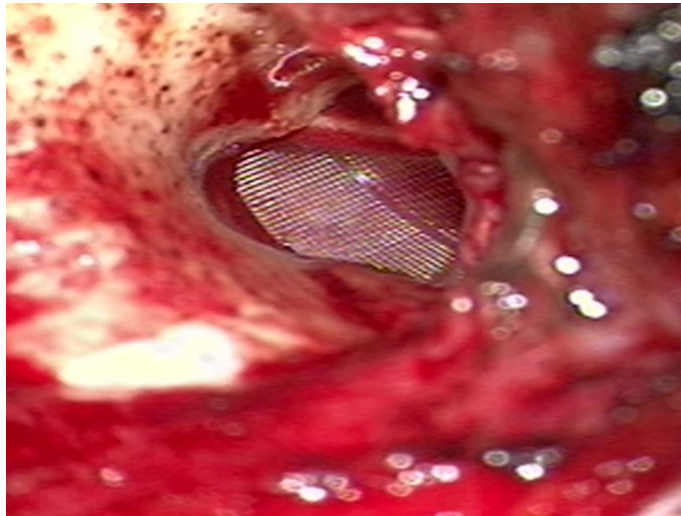
Conflict of Interest: The authors have no conflict of interest to declare.

Financial Disclosure: The authors declared that this study has received no financial support.

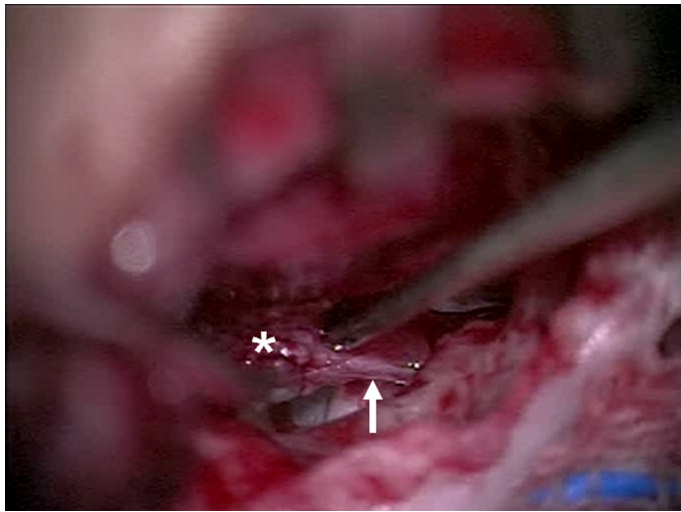
REFERENCES

- Morimitsu T, Nagai T, Nagai M, et al. Pathogenesis of cholesteatoma based on clinical results of anterior tympanotomy. *Auris Nasus Larynx*. 1989;16(suppl 1):S9-S14. [\[CrossRef\]](#)
- Marchioni D, Alicandri-Ciufelli M, Molteni G, Artioli FL, Genovese E, Presutti L. Selective epitympanic dysventilation syndrome. *Laryngoscope*. 2010;120(5):1028-1033. [\[CrossRef\]](#)
- Schuknecht HF. Sensorineural hearing loss following stapedectomy. *Acta Otolaryngol*. 1962;54:336-348. [\[CrossRef\]](#)
- Joseph RB. The effect of absorbable gelatin sponge preparations and other agents on scar formation in the dog's middle ear. an experimental histopathologic study. *Laryngoscope*. 1962;72:1528-1548. [\[CrossRef\]](#)
- Hellström S, Salén B, Stenfors LE. Absorbable gelatin sponge (gelfoam) in otosurgery: one cause of undesirable postoperative results? *Acta Otolaryngol*. 1983;96(3-4):269-275. [\[CrossRef\]](#)
- Bagger-Sjöbäck D, Holmquist J, Mendel L, Mercke U. Hyaluronic acid in middle ear surgery. *Am J Otol*. 1993;14(5):501-506. [\[CrossRef\]](#)
- Laurent C, Hellström S, Tengblad A, Appelgren LE, Sehlin J, Lilja K. Hyaluronan in the middle ear of the rat. The normal distribution of hyaluronan and the clearance of exogenously administered hyaluronan from the middle ear. *Acta Otolaryngol Suppl*. 1987;442:36-40. [\[CrossRef\]](#)
- Laurent C, Hellström S, Stenfors LE. Hyaluronic acid reduces connective tissue formation in middle ears filled with absorbable gelatin sponge: an experimental study. *Am J Otolaryngol*. 1986;7(3):181-186. [\[CrossRef\]](#)
- Li G, Feghali JG, Dinces E, McElveen J, van de Water TR. Evaluation of esterified hyaluronic acid as middle ear-packing material. *Arch Otolaryngol Head Neck Surg*. 2001;127(5):534-539. [\[CrossRef\]](#)
- Park AH, Jackson A, Hunter L, et al. Cross-linked hydrogels for middle ear packing. *Otol Neurotol*. 2006;27(8):1170-1175. [\[CrossRef\]](#)
- Jang CH, Park H, Cho YB, Choi CH. The effect of anti-adhesive packing agents in the middle ear of guinea pig. *Int J Pediatr Otorhinolaryngol*. 2008;72(11):1603-1608. [\[CrossRef\]](#)
- Dogru S, Haholu A, Gungor A, et al. Histologic analysis of the effects of three different support materials within rat middle ear. *Otolaryngol Head Neck Surg*. 2009;140(2):177-182. [\[CrossRef\]](#)
- Lipan MJ, Alava I, Abi-Hachem R, Vernon S, Van De Water TR, Angeli SI. Middle ear packing: comparison of materials in an animal model of mucosal trauma. *Otolaryngol Head Neck Surg*. 2011;144(5):763-769. [\[CrossRef\]](#)
- Yung M, James A, Merkus P, et al. International Otology Outcome Group and the international consensus on the categorization of tympanomastoid surgery. *J Int Adv Otol*. 2018;14(2):216-226. [\[CrossRef\]](#)
- James AL, Taylor G, Sherifi I. Scarring from hyaluronic acid film in middle ear surgery. *Otolaryngol Head Neck Surg*. 2009;141(3)(suppl 1):P90-P90. [\[CrossRef\]](#)
- Laurent C, Soderberg O, Hellstrom S. Esterified hyaluronan (Otosponge) in the middle ear. a new tool for otosurgery? In: Portmann M, ed. *Third International Symposium on Transplants and Implants in Otology, Bordeaux, France*. Amsterdam: Kugler Publications; 1996:49-52.
- McGhee RB Jr, DeMaria TF, Okazaki N, Lim DJ. Selective induction of macrophages in the middle ear. *Ann Otol Rhinol Laryngol*. 1983;92(5 Pt 1):510-517. [\[CrossRef\]](#)
- Deniz B, Oguzhan KR, Erdem O, Hasan S, Fuat YY, Muge O. The effects of different packing materials on healing and hearing after trauma to middle ear mucosa, an experimental study in rats. *Am J Otolaryngol*. 2019;40(3):347-352. [\[CrossRef\]](#)
- Olmos-Zuñiga JR, González-López Md R, Gaxiola-Gaxiola Md M, et al. Effects of middle ear packing with collagen polyvinylpyrrolidone and hyaluronic acid in guinea pigs. *J Invest Surg*. 2012;25(6):398-404. [\[CrossRef\]](#)
- Jacob A, Faddis BT, Chole RA. MeroGel hyaluronic acid sinonasal implants: osteogenic implications. *Laryngoscope*. 2002;112(1):37-42. [\[CrossRef\]](#)
- Martini A, Morra B, Aimoni C, Radice M. Use of a hyaluronan-based biomembrane in the treatment of chronic cholesteatomatous otitis media. *Am J Otol*. 2000;21(4):468-473.
- Saliba I, Knapik M, Froehlich P, Abela A. Advantages of hyaluronic acid fat graft myringoplasty over fat graft myringoplasty. *Arch Otolaryngol Head Neck Surg*. 2012;138(10):950-955. [\[CrossRef\]](#)
- Wong WK, Luu EH. What is the role of hyaluronic acid ester in myringoplasty? Systematic review and meta-analysis. *Otol Neurotol*. 2019;40(7):851-857. [\[CrossRef\]](#)
- Deng R, Fang Y, Shen J, et al. Effect of esterified hyaluronic acid as middle ear packing in tympanoplasty for adhesive otitis media. *Acta Otolaryngol*. 2018;138(2):105-109. [\[CrossRef\]](#)
- Sayin I, Kaya KH, Ekizoğlu O, Erdim I, Kayhan FT. A prospective controlled trial comparing spontaneous closure and Epifilm® patching in traumatic tympanic membrane perforations. *Eur Arch Otorhinolaryngol*. 2013;270(11):2857-2863. [\[CrossRef\]](#)
- Prior M, Gibbins N, John G, Rhys-Williams S, Scott P. Hyaluronic acid ester in myringoplasty. *J Laryngol Otol*. 2008;122(2):e3. [\[CrossRef\]](#)

27. Gün T, Boztepe OF, Atan D, İkinçioğulları A, Dere H. Comparison of hyaluronic acid fat graft myringoplasty, fat graft myringoplasty and temporal fascia techniques for the closure of different sizes and sites of tympanic membrane perforations. *J Int Adv Otol.* 2016;12(2):137-141. [\[CrossRef\]](#)
28. Saliba I, Froehlich P. Hyaluronic acid fat graft myringoplasty: an office-based technique adapted to children. *Arch Otolaryngol Head Neck Surg.* 2011;137(12):1203-1209. [\[CrossRef\]](#)
29. Saliba I, Woods O. Hyaluronic acid fat graft myringoplasty: a minimally invasive technique. *Laryngoscope.* 2011;121(2):375-380. [\[CrossRef\]](#)



Supplementary Figure 1. eHA in place overlying the promontory prior to replacement of tympanomeatal flap. eHA, esterified hyaluronic acid.



Supplementary Figure 2. eHA ear at second stage surgery with fibrous tissue (star) highlighted in middle ear cleft requiring dissection and appearing to have left a remnant (arrow).