

---

## CASE REPORT

---

### **Intrapetrous facial nerve tumors: Report of 3 cases and literature review**

**Andrea Ciorba MD, Marco Borgonzoni MD, Roberto Bovo MD, Alessandro Martini MD**

---

Audiology Department, University  
Hospital of Ferrara, Italy

Correspondence

Prof. Alessandro Martini  
Full Professor of Audiology  
Audiology Department  
University Hospital of Ferrara  
Ferrara, Italy

Tel: 0532- 237451  
Fax: 0532-236887  
Email: [alessandro.martini@unife.it](mailto:alessandro.martini@unife.it)

*Submitted:* 14 November 2006  
*Accepted:* 06 December 2006

Mediterr J Otol 2007; 3: 108-112

Copyright 2005© The Mediterranean  
Society of Otology and Audiology

Facial nerve tumors are a very uncommon neoplasm. They may originate from any segment of the VIIth nerve, from the cerebellopontine angle to the peripheral branch in the parotid gland. Because of lack of specific clinical symptoms, diagnosis may be difficult. Small facial tumors may also remain asymptomatic and only be discovered incidentally.

Reports of tumor excision in which the nerve is left intact and functioning are scanty.

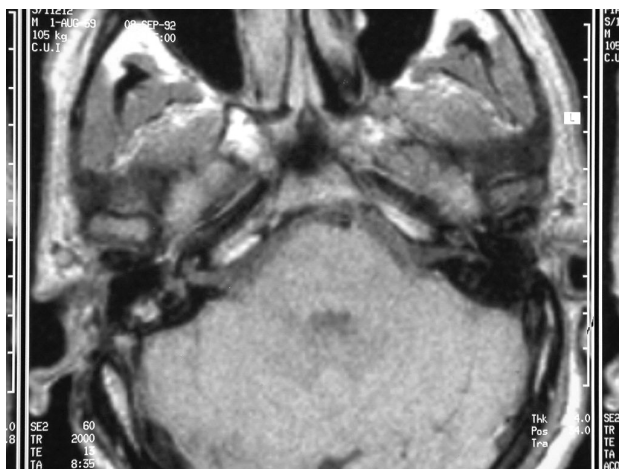
We present case reports of 2 facial nerve schwannomas and 1 facial nerve neuroma, at the intrapetrous location. We also review the literature, and characteristics of these diseases are discussed.

## CASE REPORTS

### Case 1

A 33-year-old man underwent a right radical mastoidectomy for cholesteatoma in October 1989. Four months later, he was referred to our clinic for residual cholesteatoma, complaining of right hearing loss that worsened over the previous 5 months and vertigo. No signs of facial nerve weakness were present.

Computed tomography (CT) and magnetic resonance imaging (MRI) scans showed recurrence of chronic inflammatory tissue in the right ear cavity and a small expansive lesion at the level of the horizontal segment of the facial nerve (Figure 1).



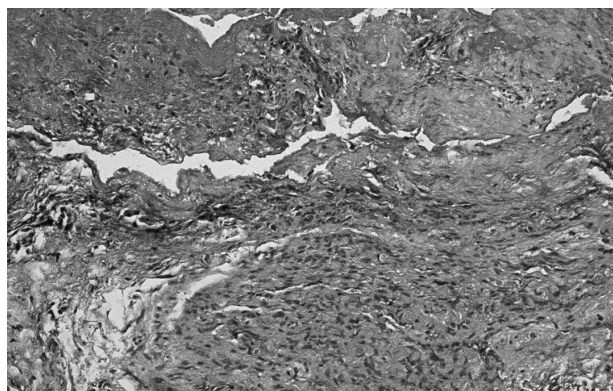
**Figure-1:** MRI: mild enlargement of the horizontal tract of the right facial nerve.

The patient underwent surgery using a transmastoid approach, and the cholesteatoma was removed. A 4-mm diameter nervous lesion of the horizontal tract was identified and carefully removed, keeping the horizontal tract intact. After histologic examination, we diagnosed neuroma of the facial nerve (Figure 2).

In May 1991, another tympanoplasty was necessary to remove the residual cholesteatoma. During recent follow-up examinations, the patient was found in good health with no signs of disease or facial nerve palsy.

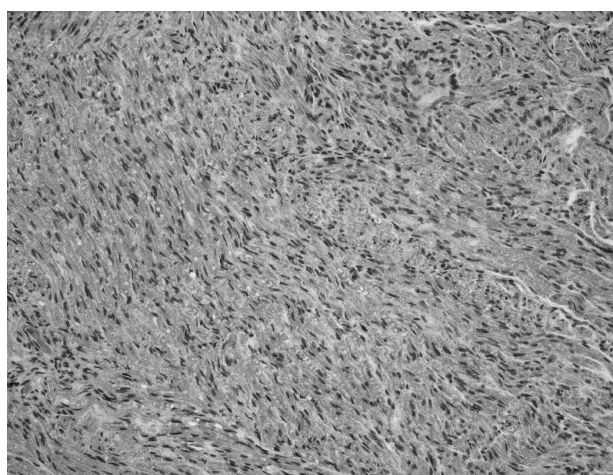
### Case 2

A 75-year-old man was admitted to our clinic in February 2002, complaining of hearing loss and tinnitus in



**Figure-2:** Histology (hematoxylin and eosin, 40 $\times$ ): facial nerve neuroma—reparative proliferation of fibroblasts and fiber nerve axons.

the left ear that worsened in the past 12 months. He denied history of vertigo, and there were no signs of facial nerve weakness. Otoscopic examination disclosed a posterosuperior left marginal perforation in the tympanic membrane and the presence of mesotympanic cholesteatoma. A high-resolution CT scan showed inflammatory tissue involving the middle ear and the ossicular chain, with signs of tegmen erosion. We noted enlargement of the horizontal tract of the facial nerve, suggesting the presence of a facial nerve lesion. The patient underwent surgery using a transmastoid approach; the cholesteatoma and facial nerve tumor were both removed. After histopathologic examination, we diagnosed a small schwannoma of the facial nerve (Figure 3).



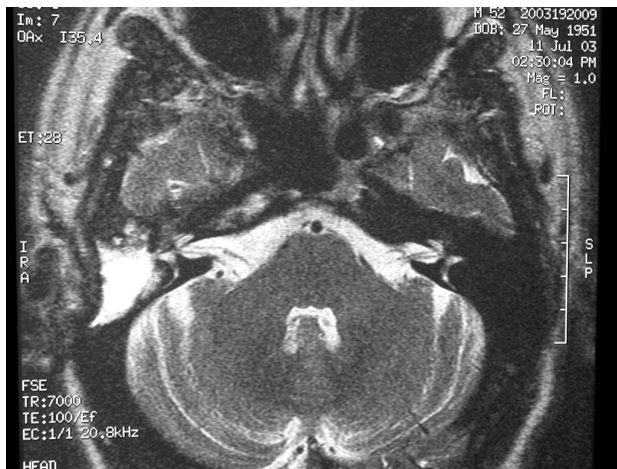**Figure-3:** Histology (hematoxylin and eosin, 40 $\times$ ): tumor composed of proliferating spindle cells forming compact zones.

After 3-years' follow-up, the patient shows no signs of recurrence or facial nerve palsy.

### Case 3

A 52-year-old man, with a 3-year history of right chronic otitis media, was admitted to our clinic in March 2002. Otomicroscopic examination revealed a small perforation in the epitympanic region, and a white mass was seen through the eardrum. The rest of the clinical examination was unremarkable. Anamnestic data revealed no previous history of middle ear trauma or surgery.

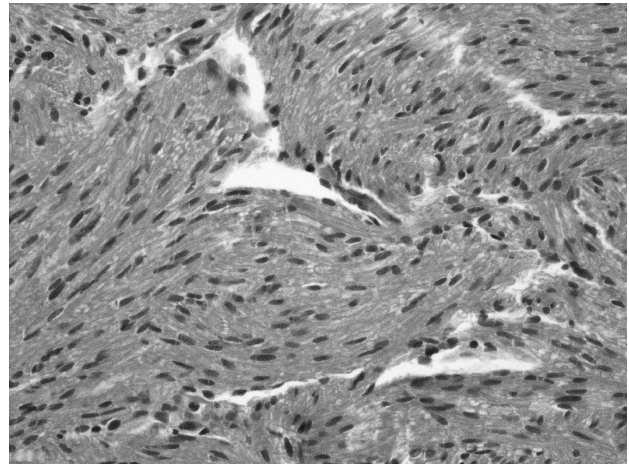
CT and MRI showed chronic inflammatory tissue in the right middle ear and in the mastoid cavity but no radiologic evidence of lesion in any facial nerve segment (Figure 4).



**Figure-4:** MRI: chronic inflammatory tissue of the right middle ear.

The patient underwent surgery using a transmastoid approach; the cholesteatoma was removed. During surgery, a small neoformation of the horizontal tract of the facial nerve was detected and removed. Histopathologic exam determined it to be schwannoma (Figure 5).

After 3-years' follow-up, the patient shows no signs of recurrence or facial nerve palsy.



**Figure-5:** Histopathology (hematoxylin and eosin, 80 $\times$ ): palisading of cells.

### DISCUSSION

Facial nerve tumors (FNT) are rare neoplasms; the most common of these are schwannomas. Other FNT types include neurofibromas, neuromas, hemangiomas, and meningiomas.

Facial nerve schwannomas (FNS) are slow-growing tumors usually benign and encapsulated,<sup>[1-4]</sup> a neoplasia of the sheath or Schwann cells, or of the neuroectodermal perineural cells.<sup>[5]</sup> Schwann and perineural cells are morphologically identical, differing solely in their location within the nerve sheath. Schwannomas tend to originate in the center of the nerve and, as they increase in size, compress the nerve fibers eccentrically toward the surrounding perineurium. They are thought to most likely originate from the sensory fibers of the nerve.<sup>[5]</sup>

Neurofibromas are other benign solitary nerve sheath tumors and are a neoplasm of both Schwann cells and fibroblasts, while neuromas arise from Schwann cells only. Facial nerve hemangiomas originate from vascular plexuses distributed along the facial nerve paths, and more frequently from the geniculate ganglion region, in the mastoid segment or in the internal auditory canal.<sup>[6]</sup>

Like acoustic schwannomas, small facial tumors have been discovered incidentally during review of larger numbers of serially sectioned human temporal



bones. Saito and Baxter reported a 0.8% incidence of occult histopathologic FNS.<sup>[3,7,8]</sup> The age of initial presentation ranges between 7 and 81 years, with a majority of tumors discovered in patients between 15 and 45 years of age and a slight peak between 26 and 35 years of age. Women are reported to be more affected than men, with the ratio about 3:1 to 3:2. No bilateral FNS have been reported.<sup>[2,3,5]</sup>

FNT may arise from any segment of the facial nerve from the cerebellopontine angle to the peripheral branch in the parotid gland.<sup>[3,5]</sup> Multiple-segment localization is also possible. Sherman and colleagues report that, in 428 cases of FNS in which location could be determined, the percentages of involvement for each segment of the nerve are 43.5% for labyrinthine, 42.8% for tympanic, 36.7% for vertical, 24.3% for internal auditory canal, 17.8% for cerebellopontine angle, and 15% for extratemporal peripheral.<sup>[2]</sup>

Tumor size can vary between less than a millimeter and several centimeters; usually the lesions are slow growing and tend to expand in the direction of least resistance.<sup>[5]</sup>

There are no specific symptoms for FNT, and for this reason, diagnosis may be difficult. In a study conducted by Schaitkin and May, it was noted that diagnosis of tumor could take place as much as 18 years after the initial onset of symptoms.<sup>[6]</sup> In our cases, FNT were very small and mainly asymptomatic; moreover, their presence was clinically masked by the coexisting cholesteatoma infection.

Symptoms of FNT may differ depending on the involved segments.<sup>[3,5]</sup> FNT originating in the cerebellopontine angle or internal auditory canal share symptoms with other space-occupying lesions in that area, especially with VIIIth nerve tumors; thus neurosensorial hearing loss, which can be gradual or sudden, and tinnitus are frequently observed.<sup>[3,5]</sup> Most lesions arising in the tympanic segment can initially compress the stapedial arch and gradually destroy it, causing a progressive conductive hearing loss. Facial paralysis can develop later.<sup>[3,5]</sup> Patients with tumors arising in the peripheral segment, frequently show a mass in the parotid gland. This also may be

accompanied by slowly progressing facial paresis.<sup>[2,3,5]</sup> Other reported symptoms of FNT include dizziness, pain, and otorrhea.<sup>[2,3,5,6]</sup>

Preoperative histopathologic diagnosis can be useful for determining surgical approach. Fine needle aspiration cytology (FNAC) is not always possible because of tumor location. Even if it is possible (as in intraparotid FNT), it has limited value for diagnosis.<sup>[2,9,10]</sup> Chong and colleagues reported that only 1 patient in 5 with intraparotid FNT had had preoperative diagnosis by FNAC suspicious of schwannoma.<sup>[11]</sup>

When determining the possible presence and extent of FNT, CT and MRI are extremely important. CT offers excellent bone detail that may reveal dilation of the intralabyrinthine segment, a middle ear mass, or expansion of the vertical canal. However, for showing disease extratemporally in the cerebellopontine angle, internal acoustic canal, or parotid gland, MRI is preferred.<sup>[3,10]</sup>

Treatment of FNT is controversial<sup>[4]</sup>. As in acoustic neurinoma, some researchers advise observation rather than surgical excision because FNT are generally slow-growing, benign tumors and many patients do not present with significant facial dysfunction. Because resection of FNT carries the risk of facial nerve paralysis, they advocate delaying surgery until the patient exhibits paralysis at least House-Brackmann (HB) grade III. During this time, the tumor may be followed by radiologic imaging.<sup>[12-14]</sup>

Classically, surgical treatment consists of excision of the lesion with the involved segment of the nerve followed by grafting or primary anastomosis.<sup>[15]</sup> Long-term follow-up studies show facial nerve paralysis of HB grade IV in about 80% of patients treated this way.<sup>[14]</sup> So far, there are only a small number of reports of tumor excision in which the nerve is left intact and functioning.<sup>[16-19]</sup> In our 3 cases, FNT was excised and axon integrity maintained, because no clinical signs of facial nerve paralysis were present at follow-up. We opted for surgical treatment so as to manage the concomitant cholesteatoma infection.

---

## CONCLUSIONS

---

FNT are very uncommon neoplasms that can originate from any segment of the facial nerve. The number of patients with undetected, asymptomatic facial nerve tumor may greatly exceed the number of those who present clinically. When proceeding with surgery, an attempt should always be made to spare the nerve, possibly providing a better outcome.

---

## REFERENCES

---

1. Mutlu C, Djeriç DR, Tekin M, Paparella MM, Schachern PA. Facial neuroma in the internal auditory canal. *Auris Nasus Larynx*. 2000;27:175-178.
2. Sherman JD, Dagnew E, Pensak ML, van Loveren HR, Tew JM Jr. Facial nerve neuromas: report of 10 cases and review of the literature. *Neurosurgery*. 2002;50:450-456.
3. Ulku CH, Uyar Y, Acar O, Yaman H, Avunduk MC. Facial nerve schwannomas: a report of four cases and a review of the literature. *Am J Otolaryngol*. 2004;25:426-431.
4. Kim JC, Bhattacharjee M, Amedee RG. Facial nerve schwannoma. *Ann Otol Rhinol Laryngol*. 2003;112:185-187.
5. Nager GT. Pathology of the temporal bone. *Williams and Wilkins* 25: 597-599, 1993.
6. Palacios E, Kaplan J, Gordillo H, Rojas R. Facial nerve hemangioma. *Ear Nose Throat J*. 2003;82:836-837.
7. Saito H, Baxter A. Undiagnosed intratemporal facial nerve neurilemmomas. *Arch Otolaryngol*. 1972;95:415-419.
8. May M, Schaitkin BM. Tumors involving facial nerve. In: May M, Schaitkin B, eds. *The Facial Nerve: May's Second Edition*. 2nd ed. New York, NY: Thieme Medical Publishers; 2000:393-408.
9. Balle VH, Greisen O. Neurilemmomas of the facial nerve presenting as parotid tumors. *Ann Otol Rhinol Laryngol*. 1984;93:70-72.
10. Krause HR, Hemmer J, Kraft K. The behaviour of neurogenic tumours of the maxillofacial region. *J Craniomaxillofac Surg* 21:258-261, 1993.
11. Chong KW, Chung YF, Khoo ML, Lim DT, Hong GS, Soo KC. Management of intraparotid facial nerve schwannomas. *Aust N Z J Surg*. 2000;70:732-734.
12. Liu R, Fagan P. Facial nerve schwannoma: surgical excision versus conservative management. *Ann Otol Rhinol Laryngol*. 2001;110:1025-1029.
13. Angeli SI, Brackmann DE. Is surgical excision of facial nerve schwannomas always indicated? *Otolaryngol Head Neck Surg*. 1997;117:S144-S147.
14. Perez R, Chen JM, Nedzelski JM. Intratemporal facial nerve schwannoma: a management dilemma. *Otol Neurotol*. 2005;26:121-126.
15. Yamaki T, Morimoto S, Ohtaki M, et al. Intracranial facial nerve neuroma: surgical strategy of tumor removal and functional reconstruction. *Surg Neurol*. 1998;49:538-546.
16. Nadeau DP, Sataloff RT. Fascicle preservation surgery for facial nerve neuromas involving the posterior cranial fossa. *Otol Neurotol*. 2002;24:317-325.
17. O'Donoghue GM, Brackmann DE, House JW, Jackler RK. Neuromas of the facial nerve. *Am J Otol*. 1989;10:49-54.
18. Nedzelski JM, Chiong CM. Intratemporal facial nerve tumor. In: Gates GA, ed. *Current Therapy in Otolaryngology-Head and Neck Surgery*. 5th ed. St. Louis: Mosby; 1994:102-107.
19. McMenomey SO, Glasscock ME 3rd, Minor LB, Jackson CG, Strasnick B. Facial nerve neuromas presenting as acoustic tumors. *Am J Otol*. 1994;15:307-312.