

ORIGINAL ARTICLE

Round Window Application of Implantable Hearing Aids in Radical Cavities

Levent Olgun, Muzaffer Balaban, Mehmet Ziya Özüer, Gürol Gültekin, Burcu Uçkan

Izmir Bozyaka Teaching and
Research Hospital, CI Center
Turkey

Correspondent Author:

Dr. Levent Olgun
Bozyaka Eğitim ve Araştırma
Hastanesi KBB Kliniği
Izmir, Turkey

E-mail: leventolgun@yahoo.com

Submitted: July 18, 2008

Revised: September 5, 2008

Accepted: September 27, 2008

Mediterr J Otol 2008; 191-196

Copyright 2005 © The Mediterranean
Society of Otolaryngology and Audiology

INTRODUCTION: Electromagnetic middle ear implants which had been originally used in patients with high frequency hearing losses with normal middle ear conductive mechanism, recently were begun to be used on patients with defective or absent ossicles. Round window application of transducer of electromagnetic implant, first used by Colletti seems to be promising in such patients.

OBJECTIVES: In this study indications and a modified technique of round window attachment of an electromagnetic implant (Vibrant Sound Bridge) are presented, and results obtained on 5 patients are discussed.

MATERIALS AND METHODS: All patients had been implanted at Izmir Teaching and Research Hospital on 2007 - 2008. All cases were formerly operated in various centers because of cholesteatoma and all but one found to be free of residual or recurrent cholesteatoma during surgery. In all cases floating mass transducer has been applied onto the round window membrane in a perichondrial envelope. Patients were switched on 4-6 weeks after surgery.

RESULTS: Pre-op AC levels were between 65-85 db (median 69.3) and BC levels were between 10.1-60db (median 33.7). SDS scores were between 46-95 % (median 77.3) In all patients we have not seen any deterioration in these values after surgery. After switch on hearing thresholds with implant were elevated near to BC levels. SDS scores were considerably better in all patients (median 83) after surgery.

Satisfactory hearing is only possible if the adequate amount of sound energy vibrates cochlear fluids and these vibrations excite the auditory neurons. Any problem which prevents sound energy to reach the inner ear fluids leads to a conductive deafness. Although various surgical techniques have been described in order to overcome problems of conductive mechanism, there remains a group of patients who can not benefit from middle ear surgery. In these patients hearing aids may be a solution.^[1] But a specific group of patients, namely patients with radical cavities have problems with hearing aids. Occlusion of ear canal leads to cavity problems, loss of acoustic energy within cavity causes feedback and inadequate gain and sound quality is far from being normal. Moreover the primary pathologies which leads to destruction of conductive mechanism may give harm to inner ear, i.e. in most of these patients a cochlear component can be seen at least in high frequencies. Most hearing aids do not cover the high frequencies. All these factors make the patients with radical cavities very bad hearing aid users.^[1,2]

Implantable hearing aids or active middle ear implants are popularized at last decade.^[3,4] Currently there are two group of implantable hearing aids; piezoelectric devices and electromagnetic devices. Patient selection is important and each device may have specific indications.^[3,4,5,6,7] Vibrant Sound Bridge(VSB) which is an electromagnetic implantable hearing aid is the only device commercially available in Turkey. It is mainly used in patients with high frequency hearing losses. Classically the transducer of the VSB is clipped to the long process of the incus.^[8,9] Although outcome is satisfactory in selected patients relatively high costs and limited indications prevents its widespread usage.^[8,10]

Sono inversion is not a new concept. First by Holmgren, later by Sourdille and Lempert, fenestration of lateral semicircular canal was used in otosclerosis.^[11] Colletti in 2005 have first used the transducer of Vibrant Sound Bridge onto the round window. Since this time round window application of implantable hearing aids have gained interest.^[12]

In this study small modifications in application of vibrant sound bridge(VSB) would be presented stressing important points in surgery and results obtained at 5 patients who were implanted at Izmir Teaching and Research Hospital CI Center will be discussed.

MATERIAL AND METHODS

Patients were aged between 23 and 58 years. One was a female and the rest were male.

All patients but one had radical cavities in both ears. One patient had open cavity tympanoplasty type 3 in one ear and radical cavity in the other, the constructed tympanic membrane was immobile and he had a severe mixt hearing loss.

All patients were bad hearing aid users for years mainly because of cavity problems and inadequate gain. All were enthusiastic about a better solution for their hearings.

In all patients VSB was applied onto the round window.

In all patients devices have switched on 4-6 weeks after operation.

All patients but one were followed up with tonal and speech audiometry on monthly basis. Patient 5 although had regularly come to follow up visits refused detailed audiological tests after second month.

Audiological results at 8 months after operation in four patients and 2 months after in one patient were evaluated for the study.

Surgical Technique

The important steps of the surgical technique is as follows :

a) A postauricular incision is used in order to reach the cavity. Cavity is entered from behind relatively high enough in order to protect the epithelial lining of the cavity from excessive tension.

b) Epithelial lining of the cavity is gently elevated caring not to tear it.

c) Promontorium and round window niche is visualized. Some bone drilling may be necessary to reach to the round window.

d) Posterior lip of round window niche is drilled with a diamond burr, caring not to touch the round window membrane.

e) A bed for VSB is created on the temporalis squama and implant body is fixed to the bed with nylon sutures.

f) A rectangular piece of tragal perichondrium is laid onto the round window membrane. (Fig.1)

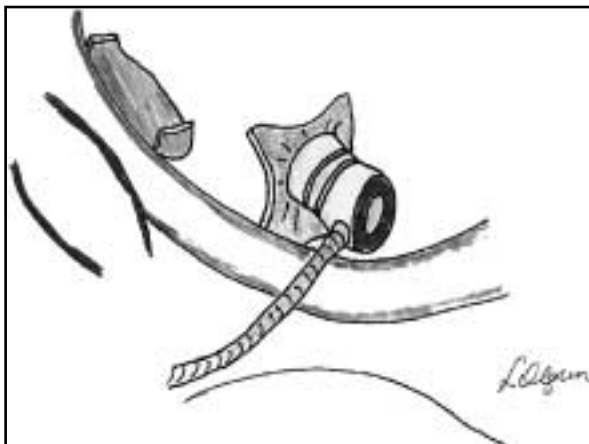


Figure-1

g) Clips of the VSB transducer (Floating Mass Transducer=FMT) is cut.

h) FMT is placed perpendicular to round window membrane.

i) Small pieces of perichondrium used in order to wrap the FMT.(Fig.2)



Figure-2


j) Electrode carrier is covered with bone dust, perichondrium and cartilage. Some fibrin glue is used for fixation.

RESULTS

Case 1




Case2



Case 3


M.B. VSB LEFT EAR BILATERAL MIXED HEARING LOSS, BILATERAL RADICAL MASTOIDECTOMY, AVERAGE FUNCTIONAL GAIN 50 dB



On audiograms 1, 2, 3, 4, 5 hearing results of the patients can be seen. In all patients we have not seen any deterioration of the hearing after surgery. Hearing levels with implants elevated near to BC levels. In patients 3,4 some over correction could be obtained in some frequencies. In all patients hearing with VSB were better than hearing with conventional aids. In speech tests both in monosyllables and sentences marked benefit was obvious. For patient 5 all speech tests could not be completed because of patients resistance to the tests which were considered boring and time consuming by him. All patients have been wearing their devices full day regularly. We have not seen any complication on these patients.

Case4

O.K. VSB RIGHT SIDE AVERAGE FUNCTIONAL GAIN 25 dB




DISCUSSION

Hearing is only possible with the vibration of cochlear fluids. In patients whose air conduction mechanism was destroyed either because of disease or previous surgeries sound energy can not reach adequately to the oval window. Although many tympanoplasty methods have been described there still remains a special group of patient who does not benefit these techniques.

Case 5

Y.C. VSB LEFT EAR BILATERAL RADICAL CAVITY OVER CLOSURE OF AIRBONE GAP LARGE FUNCTIONAL GAIN



Despite an intact tympanic membrane and a good ossiculoplasty a patient can not hear properly because of immobilization of reconstructed system due to fibrosis. Multiple surgeries which are sometimes necessary to eradicate the pathologic tissues can enhance unsatisfactory hearing results. Moreover in some patients there can be a cochlear component of hearing loss which can not be corrected by middle ear surgeries.

Ear level hearing aids or bone conducting devices may be a solution for these patients but patients who have radical cavities generally have difficulties with the conventional hearing aids. Apart from rise of cavity infections due to occlusion of the ear canal acoustical problems can occur such as inadequate amplification, unnatural sound quality and feedback. It

may be difficult to satisfy such a patient with any device and some of them wear their aids occasionally^[12].

Bone anchored hearing aids(BAHA) can restore the hearing deficit of patients with conductive deafness^[13].It seems very suitable to patients with radical cavities but disadvantage of having an abutment which penetrates the skin may cause considerable hesitancy among these patients.^[14] Moreover sensorineural component can not be corrected with BAHA in every instance.

Implantable hearing aids which are originally developed for the patients with sensorineural hearing losses seems to be beneficial in patients with conductive or mixed type deafness using special techniques. Stimulation of cochlear fluids via round window, sonoinversion is not a new concept. Sourdille first have got successful results with fenestration of lateral semicircular canal in patients with stapedial ankylosis.^[11]

Active middle ear implants seems to give promising results when they are used onto the round window. Colletti who has first used VSB onto the round window reported excellent results. He has used the method on patients who had had several unsuccessful middle ear surgeries. In all cases he could reach to better hearing levels with implants than aided conditions.^[12] Kiefer implanted an ear atresia patient combining the method with reconstruction of the auricle.^[15] Other middle ear implants have also been used onto the round window with success in atresia patients.^[16]

Among these five patients we have not seen any complications but our experience from cochlear implant patients with radical cavities shows that if the position of the implant body and the electrode array is not correctly tailored electrode array can disrupt the epithelial lining of the cavity and can cause serious problems^[17,18].One can claim that blind-sac closure of the external auditory canal(EAC) may be more suitable in such patients^[19].Although this method seems to be safer it is not possible to close the external auditory

canal in all cases because of very wide meatoplasties. All our cases had very wide meatoplasties so that we preferred to leave the EAC open.

Hearing gain obtained with the VSB onto the round window seems to give satisfactory results even better than the best aided conditions. At least in four patients' speech tests point out that patients get considerable benefit from implantation. All patients have reported that sound quality is much more better than any hearing aid which they have ever tried. Elimination of cavity occlusion is another advantage of the technique. Electromagnetic middle ear implants may be a remedy for the patients who already had lost the conductive system.

CONCLUSION

Patients with radical cavities in both ears can benefit from electromagnetic middle ear implants. (VSB) Surgery needs some skill and when technical steps carefully applied,round window application of FMT seems not to be hazardous to the residual hearing of the patients. Hearing gains are better than conventional hearing aids. Despite relatively high prices active electromagnetic middle ear implants will play an important role in the rehabilitation of selected patients with conductive and mixed hearing losses.

REFERENCES

1. Huttenbrink K-B. Current status and critical reflections on implantable hearing aids. *Am. J. Otol.*1999; 20:409-415
2. Kochkin S. 'Why my hearing aids are in the drawer' The consumers perspective. *Hearing J.* 2000; 53:34-41
3. Zenner HP, Leysieffer H, Maassen M, Lehner R, Lenarz T, Baumann J et al. Human studies of a piezoelectric transducer and a microphone for a totally implantable electronic hearing device. *Am. J. Otol.* 2000; 21:196-204

4. Jenkins HA, Niparko JK, Slattery WH, Neely JG, Fredrickson JM. Otologics middle ear transducer ossicular stimulator performance results with varying degrees of sensorineural hearing loss. *Acta Otolaryngol.*2004; 124:391-394
5. Jenkins HA, Atkins JS, Horlbeck D, Hoffer ME, Balough B, Ariago JV et al. U.S. phase 1 preliminary results of use of the Otologics MET fully-implantable ossicular stimulator. *Otolaryngol Head Neck Surg.*2007; 137:206-212
6. Hough JVD, Matthews P, Wood MW, Dyer RK. Middle ear electromagnetic semi-implantable hearing device: Results of the phase 2 SOUNDTEC direct system clinical trial. *Otol Neurotol.*2002; 23:895-903
7. Silverstein H, Atkins J, Thompson JH Jr, Gilman N. Experience with the SOUNDTEC implantable hearing aid. *Otol Neurotol.*2005; 26:211-217
8. Uziel A, Mondain M, Hagen P et al. Rehabilitation for high frequency sensorineural hearing impairment in adults with the Symphonix Vibrant Sound Bridge: A Comparative Study. *Otol Neurotol.* 2003; 24:775-783
9. Venail F, Lavieille J-P, Meller R, Deveeze A, Tardivet L, Mangan J. New perspective for middle ear implants: First results in otosclerosis with mixed hearing loss. *The Laryngoscope.*2007; 117:552-555
10. Schmuziger N, Schimmann F, Wengen D. Long-term assessment after implantation of the Vibrant Sound Bridge device. *Otol Neurotol.*2006; 27:183-188
11. Shea JJ, Shea PF, Mc Kenna MJ. Stapedectomies or otoclerosis. In "Surgery of the ear". Eds. Glosscock ME, Gulya AJ 5th Edition BC Decker Inc.2003 Spain
12. Colletti V, Soli S, Carner M, Colletti L. Treatment of mixed hearing losses via impantation of a vibratory transducer on the round window. *Int. J. Audiol.* 2006; 45:600-608
13. Hol MK, Snik AF, Mylanus EA, Cremers CW. Long-term results of bone-anchored hearing aid recipients who had previously used air-conduction hearing aids. *Arch Otolaryngol Head Neck Surg.*2005; 131:321-5.
14. Badran K, Bunstone D, Arya AK, Suryanarayanan R, Mackinnon N. Patient satisfaction with the bone-anchored hearing aid: A 14-year experience. *Otol Neurotol.*2006; 27:659-66.
15. Kiefer J, Arnold W, Staudenmaier R. Round window stimulation with an implantable hearing aid (Soundbridge) combined with autogenous reconstruction of the auricle: A new approach. *ORL* 2006; 68:378-385
16. Siegert R, Mattheis S, Kasic J Fully implantable hearing aids in patients with congenital aural atresia. *The Laryngoscope.*2007; 117(2);336-340
17. Olgun L, Batman C, Gultekin G, Kandogan T, Cerci U. Cochlear implantation in chronic otitis media *J Laryngol Otol.*2005; 119:946-9.
18. Kandogan T, Levent O, Gurol G. Complications of pediatric cochlear implantation: Experience in Izmir. *J Laryngol Otol.*2005; 119:606-10.
19. Xenelis J, Nikolopoulos TP, Marangoudakis P, Vlastarakos PV, Tsangaroulakis A, Ferekidis E. Cochlear implantation in atelectasis and chronic otitis media: long-term follow-up. *Otol Neurotol.*2008; 29:499-501.