

## CASE REPORT

### Massive Posttraumatic Otorrhoea

Maciej Wiatr, Jacek Skladzien, Marek Moskala

The Faculty of Otolaryngology and Otolaryngological Clinic at the Collegium Medicum of the Jagiellonian University of Krakow (MW, JS)  
The Faculty of Neurosurgery and Neurosurgical Clinic at the Collegium Medicum of the Jagiellonian University of Krakow (MM)

**Objective;** Otorrhoea can be iatrogenic, posttraumatic or can be a result of chronic otitis media. We present a case of a 44-year-old woman operated on in the Otolaryngology Department in Krakow due to persistent profuse discharge of the cerebrospinal fluid from the right ear.

**Materials & Methods;** The patient had experienced a head injury 26 years previously which resulted in recurrent episodes of meningitis. Previous surgeries, one neurosurgical operation and three middle ear operations were ineffective. The patient constantly complained about headaches, dizziness, balance disorder, hypoacusis in the right ear and visual dysfunction. During the middle ear surgery, it was revealed that there was a large bone loss in the middle and posterior cranial fossae, filled by meningoencephalocele and a discharge of the cerebrospinal fluid around the meningoencephalocele. Despite reconstructing skull bones, small discharge of the cerebrospinal fluid was still observed postoperatively. Then, a decision was made to close the defect by the way of neurosurgical approach. Craniotomy was performed, and the defect was closed from the side of the cranial cavity.

**Results;** The treatment proved effective. The discharge of the cerebrospinal fluid discontinued and the external auditory meatus was reconstructed as well.

**Conclusion;** Managing otorrhoea through the otological approach using the TachoComb(r) and the oxycel(r) with obliterating the mastoid process with the pedicle flap of the temporal muscle may be effective in the case of small defect. Larger defects require bony support via neurosurgical treatment.

Submitted : 20 June 2008

Revised : 19 August 2008

Accepted : 24 December 2008

Those patients diagnosed with discharge of the cerebrospinal fluid are relatively rare cases. Upon diagnosing patients as having spinal meningitis, otogenic origin must be taken into account, resulting from complications due to chronic (mainly cholesteatoma) otitis media, iatrogenic origin of the disease, as well as posttraumatic changes<sup>[1,2]</sup>.

#### Case Report

We present a case of 44-year-old woman operated on in the Department of Otolaryngology at the Jagiellonian University of Krakow due to persistent profuse discharge of cerebrospinal fluid from the right ear. The patient had experienced head injury 26 years

previously. Since then, the patient complained about headaches, dizziness, balance disorder, hypoacusis in the right ear and visual dysfunction. After the injury, this lady underwent treatment for purulent spinal meningitis which was repeated seven times. Previous surgeries, one neurosurgical approach and three middle ear operations have not brought anticipated results.

Preoperative otoscopic examination revealed meningoencephalocele filling the right external auditory meatus. During the surgery, a large bone defect was noted in the middle and posterior cranial fossa. The defect was in the shape of an irregular

#### Corresponding address:

Maciej Wiatr, MD

The Faculty of Otolaryngology and Otolaryngological Clinic at the Collegium Medicum of the Jagiellonian University of Krakow  
Krakow-Poland ul. Sniadeckich 2

Phone: 00 48 12 424 79 00; Fax 00 48 12 424 79 25; e-mail: mwiatr@mp.pl

Copyright 2005 © The Mediterranean Society of Otolaryngology and Audiology

triangle, 6 cm in height, 4 cm base, with its vertex pointed towards the peak of the petrous portion of the temporal bone. The hernia of brain tissue was mobilised and pushed back to middle cranial fossa. Considering the synostosis, meningoencephalocele was not released at the passage between the sigmoid and the transverse sinuses due to risk of haemorrhage. Skull base reconstruction using either cartilage or bone was impossible due to the synostosis, and therefore several layers of Oxycel® and TachoComb® were used. Additionally, the temporalis muscle and the sternocleidomastoid muscle flap were mobilised, and the cavity of the mastoid process was obliterated, thus making support for the structure prepared earlier. No discharge of the cerebrospinal fluid was observed during the operation.

During the follow-up period, leakage was observed again in the external auditory meatus. Due to ineffectiveness of otosurgery, the decision was made to seal the defect on the side of skull cavity (Figure 1). The right-sided fronto-temporal craniotomy was performed. After exposing the hernia sac, it was sealed with TachoComb® and tissue adhesive. Oxycel® was used as well to support these elements on the flap of the temporalis muscle that had been used in previous operation. This procedure proved effective, as confirmed by the results of postoperative CT (Figure

2a and 2b). The patient has remained subject to periodical otolaryngological and neurosurgical supervision. No episode of spinal meningitis has occurred since then. Headache has withdrawn. Dizziness occurs less frequently and with less severity. The decrease in visual acuity due to the earlier episodes of spinal meningitis has remained at the same level as observed before the surgery.

Pure tone thresholds 1 month after the surgery showed an improvement (Figure 3).

### Discussion

Posttraumatic discharge of the cerebrospinal fluid is usually observed as a result of linear fractures of the pyramid of temporal bone due to an impact on the side of the skull (in the temporoparietal region). The fracture crack passes through the external auditory meatus, the roof of tympanic and mastoid cavities and the frontal edge of the pyramid of the temporal bone. The contents discharged from the external auditory meatus is usually coloured with blood. The imaging tests show pneumocephalus (Figure 2a). In approximately 70-80% of the patients (contrary to the cases of the nasal discharge of cerebrospinal fluid), the fistula heals spontaneously within 2 weeks after injury. The discharge of the cerebrospinal fluid always requires hospitalization, and when it persists for a long

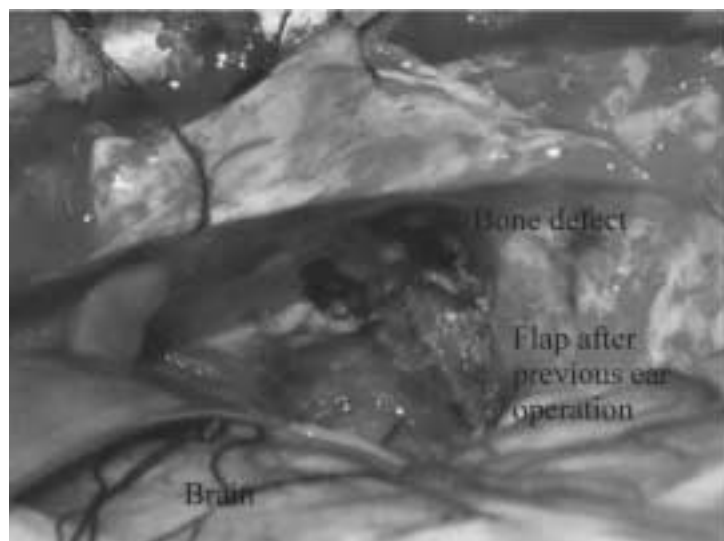


Figure 1. Intracranial approach: Defect of middle and posterior cranial fossae.

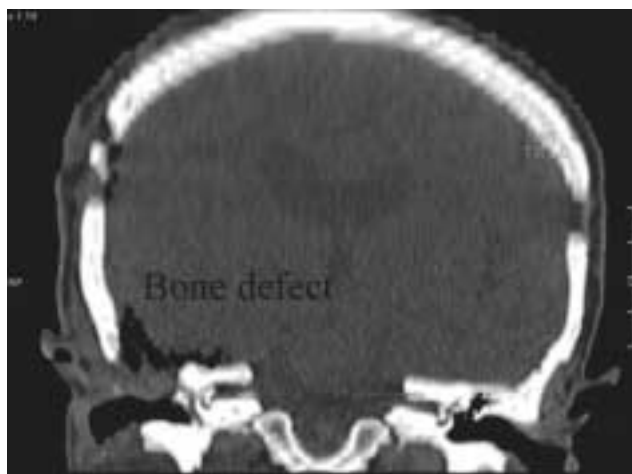


Figure 2a

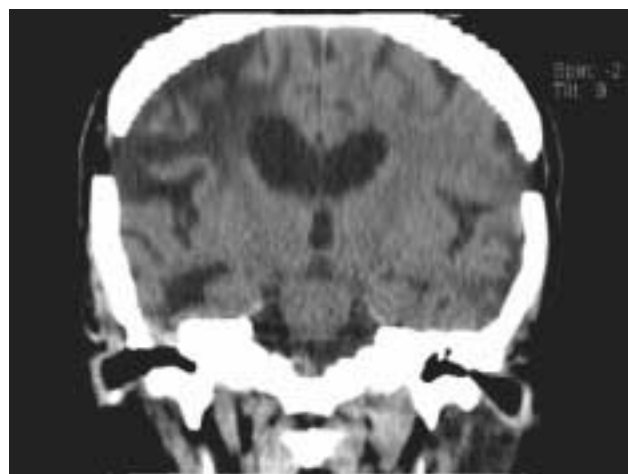


Figure 2b

Figure 2. Cranial CT - Coronal plane: Bone defect - before (Figure-2a) and after (Figure - 2b) surgery.




Figure 3. Right ear: hearing thresholds before and after the surgery.

time, the location where the cerebrospinal fluid is discharged must be sealed surgically.

The procedure comes down to preventing discharge in the course of otosurgery using TachoComb®, Oxycel®, a fragment of fascia or fake meninges and general treatment with antibiotics penetrating through the blood-brain barrier to prevent spinal meningitis<sup>[3,4]</sup>.

The method of reconstructing skull bone defects depends on their size. The most popular material used to reconstruct the bony wall of the skull base is the fascia of the temporal muscle. In the cases of minor defects, surgical treatment consists of covering the

exposed dura mater with a piece of the fascia. The fascia is often strengthened additionally with Oxycel® and TachoComb®. Considerable defects are sealed by supporting the layer described above with a piece of cartilage. Larger defects are covered using an additional pedicle muscle flap to support the structure and to obliterate the surgical cavity in the temporal bone. The largest defects, more than 1 cm in diameter, are sealed with additional layer, the third layer, located between the fascia and the pedicle muscle flap described above, which is a piece of bone taken from either the anterior or the lateral wall of the maxillary sinus accessed through

the sublabial approach. Some authors use cartilage instead of bone lamella.

In the cases of substantial bone defects with meningoencephalocele it may be required to either gain neurosurgical access or have surgery performed by a team of ENT specialists and neurosurgeons<sup>[5-7]</sup>.

Defects in the bony walls of the middle ear are found more often in the middle cranial fossa. Intracranial complications are present in every fifth patient with the dura mater exposed. However, it should be pointed out that bone defects in the skull base are one of the ways to develop such intracranial complications. The latter can also result from inflammatory changes in the bone tissue or from venous thrombophlebitis<sup>[8,9]</sup>.

Meningitis is the most frequently diagnosed condition, while meningoencephalocele is less frequent. Direct contact of the brain tissue with the regions of the middle ear which is subject to the inflammatory process is a favourable condition to develop further intracranial complications.

Nearly 80% of skull bone defects remain asymptomatic; they are revealed incidentally during the surgery of the middle ear. The above observations emphasize significant role of preoperative imaging modalities, in particular computerized axial tomography and magnetic resonance imaging, in diagnosing such abnormalities. This issue is especially important when there is absence of any symptoms in the majority of patients<sup>[10]</sup>.

In the case discussed above, the bone (taken from either frontal or lateral wall of the maxillary sinus accessed from below the cheek) could not be placed at the entrance to hernia due to synostosis at the passage between the sigmoid and the transverse sinuses. Thus reconstruction using TachoComb<sup>®</sup>, Oxycel<sup>®</sup> and obliterating the mastoid process with a muscle flap was necessary. This procedure proved ineffective due to a substantial size of the defect.

The above conclusion confirms our earlier observations that managing the CSF leak with TachoComb<sup>®</sup>, Oxycel<sup>®</sup> and obliterating the mastoid process with pedunculated muscle flap works well for smaller defects only, while larger defects in the skull base additionally require supporting with a fragment of bone.

## References

1. Patel RB, Kwartler JA, Hodosh RM, Baredes S.: Spontaneous cerebrospinal fluid leakage and middle ear encephalocele in seven patients. *Ear Nose Throat J.* 2000;79:372-3, 376-8.
2. Kizilay A, Aladağ I, Cokkeser Y, Ozturan O: Dural bone defects and encephalocele associated with chronic otitis media or its surgery. *Kulak Burun Bogaz Ihtis Derg.* 2002; 9:403-9.
3. Mosnier I, Fiky LE, Shahidi A, Sterkers O: Brain herniation and chronic otitis media: diagnosis and surgical management. *Clin Otolaryngol Allied Sci.* 2000; 25:385-91.
4. Gubbels SP, Selden NR, Delashaw JB Jr, McMenomey SO: Spontaneous middle fossa encephalocele and cerebrospinal fluid leakage: diagnosis and management. *Otol Neurotol.* 2007; 28:1131-9.
5. Nahas Z, Tatlipinar A, Limb CJ, Francis HW: Spontaneous meningoencephalocele of the temporal bone: clinical spectrum and presentation. *Arch Otolaryngol Head Neck Surg.* 2008; 134:509-18.
6. Escada P, Vital JP, Capucho C, Lima C, da Silva JM, Penha RS: Meningoencephalic herniation into the middle ear. *Rev Laryngol Otol Rhinol (Bord).* 1999; 120:47-52.
7. Lundy LB, Graham MD, Kartush JM, LaRouere MJ: Temporal bone encephalocele and cerebrospinal fluid leaks. *Am J Otol.* 1996; 17(3):461-9.
8. Migirov L, Duvdevani S, Kronenberg J. Otogenic intracranial complications: a review of 28 cases. *Acta Otolaryngol.* 2005; 125:819-22.
9. Bento R, de Brito R, Ribas GC. Surgical management of intracranial complications of otogenic infection. *Ear Nose Throat J.* 2006; 85:36-9.
10. Wiatr M, Skladzien J, Tomik J. Otogenic intracranial complications from data collected at Department of Otolaryngology Collegium Medicum Jagiellonian University between 1998-2006 [Article in Polish]. *Przegl Lek.* 2006; 63:1173-6.