

## CASE REPORT

### Primary Skull Base Lymphoma with Concomitant Petrous Cholesteatoma: Case Report

Chiara Bianchini, Andrea Ciorba, Stefano Pelucchi, Roberto Bovo, Gian Matteo Rigolin, Alessandro Martini, Antonio Pastore

ENT and Audiology Department, University Hospital of Ferrara Haematology Department, University Hospital of Ferrara

**Background:** There are no reports in the literature so far, showing the coexisting presence of a lymphoma and a cholesteatoma in the skull base. Our aim was to point up the clinical features of a primary malignant left petro-clival lymphoma presenting with a concomitant petrous cholesteatoma. The patient presented a progressive history of dysarthria and multiple cranial nerve palsies. Both the lesions were documented radiologically and histologically.

**Discussion and Conclusion:** Primary lymphoma of the clivus are rare. The clinical and the radiological features of the lesion have been described as well as the pathologic findings.

Submitted : 01 August 2009

Accepted : 20 November 2009

#### Introduction

Primary lymphomas of the skull base are relatively uncommon neoplasms that can be morphologically difficult to distinguish from other malignant neoplasms in this site. However, increasing incidence of lymphoma manifestations has been recently reported<sup>(1-4)</sup>.

Moreover, there are no reports in the literature so far, showing the coexisting presence of a lymphoma and a cholesteatoma in the skull base. The Authors are presenting the clinical radiological and histological features of a case.

#### Case Report

B.F. was a 76 years old male patient, referred to the ENT Department for more than one month lasting dysarthria and dysphagia, which worsened within the last ten days. He also noticed the onset of hearing loss and left ear otorrhea since the last three months. The heavy smoker patient (two packs a day, since his adolescence) suffered from of a generalized atherosclerotic vasculopathy with ischaemic encephalopathy.

Clinical examination revealed an orientated patient with a left IX<sup>th</sup>, X<sup>th</sup> and XII<sup>th</sup> nerve palsy; no signs of facial nerve weakness were present. The nasopharyngeal endoscopy disclosed the presence of a left hemi-nasopharyngeal mass, and a transnasal biopsy was promptly assessed. At the same time, the otomicroscopic examination disclosed a postero-superior left marginal perforation, and the presence of mesotympanic cholesteatoma.

Further neurological as well as laboratory examinations were normal.

The high resolution skull base CT scans confirmed the presence of inflammatory tissue involving the left middle ear and the ossicular chain, with initial signs of tegmen erosion; no signs of extra-petrous extension of the cholesteatoma were noticed (Figure 1). A small osteolithic area of the left petrous apex, also involving the left occipital condyl, was noticed.

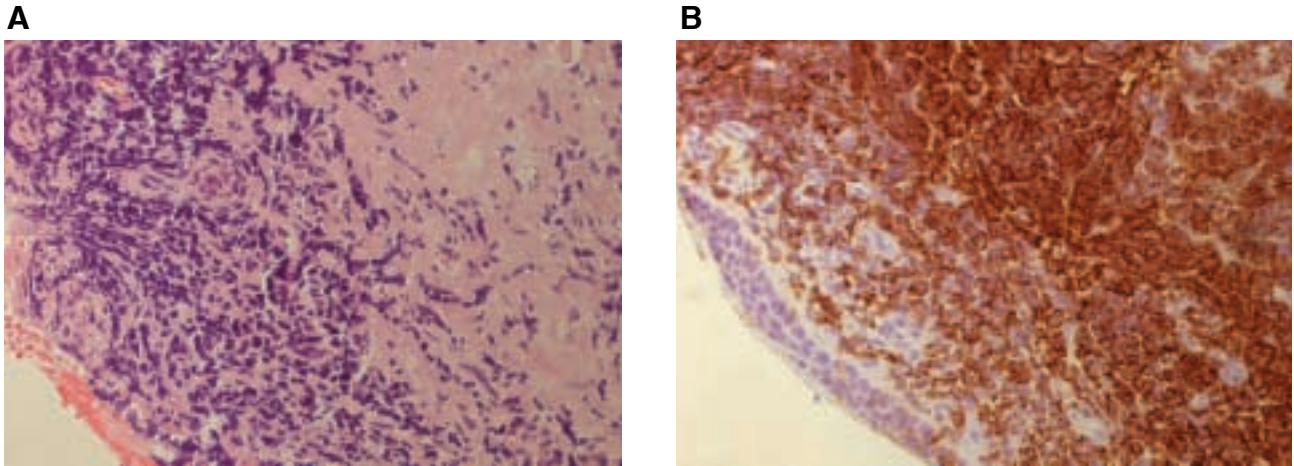
The MRI disclosed a mass involving the left petro-clival space. The lesion was occupying the clivus extending towards the left temporal bone, also

#### Corresponding address:

Andrea Ciorba  
ENT Department, University Hospital of Ferrara, C.so Giovecca 203, 44100 Ferrara, ITALY  
Phone: +39-0532-236383; Fax: +39-0532-237615 E-mail: andrea.ciorba@unife.it

Copyright 2005 © The Mediterranean Society of Otolaryngology and Audiology





**Figure 3. A.** Hematoxylin and eosin stain showing a diffuse infiltration of lymphoid cells. (200x). **B** The tumour cells resulted positive for the CD20 (200x).

### Discussion

Lymphoma is the malignant monoclonal proliferation of lymphoid cells in discrete tissue masses of the immune system, such as lymph nodes, spleen and bone marrow. Primary skull base lymphoma arising from the petro-clival space is quite rare entity, accounting for 3% of all intracranial tumors <sup>[1]</sup>. Risk factors associated with the occurrence of this disease include AIDS, immunosuppression for organ transplantation, autoimmune diseases, and congenital immunodeficiencies. Nonetheless it has been reported that over the past two decades the incidence of both intracranial and extracranial tumours is increasing equally in immunocompetent and immunocompromised patients and involving up to 6% of patients with HIV-infection <sup>[5]</sup>.

Indeed, there are no reports in the literature so far, showing the onset and the concomitant presence of two different skull base pathologies (lymphoma and cholesteatoma) at the same time: to our knowledge this is the first report in which both skull base diseases have been described together.

Both CT and MRI are essential for the complete assessment of skull base lesions. These imaging modalities give complementary information since CT depicts bony details clearly delineating bony

involvement and destruction (and it is essential for the cholesteatoma assessment), whereas MRI best demonstrates the intracranial and extracranial soft tissue anatomy. MRI with gadolinium is in fact considered as the imaging method of choice for the intracranial lymphoma diagnosis, which usually shows either space occupying lesions or diffusely infiltrating masses with intense contrast enhancement in T1-weighted images. In cases with diffuse leptomeningeal involvement, generalized post-contrast enhancement of the meninges would be present <sup>[6]</sup>. Nonetheless, the definitive diagnosis should be made with the help of a surgical biopsy, as in the presented case.

Large cell lymphoma of B-cell origin is the most common subtype of malignant non-Hodgkin's primary lymphoma that primarily involves the CNS (same type of the presented case). It is reported that this malignancy can mimic several neurological diseases. The clinical picture is sometimes similar to cerebrovascular disease or encephalitis with multiple cranial nerve palsies. Symptoms usually include focal neurological deficits (73%), neuropsychiatric symptoms (28%), seizures (9%), and increased intracranial pressure (3%). The most common sites of involvement are the frontal lobe, temporo-parietal lobe, and basal ganglia. Multiple intracranial lesions can be present in 25 to 44% of the patients <sup>[6]</sup>.

Differential diagnosis of skull base lesions includes nasopharyngeal carcinoma, meningioma, chordoma, metastasis, esthesioneuroblastoma, tuberculosis and fungal infections, miscellaneous granulomatous diseases such as Wegener's granulomatosis, melanotic melanoma, amyloidoma Schwannoma and, although exceedingly rare, pituitary adenocarcinoma<sup>[7-9]</sup>.

### Conclusions

To conclude, while the petrous cholesteatoma is a relatively frequent skull base lesion, primary skull base malignant lymphomas are quite rare. Indeed, this is the first report showing the onset and the concomitant presence of these two different skull base pathologies. It is of practical importance to recognize lymphoma as a possible cause of nasopharyngeal lesion and of cranial nerve dysfunction; even if uncommon, it should always be included in the differential diagnosis of skull base aggressive neoplasm. Moreover, since neoplasm such as lymphoma can be successfully treated with chemotherapy, it is strongly recommended that a histological diagnosis is made before instituting definitive therapy for extra-CNS tumours. Other tumours such as meningiomas, are primarily treated with surgical resection rather than chemotherapy<sup>[9]</sup>.

### References

1. Roman-Goldstein SM, Jones A, Delashaw JB, McMenomey S, Neuwelt EA Atypical central nervous system lymphoma at the cranial base: report of four cases (Discussion 615-616). *Neurosurgery* 1998; 43: 613-615.

2. Nakatomi H, Sasaki T, Kawamoto S, Fujimaki T, Furuya K, Kirino T Primary cavernous sinus malignant lymphoma treated by gamma knife radiosurgery: case report and review of the literature (Discussion 278-279). *Surg Neurol* 1996; 46:272-278.

3. Erlich RB, Swerdlow SH, Gupta NK, Lister J Primary lymphoma of the skull presenting as multiple cranial nerve palsies. *Leuk Lymphoma* 1996; 23:395- 399.

4. Han MH, Chang KH, Kim IO, Kim DK, Han MC Non-hodgkin lymphoma of the central skull base: MR manifestations. *J Comput Assist Tomogr* 1993; 17:567-571.

5. Erdag N, Bhorade RM, Alberico RA. Primary lymphoma of the CNS: typical and atypical CT and MRI imaging appearances. *AJR* 2001; 176: 1319-26.

6. Lenarz M, Durisin M, Becker H, Lenarz T, Nejadkazem M. Primary central nervous system lymphoma presenting as bilateral tumors of the internal auditory canal. *Skull Base*. 2007; 17(6):409-12.

7. King AD, Lei KI, Richards PS, Ahuja AT. Non-hodgkin's lymphoma of the nasopharynx: CT and MR imaging. *Clin Radiol* 2003; 58:621-625 6.

8. Jung CS, Zimmermann M, Seifert V. Clivus lymphoma. *Acta Neurochir (Wien)* 2004; 146:533-534.

9. Hans FJ, Reinges MHT, Nolte K, Reipke P, Krings T. Primary lymphoma of the skull base. *Neuroradiology*, 2005; 47: 539-542.