

## ORIGINAL ARTICLE

# Mastoid Cavity after Cochlear Implant Surgery with the Mastoid Saving Surgical Approach Method

Rinze A.Tange, Vedat V. Topsakal, Yvette E.Smulders, Wilko Grolman

Dept of Otorhinolaryngology University Medical Center Utrecht Utrecht the Netherlands

**Objective:** To study postoperative status of the mastoid cavity after cochlear implantation by the suprameatal approach method.

**Methods:** Pre- and postoperative protocolair prepared CT-scans of the mastoid cavity of patients who were operated for cochlear implantation were studied. 79 patients were included in this study. All patients were operated by the two authors using a mastoid saving surgical suprameatal approach for cochlear implantation. The postoperative CT-scans were evaluated after 6 months or more after surgery. Changes of the state of the mastoid observed by CT scan were documented.

**Results:** In 76 cases no abnormalities were observed in the mastoid of the operated ear for cochlear implantation. The delicate structures of the mastoid cavity were kept intact without any sign of mucosal reaction. In two cases of implantation for deafness due to otosclerosis swollen mucosa was observed in the mastoid without any clinical relevance. In one case (a child) opacification of the whole mastoid and middle ear was observed without destruction of the structures of the mastoid. Treatment with oral antibiotics cured this otitis media without rest reactions in the mastoid

**Conclusions:** The delicate structures of the mastoid cavity can be kept intact using a mastoid saving suprameatal surgical approach in cochlear implant surgery. In almost all the cases we could demonstrate by CT-scan that there is not any reaction of the mucosa in the mastoid and middle ear after cochlear implantation. There were no differences in the postoperative state of the small or large pneumatized mastoid.

Submitted : 15 December 2009

Revised : 23 December 2009

Accepted : 27 December 2009

## Introduction

Since the beginning of cochlear implantation in the mid seventies of last century the surgical technique of a mastoidectomy and posterior tympanotomy has been accepted as the classic route for both drilling of the cochleostomy and positioning of the array <sup>[1]</sup>. Alternative surgical implantation techniques have been introduced in favour to minimize surgical trauma and shortening operation time.<sup>[2-5]</sup>. All these alternative approaches have in common that besides the reduced risk of facial nerve injury a classical mastoidectomy with posterior tympanotomy is avoided. The suprameatal technique (SMA) as introduced by Kronenberg et al <sup>[4]</sup> is the most popular as alternative technique for cochlea implantation. The SMA

approach involves exposing the middle ear through the external auditory canal and inserting the electrode into the cochlea through a suprameatal tunnel bypassing then mastoid cavity. In this present study we have studied the postoperative status of the mastoid cavity after 79 cochlear implantations by the suprameatal approach method.

## Material and Methods

From October 2002 to September 2006, 79 patients with profound deafness were implanted with a cochlear implant. The group documented in a database consisted of 70 adults and 9 children. Gender was 32 men and 47 women with average age of 43,3 years. In 43 cases the right ear was implanted and in 36 cases the left ear. In 69 cases a Implants from Cochlear

### Corresponding address:

Assoc.Prof. Dr R.A.Tange

Dept of Otolaryngology University Medical Center Utrecht - G 05.129 P.O.Box 85500 3508 GA Utrecht - The Netherlands

E-mail: R.A.Tange@umcutrecht.nl

Copyright 2005 © The Mediterranean Society of Otolgy and Audiology

Company (11 CI24RCS , 33 CI24RCA and 25 CI24RE CA) was implanted and in 10 cases a Advanced Bionics (CI-1400-02H) was used. The pathology for the deafness was in 22 cases progressive sensorineural deafness followed by congenital deafness in 23 cases, meningitis in 12 cases, rubella in pregnancy 8 cases, otosclerosis in 5 cases and 9 cases aetiology unknown. In 2 cases bilateral cochlear implantation was performed. In one child simultaneous and one female adult sequential bilateral implantation. Preoperative and 6 months postoperative CT-scans of the ears were performed according a standard protocol. In all cases a modified suprameatal surgical implantation technique was used as previously described by our team <sup>[6,7]</sup>. According the work of Gérard et al <sup>[8]</sup> in adults and Black at al <sup>[9]</sup> in children we used the small retroauricular C incision in all cases studied

In 40 cases a mobile x-ray C-arm investigation was used to verify optimal positioning of the electrode in the cochlea intraoperatively. This procedure has been described in detail before. <sup>[10]</sup> The pre- and post-operative CT-scans were evaluated and changes of the state of the mastoid after surgical cochlear implantation were documented.

## Results

The comparison of the preoperative and postoperative CT-scan's produced in 76 cases demonstrated no abnormalities in the mastoid of the operated ear after

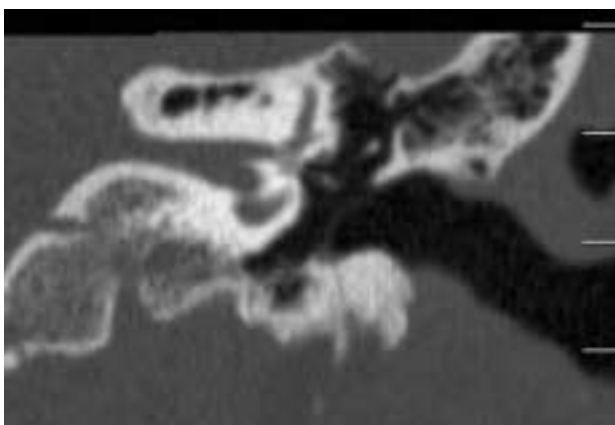


Figure 1. Pre operative CT-scan Pat.3239232

cochlear implantation. The delicate structures of the mastoid cavity were kept intact without any sign of mucosal reaction. The suprameatal tunnel showed no signs of postoperative bone or mucosa reaction. (Figures 1-2). Figures 3 to 5 demonstrate clearly no reaction of the mucosa in the mastoid and middle ear after a cochlear implantation. In two cases of implantation for deafness due to otosclerosis swollen mucosa was observed in the mastoid without any clinical relevance. In one case (a child) signs of otitis media of the mastoid and middle ear was observed without destruction of the structures of the mastoid. Treatment with oral antibiotics cured this otitis media without any further reactions in the mastoid later on. The post-implant speech perception scores improved in the whole group studied. The improvement in the phoneme scores on a CVC word testing quiet was evident. The mean CVC phoneme score after 12 months of CI use improved from 25.1% pre-implant (with hearing aid) to 88.4% post-implant. An average gain 63.3 % was obtained.

## Discussion

House <sup>[11]</sup> introduced the classic surgical technique for cochlear implantation. This surgical approach uses a complete mastoidectomy with an attempt to leave a bony overhang posteriorly and superiorly to capture the proximal electrode lead <sup>[11,12]</sup>. After the complete mastoidectomy, a posterior tympanotomy is performed with special attention to the facial nerve and

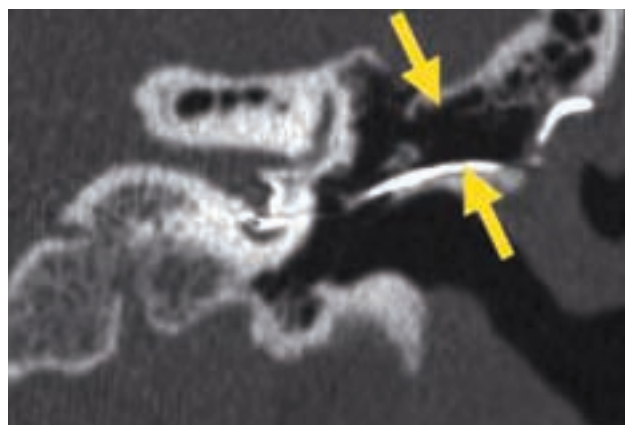
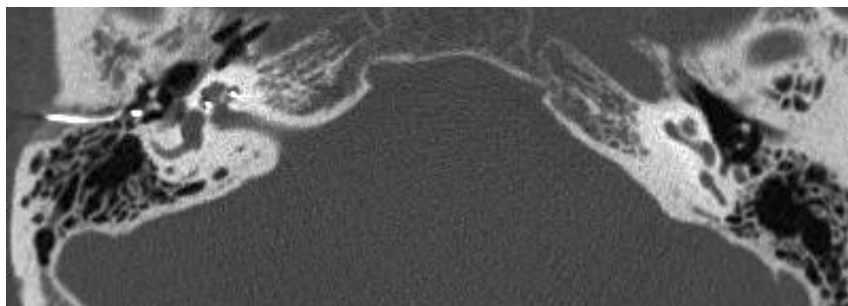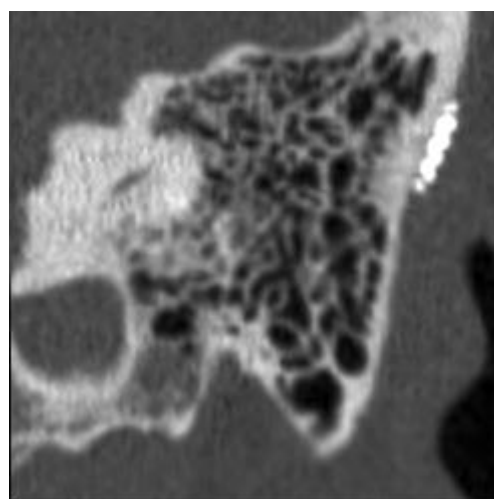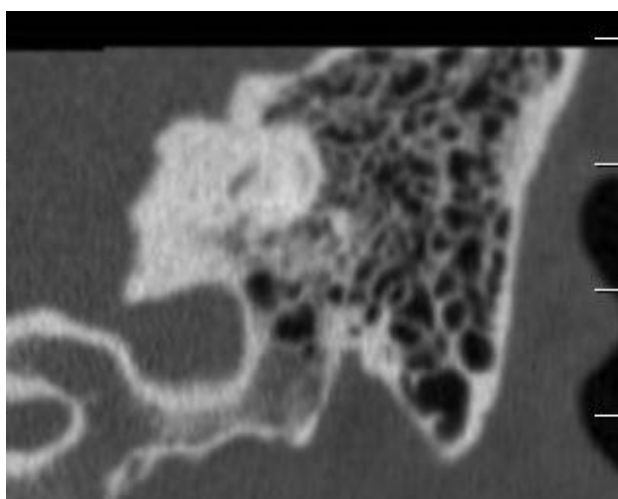


Figure 2. Post operative control CT-scan of patient in Figure 1. Note the straight array entering the cochlea and the fact that there is no mucosal reaction at all in the SMA tunnel (arrows)



**Figure 3.** An other case demonstrating no reaction of the mucosa in the mastoid and middle ear after a cochlear implantation.



**Figure 4-5.** Showing the pre and post operative CT-scans demonstrating no pathology in the fine structure of the mastoid after cochlear implantation.

the chorda tympani. Through a large posterior tympanotomy (intraoperative facial nerve monitoring is mandatory) a cochleostomy must be performed for electrode insertion. This classic technique has been proved to be sufficient in the vast majority of cochlear implantations. Still complications concerning the facial nerve and acute otitis media or acute mastoiditis in the implanted ear in adult or children can occur <sup>[14-15]</sup>. The incidence of otitis media after classic cochlear implantation can vary from 4.6% in non otitis prone children to 22.8% in otitis prone children <sup>[16]</sup>. In a large series of 366 children given implants the classic approach Kempf et al <sup>[17]</sup> observed in 5.6% during a follow-up period of 1 to 8 years otitis media or mastoiditis as complication. These cases have to be treated by myringotomy or re-opening the retroauricular incision with mastoid revision of the implanted side. Usually implanted patients who

developed an otitis media or mastoiditis are treated successfully with oral antibiotics. The incidence of otitis media or mastoiditis leading to the complication requiring explantation of the implant is low.<sup>[18]</sup> In a review paper Roehm & Gantz <sup>[19]</sup> describe that in 14% of the patients with chronic otitis media in which a cochlear implant was placed revision surgery was required following implantation.

In our present study we studied the state of the mastoid cavity by pre- and post-operative ct-scan after 79 suprameatal surgical cochlear implantation. In this series no postoperative skin reaction or severe mastoiditis was documented. In 76 cases the delicate structures of the mastoid cavity were kept intact without any sign of mucosal reaction. Even the suprameatal tunnel showed no signs of postoperative bone or mucosa reaction. In two cases of implantation for deafness due to otosclerosis same swollen mucosa

was observed in the mastoid without any clinical relevance. In one case (a child) signs of otitis media with opacification of the the mastoid and middle ear was observed without destruction of the structures of the mastoid. Treatment in this case with oral antibiotics cured this otitis media without any rest reactions in the mastoid later on. The less invasive suprameatal surgical approach for cochlear implantation showed that mastoid does not react on the surgical drill out of the suprameatal tunnel. Our observations supports the statement of Bhatia et al<sup>[20]</sup> that unnecessary manipulation of the mastoid and large skin flaps may contribute sooner to surgical complications. Kronenberg and Migirov<sup>[21]</sup> demonstrated in a comparison study that nonmastoidectomy approach provides a wide exposure of the middle ear and promontory and thus enables a well-controlled cochleostomy site and safe insertion of the electrode into the cochlea. Mastoidectomy in CI surgery is not indispensable and that it may cause more disadvantages than advantages. Our present study shows that it is possible to safe the structures of the mastoid in cochlear implant surgery. The suprameatal approach can keep the mastoid untouched with all the positive benefits.

### **Conclusions**

We can state that the structures of the mastoid cavity can be kept intact using a mastoid saving suprameatal surgical approach in cochlear implant surgery. In almost all the cases presented we could demonstrate by CT-scan that there was no reaction of the mucosa in the mastoid and middle ear after cochlear implantation. Noninvasive mastoid surgery in cochlear implantation will reduce the possibility of postoperative complications. A mastoidectomy is in our opinion not indispensable for the implantation of a cochlear implant.

### **References**

1. House W.F. Cochlear implants. *Ann.Otol. Rhinol. Laryngol* 1979; 85:1-93.
2. Banfai P.,Kubik S. Hortmann G. Our extra-scalar operating method of cochlear implantation. Experience with 46 cases. *Acta Otolaryngol Suppl* 1984; 41:9-12
3. Kiratzidis T. Veria operation : cochlear implantation without mastoidectomy and posterior tympanotomy. A new surgical technique. *Adv Otorhinolaryngol* 2000; 57:127-130
4. Kronenburg J.,MigirovL.,Dagan T. Suprameatal approach: new surgical approach for cochlear implantation. *J Laryngol Otol* 2001; 115; 283-285
5. Tange R.A. Grolman W. Een mastoidsparende benadering voor het inbrengen van een cochleair implantaat. *Ned Tijdschr. KNO-heelk.* 2004 Vol 10 - 3:143-147.
6. Tange R.A., Grolman W. Mastoid saving surgical approach and our experiences with a new electrode with softip for cochlear implantation.*Indian Soc Otolaryngology* 2004; 2; (1-2): 30-32.
7. Postelmans J.T.F.,Grolman W.,Tange R.A., Stokroos R.J. Comparison of two approaches to the surgical management of cochlear implantation. *Laryngoscope* 2009 in press
8. Gérard J.M., Monnoye V., Deggouj N. Gersdorff M. A Classical retro-auricular incision in cochlear implantation *Mediterr J Otol* 2005;1(3):105-109
9. Black B., Black J., Wallwork B. Early pediatric implantation: Cochlear implant surgery at the crossroads? *Mediterr J Otol* 2005; 1(2): 94-103.
10. Carelsen B.,Grolman W.,Tange R.A. et al Cochlear implant electrode array insertion monitoring with intra-operative 3D rotational X-ray. *Clin. Otolaryngol* 2007; 32 : 46-50.
11. Clark G.M.A. A surgical approach for a cochlear implant : An anatomical study. *J Laryngol Otol* 1975; 89/1 : 9-15.
12. Goycolea M.V.,Papparelle M.M., Muchow D. Mastoidectomy tympanotomy approach for cochlear implantation. *Laryngoscope* 1987; 97: 766-771.
13. Cohen N.L., Hoffman R.A. Complications of cochlear implant surgery in adults and children. *Ann.Otol.Rhinol.Laryngol.* 1991 : 100 :708-711
14. Kempf H.G.,Tempel S.,Johann K., Lenarz Th. Complications in cochlear implant surgery. *Laryngo-Rhino-Otologie* 1999; 78 (10): 529-537.

15. Kempf H.G.,Johann K., Lenarz Th. Complications in pediatric cochlear implant surgery. Eur. Arch. Otorhinolaryngol 1999; 256 : 128-132
16. Luntz M, Khalaila J, Brodsky A, Shpak T. Cochlear implantation in children with otitis media: third stage of a long-term prospective study. Harefuah 2007;146(2):106-110
17. Kempf H.G.,Stover T., Lenarz Th. Mastoiditis and acute otitis media in children with cochlear implants: recommendations for medical management. Ann Otol Rhinol Laryngol Suppl 2000; 185:25-27.
18. Proops DW, Stoddart RL, Donaldson I Medical, surgical and audiological complications of the first 100 adult cochlear implant patients in Birmingham J Laryngol Otol Suppl. 1999;24:14-17.
19. Roehm PC, Gantz BJ. Cochlear implant explantation as a sequela of severe chronic otitis media: case report and review of the literature. Otol Neurotol. 2006; 27(3):332-336.
20. Bhatia K.,Gibbin K.P., Nikolopoulos T.P.,O'Donoghue G.M. Surgical complications and their management in a series of 300 consecutive pediatric cochlear implantations . Otol Neurotol. 2004; 25(5):730-739.
21. Kronenberg J, Migirov L. Is mastoidectomy indispensable in cochlear implant surgery? J Otolaryngol. 2005; 34(1):29-31.

