

CASE REPORT

Eccrine Hidrocystoma of External Ear Canal

Francesco Comacchio, Barbara Pedruzzi, Giulia Tava, Lara Alessandrini, Filippo Marino, Alessandro Martini

*Endoscopic Airways Surgery (Department of Neuroscience), Azienda Ospedaliera di Padova, Padova (Italy) (BP, FT, AM)
Otorhinolaryngology-Otosurgery (Department of Neuroscience), Azienda Ospedaliera di Padova, Padova (Italy) (FC,
Pathologic Anatomy, Azienda Ospedaliera di Padova (Italy) (LA, FM)*

ABSTRACT: Hidrocystomas, eccrine or apocrine, are rare ductal cystic benign lesions of sweat gland. They are mainly found on the head and neck region. These uncommon cystic lesions are extremely rare in external ear. We describe the second case in English literature of an eccrine hidrocystoma inside the external auditory canal and discuss its origin.

Submitted : 12 August 2011

Accepted : 21 February 2012

Introduction

Hidrocystomas, eccrine or apocrine, are rare ductal cystic benign lesions of sweat gland and they are mainly found on the head and neck region [1,2]. These uncommon cystic lesions are extremely rare in external ear. Only three apocrine [3-5] and one eccrine hidrocystomas [6] of external ear canal were reported in literature. We describe the second case in English literature of an eccrine hidrocystoma inside the external auditory canal and discuss its origin.

Robinson was the first to describe eccrine hidrocystoma (EH) in 1893 in women working in a hot and humid environment and presenting with multiple vesicular lesions on the face [7]. EH is usually present as a single lesion, rarely multiple, and characteristically appear as skin-colored to bluish vesiculo-papular lesions. It is most commonly on the periorbital area, but away from the lid margin, and these lesions predominantly occur in middle-aged and elderly women. EH is a benign small cystic lesion that

usually enlarges during the summer and may disappear spontaneously in cooler weather [8]. Apocrine hidrocystoma (AH) is usually larger than EH and affect the same age groups as do EHs and they rarely occur during childhood or adolescence [8]. AH does not become more prominent in hot environments or after exercise. Histopathologically, EH, which is lined by ductal cells, differs from AH by the absence of decapitation secretions, papillary projections into the lumen, PAS-positive granules and myoepithelial cells. Clinically, EH and AH may be confused, but their histological features and immunohistochemical patterns can readily differentiated the two types of lesion, such in our case.

We found a very rare ductal cystic benign lesions of sweat glands (EH) of external auditory canal, that confirm and stress the attention to the double mechanism of secretion of ceruminous glands (apocrine and eccrine) reported in literature [9-14] and justify two different kind of sweat glands lesion in external auditory canal.

Corresponding address:

Barbara Pedruzzi
Department of Endoscopic Airways Surgery Via Giustiniani, 1
35100 Padova (Italy)
Phone: 0039 049 8213105, Fax: 0039 049 8213106
E-mail: chir.eva@sanita.padova.it , barbarendy@hotmail.com

Case Report

A 78-year-old man presented to our attention with history of left auricular fullness and progressive hearing loss, which had been present for several months. Both his past medical and family histories were not remarkable. The physical examination showed a solitary painless swelling, skin-colored, arising from antero-lateral wall of the left external ear canal that narrowed the external auditory canal (Figure 1). The tonal audiometry found a mild mixed hypoacusia.

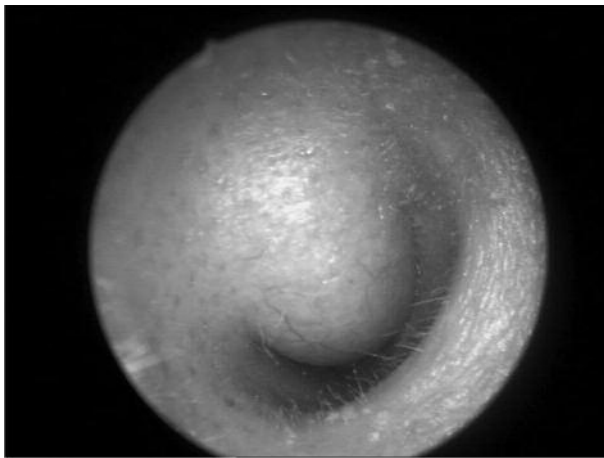


Figure 1. The physical examination showed a solitary painless swelling, skin-colored, arising from antero-lateral wall of the left external ear canal that narrowed the external auditory canal.

A computed tomography (CT) scan of the temporal bone found a well-circumscribed hypodense tissue, with a polypoid soft tissue aspect, located at the antero-superior part of the lateral portion of canal wall, extending from the entrance to the bone-cartilage limit of the auditory canal, with no bone erosion and no middle ear or mastoid involvement. Behind the lesion was present another hypodense tissue, probably due to wax deposit (Figure 2).

The ear lesion was completely resolved with an intra-aural wide local excision under local anesthesia. The lesion was removed without damaging osteocartilaginous canal wall or tympanic membrane. During the dissection, the lesion appears to be a cyst filled with sero-mucous fluid. An initial cholesteatoma of the proximal portion of external ear canal was also removed. The postoperative period was

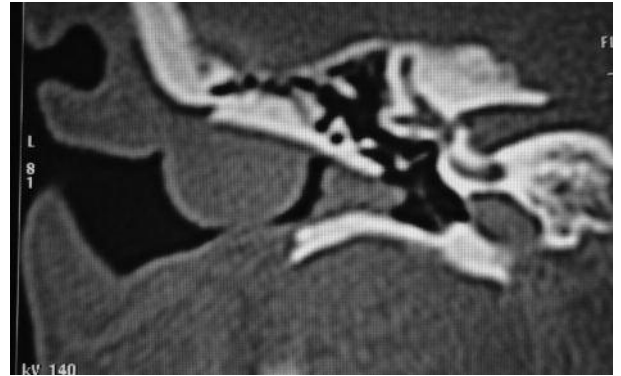


Figure 2. A computed tomography (CT) scan of the temporal bone found a well-circumscribed hypodense tissue, with a polypoid soft tissue aspect, located at the antero-superior part of the lateral portion of canal wall, extending from the entrance to the bone-cartilage limit of the auditory canal, with no bone erosion and no middle ear or mastoid involvement. Behind the lesion was present another hypodense tissue, probably due to wax deposit.

uneventful.

Histopathology examination showed a cystic cavity located in the dermis. The cyst wall present single layer of flattened epithelial cells can be seen, their flattened nuclei extending parallel to the cyst wall. Eccrine secretory tubules and ducts are often located below the cyst and in close approximation to it, and, on serial sections, one may find an eccrine duct leading into the cyst from below. However, no connection can be found between the cyst and the epidermis (Figure 3). The histochemical studies showed negativity for periodic-acid-Schiff (PAS). The definitive diagnosis of Eccrine Hydrocystoma (EH) was established based on these findings.

No recurrence has been noted during the follow-up period (16 months) (Figure 4)

Discussion

Adnexal glands in human skin can be: holocrine, apocrine, and eccrine.

Holocrine glands are exocrine glands where the secretion is formed inside the cytoplasm of the cell and then is released by the rupture of the plasma membrane and destruction of the cell, thus the secretion consists also of the whole cells that have been detached and died^[6] (for example, sebaceous gland, also present in

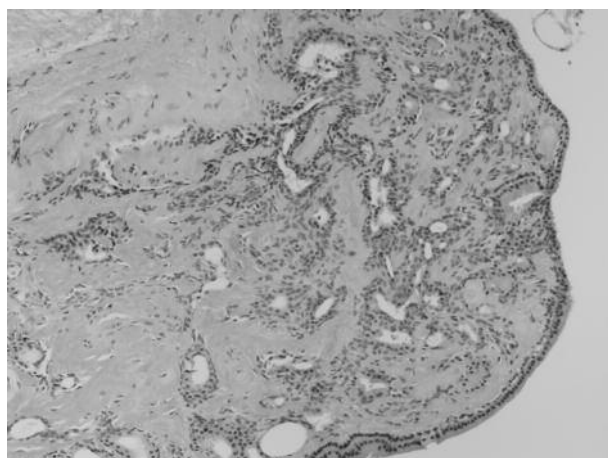


Figure 3. Histopathology examination showed a cystic cavity located in the dermis. The cyst wall present single layer of flattened epithelial cells can be seen, their flattened nuclei extending parallel to the cyst wall. Eccrine secretory tubules and ducts are often located below the cyst and in close approximation to it, and, on serial sections, one may find an eccrine duct leading into the cyst from below. However, no connection can be found between the cyst and the epidermis.

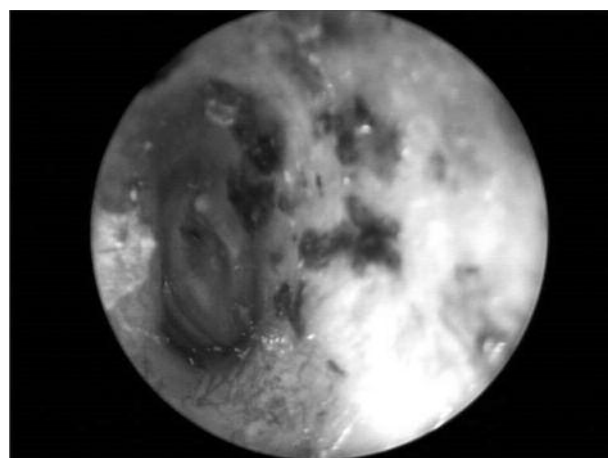


Figure 4. The physical examination showed no recurrence of the lesion after a period of 16 months.

external auditory canal).

Apocrine glands are exocrine glands which mode of secretion is decapitation, a process where the apical portion of the secretory cell cytoplasm pinches off and enters the lumen of the gland. In adult people, they are present only in a few areas of the body, such as axillae, perianal region, areolae, peri-umbilical skin, prepuce, scrotum, mons pubis, and labia minora^[15]. Specialized variants of apocrine glands also exist: the Moll's

glands seen on the eyelids; the cerumen-producing glands of the external auditory canal (ceruminous glands); and the milk-producing glands of the breasts (mammary glands). Apocrine sweat is more viscous and odorless initially, but, as apocrine sweat comes in contact with normal bacterial flora on the surface of the skin, an odor develops.

Eccrine glands are exocrine glands, where the cells lining this type of gland excreted the sweat without changing their size or shape or contents nor did they release any of their cellular material (exocytosis mechanism). The duct opens directly onto the skin surface. These merocrine glands are the most numerous sweat glands of the human body, found in virtually all the body surface^[15]. They are absent in tympanic membrane, vermilion border of the lips, nail beds, nipple, and parts of the genitalia^[15]. The highest density of eccrine glands is seen on the palms of the hands, soles of the feet, and axillae. The primary function of the eccrine unit is thermoregulation. Emotional stressors tend to induce sweating that is confined mainly to the palms and soles.

Obstruction of the sweat gland duct stopped the delivery of sweat on the skin, with a temporary or permanent retention of sweat^[6]. The pressure caused by sweat outflow blockage will determine the dilatation of the duct and the formation of small vesicle or papule at the orifice of duct, and if the obstruction of the outflow of sweat persists, a sweat retention cyst or hidrocystoma will form^[6].

EHs are small, ranging from 1 to 6 mm in diameter, tense thin-walled cysts, and can be single or multiple lesions. EHs are more frequent in white persons, typically adult females^[2], between 30 to 70 years of age^[3]. Solitary lesions are equally present among males and females. Multiple lesions are mainly found in females, and are often associated with inherited disorders. EHs are found mostly on the periorbital and malar regions, but usually do not involve the eyelid margin. EHs are classified in to 2 groups: the Smith and Chernosky type (mostly solitary, but relatively rare^[16,8]) and the Robinson type (multiple small papules, but smaller than solitary lesions^[8]). These lesions can grow in dimensions and

multiply in number during humid or hot weather, and can decrease in winter months ^[6]. Histochemically, solitary EH stain positive for S100 protein, whereas Robinson type is negative. CEA is observed in some lesions, but GCDFP-15 is negative ^[2]. The cysts and epidermis do not communicate. No decapitation secretion or the periodic-acid-Schiff (PAS) positive granules are found ^[2].

AHs can occur usually solitary, with a diameter ranging from 3 to 15 mm, and they are found mostly on the head and neck region and along the eyelid margin, near the inner cantus, but less frequent at periorbital regions. They affect older adult patients, rarely occur during childhood or adolescence. AHs can be single or multiple, although multiple type is rare in the general population. There is no evidence of seasonal variations associated with AH. Histochemically AHs are negative for S100 protein. Decapitation secretion is often present and the apocrine cells often contain PAS-positive granules, which are probably lipofuscin granules ^[2]. AHs also have papillary projections, that are vascular connective tissue covered by the secretory epithelium. However, it may be difficult to differentiate EH from AH even with conducting immunohistochemical study^[8].

Histopathologic examination of our lesion showed a cystic cavity located in the dermis, with a single layer of flattened epithelial cells in the wall, and histochemical studies were PAS-negative, so it was an eccrine hidrocystoma.

Hidrocystoma, eccrine or apocrine, is typically asymptomatic and will follow a gradual course until certain size is reached. Clinically they can be confused ^[6]. Moreover, they should be differentiated from other skin disorders such as epidermal inclusion cysts, comedone, mucoid cysts, hemangioma, lymphangioma, basal cell carcinoma, and malignant melanoma ^[1,17].

The therapeutic options can be medical and/or surgical modalities. Multiple-type lesions have been successfully treated with topical 1% atropine sulfate or scopolamine creams ^[1,16,18], but also with botulinum toxin type A ^[8]. The systemic administration of

atropine sulphate and pilocarpine hydrochloride has been shown to cause the cysts to disappear and reappear ^[6], but anticholinergic side effects could cause patients to discontinue the treatment ^[1,18]. Simple needle puncture is the most common approach, but has not been shown to produce lasting effects ^[8]. Incision and drainage, without cauterization and electrodissection of the cystic wall, can lead to recurrence. The treatment with pulsed dye laser showed favorable results in multiple EH ^[19]. Surgical excision can successfully treat single lesion, but also can lead to scars with anaesthetic results in cosmetic location ^[1].

The external auditory canal is about 2.5 cm in length measured from the bottom of the concha. It forms an S-shaped curve, is built partly by cartilage and membrane, and partly by bone, and is covered by skin (keratinising stratified squamous epithelium). The lateral one-third of canal is cartilaginous, and firmly attached to the circumference of the auditory process of the temporal bone. The cartilage is deficient at the upper and back part of the meatus, its place being supplied by fibrous membrane. The osseous portion occupies the inner two-third of canal and is narrower than the cartilaginous portion. The skin lining the external auditory meatus is very thin, measuring about 30-50 microns in thickness. It adheres closely to the cartilaginous and osseous portions of the tube, and covers the outer surface of the tympanic membrane. The epithelial lining the ear has both apocrine and sebaceous glands that are responsible for producing cerumen ^[20]. Hair follicles are numerous in the outer one-third of the external auditory canal, but are less numerous in the inner two-thirds. Sebaceous glands are plentiful and open into the follicles of fine vellus hair ^[3]. In the thick subcutaneous tissue of the cartilaginous part of the external auditory meatus are present numerous ceruminous glands, that are (like ciliary glands of Moll in the eyelids margin) modified sweat glands ^[15].

Ioannidis et al. ^[3] reported that eccrine sweat glands are not present in the auditory canal, abundantly supplied with apocrine modified (ceruminous) glands.

Gray's Anatomy Textbook ^[15] quoted instead that

eccrine glands are in almost all of the body's skin, with the exception, in the ear, only of the tympanic membrane.

Main and Lim^[9] studied human auditory canal skin by light, transmission electron and scanning electron microscopy and found that the apocrine as well as the eccrine mode of secretion were noted in the modified apocrine gland. This finding was partly in agreement with contemporaneous reports based on light microscopy with suggested only an apocrine mode and data based on transmission electron microscopy which showed only the eccrine mode. Kurosumi and Kawabata^[10] observed ceruminous gland by transmission and scanning electron microscopy and report two types of mechanism of secretion of this glands: exocytosis (typical eccrine secretion) and apocrine secretory mechanism. Also Shugyo et al.^[12] observed the same two types of secretion modalities in ceruminous gland, and also Testa-Riva and Puxeddu^[11] found two types of secretory mechanism (eccrine and apocrine) in the same secretory cells of the human ceruminous glands. Quite recently, Stoeckelhuber et al.^[21] studied ultrastructure and histochemical analysis of ceruminous gland and concluded that the eccrine secretion mode in the ceruminous gland is at least as important as the apocrine secretion mode. Mansour et al.^[13] reported furthermore that ceruminous glands should be considered as apo-eccrine glands, with both eccrine and apocrine modes of secretion, and not only as purely apocrine modified glands. Lassaletta et al.^[14] concluded that to explain the existence of pure eccrine lesions in external auditory canal, ceruminous glands have to be considered apo-eccrine glands.

According to Mansour et al.^[13] and to Lassaletta et al.^[14] we believe that ceruminous glands are apo-eccrine, so we can find in external auditory canal the two type of ceruminous glands lesions, and so the two types of hidrocystomas.

Conclusion

Hidrocystomas, eccrine or apocrine, of external ear canal are uncommon. Three apocrine^[3,4,5] and one eccrine hidrocystomas^[6] of external ear canal were reported in literature. We have reported a case of an

eccrine hidrocystoma inside the external auditory canal causing auricular fullness with progressive hearing loss and completely resolved with an intra-aural wide local excision under local anesthesia, the second case described in English literature. The distinction between eccrine and apocrine lesions can be difficult on clinical examination, and histological findings, but histochemical exams is helpful as in our case. We found a very rare ductal cystic benign lesions of sweat glands (EH) of external auditory canal, that confirm the double modalities of secretion of ceruminous glands (apocrine and eccrine). Most sweat neoplasms are uncommonly encountered in routine practice^[3], but should be consider also in external auditory lesion. Often clinically confused with basal cell carcinomas, could comport a wide overestimate excision for a benign lesion^[6].

Consent

Written informed consent was obtained from the patient for publication of this case report and accompanying images. All diagnostic and therapeutic procedures were performed with patient's consent and respecting ethical principles of our institutional and national committee.

Competing Interests

The authors declare that they have no competing interests.

References

1. Khashayar Sarabi, and Amor Khachemoune. Hidrocystomas - A Brief Review. *MedGenMed*. 2006; 8: 57. Published online 2006 September 5.
2. Fletcher CDM, editors. Tumors of the skin, 1403-1404. In: *Diagnostic histopathology of tumors*. Churchill Livingstone 2000. 2nd edition. Vol 2.
3. Ioannidis DG, Drivas EI, Papadakis CE, Feritsian A, Bizakis JG, Skoulakis CE. Hidrocystoma of the external auditory canal: a case report. *Cases J*. 2009; 2:79.
4. Shishegar M, Ashraf MJ, Azarpira N. Apocrine hidrocystoma in the external auditory canal. *Iranian Red Cresc Med J* 2007; 9(1): 42-44, cited by Ioannidis DG, Drivas EI, Papadakis CE, Feritsian A, Bizakis JG, Skoulakis CE. Hidrocystoma of the external auditory

- canal: a case report. *Cases J.* 2009; 2:79.
5. Anderson PJ. Apocrine hydrocystadenoma of the ear. *Otolaryngol Head Neck Surg.* 2005; 133:981-2.
 6. Hawke M, van Nostrand P. Eccrine hidrocystoma of the external ear canal: a case report. *J Otolaryngol.* 1987; 16:43-5.
 7. Robinson AR. Hidrocystoma. *J Cutan Genitourin Dis* 1893; 11:293-303. Quoted from: Sperling LC, Saks EL. Eccrine hidrocystomas. *J Am Acad Dermatol* 1992; 26:780-2.
 8. Jae-Hui Nam, Ga-Young Lee, Won-Serk Kim, Kea Jeung Kim. Eccrine Hidrocystoma in a Child: An Atypical Presentation. *Ann Dermatol* 2010; 22:69-72. Epub 2010 Feb 28.
 9. Main T, Lim D. The human external auditory canal, secretory system--an ultrastructural study. *Laryngoscope.* 1976; 86:1164-76.
 10. Kurosumi K, Kawabata I. Transmission and scanning electron microscopy of the human ceruminous apocrine gland. I. Secretory glandular cells. *Arch Histol Jpn.* 1976; 39:207-29.
 11. Testa-Riva F, Puxeddu P. Secretory mechanisms of human ceruminous glands: a transmission and scanning electron microscopic study. *Anat Rec.* 1980; 196:363-72.
 12. Shugyo Y, Sudo N, Kanai K, Yamashita T, Kumazawa T, Kanamura S. Morphological differences between secretory cells of wet and dry types of human ceruminous glands. *Am J Anat.* 1988; 181:377-84.
 13. Mansour P, George MK, Pahor AL. Ceruminous gland tumours: a reappraisal. *J Laryngol Otol.* 1992; 106:727-32.
 14. Lassaletta L, Patrón M, Olóriz J, Pérez R, Gavilán J. Avoiding misdiagnosis in ceruminous gland tumours. *Auris Nasus Larynx.* 2003; 30:287-90.
 15. Williams PL, Warwick R, Dyson M, Bannister LH, editors. *Sudorific (sweat) glands*, p. 93-94. In: *Gray's Anatomy.* Churchill Livingstone 1989. 37th Edition.
 16. Alfadley A, Al Aboud K, Tulba A, Mourad MM. Multiple eccrine hidrocystomas of the face. *Int J Dermatol.* 2001; 40:125-9.
 17. Singh AD, McCloskey L, Parsons MA, Slater DN. Eccrine hidrocystoma of the eyelid. *Eye (Lond).* 2005; 19:77-9.
 18. Shimokawa M, Matsushita S, Kanekura T. Successful treatment of multiple eccrine hidrocystoma with topical atropine sulfate ointment. *J Dermatol.* 2009; 36:114-5.
 19. Tanzi E, Alster TS. Pulsed dye laser treatment of multiple eccrine hidrocystomas: a novel approach. *Dermatol Surg* 2001; 27: 898-900.
 20. Hughes GB, Pensak ML, editors. *Disease of the external auditory canal*, p. 211. In: *Clinical Otolaryngology.* Thieme Publishers. 3rd Edition. 2007.
 21. Stoeckelhuber M, Matthias C, Andratschke M, Stoeckelhuber BM, Koehler C, Herzmann S, et al. Human ceruminous gland: ultrastructure and histochemical analysis of antimicrobial and cytoskeletal components. *Anat Rec A Discov Mol Cell Evol Biol.* 2006; 288:877-84.