

ORIGINAL ARTICLE

The Effects of CUSA Application to The Neural Tissue Resembling Tumor Removal: An Experimental Study

Aslihan Koseoglu, Ahmet Dagtekin, Ozlen Bagdatoglu, Ulku Comelekoglu, Necat Yilmaz, Oykut Dagtekin, Fatma Sogut, Mutlu Alimli, Emel Avci, Celal Bagdatoglu, Derya Talas

Mersin University Medical Faculty Department Of Neurosurgery, Mersin (AK, AD, MA, EA, CB)

Mersin University Medical Faculty Department Of Biochemistry, Mersin (OB)

Mersin University Medical Faculty Department Of Biophysic, Mersin (UC, FS)

Mersin University Medical Faculty Department Of Histology And Embryology, Mersin (NY, OD)

Mersin University Medical Faculty Department Of Otorhinolaryngology, Mersin (DT)

Background: The technology is fundamental for the overall success of the surgery regarding the highly complex areas. Although there are many studies on this topic, there is still a great necessity of performing further investigations to reveal the probable effects of CUSA (Cavitation Ultrasound Surgical Aspirator) to the surrounding tissue.

Objective: This study aims to evaluate the electrophysiological, electron microscopic and biochemical parameters of the peripheral nerve tissue after CUSA application.

Materials and Methods: After the exposure of the right sciatic nerve and placement of bovine liver, CUSA application is performed. Then, compound muscle action potential (CMAP) assessment is done, blood sample is taken for biochemical analysis and the nerve is dissected for electron microscopy.

Results: This study revealed that CMAP is deteriorated acutely by CUSA application directly proportional to the intensity. Biochemical parameters including the serum nitric oxide (NO) and malondialdehyde (MDA) are worth evaluating for the process of nerve tissue damage and the progression of healing. Electron microscopic evaluation showed that the nerve degeneration still continued at the end of the third week.

Conclusion: The deleterious effects of CUSA to the nerve tissue should be taken into consideration even there is a tissue between the nerve and the applicator and its use in the lowest intensity strong enough for tumor removal would be beneficial to overcome any deleterious effects. The continuation of the nerve degeneration in electron microscopy indicates a longer duration investigation and the tissue NO, MDA may contribute to the related knowledge in experimental basis.

Key Words: Electrophysiology, neural tissue, posterior fossa, skull base, ultrasonic aspirator.

Running Title: CUSA effect to neural tissue

Submitted : 07 October 2010

Revised: 24 March 2011

Accepted : 18 April 2011

Introduction

The success of approaching skull base lesions and performing transbasal craniotomy for certain pathologies that are better to access through the skull base rather than performing the convexity lesions is tremendously affected by the introduction and advancements regarding radiological technology, microsurgical optical systems and neurophysiological monitoring. Surgical drill systems, mono-bipolar cautery, ultrasonic aspirators and laser systems are also listed as operating room requirements in many neurotology and neurosurgery departments ^[1].

CUSA is an instrument that was first developed for ophthalmological surgery and is reported to gain wide acceptance from many other medical specialties including neurosurgery, general surgery, gynecology, urology and neurotology after several improvements ^[2,3].

Regarding the neurosurgical procedures, surgical resection of the lesions within or intimate to brain tissue may lead to increased morbidity due to damage of the surrounding brain tissue. Although CUSA has been pointed out as an instrument capable of selective removal of the lesion without affecting the

Corresponding address:

Ahmet Dagtekin
Ihsaniye Mah. 4935 Sok. No: 3 33079 Mersin / Turkey
Phone: +90 324 337 43 00/1118 Fax: +90 324 337 43 05
E-mail: dagtekin69@yahoo.com

Copyright 2005 © The Mediterranean Society of Otolaryngology and Audiology

surrounding tissue, serving a clear operating field ^[4], decreasing the hemorrhage ^[5] for various tissues; there is still debate on the deleterious effects on the neural tissue.

One of the parameters that has to be focused on is the duration of surgery for the overall morbidity and mortality. Cerebellopontine angle (CPA) is of ultimate importance due to its anatomical complexity and highly vulnerable and important neurovascular structures in and around. The need to overcome any unnecessary time delays for additional morbidity/mortality without underemphasizing the cautious and neat surgery for the prevention of any functional losses may be succeeded by some technological aspects. CUSA is an instrument offering the features of irrigation, aspiration, cutting and coagulation together at the tip of its handpiece. The collection of all above functions in a single hand-held device may be a great advantage on the duration and ease of the surgery while providing a cleaner surgical field. The comparison of CUSA with the routine surgical instruments regarding compression and hemorrhage should equally be evaluated with the belief regarding the safety of CUSA to the vessels and nerves ^[3,5]. The sparing of the nerves and vessel walls is explained by their strong intracellular bands ^[6].

Although CUSA is widely used in various surgeries, there is still lack of consensus on the probable deleterious effects on the neural tissue. It was proposed as an instrument increasing safety, reducing operating time, improving quality and facilitating selective surgery ^[2]. No known contraindications were reported in the past, while only some limitations were listed including personal and financial aspects. On the other hand, more recent studies pointed out nerve injury in relation to the intensity and the duration of application ^[7,8].

The present study is performed to evaluate the effects of CUSA to the neural tissue in terms of histopathological, electron microscopic, electrophysiological and biochemical aspects for a comprehensive and complementary contribution to the related literature.

Materials and Methods

Animals and Surgical Technique

The experimental protocol was approved by the Animal Care and Use Committee of the University of Mersin (02.05.2008/12, Mersin, Turkey). The rats had free access to standard laboratory diet and water, and were maintained according to the recommendations of the National Institute of Health's guidelines for the care and use of laboratory animals.

Male albino rats (250–275 g) were used in this series of experiments. Rats were divided into 12 groups according to the intensity and the duration of CUSA application (SONOCA 400, Germany). The groups are shown in table 1.

Seven rats were randomly allocated to each group. The rats were anesthetized with ketamine-HCl (50 mg/kg) and xylazine (5 mg/kg). The right sciatic nerve was exposed at the right gluteal region without any damage to the muscles. After the total exposure of the sciatic nerve, initial electrophysiological assessment was performed and this data was accepted as control. Then, a piece of bovine liver that is cut in 1x1x1 cm. dimensions was placed carefully on the nerve. The CUSA application is performed to the liver located on the nerve without direct exposure to the nerve. The liver tissue, that resembles the tumor, is quickly changed when the tissue is thinned by the effect of CUSA. Therefore, the liver is replaced, whenever needed, by the 1 cm thick another liver tissue to avoid direct CUSA effect to the sciatic nerve.

Table 1. The data of the groups regarding intensity, duration of application and evaluation time.

	1 st day		7 th day		21 th day	
	5 min	10 min	5 min	10 min	5 min	10 min
Low intensity (power: 20% of the max. exposure)	Group I (GI)	Group III (GIII)	Group V (GV)	Group VII (GVII)	Group IX (GIX)	Group XI (GXI)
High intensity (power: 50% of the max. exposure)	Group II (GII)	Group IV (GIV)	Group VI (GVI)	Group VIII (GVIII)	Group X (GX)	Group XII (GXII)

Electrophysiological assessment is performed immediately after the application to all the groups. Two sutures were performed to the neighborhood muscle to mark the level of the nerve that CUSA was applied. The incision was closed. Then, the EMG evaluations are performed at the end of the first (GI, GII, GIII, GIV), seventh (GV, GVI, GVII, GVIII) and the twenty-first (GIX, GX, GXI, GXII) days in anesthasized rats. After CMAP evaluation, the marked levels of the sciatic nerve was harvested. The blood sample was taken. The histopathological and electrophysiological assessment methods are explained in detail in the related sections.

Electrophysiological Assessment

Data were collected by means of a BIOPAC MP 100 acquisition system (Santa Barbara, USA). Bipolar surface electrodes (Medelec small bipolar nerve electrodes, 6894T, Oxford, UK) were used for recordings from the gastrocnemius muscle. The ground electrode was placed on the thigh on the side of stimulation. The sciatic nerve was stimulated by bipolar electrode. The supramaximal stimulus consisted of single square pulse (intensity 0.5 V, duration 0.2 ms). Compound muscle action potential (CMAP) records were raised on the amplifiers and then transferred to the computer translating to the numerical signals by 16 bit A/D converter for off line analysis. The sampling rate was chosen as 20 000 sample/s. BIOPAC Acknowledge Analysis software (ACK 100W) was used to measure CMAP parameters, such as the amplitude and latency. Normal amplitudes and latencies of the control records are compared with the CUSA applied groups and evaluated using a scale bar (Figure 1).

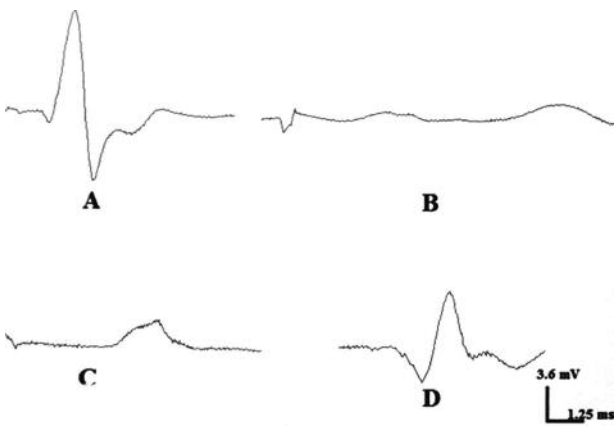


Figure 1. The amplitude and latency of: **A.** Control group, **B.** First day of high intensity 10 minutes group, **C.** Seventh day of high intensity 10 minutes group, **D.** Twenty-first day of high intensity 10 minutes group.

The Electron Microscopic Assessment

For transmission electron microscopic evaluation, the samples were fixed with 2.5% glutaraldehyde, postfixed with 1% osmium tetroxide, dehydrated in graded alcohol series, cleared with propylene oxide and embedded in epon. Thin sections (50-70 nm) were cut by a microtome (Leica UCT-125) and contrasted with uranyl acetate and lead citrate. Sections were examined and photographed by an electron microscope (JEOL JEM-1011).

Biochemical Assessment

Nitrite-nitrate (NN) assay

The final products of NO in vivo are nitrite (NO_2^-) and nitrate (NO_3^-). The relative proportion of NO_2^- and NO_3^- is variable and cannot be predicted with certainty. Thus, the best index of total NO production is the sum of both NO_2^- and NO_3^- . The oxidized end-products of NO (NO_2^- and NO_3^-) were measured in serum samples by the following assay. Measurements of NO_2^- and NO_3^- were made using a procedure based on the Griess reaction^[9]. The samples were obtained via indwelling catheters and immediately centrifuged at 4000 r.p.m. for 10 minute. The serum samples were ultrafiltrated and used in the test. Nitrates were quantitatively converted to nitrites for analysis. Enzymatic reduction of nitrate to nitrite was carried out using enzyme cofactors in the presence of nitrate reductase. Enzyme and cofactors were added to each serum samples and standards. After a one hour incubation period at room temperature Griess reagent was added and all these mixtures were incubated for 10 min. at room temperature in dimmed light. Then the absorbance of the samples and standards were measured at 540 nm using a plate reader. In the measurement of total NO products only the nitrate standard was required for standard curve preparation (Nitrate/Nitrite Colorimetric Assay Kit, 780001, Cayman Chemical Company, Ann Arbor, MI, USA). Total nitrite-nitrate levels were expressed as μM of serum.

Lipid Peroxide Assay

MDA levels, an index of lipid peroxidation, were determined by TBA reaction. The MDA levels in serum were determined by thiobarbituric acid (TBA) reaction according to Yagi^[10]. The principle of the method depends on the colorimetric measurement of

the intensity of the pink color produced by the interaction of the barbituric acid with MDA. The colored reaction 1,1,3,3 tetraoxopropane was used as the primary standard. MDA levels were expressed as nmol/ml of serum.

Statistical Analysis

SPSS 11.05 software was used for statistical analysis. The data were analyzed after normal distributions had been confirmed by the Kolmogorov-Smirnov test. The

data were expressed as mean ± standart deviation (SD). The comparisons for data were made by analysis of univariate and the Tukey posthoc test. The results were considered statistically significant when $p < 0.05$.

Results

Electrophysiological evaluation

The assessment is performed through the measurement of mean amplitudes and latencies of the rat sciatic nerves. The data is shown in table 2 and figure 2-3.

Table 2. The data of the mean amplitudes and latencies of all groups.

Day	Parameters	Control	Low		High	
			5 min	10 min	5 min	10 min
1	Amplitude (mV)	8.75±1.45	5.81±0.86*	3.31±1.05*	2.38±1.99*	0.82±0.65*
	Latency (ms)	0.42±0.24	2.08±0.81*	3.52±1.29*	5.73±1.16*	5.10±2.15*
7	Amplitude (mV)	8.19±1.16	1.34±0.88*	2.21±0.73*	2.97±1.72*	2.50±1.88*
	Latency (ms)	0.45±0.21	5.65±1.35*	5.75±2.82*	4.38±1.11*	2.97±1.01*
21	Amplitude (mV)	7.37±2.35	4.63±2.08*	5.17±1.10*	6.46±2.75*	6.09±3.06*
	Latency (ms)	0.35±0.09	4.04±2.57*	3.55±1.45*	2.49±0.60*	1.79±0.84*

*significantly different from control at $P < 0.05$

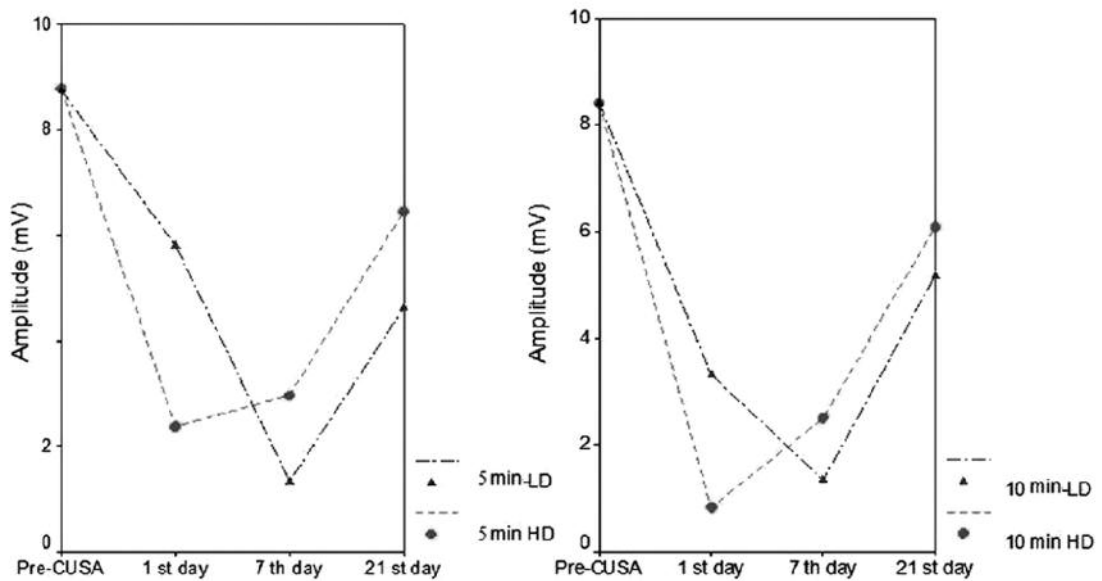


Figure 2. The data regarding the amplitudes are compared.

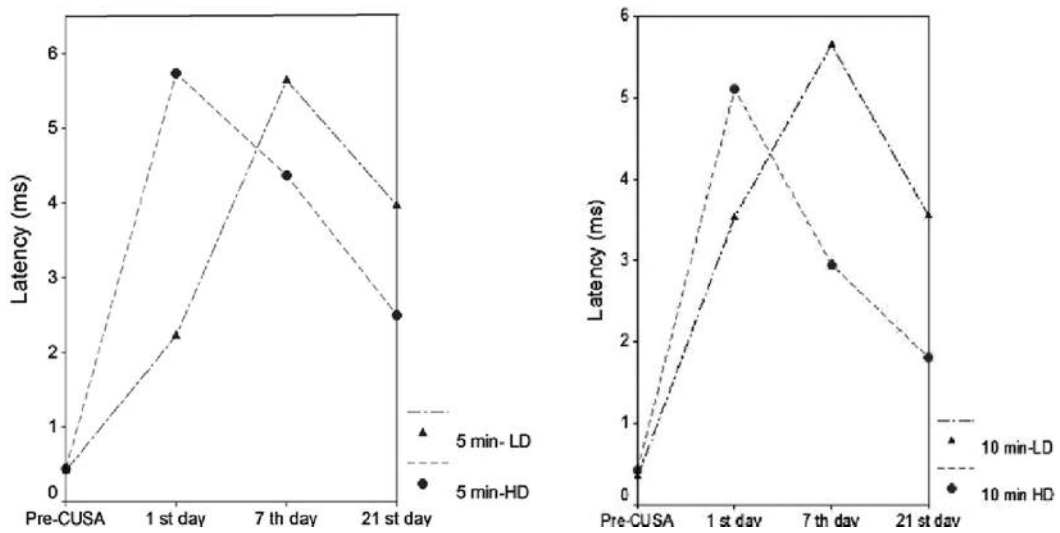


Figure 3. The data regarding the latencies are compared.

CMAP findings regarding both for the amplitude and the latencies, high intensity groups showed the worst scores at the end of the first day of application, while worst findings for low intensity groups were recognised at the end of the seventh day. After the mentioned deepest points shown by the graphics, the CMAP values tend to become better afterwards. However, neither the latencies, nor the amplitudes reach the pre-CUSA values.

The electron microscopical evaluation

This study demonstrated that the intensity of CUSA application rather than the duration was worthy on the degeneration of the neural tissue (Figure 4A-B).

The electron microscopic evaluation revealed normal histology in the first day with the exception of mild disintegration in the high intensity with long duration (10 minutes) application group (Figure 5A-B).

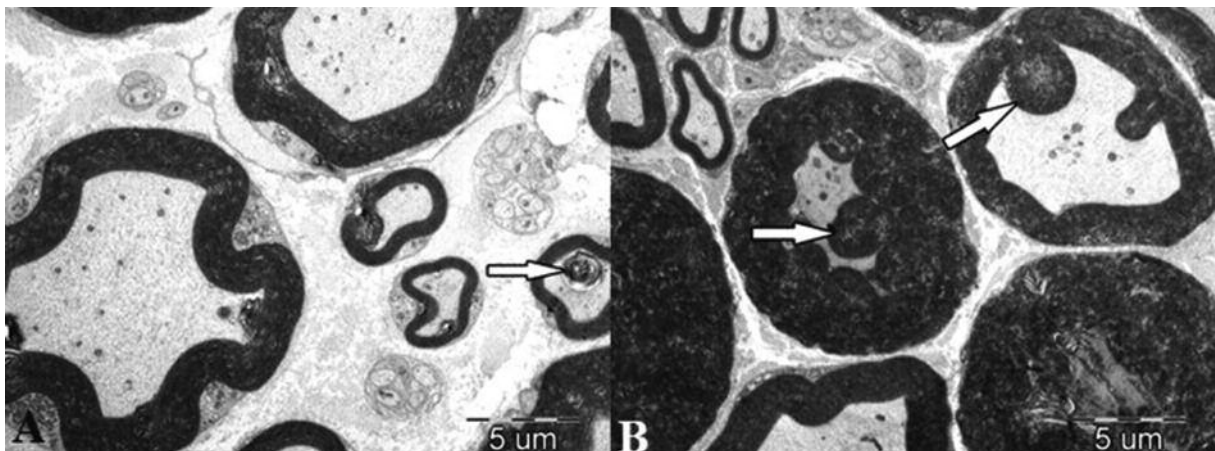


Figure 4. The myelin disintegration and delamination are severe in and heavy degenerative changes are seen including total axonal loss indicating the importance of CUSA intensity. **A:** low intensity, 10 min., 7. day; normally appearing myelin sheaths, ovoid bodies (arrow) (X7500); **B:** high intensity, 10 min., 7. day; heavily degenerated nerve fibers, ovoid bodies (arrow) (X3000).

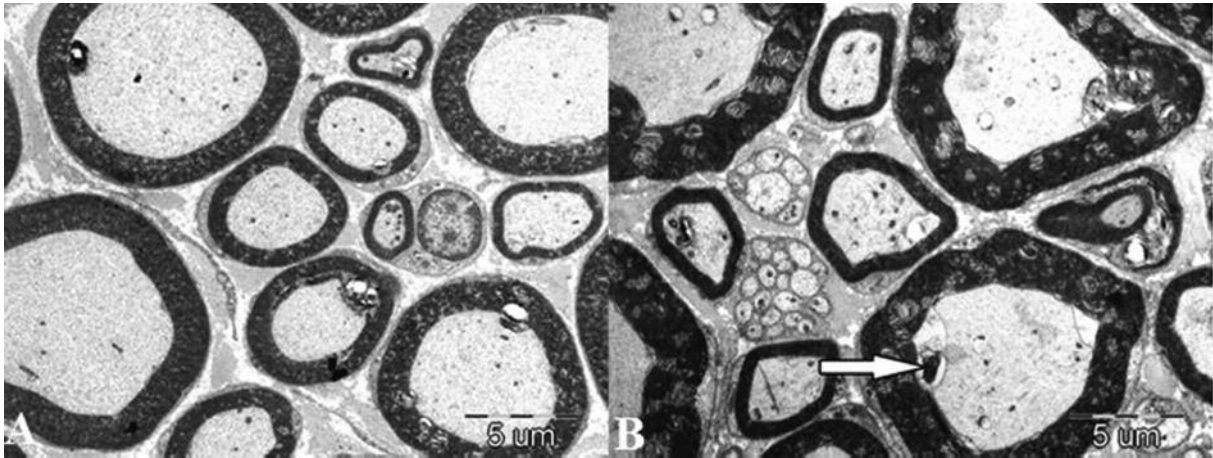


Figure 5. Only the 10 minutes duration and high intensity group revealed mild changes compared to the other groups in the first day. **A:** low intensity, 10 min., 1. day; myelin sheaths and axoplasm with normal appearance (X4000); **B:** high intensity, 10 min., 1. day; ovoid body in axoplasm (arrow), slight delamination of myelin sheath (X7500).

On the other hand, degeneration had been recognized in all the groups on seventh day and this finding persisted in the 21. day of evaluation. Low intensity

groups were relatively better in terms of degeneration (Figure 6A-B-C-D).

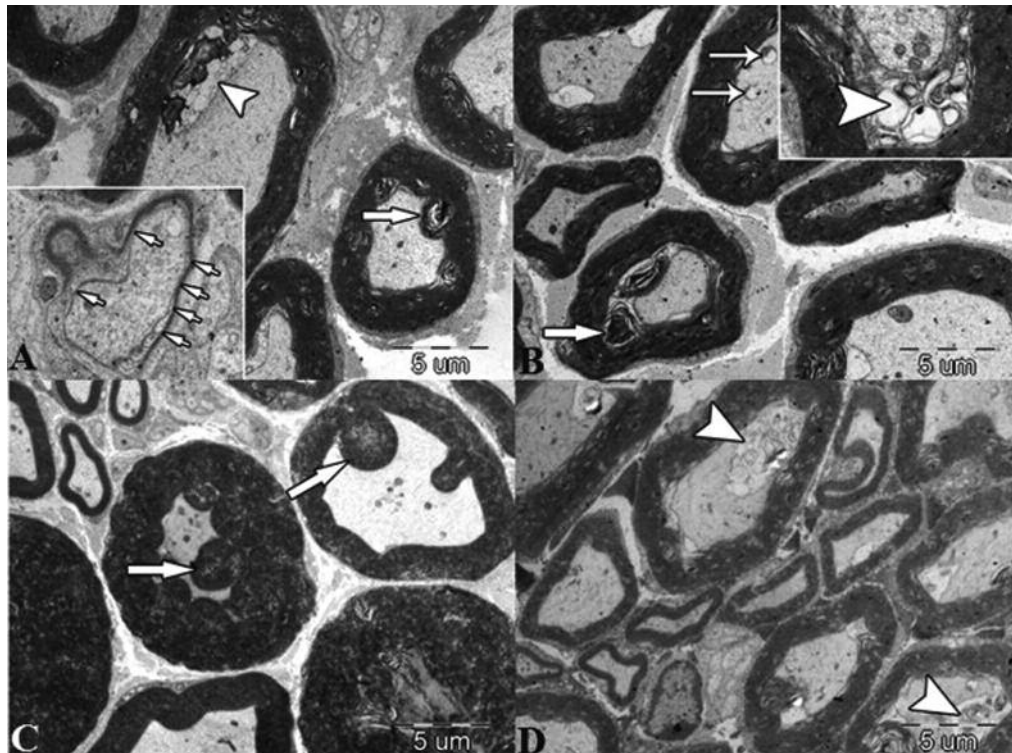


Figure 6. The degenerative changes are still ongoing in the 21. day. **A:** low intensity, 5 min., 7. day; ovoid bodies (arrows), multivesicular bodies (arrowhead) and delamination of myelin sheaths (X5000). Inset: regeneration of myelin sheaths (small arrow) (X15000); **B:** low intensity, 5 min., 21. day; delaminated myelin sheaths, ovoid bodies (arrow) and degenerated mitochondria (thin arrow) (X5000). Inset: multivesicular body (arrowhead) (X20000); **C:** high intensity, 10 min., 7. day; heavily degenerated nerve fibers, ovoid bodies (arrow) (X3000); **D:** high intensity, 10 min., 21. day; thickened and delaminated myelin sheaths, multivesicular bodies in some axoplasm (arrowhead) (X5000).

Biochemical evaluation

Serum NO and MDA levels are evaluated to find out the effect of CUSA to the neural tissue in the three

weeks duration emphasizing the change in the mean values (Figure 7A-B, 8A-B).

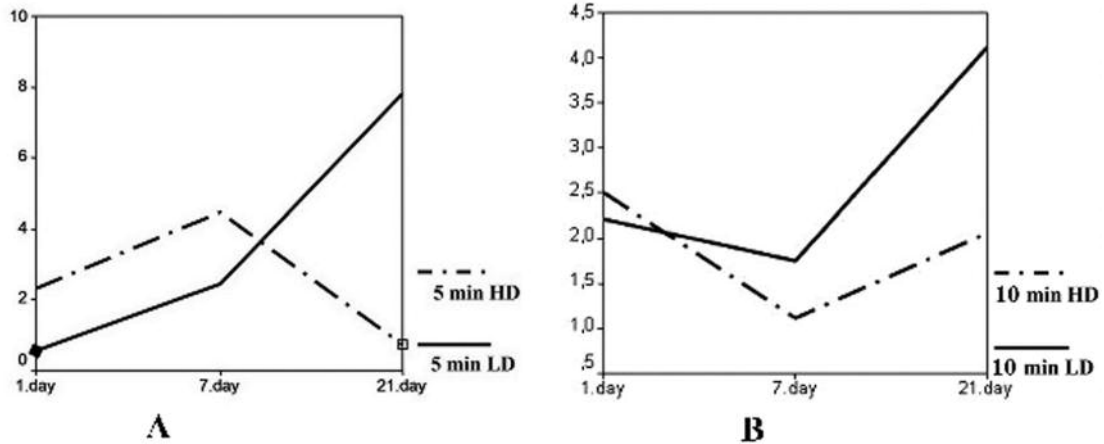


Figure 7. The mean values of NO is shown for 5 minutes (**A**) and 10 minutes (**B**) CUSA applications.

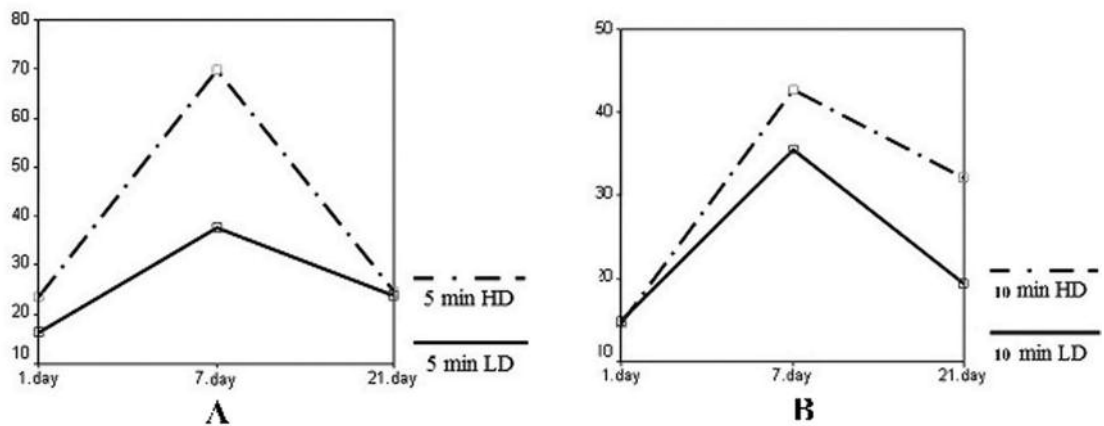


Figure 8. The mean values of MDA is shown for 5 minutes (**A**) and 10 minutes (**B**) CUSA applications.

Discussion

The present investigation of CUSA revealed neural damage directly proportional to the intensity and duration of the application despite the presence of a tissue placed between the tip of the handpiece and the peripheral nerve. The reason for the placement of hepatic tissue is thought to resemble the tumor debulking when there is some tumor tissue between the tip of the probe and the cranial nerve in CPA.

Although several investigations were performed on the effects of CUSA to the neural tissue, one particular

conclusion had not been established. Young and coworkers reported that the adverse effects were not found on the sciatic nerve after CUSA application unless the tip is at least 1 mm. distant from the nerve. However, touching the nerve briefly resulted in abolishment of the action potential. This study was performed to evaluate just the acute effects of the procedure and lacked the long term electrophysiological results [4]. However, Foley and coworkers reported that the neural function, in terms of CMAP values, remained absent even 28 days after treatment for the high intensity exposed group [11].

Another study was performed on the evaluation of functional recovery of the rat sciatic nerves after direct contact of the CUSA device. The poorest recovery was reported from the group of animals exposed to the highest amplitude and exposure. This study had been designed on subjective functional measurements rather than objective electrophysiological evaluation [8]. Abounader and coworkers showed that the ultrasonic effect with an intensity of 10% and a duration of 20 seconds did not alter the nerve, while exposure beyond these values caused neural damage proved by objective means including action potential recording, microphotography and histology [12].

Ultrasonic energy induced multiple nerve damage was reported after acoustic tumor removal and was attributed to the transmission via the petrous bone. The surgeons of this procedure suggested that the direct contact of the probe to the surrounding bone should be avoided [13].

Histopathological evaluation of the neural tissue exposed to the CUSA application would be a very important complementary assessment to the electrophysiological results of the investigations. It would be beneficial to discuss our results in light of the recent studies.

Early studies gave some light microscopic evaluation reported as edema and disrupted fibers for those exposed to 20% power levels [4]. Howard and coworkers reported disrupted neural architecture with histiocytes and mast cell infiltration which was thought to be consistent with remote neural injury and myelin breakdown [8]. Histologic evaluation of CUSA applied to the cortex of the dogs revealed that the damage was directly proportional with the percentage of the maximal power showing mild hemorrhage at 30 % and cortical disruption at the 40 % of the maximal exposure [7].

In accordance with the above mentioned studies, we also recognised that the intensity of CUSA application was indicative. The electron microscopic evaluation of only the high intensity with long duration (10 minutes) application group revealed mild disintegration. On the other hand, short duration or low intensity groups' electron microscopic assessment was in normal range at the end of the first day. Degeneration had been recognized in all the groups on seventh day and this finding persisted in the 21. day of evaluation. Low intensity groups were relatively better in terms of degeneration. When CMAP findings are assessed, the

worst scores were found at the end of the first day of application for the high intensities and seventh day for the low intensities regarding both for the amplitude and the latencies (Figure 2-3). After the mentioned deepest points shown by the graphics, the CMAP values tend to become better afterwards. However, neither the latencies, nor the amplitudes reach the pre-CUSA values. The comparison of the mean amplitudes and latencies for the same intensities with different duration showed difference in values although failed to reach statistical significance. This data may implicate that the power of the CUSA application should be carefully set in order to overcome any neural damage accepting that the time of surgery may be longer. The observation during the experiment also supported the above mentioned data. In contrast to the fact that the high intensity damaged the liver tissue even in 5 minutes leading to the necessity for changing the tissue immediately, low intensity did not even necessitate tissue replacement in 10 minutes.

The present study is tried to be based on the data of electrophysiology, electron microscopy and the biochemical values and the relationship among these parameters.

Neural function of the sciatic nerve is evaluated in terms of amplitude and the latency for the experimental groups and the data is shown in Table 1. The overall assessment revealed that both the mean latencies and the mean amplitudes of the groups showed deterioration after the application of CUSA when compared to the values measured before the CUSA effect ($p < 0.05$). Although it is not statistically significant, these values tend to reach to the control values in the 7th and the 21th day of the experiment with the exception of low dose groups in the seventh day.

The extrinsic, circumneural blood supply of the nerves distributes to the intrinsic vascular framework that is situated in the perineural compartment. Venous stasis and stagnation of capillary flow due to the pressure elevations of any reason may lead to edema and further intraneural pressure leading to acidosis and anoxia [14].

NO is a substance that has complex properties affecting various metabolic cascades. NO plays an important role in the host defense against wound infections due to its toxic effects to microbes and parasites [15], regulates collagen synthesis for the establishment of mechanical wound strength [16], acts as

a modulator in all phases of healing process including the inflammatory, proliferative and remodelling stages [17-19]. NO acts as an anti-oxidant during cellular lipid peroxidation [20] and as a prooxidant in the reaction with superoxide to form peroxynitrite through its protective function in oxidative stress conditions including shock, sepsis, trauma, hypoxia, ischemia-reperfusion injury and surgery [21]. During the aforementioned oxidative stress conditions, reduced oxygen species interact with lipids, proteins and nucleic acids leading to the loss of membrane integrity, structural or functional changes in proteins and genetic mutations, respectively. MDA is the product of lipid peroxidation process [22].

In the present study, the tissue NO-MDA were not assessed. The serum values were used due to their availability in patients in clinical basis. Although serum samples may be taken from the patients, tissue samples cannot be harvested for follow-up.

In the present study, 5 minutes duration groups' NO levels tended to increase during the first week. Low intensity 5 minutes group NO level began to decrease afterwards that may indicate normal healing. However, high intensity 5 minutes group NO continued to increase which may indicate the continuation of tissue healing necessitating still to overcome probable biochemical disturbances in the proliferative phase of healing (Figure 7A-B). The NO levels of ten minutes duration groups, both the low and high intensity applied rats, showed a gradual decline during the first week and then began to increase afterwards. The pattern of increase was similar to the high intensity 5 minutes group (Figure 7A-B). The starting point of NO level of the high intensity 10 minutes group could be expected to be similar or near to the point of high intensity 5 minutes group. However, the need to change the liver tissue that had been thinned in the high intensity 10 minutes group might create some time for the neural tissue to replenishment. This situation may resemble the condition, in the neurosurgical approaches, that the surgeon is advised to wait for some time by the electrophysiological monitoring professional after the nerve is thought to get dry or stretched during the surgery. The idea that there may be different mechanisms of action or logic to explain the NO levels had been suggested by earlier studies [23].

However different mechanisms of action are suggested regarding NO levels for the groups of the present study, MDA levels reached the highest point at the end of the first week and began to decline afterwards for all the groups (Figure 8A-B). This pattern indicates that the lipid peroxidation continues and limited in the first week and then tissue injury seems to began healing.

Although electrophysiological parameters including amplitude and latency and lipid peroxidation process measured by MDA shows the tendency indicating healing, all of the mentioned parameters had been recognised to fail to reach the first day values. This indicates that further assessment may be needed in longer periods to contribute to the knowledge of this subject.

Conclusion

The present study revealed that the application of CUSA is to be performed cautiously in order to preserve neural functions. This study is performed on the peripheral nerves having a neural sheath. The lack of a sheath of nerves in the central nervous system necessitates further caution of CUSA application. The authors also suggest that similar studies would be necessary to assess the evaluated parameters performed in longer periods.

References

1. Jackler RK: Surgical Neurotology. An Overview. In: Jackler RK, Brackmann DE (Eds). Neurotology. Philadelphia: Elsevier Mosby; 2005; pp. 675-711.
2. Brock M, Ingwersen I, Roggendorf W. Ultrasonic aspiration in neurosurgery. *Neurosurg Rev.* 1984; 7:173-177.
3. Desinger K, Liebold K, Helfman J, Stein T, Müller T. A new system for a combined laser and ultrasound application in neurosurgery. *Neurological Research.* 1999; 21:84-88.
4. Young W, Cohen AR, Hunt CD, Ransohoff J. Acute Physiological effects of ultrasonic vibration on nervous tissue. *Neurosurgery.* 1981; 8:689-694.
5. Millat B, hay JM, Descottes B, Fingerhut ABE, Fagniez PL. Prospective evaluation of ultrasonic surgical dissectors in hepatic resection: A cooperative multicenter study. *HPB Surgery.* 1992; 5:135-145.
6. Jallo GI. CUSA EXcel Ultrasonic Aspiration System. *Neurosurgery.* 2001; 48:695-697.

7. Bagley RS, Harrington ML, Gay JM, Silver GM. Effects of changes in power setting of an ultrasonic aspirator on amount of damage to the cerebral cortex of healthy dogs. *AJVR*. 2001; 62:248-251.
8. Howard BK, Beran SJ, Kenkel JM, Krueger JE, Rohrich RJ. The effect of ultrasonic energy on peripheral nerves: Implications for ultrasound-assisted liposuction. *Plast Reconstr Surg*. 1999; 103:984-9.
9. Green LC, Wagner DA, Glogowski J, Skipper PL, Wishnok JS, Tannenbaum SR. Analysis of nitrate, nitrite and [15N] nitrate in biological fluids. *Anal Biochem*. 1982; 126:131-138.
10. Yagi K. Lipid peroxides and related radicals in clinical medicine. In: Armstrong D, ed. *Free radicals in diagnostic medicine*. New York: Plenum Press; 1994, pp. 1-15.
11. Foley JL, Little JW, Vaezy S. Effects of high intensity focused ultrasound on nerve conduction. *Muscle and Nerve*. 2008; 37: 241-250.
12. Abounader M, De Boisvilliers S, Barneon G, et al. Effects of ultrasonic aspiration on the sciatic nerve of rats. Experimental study. *Neurochirurgie*. 1991; 37: 119-122.
13. Ridderheim PA, von Essen C, Zetterlund B. Indirect injury to cranial nerves after surgery with Cavitron ultrasonic surgical aspirator (CUSA). Case report. *Acta Neurochir (wien)*. 1987; 89:84-6.
14. Limb CJ, Niparko JK: The Acute Facial Palsies. In: Jackler RK, Brackmann DE (Eds). *Neurotology*. Philadelphia: Elsevier Mosby; 2005, pp. 1230-1257.
15. Ulland AE, Shearer JD, Coulter C, Caldwell MD. Altered wound arginine metabolism by corticosterone and retinoic acid. *J Surg Res*. 1997; 70:84-88.
16. Schaffer MR, Tantry U, Gross SS, Wasserkrug HL, Barbul A. Nitric oxide regulates wound healing. *J Surg Res*. 1996; 63:237-240.
17. Schaffer MR, Tantry U, van Wesep RA, Barbul A. Nitric oxide metabolism wounds. *J Surg Res*. 1997; 71:25-31.
18. Schaffer MR, Efron PA, Thornton FJ, Klingel K, Gross SS, Barbul A. Nitric oxide an autocrine regulator of wound fibroblast synthetic function. *J Immunol*. 1997; 158:2375-2381.
19. Wang R, Ghahary A, Shen YJ, Scott PG, Tredget EE. Human dermal fibroblasts produce nitric oxide and express both constitutive and inducible nitric oxide synthase isoforms. *J Invest Dermal*. 1996; 106:419-427.
20. Kappenol WH. The basic chemistry of nitrogen monoxide and peroxy nitrite. *Free Radic Biol Med*. 1998; 25:385-91.
21. Borovic S, Meinitzer A, Loncaric I, et al. Monitoring influence of surgical stress on formation of hydroxyl radicals in tumour bearing rats by measuring salicylic acid metabolism. *Electronic J Int Fed Clin Chem Lab Med*. 2000; 12:1-4.
22. Gilham B, Papachristodoulou DK, Thomas JH. *Wills' biochemical basis of medicine*. London: Butterworths; 1997, pp. 343-354.
23. Talas DU, Nayci A, Polat G, et al. The effects of dexamethasone on lipid peroxidation and nitric oxide levels on the healing of tracheal anastomoses: An experimental study in rats. *Pharmacological Research*. 2002; 46:265-271.