

## ORIGINAL ARTICLE

### A Case of Ramsay Hunt Syndrome After Inactive Influenza Vaccine

Melek Kezban Gurbuz, Leman Birdane, Armagan Incesulu, Suzan Saylisoy, Cem Kecik

Department of Otorhinolaryngology, Eskisehir Osmangazi University, (MG, LB, AI, CK)  
Dept. of Radiology, Eskisehir Osmangazi University, (SS)

Ramsay Hunt syndrome (RHS) is a polineuropathy which occurs in any time after a primary infection of varicella Zoster virus (VZV). It is a rarely manifestation of VZV, but it is usually more common with aging or immunocompromised conditions. In this paper we present a case report of RHS involving facial and vestibulocochlear nerves after vaccination with inactive influenza vaccine.

Submitted : 09 February 2010

Revised : 27 September 2010

Accepted : 27 September 2010

#### Introduction

Ramsay Hunt Syndrome (RHS) is described by Ramsay Hunt in 1907. Herpes Zoster Oticus or Cephalicus are the alternate names of this syndrome. RHS is a viral polineuropathy, occurs after reactivation of Varicella Zoster virus (VZV) hiding inside dorsal roots and cranial nerve ganglions. Aging, malignity, chemoradiotherapy exposure, immune deficiency may trigger reactivation of this virus [1-4]. Characteristic features of RHS are painful herpetic vesicles on tympanic membrane and/or external auditory meatus with facial paralysis on the same side. Presence of these vesicles facilitate differential diagnosis from Bell's Palsy. Vesicular rashes might also be seen on ear auricles, external auditory canal, tympanic membrane, 2/3 front piece of tongue, face, neck, buccal mucosa, larynx. In addition to the facial nerve involvement, other cranial nerves including 5, 6, 8, 9, 10, 11 and 12th are also reported to be involved in Ramsey Hunt Syndrome. Vestibulocochlear nerve is the most affected among them [5]. In this paper, we present a case report of a RHS involving facial and vestibulocochlear nerves after vaccination with inactive influenza vaccine.

#### Case Report

A 66-year old woman was admitted to local health center with complaints of weakness, running nose, headache with history of vaccination with inactive influenza vaccine 10 days ago. Amoxicillin was

prescribed as antibiotic treatment. One week later, upon the complaints of dizziness, nausea and vomiting patient was referred to our hospital. She was hospitalized in neurology ward with the pre-diagnosis of vestibular neuritis. On the third day of hospitalization, new symptoms developed which were hearing loss, earache and itchy and painful vesicles on the right ear as well as on the right side of 2/3 of anterior tongue (Figures 1 and 2). Two days after appearance of vesicular lesions, the patient experienced sensory and motor loss on right side of her face. At this stage, we were consulted and hospitalized the patient was hospitalized at ENT department with the pre-diagnosis of Ramsay Hunt syndrome. She has been hypertension, asthma and hyperlipidemia for 15 years. She reported that she had chicken pox and mumps in her childhood and it was confirmed by positive antibodies in her blood studies. On physical examination, right tympanic membrane was normal while edema and vesicular lesions were observed in the external auditory canal and auricle. These lesions were also seen on the 2/3 of right anterior portion of tongue and soft palate. Her facial paralysis was graded as House-Brackmann grade IV. She had no previous history of hearing loss. On audiological examination, there was severe-to-profound sensorineural hearing loss in right ear.

Temporal Bone Magnetic Resonance Imaging (TMRI) revealed contrast enhancement in cochlea, internal acoustic canal and along the facial nerve (Figure 3).

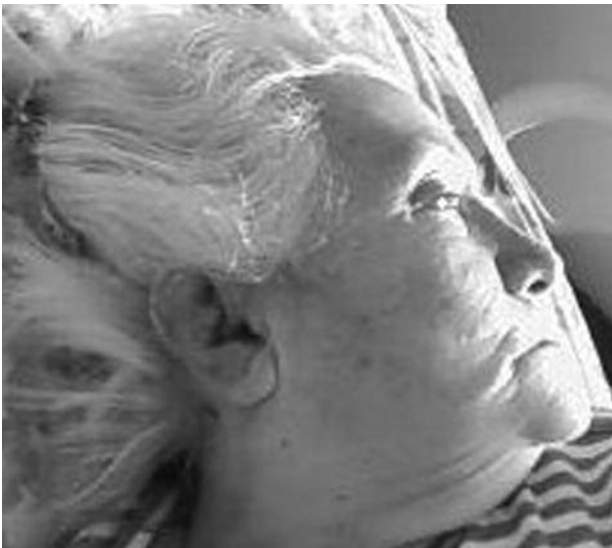#### Corresponding address:

Dr. Melek Kezban Gurbuz  
Osmangazi Üniversitesi, KBB Anabilim Dalı, Eskişehir  
Phone: 0 222 239 2979-3800, Fax: 0 222 239 3774, E-mail: mkezban@yahoo.com.tr

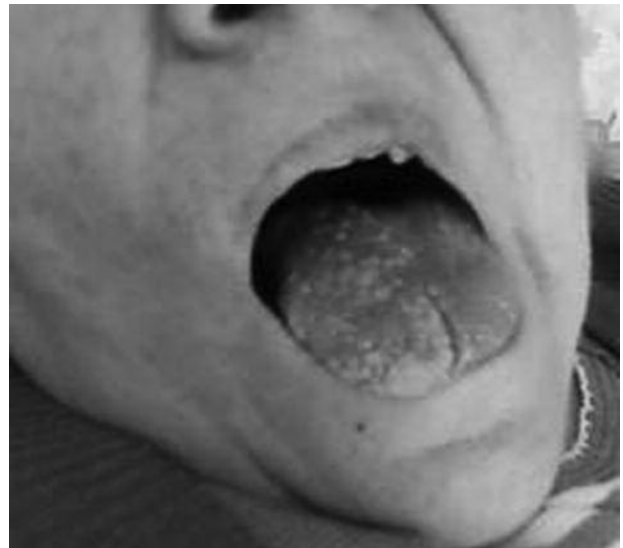Copyright 2005 © The Mediterranean Society of Otolaryngology and Audiology

Prednisolone (1mg/kg) and Acyclovir (1000 mg / day) treatment was instituted. Vestibular suppressant medications were also given for dizziness. On the fourth day of the treatment, total hearing loss occurred and her facial paralysis progressed to grade VI (Figure 4). Her vesicular lesions regressed totally on the 7th day of the treatment. Dizziness subsided gradually. At the end of 4-week-treatment, there was no recovery of

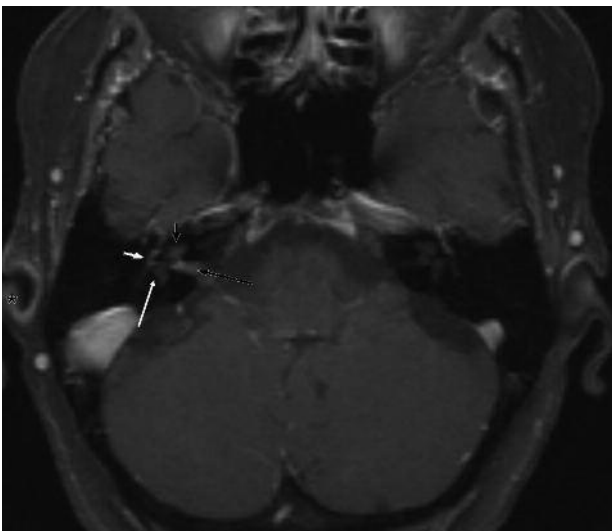
total hearing loss and facial paralysis. Since there was no improvement at two months after the end of treatment, we performed facial decompression involving mastoid and tympanic segments up to first angle. During the operation, we observed edema of facial nerve. However it is not possible to report the final result of surgery because of the short follow-up period.



**Figure 1.** Vesicles on the right ear



**Figure 2.** Vesicles on the right side of 2/3 of anterior tongue



**Figure 3.** Axial contrast-enhanced T1-weighted magnetic resonance imaging shows enhancement within internal auditory canal (black arrow), cochlea (small black arrow), vestibule (white arrow), tympanic segment of facial nerve (small white arrow) and auricle (asterisk) on the right



**Figure 4.** House-Brackmann grade VI facial paralysis

## **Discussion**

Varicella Zoster virus (VZV) causes chickenpox at childhood. This virus resides silent and inactive within the central nervous system for long years. Recurrence of this primary infection at childhood is named as Ramsay Hunt Syndrome (RHS) at senior ages. Advanced age, chronic-systemic diseases, immune deficiency conditions may cause reactivation and lead to RHS which is a form of polineuropathy [1,6]. It is particularly interesting in this case report that RHS appeared after vaccination with inactive influenza vaccine. Influenza A and B viruses cause seasonal epidemics or pandemics especially in winter. This viral infection might be fatal in elderly, severe or chronic disease patients. Therefore, seasonal influenza vaccine is recommended by WHO for elderly over the age of 65, immune deficient and chronic cardiopulmonary disease patients. Vaccination is also advised by health authorities in our country. The vaccine is safe except for people who have an egg allergy. Minor side effects like local rash, stiffness, malaise, subfebrile fever are reported. However, it might rarely cause neurological problems like Guillain Barre syndrome or Bell's palsy. It is suggested that the vaccine is destructing the myelin sheath [7-10]. In our case, the pathophysiology of RHS after seasonal influenza vaccine is not clear. There is a possibility that a transient immune-deficient condition just after vaccination might have been triggered, reactivating the inactive VZV. This is supposed to cause RHS.

In RHS; the first symptom is mostly facial paralysis, at the same time vesicular rashes, hearing loss, sense of imbalance may also be seen. The clinical situation of our case was in the first place with dizziness, nausea, vomiting; then vesicular rashes are seen, facial paralysis developed thereafter. It has been suggested that hearing is less affected than the vestibular system in RHS. Degree of hearing loss is generally in spectrum between mild to and severe loss. Progression of the disease and involvement of the labyrinth may be together with severe sensorineural loss [5,10]. Likewise, our case had also severe sensorineural loss in the first place and then eventually total hearing loss developed with the progression of the disease.

In diagnosis of RHS, clinical findings are usually enough, but viral serology with CSF examination may also be considered. Facial nerve functions can be

measured with electrodiagnostic methods. Edema and inflammation of the facial nerve are detected with Gadolinium-contrast-MRI, which is accepted as the worst prognosis [11,12]. Our case revealed complete destruction of the facial nerve on EMG. Our MRI revealed that there was gadolinium enhancement within the cochlea, internal acoustic canal and all along the facial nerve.

High dose steroids together with antiviral medications (i.v or oral) are preferred for treatment of RHS. The aim is to decrease the degeneration of the nerve. Although it is known that RHS usually may not be responsive to medical therapy, a better prognosis might be acquired if started within 72 hours of onset of disease [13,14]. Our patient's history revealed exposure to seasonal influenza vaccine which caused misdiagnosis and delayed treatment. She received appropriate treatment, immediately after vesicles appeared in the external auditory canal. In the literature, RHS prognosis is reported to be better if vesicles appear before facial paralysis and cranial neuropathies [15]. This might be due to earlier diagnosis and onset of treatment with observation of vesicles. Intractable RHS cases resistant to medical therapy usually require surgical decompression of the facial nerve. However, there are some studies reporting that decompression is not useful. Similarly, our case was also resistant to medical therapy, and surgical decompression was performed 2 months after medical therapy. During the operation, we observed edema of the facial nerve on the mastoid and tympanic segments. One week after operation, our patient had sensation of the upper eyelid. However, this was just a subjective feeling. As mentioned above, our case had all the worst prognostic criteria, and yet there is no any sign of improvement. In the long term, there may be some response to decompression.

As far as we know, there is no case report of a RHS in the literature, which developed after inactive influenza vaccination. We aim to share the clinical progression of our case, and hope to compare with similar cases in the literature.

## **Conclusion**

It is quite an interesting case of RHS with involvement of both 7th and 8th nerves with a prior history of inactive influenza vaccination since there is no reported similar case in the literature so far. It is not explainable yet, which mechanisms are effective in association of RHS and vaccination. We suggest that transient immune suppression might be associated with this case.

## References

1. Sweeney CJ, Gilden DH. Ramsay Hunt syndrome. *J Neurol Neurosurg Psychiatry* 2001; 71(2):149-54.
2. Wackym PA. Molecular temporal bone pathology: II. Ramsay Hunt syndrome (herpes zoster oticus). *Laryngoscope* 1997; 107(9):1165-75.
3. Mortada R.A, El-Fakih RO, Assi M. Unusual presentation of Ramsay Hunt syndrome in renal transplant patients case report and literature review *Transpl Infect Dis* 2009; 11. 72-74.
4. Ocak Meydan F.D, Tutar İ, Yıldırım A, Konuralp N. Case report: Ramsay - Hunt syndrome, peripheral facial paralysis treated with electrostimulation. *Turk J Phys Med Rehab* 2005; 51(3):111-13.
5. Iragui VJ. Auditory dysfunction in Ramsay Hunt Syndrome. *Journal of Neurology, Neurosurgery and Psychiatry* 1986; 49:824-26.
6. Gnann JW, Whitley RJ. Herpes Zoster . *The New England Journal of Medicine* 2002; 347:340-46.
7. Looijmans-Van den Akker I, Verheij TJ, Buskens E, Nichol KL, Rutten GE, Hak E. Clinical effectiveness of first and repeat Influenza Vaccination in adult and elderly diabetic patients. *Diabetes Care*. 2006; 29(8):1771-6.
8. McElhaney JE. Influenza vaccination in the elderly: seeking new correlates of protection and improved vaccines. *Aging health* 2008; 4(6):603-13.
9. Chou CH, Liou WP, Hu KI, Loh CH, Chou CC, Chen YH. Bell's palsy associated with influenza vaccination: two case reports. *Vaccine*. 2007; 25(15):2839-41.
10. Syal R, Tyagi I, Goyal A. Bilateral Ramsay Hunt syndrome in a diabetic patient. *BMC Ear Nose Throat Disord*. 2004; 4(1):3.
11. Whitley RJ. A 70 year old Woman With Shingles. *JAMA*. 2009; 302(1):73-80
12. Kim IS, Shin SH, Kim J, Lee WS, Lee HK. Correlation between MRI and Operative Findings in Bell's Palsy and Ramsay Hunt Syndrome. *Yonsei Med J* 2007; 48(6):963-68 .
13. Kinishi M, Amatsu M, Mohri M , Saito M, Hasegawa S. Acyclovir improves recovery rate of facial nerve palsy in Ramsay Hunt syndrome. *ANL* 2001; 28 223-26.
14. Murakami S, Hato N, Horiuchi J, Honda N, Gyo K, Yanagihara N. Treatment of Ramsay Hunt syndrome with acyclovir-prednisone: significance of early diagnosis and treatment. *Ann Neurol*. 1997; 41(3):353-7.
15. Murakami S, Hato N, Horiuchi J, Miyamoto Y, Aono H, Honda N, Yanagihara N. Clinical features and prognosis of facial palsy and hearing loss in patients with Ramsay Hunt syndrome (Abstract). *Nippon Jibiinkoka Gakkai Kaiho*. 1996; 99(12):1772-9.