

CASE REPORT

Polymorphic Clinical Presentation of Cerebellar Arachnoid Cyst: A Case Report. Etiopathogenetic Theory and Review of the Literature

Mario Faralli, Luca D'Ascanio, Ruggero Lapenna, Giampietro Ricci

Department of Otolaryngology, University of Perugia, Perugia (Italy) (MF, RL, GR)

Department of Otolaryngology - Head & Neck Surgery, Città di Castello Civil Hospital, Città di Castello (Perugia), Italy (LD)

Arachnoid cysts (AC) are developmental collections of cerebrospinal fluid covered by layers of arachnoidal epithelium and are usually located in the middle cranial fossa. Localizations in the posterior fossa are uncommon and generally remain asymptomatic or cause vague and non-specific symptoms. We describe the unusual case of a patient with an AC suffering from recurrent polymorphic vertigo with atypical nistagmus and transient sensorineural hearing loss. The clinical-diagnostic features are discussed, etiopathogenetic theories are proposed and a review of the literature on posterior cranial fossa AC is reported.

Submitted : 17 February 2013

Revised : 21 August 2013

Accepted : 25 September 2013

Introduction

Arachnoid (AC) or leptomeningeal cysts are benign, intra-arachnoid cystic lesions that are filled with cerebrospinal fluid (CSF). Likely developmental in origin and generally asymptomatic, these lesions can become symptomatic as a result of enlargement or intracystic hemorrhage^[1]. Although their exact etiology is unknown, various hypotheses have been considered. These hypotheses include active fluid secretion from the cystic wall, fluid accumulation secondary to changes in the osmotic gradient, and vascular pulsation causing CSF flow between the cyst and subarachnoid space^[1]. AC occur throughout the central nervous system (CNS), and while generally no communication is demonstrable with the subarachnoid space, a more recent hypothesis has been suggested based on intraoperative reports of apparent one-way, slit-valve communications between

the cyst and subarachnoid space. AC represent approximately 1% of all intracranial space-occupying lesions. They are typically located in the middle cranial fossa, but other locations including the cerebellopontine angle, cerebellar hemispheres and posterior fossa have been described.^[2-4]

They may be associated with other clinical situations, such as a carotid-jugular fistula, dissection of the contralateral carotid artery and hemifacial atrophy and thus represent a generalized connective tissue disorder^[5].

AC may remain asymptomatic and undiagnosed until the compression of adjacent anatomical structures caused by the growth of the cyst results in various clinical symptoms that are dependent on the location of the cyst. When an AC is located in the posterior fossa, the presenting symptoms are frequently otologic.^[6]

Corresponding address:

Mario Faralli
mario.far@hotmail.it
phone 3479379478

Copyright 2005 © The Mediterranean Society of Otolaryngology and Audiology

We here report the case of a patient with a cerebellar AC suffering from recurrent polymorphic vertigo with atypical nystagmus and transient sensorineural hearing loss. We describe the clinical-diagnostic features together with a review of the literature on such a topic.

Case Report

This 73-year old woman, who had been in good health previously, presented to the Department of Otolaryngology (tertiary referral center) of the Department of Otolaryngology, University of Perugia,, with a 2-day history of positional vertigo attacks associated with neurovegetative symptoms and dizziness. The patients did not refer any aural fullness or tinnitus.

Current medications included oral hypoglycemic agents for type II diabetes mellitus and amlodipine for hypertension. She did not report any previous vertigo attack or dizziness, migraine or other neurological symptoms. Pure tone audiometry revealed only a mild, symmetrical, high-frequency, sloping, sensorineural hearing loss, compatible with presbycusis.

Vestibular examination confirmed a vestibular paroxysmal positional vertigo (BPPV) for a canalolithiasis of the posterior semicircular canal. Semont's liberatory maneuver was performed with immediate resolution of patient's symptoms. After 2 weeks of complete health, the patient presented a new BPPV attack, which was successfully treated with liberatory maneuvers.

Two weeks later the patient presented at our Department with substantially different complaints: objective vertigo unrelated to head position, associated with hearing symptoms. Bedside vestibular examination showed rotatory horizontal right-beating nystagmus unrelated to head movements, slight left-side index deviation and normal cerebellar vestibular tests. Audiometry showed a low-medium frequency, climbing-shape, sensorineural hearing loss on the right ear. Osmotic diuretics were administered with complete resolution of patient's vestibular symptoms after one day of treatment. In particular, vestibular examination (including head-shaking and caloric tests) was normal and a resolution of right ear hearing loss was noticed. Such presentation was suggestive of a

newly onset Meniere-like attack. Computerized tomography showed a posterior cranial fossa AC, occupying the median-right paramedian cerebellum, associated with hypoplasia of the right cerebellar lobe and vermis, without any focal lesion or recent bleeding image (Figure 1). Such findings were confirmed by magnetic resonance imaging (Figures 2a, b). During the next month the patient presented 2 more BPPV episodes and 1 more hydropic attack, with residual dizziness and low tolerance to head movements and optokinetic stimuli. She also developed a persistent, spontaneous, down-beating nystagmus. In agreement with our neurologist, we considered such nystagmus related to the AC. A neurosurgical consultation was carried out, which however excluded any surgical approach in relation to patient's age and absence of endocranial hypertension symptoms.

Discussion

Arachnoid cysts, firstly described by Bright in 1831, are fluid-filled spaces generated by congenital anomalous splitting of the arachnoid membrane; they may communicate with the subarachnoid space or may be partially or completely separated from it. [7,8]

AC may form in any position within the skull, more commonly in the left hemisphere, in the middle and

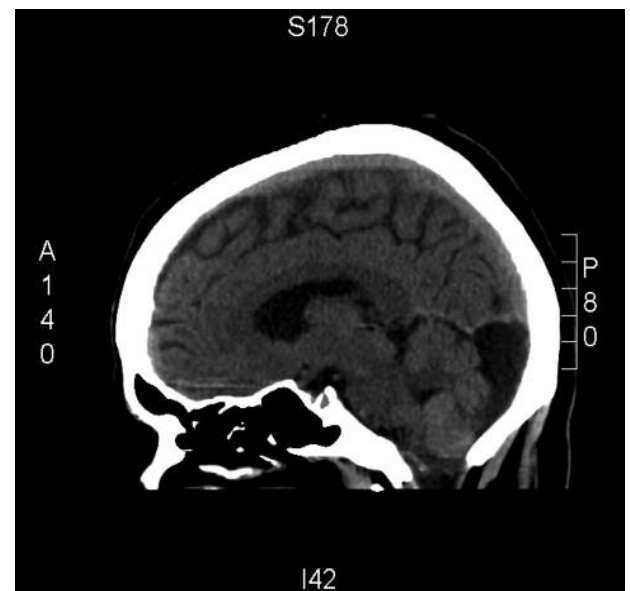


Figure 1. Computerized tomography (sagittal scan) showing the posterior cranial fossa arachnoid cyst.

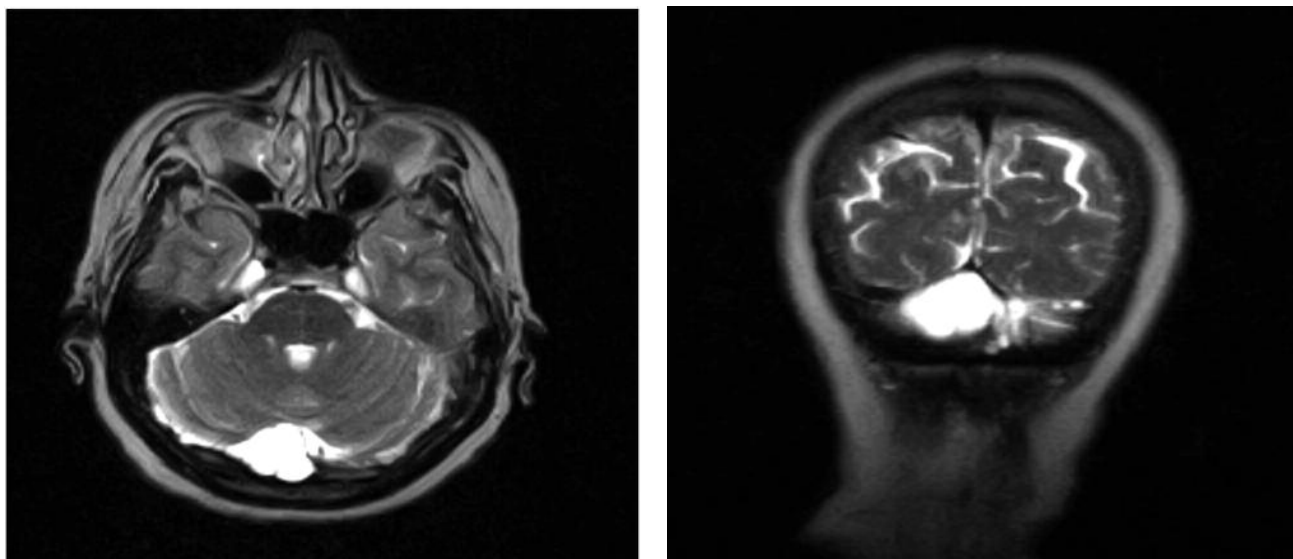


Figure 2. Axial (a) and coronal (b) magnetic resonance scans showing the arachnoid cyst occupying the median-right paramedian cerebellum: note the hypoplasia of the right cerebellar lobe and vermis.

anterior cranial fossa; in a lower percentage of cases (from 20 to 30 per cent) they are located in the posterior cranial fossa, where they may occupy a retrocerebellar area, or grow in the cerebello-pontine angle.^[9]

The male/female ratio ranges from 2/1 to 3/1 in the different reports and average duration of symptoms before the definitive diagnosis may vary from six months to five years.^[10]

Signs and symptoms related to the presence of AC depend on their size and location: while supratentorial cysts may produce mild untreatable headache, difficulties in concentration, more rarely temporal lobe epilepsy and, in paediatric patients, bulging of parietal bone, posterior fossa AC tend to have a protean clinical manifestation, with hypoacusis, tinnitus, dysmetria, ataxia, together with the cerebello-pontine angle syndrome, and sometimes vomiting, headache and papillar edema for endocranial hypertension secondary to fourth ventricle obstruction.^[8] Interestingly, vestibular symptoms (vertigo and dizziness) predominate over cochlear symptoms (tinnitus and hearing loss) and nystagmus is by far the most common clinical sign.^[8]

Atypical presentation of AC, especially in case of posterior fossa location, have also been reported (Table 1)^[11-24].

The case we present is didactic because of the polymorphic atypical symptoms presented by the patient: firstly, BPPV attacks resolved with liberatory maneuvers; secondly, a Meniere-like attack (objective vertigo with rotatory horizontal right-beating nystagmus unrelated to head movements, sand right sensorineural hearing loss) responding to osmotic diuretics; finally, a persistent, spontaneous, down-beating nystagmus, with BPPV and Meniere-like episodes. Since no surgical procedure was carried out, it is not possible to have a definite confirmation of a cause-effect relation between patient's clinical presentation and her posterior cranial fossa AC. However, AC polymorphic clinical presentation reported in the literature suggests a role of AC in the development of our patient's signs and symptoms. The mechanisms proposed to explain the atypical clinical presentation of the AC are the generation of a neurovascular conflict or an impairment of 'vasa nervorum' due to the stretching of the involved cranial nerves. This may determine an alteration in the normal endolymphatic circulation and an impaired terminal vascularisation of the macular neuroepithelium with detachment of otoconial debris that could explain respectively the relapsing episodes of Menieriform and positional vertigo. Down-beating nystagmus may be secondary to AC-related vermian and cerebellar lobe hypoplasia with consequent disinhibition of the vestibulo-ocular reflex.

Table 1. Review of the literature on arachnoid cyst presenting otologic symptoms

Author (year)	Arachnoid cyst location	Clinical presentation	Proposed pathophysiology
Jallo et al (1997) [11]	Cerebellopontine angle (5 patients)	Refractory headaches associated with nausea and vomiting (3 cases); cerebellar signs (2 cases)	Cyst-related compression on neurovascular structures of the cerebellopontine angle
Babu et al (1991) [12]	Cerebellopontine angle (1 patient)	Contralateral trigeminal neuralgia; symptoms resolution after cyst excision	Stretching of brainstem and cranial nerves
Higashi et al (1992) [13]	Cerebellopontine angle (1 patient)	Ipsilateral hemifacial spasm; symptoms resolution after surgery	Stretching of brainstem and cerebellopontine angle cranial nerves
Sakata et al (1987) [14]	Vermis (20 patients)	Positioning nystagmus with augmented latency and reduced fatigability	Incomplete inhibition of the vestibulo-oculomotor system including the cerebellar flocculonodular lobe or vestibulo-cerebellum
O'reilly et al (2003) [4]	Posterior fossa (2 patients)	Aural fullness, tinnitus, vertigo, nausea and emesis (Meniere-like syndrome); symptoms resolution in 1 patient after cysto-peritoneal shunt.	Cyst-related vascular compromise, altered cerebro-spinal fluid dynamics, displacement of the VIII nerve, or compression of the endolymphatic sac
Haberkamp et al (1990) [6]	Posterior cranial fossa	fluctuating sensorineural hearing loss (1 case); vague dizziness and ataxia with no vertigo (1 case)	Cyst-related compressive effect on neurological structures
Pollice et al (1997) [15]	Posterior cranial fossa (1 case)	Bilateral progressive sensorineural hearing loss and episodic vertigo; the hearing loss was more pronounced in the right than the left ear; bilateral vestibular weakness was found with a "severe" right-sided loss.	Cyst-related compression of neurological structures
Samii et al (1999) [16]	Cerebellopontine angle (12 patients)	Vertigo or dizziness (8 cases), tinnitus (5 cases), hearing loss (6 cases); most symptoms resolution after cyst surgical removal	Cyst-related compression on neurovascular structures of the cerebellopontine angle
Pappas et al (1981) [17]	Internal auditory canal (3 cases), cerebellum (1 case)	Progressive right-sided hearing loss, tinnitus, and experiences of dizziness; diminished caloric response in the right ear	Compression on neurovascular structures
Hadley et al (1985) [18]	Posterior cranial fossa (5 cases)	Tinnitus, lightheadedness, incoordination, and occasional vertigo with normal audiometry	Compression on neurovascular structures
Erdinçler et al (1999) [19]	Posterior cranial fossa (12 patients)	Vertigo, hypoacusis and gait instability (all cases) resolved after surgical treatment; V and VIII nerve palsies (1 case)	Compression on neurovascular structures
Gosepath et al (1994) [20]	Posterior cerebellum (1 case)	episodic vertigo with nausea, emesis, left-sided hearing loss, and bilateral tinnitus	Compression on neurological structures
Buongiorno et al (2003) [8]	Left fronto-parietal lobe (1 case)	Dizzy while sitting, left tinnitus and aural fullness (Meniere-like syndrome)	Cyst-related clockwise rotation of the brainstem causing acoustic-facial bundle stretching
Chan et al (1991) [21]	Cerebellar vermis	Dizziness and intermittent vertical oscillopsia after oblique extension of the head and neck, intermittent downbeat nystagmus lasting about 50 seconds and elicited by head extension and rotation; nystagmus resolution after cyst removal	Obstructive hydrocephalus
Aggouri et al (2010) [22]	Posterior fossa	Two- month history of headaches, nausea, and vertigo associated with walking instability; symptoms resolution after cyst removal.	Compression on neurological structures
Jayarao et al (2009) [1]	Right cerebellopontomedullary area	Right-sided sensorineural hearing loss and tinnitus; symptoms resolution after surgical treatment	Compression on neurovascular structures
Ottaviani et al (2002) [23]	Cerebellar convexity	Left-sided hypoacusis and tinnitus	Compression on the cerebellopontine angle
Marqués Rebollo et al (2006) [24]	Left cerebello-pontine angle (1 case)	Tinnitus, hearing loss and vertigo (Meniere-like syndrome)	Compression on neurovascular structures

In conclusion, posterior fossa arachnoid cysts must be considered in the differential diagnosis of patients presenting with atypical audiovestibular or Meniere-like signs and symptoms. Neuroimaging (magnetic resonance and computerized tomography) is mandatory for AC diagnosis.

Conflict of interest: none

Financial support: none

References

1. Jayarao M, Devaiah AK, Chin LS. "Recovery of sensorineural hearing loss following operative management of a posterior fossa arachnoid cyst. Case report". *J Neurosurg Pediatr.* 2009 Aug;4:121-4.
2. Hadley MN, Graham TW, Daspt CP, Spetzler RF. "Otolaryngologic manifestations of posterior fossa arachnoid cysts". *Laryngoscope.* 1985 Jun;95:678-81.
3. Miyamoto T, Ebisudani D, Kitamura K, Ohshima T, Horiguchi H, Nagahiro S. Surgical management of symptomatic intrasellar arachnoid cysts--two case reports. *Neurol Med Chir (Tokyo).* 1999 Dec;39:941-5.
4. O'reilly RC, Hallinan EK. Posterior fossa arachnoid cysts can mimic Meniere's disease. *Am J Otolaryngol.* 2003 Nov-Dec;24:420-5.
5. Schievink WI, Piegras DG, Nichols DA. Spontaneous carotid-jugular fistula and carotid dissection in a patient with multiple intracranial arachnoid cysts and hemifacial atrophy: a generalized connective tissue disorder? Case report. *J Neurosurg.* 1995 Sep;83:546-9.
6. Haberkamp TJ, Monsell EM, House WF, Levine SC, Piazza L. Diagnosis and treatment of arachnoid cysts of the posterior fossa. *Otolaryngol Head Neck Surg.* 1990 Oct;103:610-4.
7. Bright R. Serous cysts in arachnoid. In Reports of medical cases selected with a view of illustrating the symptoms and cure disease by reference to morbid anatomy. Disease of the brain and nervous system, Part I. Vol II, London: Richard Taylor Publications, 1831;II:437-49.
8. Buongiorno G, Ricca G. Supratentorial arachnoid cyst mimicking a Ménière's disease attack. *J Laryngol Otol.* 2003 Sep;117:728-30.
9. Rengachary SS, Watanabe I. Ultrastructure and pathogenesis of intracranial arachnoid cysts. *J Neuropathol Exp Neurol.* 1981 Jan;40:61-83.
10. Daneyemez M, Gezen F, Akbörü M, Sirin S, Ocal E. Presentation and management of supratentorial and infratentorial arachnoid cysts. Review of 25 cases. *J Neurosurg Sci.* 1999 Jun;43:115-21.
11. Jallo GI, Woo HH, Meshki C, Epstein FJ, Wisoff JH. Arachnoid cysts of the cerebellopontine angle: diagnosis and surgery. *Neurosurgery.* 1997 Jan;40:31-7; discussion 37-8.
12. Babu R, Murali R. Arachnoid cyst of the cerebellopontine angle manifesting as contralateral trigeminal neuralgia: case report. *Neurosurgery.* 1991 Jun;28:886-7.
13. Higashi S, Yamashita J, Yamamoto Y, Izumi K. Hemifacial spasm associated with a cerebellopontine angle arachnoid cyst in a young adult. *Surg Neurol.* 1992 Apr;37:289-92.
14. Sakata E, Ohtsu K, Shimura H, Sakai S. Positional nystagmus of benign paroxysmal type (BPPN) due to cerebellar vermis lesions. Pseudo-BPPN. *Auris Nasus Larynx.* 1987;14:17-21.
15. Pollice PA, Bhatti NI, Niparko JK. Imaging quiz case 1. Posterior fossa arachnoid cyst. *Arch Otolaryngol Head Neck Surg.* 1997 Jul;123:762, 764-5.
16. Samii M, Carvalho GA, Schuhmann MU, Matthies C. Arachnoid cysts of the posterior fossa. *Surg Neurol.* 1999 Apr;51:376-82.
17. Pappas DG, Brackmann DE. Arachnoid cysts of the posterior fossa. *Otolaryngol Head Neck Surg.* 1981 Mar-Apr;89:328-32.
18. Hadley MN, Graham TW, Daspt CP, Spetzler RF. Otolaryngologic manifestations of posterior fossa arachnoid cysts. *Laryngoscope.* 1985 Jun;95:678-81.
19. Erdinçler P, Kaynar MY, Bozkus H, Ciplak N. Posterior fossa arachnoid cysts. *Br J Neurosurg.* 1999 Feb;13:10-7.

20. Gosepath K, Maurer J, Mann W. Rare differential diagnosis in "vertigo" symptoms. *Laryngorhinootologie*. 1994 Jun;73:326-30.
21. Chan T, Logan P, Eustace P. Intermittent downbeat nystagmus secondary to vermian arachnoid cyst with associated obstructive hydrocephalus. *J Clin Neuroophthalmol*. 1991 Dec;11:293-6.
22. Aggouri M, Boujraf SA, Benzagmout M, Chaoui ME. Arachnoid cyst of the posterior fossa. *Neurosciences (Riyadh)*. 2010 Oct;15:277-9.
23. Ottaviani F, Neglia CB, Scotti A, Capaccio P. Arachnoid cyst of the cranial posterior fossa causing sensorineural hearing loss and tinnitus: a case report. *Eur Arch Otorhinolaryngol*. 2002 Jul;259:306-8.
24. Marqués Rebollo L, Blasco Huelva A. Arachnoid cyst of cerebellar-pontine angle clinically mimicking Meniere's disease. *An Otorrinolaringol Ibero Am*. 2006;33:169-74.