



Original Article

# Clinical Analysis of Paper Patch Myringoplasty in Patients with Tympanic Membrane Perforations

Dong-Hee Lee, Jisun Kim, Eunhye Shin, Yulgyun Kim, Yesun Cho

Department of Otolaryngology-Head and Neck Surgery, College of Medicine, the Catholic University of Korea, Seoul, Korea

**OBJECTIVE:** The aims of our study were to evaluate the outcome of office-based paper patch grafting in tympanic membrane (TM) perforation regardless of the disease duration or etiology and to compare the clinical factors influencing the successful closure of perforation between the success and failure groups of paper patch myringoplasty.

**MATERIALS and METHODS:** This is a retrospective study of 114 patients that underwent paper patch myringoplasty in an outpatient setting (success group, 83 cases; failure group, 31 cases). Thirteen clinical factors with potential impact on the healing status of the TM were investigated: gender, age, laterality, etiology, duration of perforation, tinnitus, hearing loss, otorrhea, size and location of perforation, status of contralateral ear, ipsilateral findings of computed tomography, and duration of complete healing. The follow-up period was at least 1 year.

**RESULTS:** The total success rate of paper patch grafting was 72.8%. The mean age of the failure group was significantly more higher than that of the success group. Significant differences in the etiology as well as in the history of otorrhea were found between the success and failure groups. There were no significant differences for any of the other factors between chronic and non-chronic perforations.

**CONCLUSION:** The predictors of successful outcome were patient's age, etiology of perforation, and history of otorrhea. Clinicians can attempt paper patch myringoplasty first in younger patients, traumatic TM perforation cases, and in patients with no history of otorrhea. Paper patch grafting can also be considered before formal surgical myringoplasty in the case of small, dry, chronic TM perforations.

**KEYWORDS:** Tympanic membrane perforation, paper patching, myringoplasty

## INTRODUCTION

Tympanic membrane (TM) perforations mainly result from infectious and traumatic etiologies. Perforations due to acute otitis media and trauma tend to heal spontaneously. However, if there are repeated infections or if the infection is persistent, these perforations become chronic and are less likely to heal spontaneously. Long-standing TM perforations may cause conductive hearing loss and middle ear infection even if they are small. The purpose of the closure of TM perforations is to restore the continuity of the TM to improve hearing ability and decrease the risk of middle ear infection<sup>[1-4]</sup>. Although many reports have demonstrated that numerous cases of perforated TM heal spontaneously, several operative interventions can be helpful, particularly for large-sized and peripherally-located perforations<sup>[2,4]</sup>.

The use of paper patches in an outpatient setting has been a widely used technique for many decades. Several studies have demonstrated that paper patches can be used to promote the healing of perforated TMs while avoiding a formal surgical procedure<sup>[1,5]</sup>. The size of TM perforation has been reported as the prognostic indicator for successful patch myringoplasty. Golz et al.<sup>[1]</sup> evaluated only chronic perforations of more than 1 year regardless of the cause and followed up the cases until 18 weeks; they recommended paper patching as the first treatment option for TM perforations smaller than 5 mm. Lee et al.<sup>[2]</sup> evaluated only chronic otitis media and followed up the cases through five trials of paper patching; they reported that TM perforations of less than 4 mm had significantly higher closure rates. However, these two studies did not include other clinical factors apart from the size of TM perforations as outcome predictors. Park et al.<sup>[4]</sup> reported that the outcome predictor of paper patch myringoplasty was perforation size; however, they evaluated only chronic perforations of more than 3 months, regardless of the cause, and followed up the cases until 3 months.

The aims of the present study are to evaluate the outcome of office-based patch grafting in TM perforations, regardless of the disease duration or etiology, and to explore the clinical factors influencing the successful closure of TM perforations. This study included a long-term observation of the healing status of TM perforations over at least 1 year.

**Presented in:** This study was presented at the 3<sup>rd</sup> Congress of European Otorhinolaryngology and Head and Neck Surgery, 7-11 June 2015, Prague, Czech Republic.

**Corresponding Address:** Dong-Hee Lee E-mail: leedh0814@catholic.ac.kr

**Submitted:** 28.04.2016 **Revision received:** 30.06.2016 **Accepted:** 30.06.2016

©Copyright 2016 by The European Academy of Otolology and Neurotology and The Politzer Society - Available online at [www.advancedotology.org](http://www.advancedotology.org)

## MATERIALS and METHODS

### Subjects

This retrospective study enrolled all cases in which patch graft myringoplasty was performed to close a TM perforation by an otologic surgeon in an outpatient setting at a university-based, secondary referral hospital from June 2010 to September 2014. Ethics committee approval was received for this study from the ethics committee of Uijeongbu St. Mary's Hospital (IRB #UC15RISI0039) and informed consent was waived because of the retrospective nature of the study.

The candidates for data analysis were patients with TM perforations regardless of the cause or onset. The middle ear/mastoid pathology was verified by operating microscope/otoendoscopy or computed tomography (CT).

Exclusion criteria were as follows: 1. history of previous middle ear surgery; 2. nasopharyngeal or skull base pathology resulting in Eustachian tube dysfunction; 3. history of radiation to head and neck region; 4. attic perforation; 5. patient refusing paper patch grafting and choosing alternative treatment options; and 6. patients who were followed up for less than 1 year after paper patch grafting.

### Predictive Clinical Factors

Thirteen clinical factors were investigated: 1. gender, 2. age, 3. laterality of TM perforation, 4. etiology of TM perforation, 5. time interval between TM perforation and patch grafting, 6. tinnitus, 7. hearing loss, 8. otorrhea, 9. size and 10. location of TM perforation, 11. status of contralateral ear, 12. ipsilateral CT finding, and 13. duration of complete healing (Table 1).

Based on the size of TM perforation, the cases were classified into three groups: 1. smaller than one third of the pars tensa, 2. one third to two thirds of the pars tensa, and 3. larger than two thirds of the pars tensa. After a photograph of the entire TM was taken using a 0 degree, 4-mm diameter endoscope and transferred to the picture archiving and communication system, the size of the perforation was calculated using the Marosis m-View™ tool (Marotech; Seoul, South Korea). The location of the TM perforation was classified into the following five groups: group 1. anterior to malleus, group 2. posterior to malleus, group 3. inferior to umbo, group 4. larger than group 1–3, and group 5. multiple perforations (Figure 1). Pure-tone average (PTA) is the average of hearing sensitivity at 0.5, 1, 2, and 3 kHz, and normal hearing was defined as a PTA of 25 dB HL or less. Tinnitus was subjectively evaluated through the question “Do you have a constant ringing or some other disturbing sound in your ears?”

### Surgical Technique

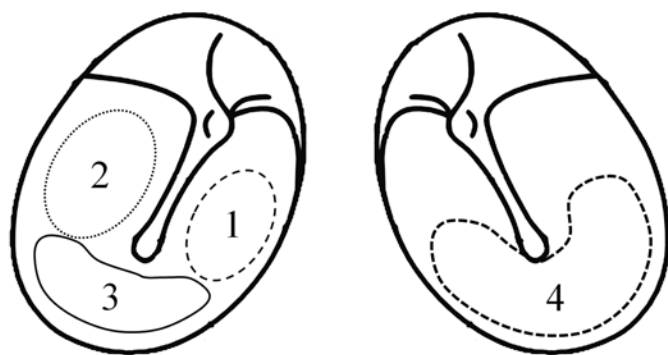
Prior to the surgical procedure, possible outcomes and alternative surgical options were properly explained to the patient, and written informed consent was acquired. All the procedures were performed by an otologic surgeon in an outpatient setting. If active otorrhea was found at the initial visit, it was controlled by oral medication and conservative management. Paper patch myringoplasty was performed when TM perforations were free of infection and dry. For local anesthesia, a cotton ball soaked in 10% lidocaine (Veracaine spray; Sung Kwang Pharm, Cheonan, South Korea) was applied in the external auditory canal under an operating microscope, preventing lidocaine from entering the middle ear cavity. The edge of the perforation was

**Table 1.** Demographic data (n=114 cases)

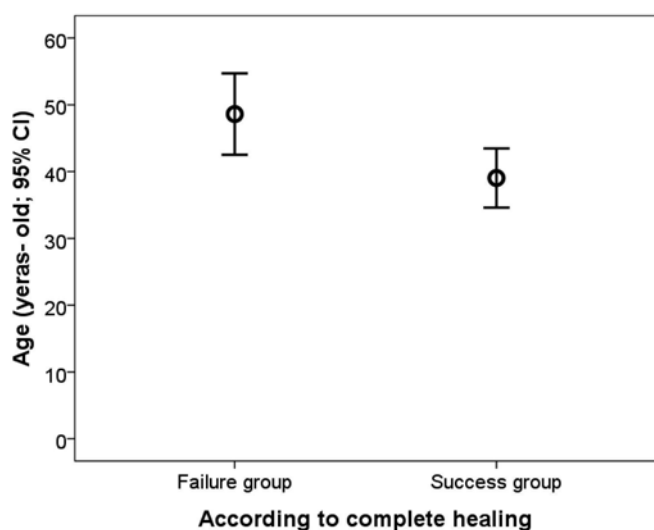
		Percentage	n
Gender	Male	47.4	54
	Female	52.6	60
Age (years, mean±SD)	41.6±19.7		
Laterality of TM perforation	Right	38.6	44
	Left	61.4	70
Etiology of TM perforation	Trauma	47.4	54
	Infection/Inflammation	44.7	51
	Iatrogenic	2.6	3
	Unknown	5.3	6
Time interval between TM perforation and patch grafting	<3 weeks	71.1	81
	≥3 weeks but <3 months	17.5	20
	≥3 months but <1 year	7.0	8
	≥1 year	4.4	5
Tinnitus	Presence	50.9	58
	Absence	49.1	56
Hearing loss	Presence	63.2	72
	Absence	36.8	42
Otorrhea	No history	54.4	62
	Past history but none on the initial visit	11.4	13
	Active otorrhea on the initial visit	34.2	39
Size of TM perforation	<1/3	78.9	90
	≥1/3 but <2/3	15.8	18
	≥2/3	5.3	6
Location of TM perforation	Anterior	65.8	75
	Inferior	7.9	9
	Posterior	16.7	19
	Large	5.3	6
	Multiple	4.4	5
Status of contralateral ear	Normal	82.5	94
	Abnormal Atelectatic	6.1	7
	Retracted/Adhesive	2.6	3
	Perforated	8.8	10
Ipsilateral CT finding	Normal middle ear and mastoid	58.5	24
	Sclerotic mastoid only	29.3	12
	Abnormal middle ear and mastoid	12.2	5
Duration for complete healing (weeks, mean±SD)		15.1±12.9	

SD: standard deviation; TM: tympanic membrane; CT: computed tomography

irritated mechanically using the blade of a myringotomy knife but was not trimmed. Under the operating microscope, ethylene oxide gas (Steri-Gas™; 3M, St. Paul, USA)-sterilized cigarette paper was placed over the perforation using alligator forceps. Subsequently, a cotton-tipped applicator soaked in steroid-containing ciprofloxacin



**Figure 1.** Classification of the location of perforation on the tympanic membrane in this study. Perforation anterior to malleus (1), perforation posterior to malleus (2), perforation inferior to umbo (3), larger perforation (4), and multiple perforations.



**Figure 2.** Mean age and 95% confidence interval for the success and failure groups of patch grafting. Student's t-test showed a significant difference between the success group of  $39.0 \pm 20.2$  years of age and the failure group of  $48.6 \pm 16.6$  years of age.

ear drops (Cetraxal Plus Ear Drops; Pharmatronic Co., Seoul, South Korea) was used to wet the paper and enable it to adhere to the remaining TM. After the procedure, patients were prescribed only oral antibiotics for less than 1 week.

The perforation was inspected every 2 weeks during the first month and every month thereafter until at least 1 year after the paper patch grafting. If necessary, additional applications of paper patches were performed as described above during the follow-up period (two times in 35 cases, three times in 7 cases, and four times in 3 cases).

Complete healing of the perforation was confirmed when 1. complete closure of the perforation was observed under the operating microscope and 2. a tympanogram of type A or C was acquired for further verification.

#### Statistical Analysis

Student's t-test and Pearson's Chi-square test were performed using IBM-SPSS statistics software (version 19, IBM Corporation; New York,

USA). Multivariate analysis to determine the relative contributions of many clinical factors to successful paper patch grafting was performed using the binary logistic regression model. The data were described as mean  $\pm$  standard deviation. P values less than 0.05 were considered to be statistically significant.

#### RESULTS

The data of 114 patients was analyzed. The total success rate of paper patch grafting was 72.8% (83 of 114 cases). Table 1 summarizes the data of 114 patients that were analyzed in this study. The most common cause of TM perforation in this study was trauma; however, there was a difference in etiology between the right and left sides. The most common cause of right TM perforation was infection/inflammation (50.0%), followed by trauma (43.2%), iatrogenic etiology (4.5%), and unknown etiology (2.3%). However, trauma was the most common cause of left TM perforation (50.0%), followed by infection/inflammation (41.4%), unknown etiology (7.1%), and iatrogenic etiology (1.4%).

#### Sub-Analysis by Etiology

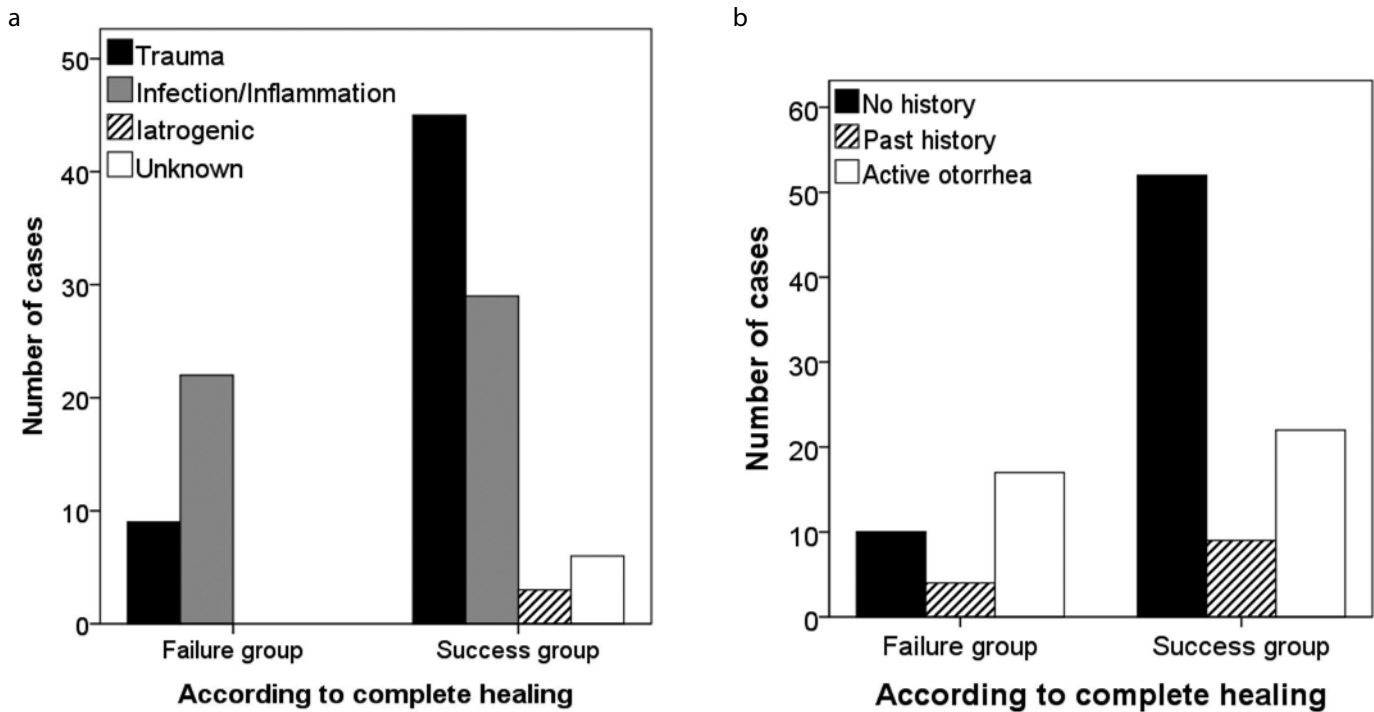
In cases of traumatic TM perforation, the mean age was  $31.4 \pm 19.7$  years, the onset was acute in 92.4% cases, there was no history of otorrhea in 94.4% cases, the size of TM perforation was less than one third of the TM in 64.8% cases, TM perforation was anterior in 61.1% cases, the contralateral ear was normal in 94.2% cases, and ipsilateral CT finding was normal in 75% cases. TM perforation completely healed in 83.3% cases, and the mean duration of complete healing was  $12.0 \pm 10.6$  weeks.

For infectious/inflammatory TM perforation, the mean age was  $51.6 \pm 14.2$  years, the onset was acute in 54.94% and subacute in 29.4% cases, active otorrhea was found in 72.5% cases, the size of TM perforation was less than one third of the TM in 90.2% cases, TM perforation was anterior in 68.6% cases, the contralateral ear was normal in 76.5% cases, and ipsilateral CT finding was normal in 50% cases. TM perforation completely healed in 56.9% cases, and the mean duration of complete healing was  $18.4 \pm 15.8$  weeks.

#### Comparison between the Success and Failure Groups of Complete Healing

Student's t-test showed that patients in the failure group were significantly older than those in the success group ( $39.0 \pm 20.2$  years of age in the success group and  $48.6 \pm 16.6$  years of age in the failure group;  $p=0.012$ ) (Figure 2). Pearson's Chi-square test revealed a significant difference between the success and failure groups in the etiology of TM perforation as well as in the history of otorrhea ( $p=0.005$  and  $0.010$ , respectively). The proportion of cases of traumatic TM perforation was higher in the success group than in the failure group. The proportion of cases of infectious/inflammatory TM perforation was higher than that of traumatic TM perforation in the failure group (Figure 3a). The proportion of cases without otorrhea history was higher in the success group than in the failure group. The proportion of cases with active otorrhea was higher than those with no or past history of otorrhea in the failure group (Figure 3b).

Pearson's Chi-square test failed to show any statistical difference in gender, laterality, time interval between TM perforation and patch grafting, size of TM perforation, location of TM perforation, status of



**Figure 3. a, b.** Differences in the etiology of tympanic membrane perforation (a) and the history of otorrhea between the success and failure groups of patch grafting (b).

contralateral ear, and ipsilateral CT finding between the success and failure groups ( $p=0.296, 1.000, 0.216, 0.749, 0.472, 1.000, \text{ and } 0.502$ , respectively).

Binary logistic regression analysis demonstrated that a history of otorrhea was the only explanatory variable of successful paper patch grafting for TM perforation. Compared with patients with active otorrhea on the initial visit, the odds ratio of patients without a history of otorrhea for successful paper patch grafting was 3.121 (95% CI=1.147 to 8.496;  $p=0.026$ ). Compared to cases who had active otorrhea on the initial visit, a history of previous otorrhea but no otorrhea on the initial visit did not change the likelihood of successful paper patch grafting (odds ratio=1.773 (95% CI=0.462 to 6.802);  $p=0.404$ ). Compared with patients without a history of otorrhea, the likelihood of successful paper patch grafting for patients who had otorrhea in the past but not on the initial visit was not significantly different (odds ratio=0.568 (95% CI=0.137 to 2.353);  $p=0.435$ ).

#### Analysis Focused on Chronic TM Perforations

This study included 13 cases with chronic TM perforation lasting for 3 months and longer. The mean age was  $47.8 \pm 18.8$  years; active otorrhea was found in 30.8% cases; the size of TM perforations was less than one third of the TM in 100% cases; TM perforation was anterior in 61.5% cases; the contralateral ear was normal in 61.5% cases; and ipsilateral CT finding was normal in 40% cases. The long-term success rate was 84.6%, and the mean duration of complete healing was  $22.8 \pm 17.4$  weeks.

Thirteen cases with chronic TM perforations were compared with 101 non-chronic cases. Between the 13 chronic and 101 non-chronic cases, there were no significant differences in age, gender, laterality, size of TM perforation, location of TM perforation, status of contralateral

ear, ipsilateral CT finding, and successful closure rate ( $p=0.236, 0.080, 0.243, 0.141, 0.394, 0.051, 0.239, \text{ and } 0.509$ , respectively).

#### DISCUSSION

The long-term success rate of paper patch grafting for TM perforation was 72.8% in this study. Our success rate is similar to or slightly higher than those in previous reports<sup>[1,2,4]</sup>. However, our general success rate is lower than that reported by Lou et al.<sup>[6]</sup> In their study, almost 98% of 504 cases with traumatic TM perforations were acute onset (within 1 month after a trauma), and a spontaneous healing rate of 89% cases was reported. In this study, the long-term success rate reached 86.0% only for 50 cases with traumatic TM perforations within 3 weeks after onset. Our success rate of paper patch grafting for traumatic TM perforations were acute onset is still lower than that of Lou et al.<sup>[6]</sup> and this difference in success rate suggests that there may be other prognostic factors apart from etiology.

The strength of this study is that we evaluated the predictive clinical factors for successful paper patch myringoplasty for TM perforation. Previous studies reported the size of TM perforations as the predictor for successful paper patching. Golz et al.<sup>[1]</sup> reported that the closure rate of paper patch myringoplasty depended on the perforation size in the cases of chronic perforations of more than 1 year. Lee et al.<sup>[2]</sup> also reported that TM perforations of less than 4 mm show the highest closure rate, significantly in cases of chronic otitis media. However, these two studies analyzed only the size of TM perforation as the outcome predictor and did not evaluate any other clinical factors.

The study by Park et al.<sup>[4]</sup> had a study design and analysis similar to our study. They reported that perforation size was the only outcome predictor of paper patch myringoplasty, although they analyzed predictive factors, including age, sex, affected ear, hearing level, dura-

tion of perforation, cause, location and size of perforation, relationship between the perforation border and the malleus, status of TM surface, and number of patch applications. Contrastingly, our study revealed that patient's age, etiology of TM perforation, and history of otorrhea were the important predictive factors for successful paper patch myringoplasty for TM perforation. There were three major differences between the materials and methods of the two studies. 1. The candidates of Park et al. [4] had chronic perforations lasting for more than 3 months; however, our study included all TM perforations regardless of duration. 2. Park et al. [4] performed paper patch grafting only on ears without otorrhea and middle ear/mastoid pathology by otoendoscopy and temporal bone CT scan, but we performed the operation on infection-free and dry ears regardless of otorrhea history and ipsilateral CT finding. 3. Park et al. [4] defined perforation persisting after three patching attempts within 3 months as a treatment failure; however, we followed up the patients for 1 year and longer and did not limit the number of patching attempts.

Our cases consisted of cases of traumatic perforation (47.4%) and of infectious/inflammatory perforation (44.7%). Most clinicians encountered numerous infectious/inflammatory perforations in their clinics, and most of the infectious/inflammatory perforations develop from myringitis or acute suppurative otitis media. This study failed to show any difference between chronic perforations (lasting for more than 3 months) and other perforations and demonstrated a high success rate of paper patch myringoplasty in chronic TM perforation, which is similar to the study of Park et al. [4] This study suggested that paper patch myringoplasty can be attempted for chronic TM perforation if the TM perforation is smaller than one third of the TM and dry.

In this study, the likelihood of successful paper patch grafting was 3.121 times higher in patients without otorrhea history than in patients who had active otorrhea on the initial visit. This study showed that a previous history of otorrhea but no otorrhea on the initial visit did not change the likelihood of successful paper patch grafting compared to cases who had active otorrhea on the initial visit [odds ratio=1.773 (95% CI=0.462 to 6.802);  $p=0.404$ ] or cases without otorrhea history [odds ratio=0.568 (95% CI=0.137 to 2.353);  $p=0.435$ ]. This suggests that clinicians do not have to be concerned about a previous history of otorrhea if chronic otitis media is not shown by CT.

The limitation of this study was the study design. This study was retrospective and did not include any control group with observation or formal myringoplasty. In addition, this retrospective study did not include some patients who declined paper patch grafting or who chose alternative treatment, including formal myringoplasty. The second limitation was that this study did not investigate clinically assessed hearing levels using pure tone audiometry because pure tone audiometry was not included in some cases. Another limitation of this study was the small number of chronic cases. The hypothesis of this study was that office-based patch grafting might be successful

for TM perforation regardless of disease duration or etiology. However, this study included only 13 chronic cases among the total 114 cases, which was too small a number to draw a conclusion.

Of the 114 TM perforations, including 54 traumatic, 51 infectious/inflammatory, 6 of unknown etiology, and 3 iatrogenic, 72.8% were completely healed by paper patch grafting in an outpatient setting over 1 year. This study showed that the patient's age, etiology, and otorrhea were the significant factors determining the success of patch grafting for the management of simple TM perforation. Younger patients, traumatic TM perforation, and no history of otorrhea can result in successful paper patch grafting regardless of the etiology and the duration of TM perforation. This study supports that clinicians should attempt paper patch grafting in cases of small, dry, chronic TM perforations before formal surgical myringoplasty.

**Ethics Committee Approval:** Ethics committee approval was received for this study from the ethics committee of Uijeongbu St. Mary's Hospital/IRB #UC15RISI0039.

**Informed Consent:** N/A.

**Peer-review:** Externally peer-reviewed.

**Author Contributions:** Concept - D.H.L.; Design - D.H.L.; Data Collection and/or Processing - D.H.L., J.K., E.S., Y.K., Y.C.; Analysis and/or Interpretation - D.H.L., J.K., E.S., Y.K., Y.C.; Literature Search - E.S., Y.K., Y.C.; Writing Manuscript - D.H.L., J.K.; Critical Review - D.H.L., J.K., E.S., Y.K., Y.C.

**Conflict of Interest:** No conflict of interest was declared by the authors.

**Financial Disclosure:** The authors declared that this study has received no financial support.

## REFERENCES

1. Golz A, Goldenberg D, Netzer A, Fradis M, Westerman ST, Westerman LM, et al. Paper patching for chronic tympanic membrane perforations. *Otolaryngol Head Neck Surg* 2003; 128: 565-70. [CrossRef]
2. Lee SH, Jin SM, Lee KC, Kim MG. Paper-patch myringoplasty with CO2 laser for chronic TM perforation. *Eur Arch Otorhinolaryngol* 2008; 265: 1161-4. [CrossRef]
3. Roosli C, Sim JH, Chatzimichalis M, Huber AM. How does closure of tympanic membrane perforations affect hearing and middle ear mechanics? An evaluation in a patient cohort and temporal bone models. *Otol Neurotol* 2012; 33: 371-8. [CrossRef]
4. Park SN, Kim HM, Jin KS, Maeng JH, Yeo SW, Park SY. Predictors for outcome of paper patch myringoplasty in patients with chronic tympanic membrane perforations. *Eur Arch Otorhinolaryngol* 2015; 272: 297-301. [CrossRef]
5. Dursun E, Dogru S, Gungor A, Cincik H, Poyrazoglu E, Ozdemir T. Comparison of paper-patch, fat, and perichondrium myringoplasty in repair of small tympanic membrane perforations. *Otolaryngol Head Neck Surg* 2008; 138: 353-6. [CrossRef]
6. Lou ZC, Lou ZH, Zhang QP. Traumatic tympanic membrane perforations: a study of etiology and factors affecting outcome. *Am J Otolaryngol* 2012; 33: 549-55. [CrossRef]