



Original Article

The Effect of National Pneumococcal Vaccination Program on Incidence of Postmeningitis Sensorineural Hearing Loss and Current Treatment Modalities

Tevfik Sözen , Münir Demir Bajin , Ateş Kara , Levent Sennaroğlu

Department of Otolaryngology, Hacettepe University School of Medicine, Ankara, Turkey (TS, MDB, LS)

Department of Pediatric Infectious Diseases, Hacettepe University School of Medicine, Ankara, Turkey (AK)

ORCID IDs of the authors: T.S. 0000-0003-1491-5060; M.D.B. 0000-0003-1088-4367; A.K. 0000-0002-1654-3232; L.S. 0000-0001-8429-2431.

Cite this article as: Sözen T, Bajin MD, Kara A, Sennaroğlu L. The Effect of National Pneumococcal Vaccination Program on Incidence of Postmeningitis Sensorineural Hearing Loss and Current Treatment Modalities. J Int Adv Otol 2018; 14(3): 443-6.

OBJECTIVES: The aim of the present study was to investigate the effect of the national pneumococcal vaccination program on postmeningitis sensorineural hearing loss (SNHL).

MATERIALS and METHODS: Overall, 2751 patients (2615 cochlear implantation and 136 auditory brainstem implantation) who underwent cochlear implantation (CI) and auditory brainstem implantation (ABI) at a tertiary referral hospital otolaryngology clinic were retrospectively analyzed. One hundred sixteen patients with a history of meningitis were included in the study. Patients were evaluated for their age at the time of surgery, gender, computerized tomography (CT) and magnetic resonance imaging (MRI) findings, implant type, side, and incidence before and after the vaccination program.

RESULTS: When patients with cochlear implants or ABI were examined, the incidence of meningitis-induced hearing loss was 6.2% in the pre-vaccination period and 0.6% in the post-vaccination period. There is a significant difference between them when compared by chi-square test ($p < 0.001$).

CONCLUSION: The most important finding of the present study is the dramatic decrease in the number of CI and ABI surgeries performed in patients with SNHL due to meningitis. This shows the effectivity of pneumococcal vaccination in this special group of patients. If total ossification is detected on CT of patients with postmeningitis, ABI should be preferred to CI.

KEYWORDS: Sensorineural hearing loss, pneumococcal meningitis, cochlear implantation, auditory brainstem implantation

INTRODUCTION

Meningitis infection is one of the most common causes of acquired sensorineural hearing loss (SNHL) ^[1]. SNHL has been reported in 10%-23% of patients with meningitis at various grades ^[1,2]. The most frequent pathogens are *Neisseria meningitidis*, *Streptococcus pneumoniae*, and *Haemophilus influenza* ^[3]. Infection in the subarachnoid space progresses to the cochlea via the internal acoustic canal, hematogenous pathway, and most commonly through the cochlear aqueduct ^[4]. Meningitis-induced labyrinthitis with accompanying inflammation leads to fibrosis and ossification ^[5]. The ossification that occurs in the labyrinth is called "labyrinthine ossification" (LO). Initial involvement of LO is at the basal turn of the cochlea and scala tympani ^[6].

Temporal bone computerized tomography (CT) and temporal bone magnetic resonance imaging (MRI) are used as diagnostic tools in patients with SNHL after meningitis. Ossification is seen as a white area in the cochlea and semicircular canal (SCC) on CT and a loss of fluid signal on MRI. LO begins within 4-8 weeks after meningitis, and ossification is completed in 5 months ^[7].

The placement of the entire electrode in a standard cochlear implant (CI) surgery in patients who begin to develop LO is usually not possible. For this reason, scala vestibuli insertion, cochlear drill out techniques, and double or split array cochlear implants are used in various cases ^[8]. More recently auditory brainstem implantation (ABI) has been used in patients with postmen-

ingitic complete LO when it was not possible to implant cochlear implants. In ABI, the cochlea and cochlear nerve are bypassed, and the cochlear nuclei are stimulated directly in the brainstem [9].

With the inclusion of *S. pneumoniae* and *H. influenzae* vaccinations in the national vaccination program, reduction of meningitis and its complications was aimed. In the present study, the effect of the vaccination program on postmeningitis SNHL, the imaging findings, were investigated, and the treatment modalities of these patients were discussed.

MATERIALS and METHODS

Between 1997 and 2018, 2751 patients (2615 CI and 136 ABI) who underwent cochlear implant and ABI at a tertiary referral hospital were retrospectively analyzed. One hundred sixteen patients with a history of meningitis were included in the study. Patients were evaluated for their age at the time of surgery, gender, CT and MRI findings, implant type, side of intervention, and also incidence of SNHL before and after the vaccination program. CT imaging was performed on a 4-channel multidetector CT scanner (SOMATOM Plus 4 Volume Zoom; Siemens, Erlangen, Germany). MRI examinations were performed by either a 3T (Allegra; Siemens) or a 1.5 T scanner (Symphony, Siemens) using a standard head coil. CT scans and MRI examinations of the temporal bones were analyzed by an experienced neuroradiologist and neuro-otologist using the axial sections.

Table 1. The type of implantation and CT findings

| CT | Implantation type (n%) | |
|----------------------|------------------------|----------|
| | CI | ABI |
| No ossification | 73 (62.9%) | 0 |
| Partial ossification | 30 (5.9%) | 0 |
| Total ossification | 6 (5.2%) | 7 (100%) |
| Total | 109 | 7 |

CT: computerized tomography; CI: cochlear implant; ABI: auditory brainstem implantation

Table 2. The type of implantation and MRI findings

| MRI | Implantation type (n%) | |
|---|------------------------|----------|
| | CI | ABI |
| Normal | 48 (41.4%) | 0 |
| Cochlear fibrosis | 54 (46.6%) | 7 (100%) |
| Lateral SCC fibrosis | 6 (5.2%) | 0 |
| Decrease in scala tympani fluid in basal turn | 1 (0.9%) | 0 |
| Total | 109 | 7 |

MRI: magnetic resonance imaging; CI: cochlear implant; ABI: auditory brainstem implantation

Table 3. The prevalence of SNHL during pre- and post-vaccination periods

| | Pre-vaccination period | Post-vaccination period |
|---------------------------------------|------------------------|-------------------------|
| Incidence of postmeningitis SNHL (n%) | 111/1781 (6.2%) | 5/844 (0.6%) |
| p | | <0.001 |

SNHL: sensorineural hearing loss

In 2008, the pneumococcal vaccine was included in the national vaccination program. To investigate the effect of vaccination on the incidence of meningitis-induced SNHL, two groups were formed from 116 patients with postmeningitis and 2625 patients who underwent cochlear implant and ABI between 1997 and 2018: patients who had SNHL and not been vaccinated and born before 2008 (group 1) and patients who had been vaccinated and born after 2008 (group 2). Inclusion criteria for group 1 were all of the patients' medical records that were searched for pneumococcal vaccination. None of the patients had a history of vaccination. In order to be in group 2, pneumococcal vaccination was mandatory. CT findings were classified as no ossification, partial ossification, and total ossification. MRI findings were classified as normal, cochlear fibrosis, and lateral SCC fibrosis.

CI or ABI surgeries were performed in patients, and the sides of operation were analyzed.

Statistical Analysis

Statistical analysis was performed using The Statistical Package for the Social Sciences (SPSS) 21.0.0 (IBM Corp., Armonk, NY, USA). Chi-square test was used to compare the effect of the pneumococcal vaccination program on meningitis-induced SNHL. Descriptive results were analyzed by frequency tables, and patients who underwent surgery for meningitis according to years were analyzed by Spearman correlation test.

The study protocol was approved by the Hacettepe University Ethics Committee (approval no: GO 18/692-35) in accordance with the Declaration of Helsinki's ethical principles on human experimentation. Written informed consent was not obtained from the patients since this was a retrospective study conducted from the medical records of the patients in which the patients' personal identities were not revealed.

RESULTS

Of the 116 patients included in the study, 60 (51.7%) were male, and 56 (48.3%) were female. Of the patients, 111 were born before 2008, and 5 were born after 2008. Patients' age at the time of surgery was not normally distributed. The minimum is 0, the maximum is 68, and the median is 13.

When CT images of the patients were examined, no ossification was found in 73 (62.9%) patients, partial ossification in 30 (25.9%) patients, and total ossification in 13 (11.2%) patients. MRI showed normal findings in 48 (41.4%) patients, cochlear fibrosis in 61 (52.6%) patients, fibrosis in lateral SCC in 6 (5.1%) patients, and decrease in scala tympani fluid in 1 (0.9%) patient in the basal turn.

One hundred nine (94%) patients had CI, and 7 (6%) patients had ABI. Fifty seven (49.1%) patients had right-sided implantation, 51 (44%) patients had left-sided implantation, and 8 (6.9%) patients were treated bilaterally.

Among 109 CI cases, 73 (62.9%) patients had no ossification findings, 30 patients had partial ossification, and the remaining 6 (5.2%) patients had total ossification. All ABI cases have total ossification according to CT findings (Table 1).

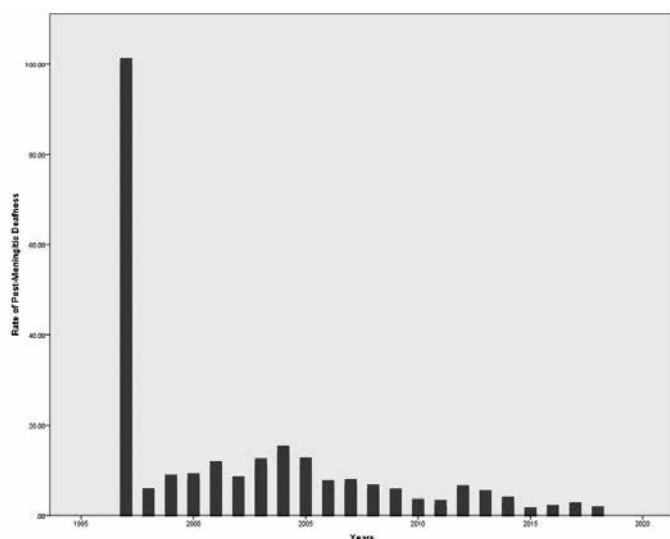


Figure 1. Histogram shows the rate of patients who were implanted due to SNHL after meningitis for years.

Forty-eight (41.4%) patients had normal MRI, 54 (46.6%) patients had cochlear fibrosis, 6 (5.2%) patients had lateral SCC fibrosis, and only 1 patient had decreased scala tympani fluid in the basal turn (Table 2).

There was a very strong negative correlation between year and rate of patients with CI and ABI due to meningitis ($r=-0.837$, $p<0.001$) (Figure 1). It has to be noted that CI surgery was started in our department in November 1997, and only one patient with meningitis was operated in 1997, yielding 100% incidence for that year.

When the effect of the pneumococcal vaccine on meningitis-induced SNHL was examined, meningitis-induced SNHL was seen in 111 of 1781 patients who were born before 2008 and underwent cochlear implant or auditory brainstem implant in our clinic. Of the 844 patients born after 2008, 5 have a meningitis-induced SNHL. Therefore, the pre-vaccination incidence was 6.2%, but after vaccination decreased to 0.6%. There is a significant difference between the two groups ($p<0.001$) (Table 3).

DISCUSSION

N. meningitidis is the most common cause of meningitis infection, but *S. pneumoniae* meningitis is associated more frequently with profound SNHL [3]. Studies showed that changes in the labyrinth begin in the very early stage of infection. For this reason, imaging should also be performed early in patients with postmeningitic SNHL. It is suggested that CT should be done with MRI because CT imaging alone is insufficient to show the early changes in labyrinth [10]. In our study, 62.9% of CT and 41.4% of MRIs had no ossification. On MRI, cochlear fibrosis was detected in 52.6% of the patients. MRI showed fibrosis in lateral SCC in four patients with normal findings on CT, and reduced fluid level in the scala tympani of the basal turn was seen in one patient. For this reason, at the time of diagnosis, MRI is recommended as the first imaging modality in addition to CT in postmeningitic SNHL.

Meningitis-related labyrinthitis is associated with hair cell loss and spiral ganglion damage, followed by ossification. Ossification most

commonly begins with the scala tympani of the basal turn. Smullen and Balkany have classified labyrinth ossification based on radiological and surgical findings: round window involvement as grade 1, basal turn involvement as grade 2, and basal turn involvement $>180^\circ$ as grade 3 [11]. In the present study, CT findings were classified as no ossification, partial ossification, and total ossification (LO).

The cochlear implant is the most effective treatment for profound SNHL for nearly 40 years. In patients with meningitis, when signs of cochlear fibrosis begin to develop on MRI, CI is recommended as early as possible. The method to be used for implantation varies according to the degree of ossification. In cases where the basal turn has incomplete ossification, full insertion of a CI can be achieved after the lumen is enlarged with the aid of a drill and various angled pics. Scala vestibuli insertion, double or split array electrode implantation, and middle and basal turn cochleostomy can be performed if there is an advanced ossification in the scala tympani and basal turn. In advanced cases of LO, a circummodiolar drill out is required for implantation [12].

The most important factor determining the benefit of CI in postmeningitic SNHL is the degree of ossification. Data from previous studies showed that the result of cochlear implant is better in postmeningitic cochlea when there is no ossification. If drill out is required due to ossification, the benefit is less. However, some data suggest that patients still benefit from cochlear implants even if they are not fully inserted into cochlea [13, 14].

In recent years, auditory brainstem implantation has become the first treatment option in patients with total labyrinthine ossification, beginning to be used as a treatment modality for patients with advanced sensorineural hearing loss. When the literature is examined, it is seen that with the education and lip reading, disyllabic word score and sentence score of LO patients reached to 100% and 93% respectively after ABI [9, 15].

Since 2006, ABI has been applied in our hospital in patients where CI cannot be performed due to severe cochlear anomaly or cochlear nerve aplasia / hypoplasia. In this study, ABI was applied to all of the 7 postmeningitic patients who were examined after 2008, had LO and total fibrosis on CT and MRI. The pneumococcal vaccine was included in the national vaccination program in 2008. In this study, the effect of pneumococcal vaccine on meningitis induced SNHL was examined and there was a statistically significant decrease in incidence after vaccination. Currently, the incidence of patients who underwent implantation due to meningitis induced SNHL has decreased to 0.6%. Yet, after 2008 we had 7 patients with postmeningitic SNHL, most probably due to other rare causes of meningitis or broken vaccine cold chain. Nevertheless, this marked decrease in incidence proves the effectiveness of national vaccination program.

CONCLUSION

The most important finding of the present study is the dramatic decrease in the number of CI and ABI surgeries performed in patients with SNHL due to meningitis. This shows the effectiveness of pneumococcal vaccination in this special group of patients.

Ethics Committee Approval: Authors declared that the research was conducted according to the principles of the World Medical Association Decla-

ration of Helsinki "Ethical Principles for Medical Research Involving Human Subjects", (amended in October 2013).

Informed Consent: Written informed consent was not obtained from the patients since this was a retrospective study conducted from the medical records of the patients in which the patients' personal identities were not revealed.

Peer-review: Externally peer-reviewed.

Author Contributions: Concept – T.S., M.D.B., L.S.; Design – T.S., M.D.B., L.S.; Supervision – L.S., A.K.; Resource – T.S., M.D.B., L.S.; Materials – T.S., M.D.B., L.S.; Data Collection and/or Processing – T.S., M.D.B., L.S.; Analysis and/or Interpretation – T.S., M.D.B., L.S.; Literature Search – T.S., M.D.B., L.S.; Writing – T.S., M.D.B., L.S.; Critical Reviews – L.S.

Conflict of Interest: The authors have no conflict of interest to declare.

Financial Disclosure: The authors declared that this study has received no financial support.

REFERENCES

- Nadol JB Jr. Hearing loss as a sequela of meningitis. *Laryngoscope* 1978; 88: 739-55. [\[CrossRef\]](#)
- Dodge PR, Davis H, Feigin RD, Holmes SJ, Kaplan SL, Jubelirer DP et al. Prospective evaluation of hearing impairment as a sequela of acute bacterial meningitis. *N Engl J Med* 1984; 311: 869-74. [\[CrossRef\]](#)
- Douglas SA, Sanli H, Gibson WP. Meningitis resulting in hearing loss and labyrinthitis ossificans-does the causative organism matter? *Cochlear Implants Int* 2008; 9: 90-6. [\[CrossRef\]](#)
- Merchant SN, Gopen Q. A human temporal bone study of acute bacterial meningogenic labyrinthitis. *Am J Otol* 1996; 17: 375-85.
- Fortnum HM. Hearing impairment after bacterial meningitis: a review. *Arch Dis Child* 1992; 67: 1128-33. [\[CrossRef\]](#)
- Steenerson RL, Gary LB, Wynens MS. Scala vestibuli cochlear implantation for labyrinthine ossification. *Am J Otol* 1990; 11: 360-3.
- Novak MA, Fifer RC, Barkmeier JC, Firszt JB. Labyrinthine ossification after meningitis: its implications for cochlear implantation. *Otolaryngol Head Neck Surg* 1990; 103: 351-6. [\[CrossRef\]](#)
- Lenarz T, Büchner A, Tasche C, Cristofoli T et al. The results in patients implanted with the nucleus double array cochlear implant: pitch discrimination and auditory performance. *Ear Hear* 2002; 23: 90-101. [\[CrossRef\]](#)
- Colletti V, Fiorino FG, Carner M, Miorrelli V, Guida M, Colletti L. Auditory brainstem implant as a salvage treatment after unsuccessful cochlear implantation. *Otol Neurotol* 2004; 25: 485-96. [\[CrossRef\]](#)
- Isaacson B, Booth T, Kutz JW Jr, Lee KH, Roland PS. Labyrinthitis ossificans: How accurate is MRI in predicting cochlear obstruction? *Otolaryngol Head Neck Surg* 2009; 140: 692-6. [\[CrossRef\]](#)
- Nadol JB, Hsu W. Histopathologic correlation of spiral ganglion. *Ann Otol Rhinol Laryngol* 1991; 100: 712-6. [\[CrossRef\]](#)
- Balkany T, Gantz BJ, Steenerson RL, et al. Systematic approach to electrode insertion in the ossified cochlea. *Otolaryngol Head Neck Surg* 1996; 114: 4-11. [\[CrossRef\]](#)
- Steenerson RL, Gary LB. Multichannel cochlear implantation in children with cochlear ossification. *Am J Otol* 1999; 20: 442-4.
- El-Kashlan HK, Ashbaugh C, Zwolan T, Telian SA. Cochlear implantation in prelingually deaf children with ossified cochleae. *Otol Neurotol* 2003; 24: 596-600. [\[CrossRef\]](#)
- Grayeli AB, Bouccara D, Kalamarides M, et al. Auditory brainstem implant in bilateral and completely ossified cochlea. *Otol Neurotol* 2003; 24: 79-82. [\[CrossRef\]](#)