

Cerebellopontine Angle Surgery by the Retrosigmoid Approach: Our Experience in Elderly Patients

Jacques Magnan, M.D., Arnaud Deveze, M.D., Hidemi Miyazaki, M.D., Francesco Berni Canani, M.D.

From the Department of ENT, North University Hospital, Marseille, France (J. Magnan, A. Deveze, H. Miyazaki); Department of ENT, The Jikei University School of Medicine, Tokyo, Japan (H. Miyazaki); and Department of ENT, Santobono Hospital, Naples, Italy (F. B. Canani).

Correspondence:

Prof. Jacques Magnan
ENT Department,
Hopital Nord
Chemin des Bourrelly
13915 Marseille, France.

Tel: +33 491 96 86 75
Fax: +33 491 96 81 98
e-mail: j magnan@ap-hm.fr

Submitted: December 1, 2004
Accepted: December 3, 2004

Mediterr J Otol 2005;1:00-00.

Copyright 2005 © The Mediterranean
Society of Otology and Audiology

OBJECTIVES: We retrospectively evaluated the clinical results and peri- and postoperative complications of otoneurosurgical procedures by the retrosigmoid approach performed in a series of patients aged 70 or over.

PATIENTS AND METHODS: From January 1993 to January 2004, 111 consecutive patients (age range 70 to 83 years) underwent surgery with the use of the retrosigmoid approach for trigeminal neuralgia (n=36), hemifacial spasms (n=35), Ménière's disease (n=13), tinnitus (n=2), and tumors of the cerebellopontine angle (CPA) (n=26). One patient with Ménière's disease also had an asymptomatic meningioma of the CPA.

RESULTS: The time for complete recovery for hemifacial spasms was usually less than three months. Hemifacial spasms recurred in six patients after a mean of eight months, five of whom underwent revision surgery that was successful in three. The overall rate for complete recovery was 91.4%. For trigeminal neuralgia, recurrences or failure were encountered in eight patients, of whom four underwent revision surgery resulting in recovery in two, and significant improvement in one. The overall rates for complete relief and significant improvement were 66.7% and 19.4%, respectively. Problems arising from the otoneurosurgical procedures were relatively low, accounting for 13.8%. Mortality did not occur. Of 16 postoperative problems encountered in 15 patients, only six were life threatening. The most common problems were cerebrospinal fluid collection/ leakage (n=4), wound infection/inflammation (n=3), and deep venous thrombosis (n=3). None of these required revision surgery except for a wound infection.

CONCLUSION: As life expectancy increases, a growing number of elderly patients suffer from neurovascular conflicts and acoustic tumours which are associated with significant deterioration in quality of life. Our results show that minimally invasive retrosigmoid approach is a safe and efficient procedure, even for this fragile population. In this respect, documentation favoring the safety of the retrosigmoid approach may be encouraging for elderly patients in choosing surgical treatment to return to a more desirable level of living.

The progressive increase in life expectancy and improved quality of life, particularly in industrialized countries, have exposed ENT specialists to an increasing number of requests for surgery by elderly patients.

Ménière's disease and the neurovascular conflicts in the cerebellopontine angle (CPA) undoubtedly constitute a disabling disorder for elderly patients, worsening their quality of life and interfering with their performance in working and social life.^[1-3] A neurovascular conflict in the CPA was initially proposed by Dandy, in 1934, as a possible cause of trigeminal neuralgia, and then was suggested by Gardner, in 1960, for the pathogenesis of hemifacial spasms.^[4,5] Progressive development and improvement, in recent decades, in diagnostic imaging techniques such as three-dimensional magnetic resonance imaging (3D-MRI), electrophysiological studies, and video endoscopy of the CPA have made it possible to obtain objective and organic data for the pathogenic interpretation of such disorders.^[6-10] Indications for surgery of neurovascular conflicts are based on a careful clinical assessment of the patient; the onset, intensity, duration, and frequency of the episodes; evolution of the symptoms and trigger factors; and on psychophysical involvement.^[11-15] In Ménière's disease, the criteria for choosing surgery are essentially based on the frequency of the vertigo episodes, the degree of hearing impairment both in the affected ear and the contralateral ear, and on a careful consideration of the patient's emotional state and his/her professional status.^[16-19] Progress in imaging techniques and audiologic tests has led to the early identification of CPA lesions that are often pauci or totally asymptomatic.^[20] Although surgical resection is the treatment of choice for almost all CPA tumors, management of acoustic tumors in the elderly are controversial.^[21-23] Small and medium-sized acoustic neurinomas are to be treated surgically in their growth course. Several age-related factors are to be considered including the remaining life expectancy and general health status of the patient,

and his/her existing capacity to equilibrate postoperatively.^[24]

Progress in otoneurosurgical techniques with the introduction of endoscopic procedures, improvements in anesthesiological techniques, and the increasingly widespread use of intraoperative nerve monitoring devices have expanded the range of elderly patients for surgery, for whom the retrosigmoid approach offers less invasiveness and a significant decrease in operating time and morbidity.

The aim of this retrospective study was to assess the clinical results and peri- and postoperative complications of the retrosigmoid approach performed for trigeminal neuralgia, hemifacial spasms, Ménière's disease, tinnitus, and CPA tumors in a series of patients aged 70 or over.

PATIENTS AND METHODS

From January 1993 to January 2004, a total of 1,141 otoneurosurgery operations were carried out using the retrosigmoid approach. Of these, 111 consecutive patients aged 70 years or above (range 70 to 83 years) were retrospectively evaluated. Distribution of the patients according to ear pathologies is summarized in Table 1.

All the patients were examined by 3DFT-MRI (three-dimensional Fourier transform) with special T₂- (CISS) and T₁-weighted (turbo FLASH) sequences. Magnetic resonance angiography (MRA) was employed in case of a neurovascular conflict. It has been reported that agreement between MRI and intraoperative findings is 92%, with specificity of 3D-MRI being 100% in neurovascular conflicts.^[25]

The mean duration of hemifacial spasms in 35 patients was 11 years. Forty percent of these had been treated with botulinum toxin for short-term relief. In 36 patients with trigeminal neuralgia, the mean duration of the disease was six years, with 90% of the patients having been treated with medical

Table 1. Distribution of 111 patients according to ear pathologies

Disease	No. of patients	%	Male/Female	Mean age	Range
Trigeminal neuralgia	36	32.4	16/20	73.8	70-82
Hemifacial spasm	35	31.5	6/29	72.7	70-83
Ménière's disease	13	11.7	7/6	72.4	70-78
Tinnitus	2	1.8	0/2	70.5	70-71
Cerebellopontine angle tumor	26*	22.5	5/21	73.5	70-78

* One patient with Ménière's disease also had a CPA meningioma.

treatment (carbamazepine) and/or thermocoagulation and alcoholization of Gasser's ganglion. One patient with Ménière's disease had an asymptomatic meningioma in the CPA, that caused no neurologic signs of brain stem compression. Two patients suffering from unilateral tinnitus had already received medical treatment.

Anesthesia. Patients are deeply anesthetized with the use of analgesics, hypnotics, or neuroleptics (propofol, sufentanil). Before opening the dura mater, the patient is hyperventilated to induce hypocapnia ($p\text{CO}_2 < 25 \text{ mgHg}$) so as to reduce intracranial pressure, allowing the CPA to be reached without the need for retractors and with minimal manipulation of the cerebellum. The use of mannitol 20% has become a rare occurrence. The facial nerve is monitored and a perioperative electromyographic evaluation is made.

Surgical technique. The patient is in the supine position, with the head slightly bent and rotated to the contralateral side. The homolateral shoulder is lowered as much as possible to give the surgeon as good a view as possible (Fig. 1a). The retrosigmoid approach with minimum craniotomy, about 2 cm in diameter, affords a direct view of the CPA and an

exposure of the cranial nerves (Fig. 1b). Endoscopy offers a wide panoramic exposure of the CPA, with an improved monoaxial microscopic view. The neurovascular conflict is identified (Fig. 2a) and Teflon patches are interposed to ensure vascular decompression (Fig. 2b).

For the treatment of Ménière's disease, the dissection is carried out on the cochleovestibular nerve to find the cochlear-vestibular cleavage plane near to the porus acusticus. At this point, vestibular fibers are easily identified and separated from the cochlear fibers. Section of the vestibular nerve is performed with microsurgical scissors medial to Scarpa's ganglion.^[26]

Tumors of the CPA included vestibular schwannomas in 23 patients (2 intracanalicular, 15 stage II, and 6 stage III) (Fig. 3), two meningiomas (one was found in a patient with Ménière's disease), and one CPA metastasis from hepatocarcinoma. Growth of all the tumors was observed during a wait and scan period; six patients had persistent vertigo.

These tumors were removed with the use of a minimally invasive retrosigmoid approach, involving exposure of the internal auditory canal and dissection

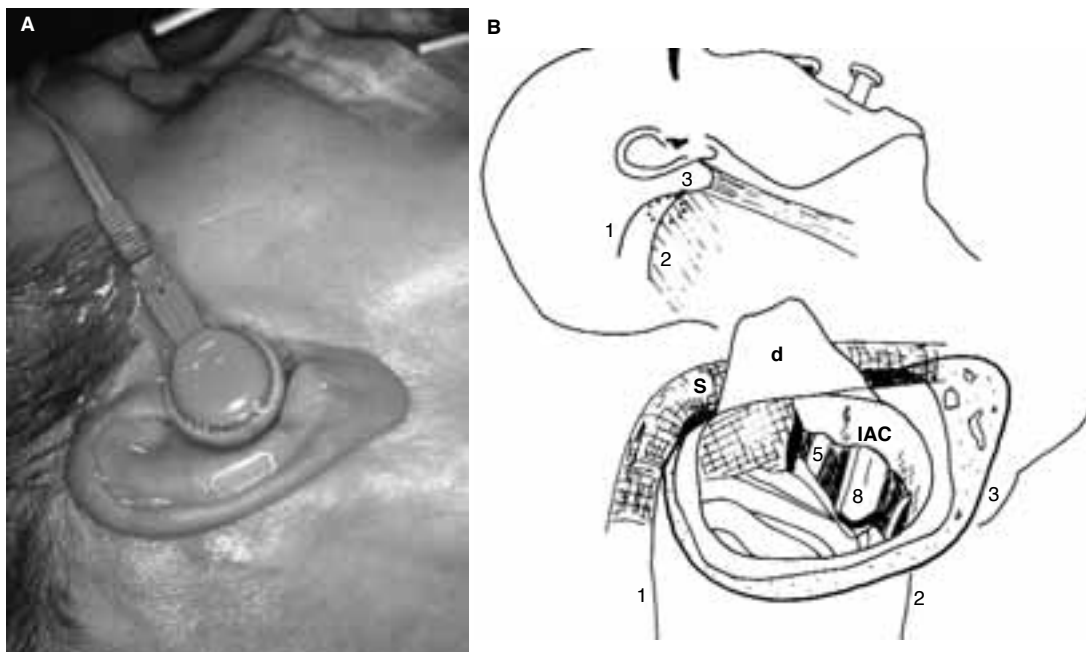


Fig. 1. A. The patient in supine position with the head turned toward the opposite side, exposing the retrosigmoid operative field. Cochlear and facial monitoring set. **B.** Retrosigmoid approach. The craniotomy (dotted line) is inferior to the superior curved occipital line (1) and posterior to the posterior margin of the mastoid process (3). Acousticofacial bundle (8); Trigeminal nerve (5); Posterior wall of the internal auditory canal (IAC); Dura mater (d); Sigmoid sinus (S).

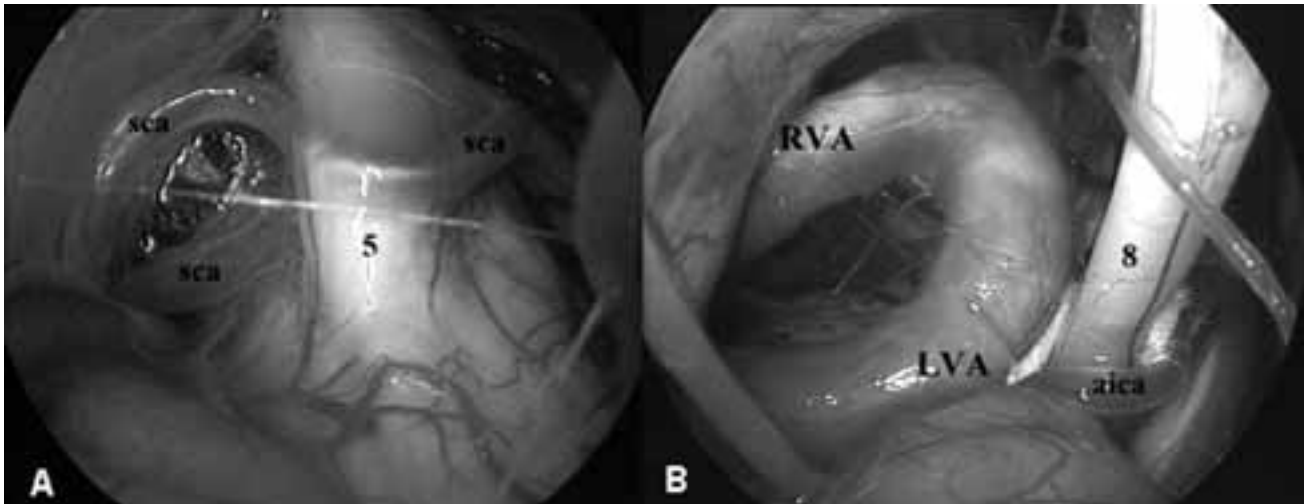


Fig. 2. Two cases of neurovascular conflict. **A.** Right trigeminal neuralgia with distortion of the fifth cranial nerve (5) by the superior cerebellar artery (sca). **B.** Left hemifacial spasm. The facial nerve hidden by the eighth cranial nerve (8) is offended by both the anteroinferior cerebellar artery (aica) and the left vertebral artery (LVA). Right vertebral artery (RVA).

of the tumor by drilling the posterior wall of the internal auditory canal without exposing the posterior semicircular canal. Wherever necessary, endoscopic surgery was utilized at the end of the procedure in order to completely remove any remnants within the internal auditory canal.

RESULTS

Hemifacial spasms. All the patients had improvement in their symptoms in the immediate postopera-

tive course. The time for complete recovery was usually less than three months. One patient had complete recovery 11 months after surgery. Hemifacial spasms recurred in six patients after an average of eight months, five of whom underwent revision surgery that was successful in three. One patient refused revision surgery. The overall rate for complete recovery was 91.4%.

Postoperatively, one patient developed contralateral subdural hematoma and a sural thrombophlebitis and another an extracerebral pneumo-encephalocele, all of which were managed conservatively. Vertigo in one patient and delayed grade II facial paralysis (Bell's palsy) in two patients completely disappeared one month after surgery. One patient complained of Arnold's neuralgia in the occipital territory.

Trigeminal neuralgia. Total relief of pain was achieved in 22 patients (61.1%) and improvement in its severity in six patients (16.7%) who had residual pain controlled by medical therapy. Failure (immediate or delayed) was encountered in eight patients (22.2%), of whom four underwent revision surgery resulting in recovery in two patients and significant improvement in one. One patient required partial trigeminal rhizotomy. The overall rates for complete relief and significant improvement were 66.7% and 19.4% respectively.

No serious neurologic, cardiopulmonary, or circulatory problems were detected. Wound problems occurred in four patients: subcutaneous cerebrospinal fluid collections detected in two patients were suc-

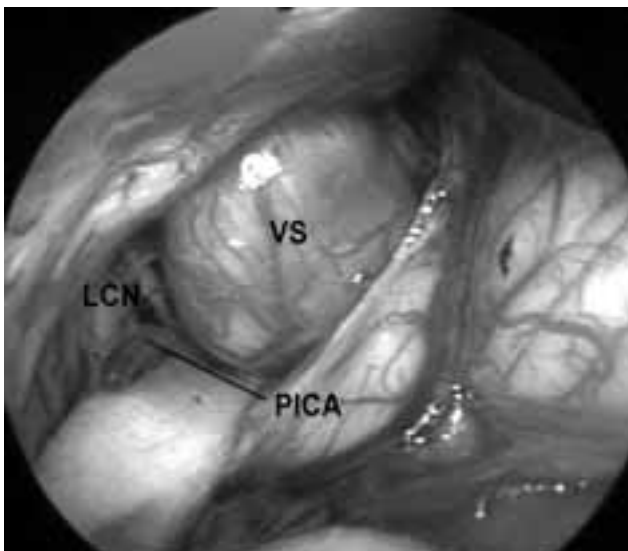


Fig. 3. The left ear. Stage III vestibular schwannoma (VS) in a 77-year-old woman. The lower cranial nerves (LCN) are protected with the use of a cottonoid.

Table 2. Postoperative problems and their influence on the outcome

Complication	No. of problems	Treatment	Influence on outcome
Cerebrospinal fluid collection / leakage	4	Conservative	None
Wound infection / inflammation	3	Conservative in 2. Debridement under local anesthesia in 1.	Lengthened hospital stay
Deep venous thrombosis	3	Anticoagulation for 3 months	Pulmonary embolism without respiratory failure (1 patient)
Arnold's neuralgia	2	Medical treatment	None
Subdural hematoma (contralateral to the side of surgery)	1	Conservative	Lengthened hospital stay
Pneumo-encephalocele	1	Conservative	Lengthened hospital stay
Seizure	1	Anti-epileptic therapy for 1 month to prevent recurrence	None
Intestinal subocclusion	1	Conservative	Lengthened hospital stay

cessfully managed conservatively (compressive dressing, acetazolamide); one patient developed foreign-body inflammatory reaction one month after surgery due to the use of nonabsorbable suture; wound infection seen in another patient was resolved by debridement under local anesthesia. Two patients had mild facial hyperesthesia and intense headache attacks, respectively, which were controlled with medical therapy. Finally, the onset of seizures in a male patient in the immediate postoperative period was attributed to a past severe cranial trauma in his childhood.

Ménière's disease and vestibulocochlear vascular compression. Relapse of vertigo was seen in only one patient who refused a subsequent operation. Three patients with Ménière's disease experienced a slight unbalance after surgery. One female patient underwent vestibular neurectomy for Ménière's disease and total exeresis for accompanying stage II meningioma, after which she got rid of vertigo attacks without any impairment to other cranial nerves.

Cerebellopontine angle tumors. All but two schwannomas extended into the extracanalicular space. Total exeresis of the lesion was performed in all cases except for the patient with metastasis from hepatocarcinoma. The patient with petroclival meningioma had transient diplopia preoperatively without any other neurologic signs. After total removal of the lesion, she developed deep venous thrombosis and pulmonary embolism.

Seven patients sustained postoperative anacusis. Three patients had transient paralysis of the facial nerve (grade II). Of these, one developed dysfunction of the intermedius nerve (dry eye). This patient and another had densely adherent tumors and sustained postoperative anacusis. In one patient who underwent

surgery for cochlear schwannoma of stage II, cerebrospinal fluid leakage was detected through the wound site and was treated with compressive dressing.

DISCUSSION

As life expectancy increases, a growing number of elderly patients become candidates of surgical therapy for neurotological disorders such as vertigo, hemifacial spasm, trigeminal neuralgia, and for expansive CPA lesions.

In this series of 111 patients at the age of 70 years or above, when the above-mentioned disease-related postoperative events, including facial nerve disorders, anacusis, deterioration in the hearing level, balance problems, and headache are excluded, problems arising from the surgical approach and the technique seem to be relatively low, accounting for 13.8% (Table 2). Of 16 postoperative problems encountered in 15 patients, only six were life threatening. None of these patients required revision surgery except for one with a wound infection.

Hemifacial spasms or trigeminal neuralgia in the elderly population are associated with significant deterioration in quality of life, making it difficult for the patient to lead a normal working and social life. Medical therapy is often ineffective and is associated with well-documented adverse effects. Through improved imaging techniques, however, it is now possible to demonstrate the cause of such disorders, namely a neurovascular conflict. It was considered that 65 years was the age-limit for an intracranial procedure. Age is no longer a selective criteria for such a functional surgery.

It has been a common belief for some years that vertigo episodes in Ménière's disease are expected to undergo a spontaneous decrease or cessation as age increases. However, this is in contradiction to several published series and the authors' experience. In addition, elderly people are far more prone to falls due to sudden vertigo episodes and unsteadiness results in significant increases in the incidence of severe physical injuries such as fractures. For these patients, although chronological age is important, one must also take into account the physiological age assessed in terms of physical activity levels and general health of the individual and his/her social and working engagements.

In this study, none of the 13 patients suffered from recurrent vertigo, with only three patients having some balance problems after surgery. Hence, surgical treatment of pathologies such as neurovascular conflicts that are associated with intractable vertigo with serviceable hearing is now a real reality rather than a relative reality in the elderly. In particular, the retrosigmoid approach offers the best and easiest access to the acousticofacial nerve bundle for selective vestibular neurectomy and neurovascular decompression, with a very low incidence of complications.

As human longevity increases, and with advances in imaging techniques, more and more neurotologists are confronting with a growing population of elderly people with CPA tumors, especially acoustic neuromas. In this age group, the factors to be considered when making decisions not only include tumor size, growth pattern, and residual hearing, but also general health, compliance, and the desire of the patients. Our experience clearly showed that total removal of the lesion through the retrosigmoid approach was associated with no severe peri- or postoperative complications in all the patients, and the mean hospital stay was eight days.

In conclusion, otoneurosurgery in elderly patients undoubtedly requires a close collaboration between anesthesiologists and surgeons in order to achieve the best results with minimum perioperative morbidity and mortality. If it were not for the introduction of the most recent anesthesiologic techniques, the continuous intraoperative monitoring of the cranial nerves and vital parameters such as those of cardiopulmonary and vascular, such delicate operations

usually lasting for a long time would not be feasible in very close proximity to the vital structures of the brain stem in elderly patients. The retrosigmoid approach, together with the use of endoscopy, has made it possible to extend the range of eligibility of elderly patients for surgery in the cerebellopontine angle, with a significant reduction in operating time and morbidity.

REFERENCES

1. Rubenstein LZ, Robbins AS, Schulman BL, Rosado J, Osterweil D, Josephson KR. Falls and instability in the elderly. *J Am Geriatr Soc* 1988;36:266-78.
2. Venna N. Dizziness, falling, and fainting: differential diagnosis in the aged (Part I). *Geriatrics* 1986; 41:30-42.
3. Greer M. How serious is dizziness? *Geriatrics* 1981; 36:34-42.
4. Dandy WE. Concerning the cause of trigeminal neuralgia. *Am J Surg* 1934;24:447-55.
5. Gardner WJ, Sava GA. Hemifacial spasm: a reversible pathophysiologic state. *J Neurosurg* 1962;19:240-7.
6. Adler CH, Zimmerman RA, Savino PJ, Bernardi B, Bosley TM, Sergott RC. Hemifacial spasm: evaluation by magnetic resonance imaging and magnetic resonance tomographic angiography. *Ann Neurol* 1992;32:502-6.
7. Daniels DL, Pech P, Pojunas KW, Kilgore DP, Williams AL, Haughton VM. Trigeminal nerve: anatomic correlation with MR imaging. *Radiology* 1986;159:577-83.
8. Deimling M, Laub GA. CISS (Constructive interferences in steady state). In: Book of abstracts. Eighth Annual Meeting of the Society of Magnetic Resonance in Medicine. 1989; Amsterdam, The Netherlands. Vol. 1, Berkeley, CA: Society of Magnetic Resonance in Medicine; 1989. p. 842.
9. Magnan J, Chays A, Caces F, Lepetre C, Cohen JM, Belus JF, et al. Contribution of endoscopy of the cerebellopontine angle by retrosigmoid approach. Neuroma and vasculo-nervous compression. [Article in French] *Ann Otolaryngol Chir Cervicofac* 1993;110:259-65.
10. Magnan J, Chays A, Lepetre C, Pencroffi E, Locatelli P. Surgical perspectives of endoscopy of the cerebellopontine angle. *Am J Otol* 1994;15:366-70.
11. Magnan J, Caces F, Locatelli P, Chays A. Hemifacial spasm: endoscopic vascular decompression. *Otolaryngol Head Neck Surg* 1997;117:308-14.
12. Jannetta PJ. Neurovascular compression in cranial nerve and systemic disease. *Ann Surg* 1980;192:518-25.
13. Jannetta PJ, Resnick D. Cranial rhizopathies. In: Youmans JR, editor. *Neurological surgery*. 4th ed. Philadelphia: W. B. Saunders; 1996. p. 3563-74.

14. Jannetta PJ. Microvascular decompression. In: Rovit R, Murali R, Jannetta PJ, editors. Trigeminal neuralgia. Baltimore: Williams & Wilkins; 1990. p. 201-22.
15. Barker FG 2nd, Jannetta PJ, Bissonette DJ, Shields PT, Larkins MV, Jho HD. Microvascular decompression for hemifacial spasm. *J Neurosurg* 1995;82:201-10.
16. Silverstein H, Norrell H, Haberkamp T. A comparison of retrosigmoid IAC, retrolabyrinthine, and middle fossa vestibular neurectomy for treatment of vertigo. *Laryngoscope* 1987;97:165-73.
17. Zini C, Gandolfi A, Piazza F. Les voies suspétreuse élargie et rétrosigmoïde: indications et détails techniques. *Rev Laryngol Otol Rhinol* 1988;109 Suppl:173.
18. De la Cruz A, McElveen JT Jr. Hearing preservation in vestibular neurectomy. *Laryngoscope* 1984;94:874-7.
19. Dayal VS, Proctor T. Labyrinthectomy in the elderly. *Am J Otol* 1995;16:110-4.
20. Casselman JW, Kuhweide R, Deimling M, Ampe W, Dehaene I, Meeus L. Constructive interference in steady state-3DFT MR imaging of the inner ear and cerebello-pontine angle. *AJNR Am J Neuroradiol* 1993;14:47-57.
21. Nedzelski JM, Canter RJ, Kassel EE, Rowed DW, Tator CH. Is no treatment good treatment in the management of acoustic neuromas in the elderly? *Laryngoscope* 1986;96:825-9.
22. Silverstein H, McDaniel A, Norrell H, Wazen J. Conservative management of acoustic neuroma in the elderly patient. *Laryngoscope* 1985;95(7 Pt 1):766-70.
23. Glasscock ME 3rd, Pappas DG Jr, Manolidis S, Von Doersten PG, Jackson CG, Storper IS. Management of acoustic neuroma in the elderly population. *Am J Otol* 1997;18:236-41.
24. Robier A, Jan M, Capelier Y, Velut S, Aesch B, Ades PE, et al. Otoneurosurgery in the elderly. [Article in French] *Rev Laryngol Otol Rhinol* 1989;110:51-3.
25. Girard N, Poncet M, Caces F, Tallon Y, Chays A, Martin-Bouyer P, et al. Three-dimensional MRI of hemifacial spasm with surgical correlation. *Neuroradiology* 1997;39:46-51.
26. Magnan J, Bremond G, Chays A, Gignac D, Florence A. Vestibular neurectomy by retrosigmoid approach: technique, indications, and results. *Am J Otol* 1991;12:101-4.