



Original Article

Using Non-Echoplanar Diffusion Weighted MRI in Detecting Cholesteatoma Following Canal Wall Down Mastoidectomy – Our Experience with 20 Patient Episodes

Bhavesh Patel , Andrew Hall , Ravi Lingam , Arvind Singh

Clinic of Otolaryngology, Head and Neck Surgery, Northwick Park Hospital & Central Middlesex Hospital, Harrow, United Kingdom (BP, AH, AS)
Clinic of Radiology, Northwick Park Hospital & Central Middlesex Hospital, Harrow, United Kingdom (RL)

ORCID IDs of the authors: B.P. 0000-0002-8664-2287; A.H. 0000-0002-4134-661X; R.L. 0000-0002-6218-8606; A.S. 0000-0001-8112-9858.

Cite this article as: Patel B, Hall A, Lingam R, Singh A. Using Non-Echoplanar Diffusion Weighted MRI in Detecting Cholesteatoma Following Canal Wall Down Mastoidectomy – Our Experience with 20 Patient Episodes. J Int Adv Otol 2018; 14(2): 263–6.

OBJECTIVE: To our knowledge, there is no study exploring specifically the diagnostic performance of diffusion-weighted imaging (DWI) in patients with previous canal wall down (CWD) surgery when combined with appropriate clinical evaluation. The aim of the present study was to evaluate the performance of DWI in the detection of residual or recurrent disease in patients who have had a previous CWD mastoidectomy.

MATERIALS and METHODS: We identified 13 patients with a CWD mastoidectomy subsequently having at least one further DWI prior to further mastoid exploration that generated a total of 20 patient episodes. Magnetic resonance imaging was performed on a 1.5 T superconductive unit using a standard head matrix coil. Coronal 2 mm thick TSE T2-weighted images (TR: 4640 ms; TE: 103 ms; matrix: 245,384; field of view: 150×200 mm) were performed. Operative findings were reviewed for all 20 patient episodes to compare DWI findings with intraoperative findings. Based on this, the sensitivity, specificity, positive predictive value (PPV), negative predictive value (NPV), and accuracy were calculated.

RESULTS: DWI had a sensitivity of 93%, specificity of 60%, PPV of 87%, NPV of 75%, and accuracy of 80%.

CONCLUSION: Given the high sensitivity of DWI in the detection of residual or recurrent disease, the present study supports DWI as a useful tool in the detection of residual or recurrent cholesteatoma in cases following CWD surgery, where clinical acumen suggests an ongoing disease process despite no overt cholesteatoma being visible.

KEYWORDS: Diagnostic imaging, diffusion magnetic resonance imaging, diffusion-weighted magnetic resonance imaging, cholesteatoma, middle ear

INTRODUCTION

The aims of surgery in the treatment of cholesteatoma are to achieve complete clearance of cholesteatoma while causing the least disruption to the natural structures within the temporal bone. Depending on the extent of the disease, the posterior bony canal wall may be preserved, canal wall up (CWU) surgery, or removed to create a mastoid cavity, canal wall down (CWD) surgery.

With CWU surgery, residual disease can be monitored through the use of non-echo planar diffusion-weighted imaging (DWI) if second-look surgery is to be avoided. Non-echo planar DWI is currently the imaging modality of choice due to its high diagnostic performance in the detection of post-operative cholesteatoma^[1–3].

In CWD cases, as there is an open mastoid cavity that can be directly examined through otomicroscopy, residual or recurrent disease can often be detected and managed with microsuction in the clinic. In addition, a recent pooled analysis of level II and III studies demonstrated that CWD surgery has a lower rate of recurrent disease at 6.6%–16.5% than CWU procedures with recurrence in 12.6%–29.5% of cases^[4]. Given the lower rates of recurrent disease and ability to monitor the mastoid cavity in the outpatient setting, there is presently no clear role for the use of DWI in surveillance patients following CWD surgery. Despite this, there remains a cohort of patients encoun-

This study was presented at the British Academic Conference in Otolaryngology (BACO), 4–6 July 2018, Manchester, United Kingdom.

Corresponding Address: Bhavesh Patel E-mail: bhavesh.patel07@imperial.ac.uk

Submitted: 26.03.2018 • **Revision received:** 12.05.2018 • **Accepted:** 21.05.2018 • **Available Online Date:** 26.07.2018

©Copyright 2018 by The European Academy of Otolology and Neurotology and The Politzer Society - Available online at www.advancedotology.org

tered in clinical practice who may present with symptoms suggestive of potential recurrent disease and equivocal findings on clinical examination. In this situation, imaging by non-echo planar DWI may provide additional information to guide the management of such patients [5].

To the best of our knowledge, there is no study that specifically explored the diagnostic performance of DWI in patients with previous CWD surgery when combined with appropriate clinical evaluation. The aim of the present study was to evaluate the performance of DWI in the detection of residual or recurrent disease in patients who have had a previous CWD mastoidectomy.

MATERIAL and METHODS

Ethical Considerations

Patients were appropriately counseled regarding their management options. We searched a prospectively updated electronic database of anonymized patient information of patients undergoing non-echo planar DWI or surgery for suspected or confirmed cholesteatoma at our institution. The database has been compiled from 2009 to 2014 and was used to identify patients who had previously undergone a CWD mastoidectomy and subsequently have had non-echo planar DWI prior to a further surgical exploration of their mastoid cavity. The ethics committee of Trust approved the study.

Patients

We identified 13 patients with a CWD mastoidectomy subsequently having at least one further DWI prior to further mastoid exploration. A patient episode was defined as a DWI followed by a subsequent mastoid exploration in a patient who had previously had a documented CWD mastoidectomy. Of the patients, two underwent multiple mastoid explorations, each with a preceding DWI. These patients, therefore, generated multiple patient episodes suitable for analysis. A total of 20 patient episodes were generated from the 13 patients in our sample. DWI was requested pre-operatively in these patients to aid in surgical decision making.

Table 1. Indication for pre-operative DWI in CWD cases

Indication for pre-operative DWI	No. of cases
Incomplete ear examination (intolerable to microsuction or inaccessible cavity)	7
Previous aggressive disease, DWI to assess for recurrence	6
New or persistent otological symptoms	4
Pre-operative planning	3

DWI: diffusion-weighted imaging; CWD: canal wall down

Table 2. Performance of DWI in the identification of cholesteatoma in patients following a canal wall down mastoidectomy

Sensitivity	93%
Specificity	60%
Positive predictive value	87%
Negative predictive value	75%
Accuracy	80%

DWI: diffusion-weighted imaging

Diffusion Weighted Imaging was requested in a minority of our CWD population undergoing further mastoid exploration to aid in diagnosis and pre-operative planning. These were symptomatic patients in which a cause could not be determined clinically. This was because some patients were unable to tolerate complete clinical examination or reported new or persistent otological symptoms despite a normal clinical examination. The other patients underwent DWI to assess recurrent disease having had aggressive disease previously. A smaller cohort underwent DWI for pre-operative planning purposes. Table 1 shows the specific indication for DWI.

Informed consent

All patients included in the study were fully informed about the indications and risks of pre-operative imaging and subsequent surgical intervention. Verbal and written consents were obtained from the patients who participated in the study. Patients also consented for anonymized information relating to their outcomes to be used for research purposes.

Intervention

Magnetic resonance imaging was performed on a 1.5 T superconductive unit (MAGNETOM Avanto; Siemens Medical Solutions, Erlangen, Germany) using a standard head matrix coil. Coronal 2 mm thick TSE T2-weighted images (TR: 4640 ms; TE: 103 ms; matrix: 245,384; field of view: 150×200 mm) were also performed. In all patients, a 2 mm thick HASTE DWI sequence was acquired in the coronal plane (TR: 1600 ms; TE: 113 ms; matrix: 134×192; field of view: 220×220 mm; b factors: 0 and 1000 s/mm²). An apparent diffusion coefficient (ADC) map was calculated post-acquisition using a diffusion scan raw data. post-acquisition using a diffusion scan raw data.

All scans were reviewed by a senior radiologist (RKL) who is experienced in head and neck imaging. A diagnosis of cholesteatoma was made if the lesion demonstrated a high signal on the b0 and b1000 images and a low signal on the ADC map and T1-weighted images.

Main Outcome Measures

Operative findings were reviewed for all 20 patient episodes. All operations were performed by experienced otologists at our institution. The operation notes were reviewed to compare DWI findings with intraoperative findings.

Statistical Analysis

A descriptive analysis of sociodemographic information was performed. Performance statistics were used to calculate the accuracy, sensitivity, specificity, and negative and positive predictive values using Microsoft Excel (Microsoft, Redmond, WA, USA).

RESULTS

A total of 20 patient episodes were generated by 13 patients. Of the patient episodes, 90% were male, and 10% were female patients. The mean age of the patient episodes at the time of surgery was 16.69 (6.72–40.88) years. Figure 1 outlines the outcome of 20 DWI scans that had surgical correlation. The accuracy of DWI in the detection of cholesteatoma in patients with CWD was 80% in surgically confirmed cases. Table 2 shows the sensitivity, specificity, positive predictive value, negative predictive value, and accuracy of DWI.

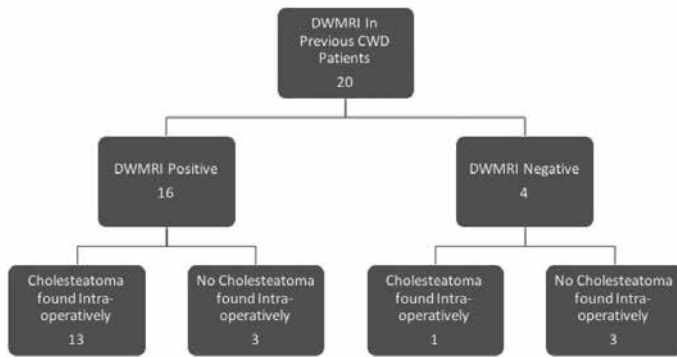


Figure 1. Outcome of DWI scans performed to assess patients following a canal wall down mastoidectomy

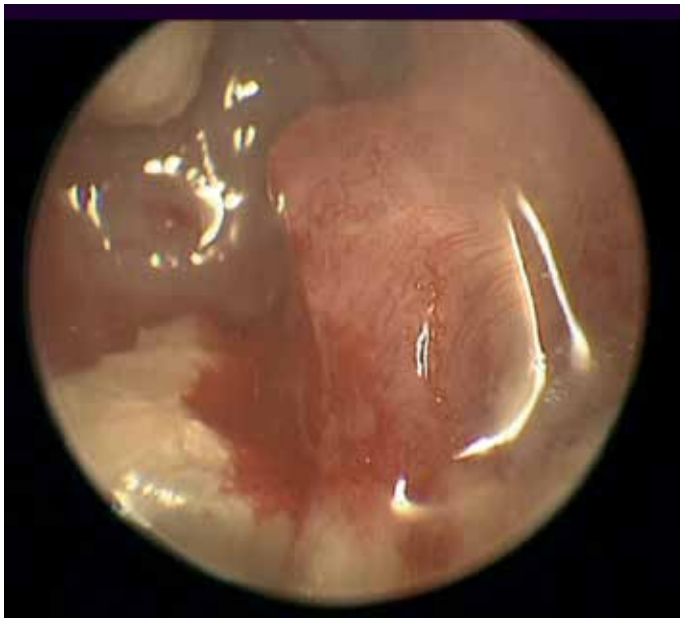

Figure 2. Intraoperative photograph following debulking of polyp under general anesthesia displaying large underlying cholesteatoma

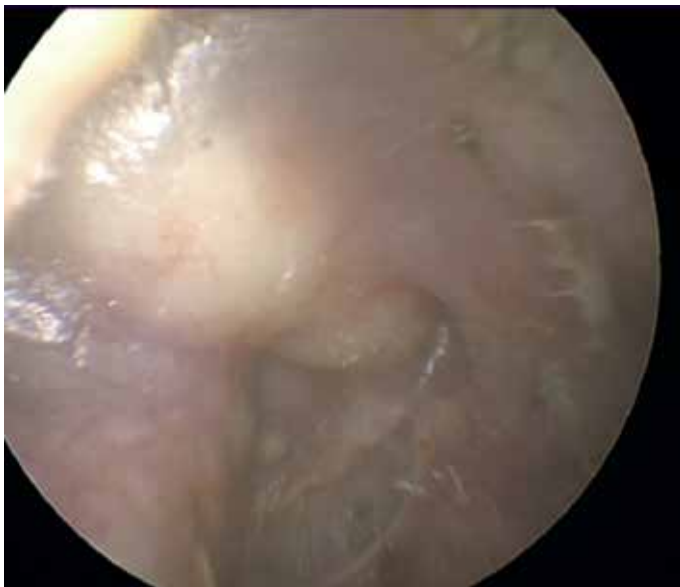

Figure 3. Evidence of multiple foci of cholesteatoma affecting neotympanum of patient with previous canal wall down procedure (intraoperative photograph)

DISCUSSION

The need of any radiological investigation is naturally dependent on its utility in influencing the overall clinical management of the patient. While the rate of residual disease following CWD mastoidectomy is lower than that following a CWU mastoidectomy, non-echo planar DWI with a sensitivity of 93% can aid in the detection of cholesteatoma in cases who are difficult to examine clinically^[6]. A single false negative case was found in a patient who has a 2 mm cholesteatoma intraoperatively. This is in line with the recognized limitation of the technique of not being reliable in the detection of small cholesteatoma <2–3 mm^[7, 8]. DWI can, therefore, be useful in screening post-operative patients for residual disease. Indeed, patients with CWD with known aggressive disease underwent planned DWI to detect early recurrence in our center.

Residual disease can often be detected and cleared in the clinic through micro-otoscopy of the mastoid cavity. In our patient sample, there were, however, instances where DWI was found to be valuable in guiding clinical decision making. In many patients, the entire mastoid cavity was not readily visible on micro-otoscopy due to either a high facial ridge or a polypoid disease precluding examination or patient intolerance to suction clearance (Figure 2). In addition, some patients were found on DWI to have disease extension toward the petrous apex and mastoid tip areas that are inaccessible on micro-otoscopy. In these situations, DWI aided our detection of residual disease.

Diffusion weighted imaging (DWI) can also be useful in pre-operative planning. Pre-operative imaging can characterize the extent of the disease, allowing a more tailored surgical approach. For example, a pre-operative DWI identifying a distinct pearl of keratin behind a neotympanum may allow a more limited surgical approach using endoscopic techniques, whereas a scan demonstrating extensive recurrence in yet unopened mastoid tip cells would require further mastoid surgery (Figure 3).

A mixture of wax and keratin was found intraoperatively in all of the false positive patients. This is in line with known false positive causes for DWI found in the literature^[9, 10]. As wax build-up is not uncommon in an open mastoid cavity, it can cause radiological misinterpretation if the radiologist is not aware that they are dealing with an open cavity. Precise communication with radiology colleagues regarding the type of surgery performed and the middle ear cleft subsites that specifically require radiological assessment can promote optimal radiological interpretation. In addition, the use of T1-weighted images can help to improve specificity. T1-weighted images can be used to differentiate between cholesteatoma, and debris as proteinaceous fluid, inflammatory soft tissue or cholesterol granuloma can yield a high T1W signal that is not associated with cholesteatoma^[7].

While the present study supports the use of DWI in the detection of residual or recurrent disease in patients with CWD, it is important to recognize the limitations of the study. As there were a total of 20 patient episodes obtained through our retrospective review of patients, a larger prospective study is required to validate these findings. In addition, our methodology involved all DWI being interpreted by a single radiologist. DWI should be reviewed by multiple radiologists to ensure inter-observer agreement in future studies.

CONCLUSION

The routine use of DWI in CWD monitoring is not warranted, but the present study supports the use of DWI in specific diagnostically difficult cases. With experienced radiological interpretation, DWI is a useful tool in the detection of residual or recurrent cholesteatoma following CWD surgery, where clinical acumen suggests an ongoing disease process despite no overt cholesteatoma being visible.

Ethics Committee Approval: Ethics committee approval was provided by the clinical governance and audit department at Northwest London Hospitals NHS Trust.

Informed Consent: Written informed consent was obtained from the patients who participated in this study.

Peer-review: Externally peer-reviewed.

Author contributions: Concept – A.S., R.L.; Design – B.P., A.H, R.L., A.S.; Supervision – A.S., R.L.; Resource – B.P., A.S.; Materials – B.P., A.S.; Data Collection and/or Processing – B.P., A.H Analysis and/or Interpretation – B.P., A.H. Literature Search – A.H. Writing – B.P., A.H., R.L., A.S.; Critical Reviews – R.L., A.S.

Conflict of Interest: The authors have no conflict of interest to declare.

Financial Disclosure: The authors declared that this study has received no financial support.

REFERENCES

1. Lingam RK, Bassett P. A meta-analysis on the diagnostic performance of non-echoplanar diffusion-weighted imaging in detecting middle ear cholesteatoma: 10 years on. *Otol Neurotol* 2017; 38: 521-8. [\[CrossRef\]](#)
2. Majithia A, Lingam RK, Nash R, Khemani S, Kalan A, Singh A. Staging primary middle ear cholesteatoma with non-echoplanar (half-Fourier-acquisition single-shot turbo-spin-echo) diffusion-weighted magnetic resonance imaging helps plan surgery in 22 patients: our experience. *Clin Otolaryngol* 2012; 37: 325-30. [\[CrossRef\]](#)
3. Jindal M, Riskalla A, Jiang D, Connor S, O'Connor AF. A systematic review of diffusion-weighted magnetic resonance imaging in the assessment of postoperative cholesteatoma. *Otol Neurotol* 2011; 32: 1243-9. [\[CrossRef\]](#)
4. Harris AT, Mettias B, Lesser THJ. Pooled analysis of the evidence for open cavity, combined approach and reconstruction of the mastoid cavity in primary cholesteatoma surgery. *J Laryngol Otol* 2016; 130: 235-41. [\[CrossRef\]](#)
5. Nash R, Kalan A, Lingam R., Singh A. The role of diffusion-weighted magnetic resonance imaging in assessing residual/recurrent cholesteatoma after canal wall down mastoidectomy. *Clin Otolaryngol* 2016; 41: 307-9. [\[CrossRef\]](#)
6. Li PMMC, Linos E, Gurgel RK, Fischbein NJ, Blevins NH. Evaluating the utility of non-echo-planar diffusion-weighted imaging in the preoperative evaluation of cholesteatoma: A meta-analysis. *Laryngoscope* 2013; 123: 1247-50. [\[CrossRef\]](#)
7. Lingam RK, Nash R, Majithia A, Kalan A, Singh A. Non-echoplanar diffusion weighted imaging in the detection of post-operative middle ear cholesteatoma: navigating beyond the pitfalls to find the pearl. *Insights Imaging* 2016; 7: 669-78. [\[CrossRef\]](#)
8. Plouin-Gaudon I, Bossard D, Fuchsmann C, Ayari-Khalfallah S, Froehlich P. Diffusion-weighted MR imaging for evaluation of pediatric recurrent cholesteatomas. *Int J Pediatr Otorhinolaryngol* 2010; 74: 22-6. [\[CrossRef\]](#)
9. Khemani S, Lingam RK, Kalan A, Singh A. The value of non-echo planar HASTE diffusion-weighted MR imaging in the detection, localisation and prediction of extent of postoperative cholesteatoma. *Clin Otolaryngol* 2011; 36: 306-12. [\[CrossRef\]](#)
10. Lingam RK, Khatri P, Hughes J, Singh A. Apparent diffusion coefficients for detection of postoperative middle ear cholesteatoma on non-echo-planar diffusion-weighted images. *Radiology* 2013; 269: 504-10. [\[CrossRef\]](#)