



Original Article

Radiological Evaluation of Inner Ear with Computed Tomography in Patients with Unilateral Non-Pulsatile Tinnitus

Emre Ocak, Deniz Kocaöz, Baran Acar, Melih Topçuoğlu

Department of Otorhinolaryngology, Keçiören Training and Research Hospital, Ankara, Turkey (EO, DK, BA)
Department of Radiology, Keçiören Training and Research Hospital, Ankara, Turkey (MT)

Cite this article as: Ocak E, Kocaöz D, Acar B, Topçuoğlu M. Radiological Evaluation of Inner Ear with Computed Tomography in Patients with Unilateral Non-Pulsatile Tinnitus. J Int Adv Otol 2018; 14(2): 273-7.

OBJECTIVE: The objective of this research was to investigate the possible relationship between tinnitus and certain bony inner ear structures using computed tomography (CT).

MATERIALS and METHODS: This was a prospective, controlled, double-blind study. The subjects of the study were divided into the following three groups: group 1 (G1), patients with unilateral sensorineural hearing loss (SNHL) and unilateral non-pulsatile tinnitus in the same ear; group 2 (G2), patients with normal hearing and unilateral non-pulsatile tinnitus; and group 3 (G3), healthy volunteers with neither tinnitus nor hearing loss. The basal turn length, internal acoustic canal (IAC) width and length, bony cochlear nerve canal (BCNC) width, and IAC diameter at the porus acousticus internus (PAI) were measured.

RESULTS: The mean BCNC width was significantly narrower in G1 and G2 than in the control group (G3) ($p < 0.001$). For patients in G2, BCNC width was significantly narrower in ears with tinnitus ($p < 0.001$) than in ears without tinnitus. The mean IAC diameter at PAI was also narrower in the G1 patients ($p = 0.007$) compared with the other groups.

CONCLUSION: The results of this study suggest that CT evaluation of the inner ear structures is important in patients with tinnitus. According to the results, a narrow BCNC may cause phantom sensations and be related to cochlear nerve dysfunction. Therefore, it is recommended that clinicians evaluate BCNC carefully while assessing such patients.

KEYWORDS: Tinnitus, temporal bone, computed tomography, bony cochlear nerve canal

INTRODUCTION

Despite years of research on the topic, little is known about tinnitus, which is defined as the perception of sound without any external source. Nearly 20% of the world's population suffers from tinnitus, and according to a recent study, at least one-fourth of this group has reported interference with daily activity and quality of life ^[1]. With estimated treatment costs exceeding \$345.5 million per year in the United States alone, tinnitus has also resulted in massive financial burden ^[2]. Furthermore, evidence has indicated that patients with tinnitus can suffer mental health problems.

The pathophysiology of tinnitus is complicated, and its distinct etiology can only be found in a limited number of patients. Numerous types of treatment modalities, such as oral medication, retraining therapy, or transtympanic laser therapy, have been attempted ^[3]. However, because of the unclear etiology of tinnitus in most cases, clinicians often fail to constitute a proper algorithm that can effectively treat it.

Because the clarification of tinnitus' pathogenesis plays a key role in the effective treatment of the disease, studies should focus on tinnitus' possible etiological factors in order to achieve satisfactory treatment results. This study aimed to evaluate certain inner ear structures in patients who suffered from tinnitus, hypothesizing that regardless of the presence of hearing loss, tinnitus may occur when the bony structures that surround the cochlear nerve become narrower.

This study was presented at the 8th EAONO Instructional Course, 18-21 January 2016, İzmir, Turkey.

Corresponding Address: Emre Ocak E-mail: dremreocak@gmail.com

Submitted: 15.03.2017 • **Revision Received:** 12.09.2017 • **Accepted:** 23.10.2017 • **Available Online Date:** 14.12.2017

©Copyright 2018 by The European Academy of Otology and Neurotology and The Politzer Society - Available online at www.advancedotology.org

MATERIALS and METHODS

Subjects and Clinical Setup

This prospective, controlled, double-blind study was conducted in a tertiary referral hospital, and all clinical examinations and radiological evaluations were performed in the departments of radiology and otolaryngology. Each patient signed an informed consent form before the study began, and the Declaration of Helsinki's ethical principles on human experimentation were followed. The study was approved by the ethics committee (EC) of Keçiören Research and Training Hospital (EC No: 868).

Patients with and without hearing loss were included in the study if they had been admitted to the otolaryngology outpatient clinic with complaints of unilateral non-pulsatile tinnitus. Patients with a Tinnitus Handicap Inventory (Turkish Validated) score <76 were included in this study [4]. Patients were excluded from the study if they used chronic medications, such as acetylsalicylic acid; had histories of malignancies, otologic surgery, and prior otitis media/externa; were using hearing aids; or had psychiatric disorders, abnormal otoscopic findings, accompanying vestibular complaints, chronic systemic and/or vascular diseases, and the presence of conductive types of hearing loss or abnormal tympanometry findings. All study subjects were given a detailed clinical examination by the same otolaryngologist. Audiological status was assessed with tympanometry and pure tone audiometry (PTA). Inner ear structures were evaluated with temporal bone computed tomography (CT).

The subjects were divided into the following three groups: group 1 (G1), patients with unilateral sensorineural hearing loss (SNHL) and unilateral non-pulsatile tinnitus in the same ear; group 2 (G2), patients with normal hearing and unilateral non-pulsatile tinnitus; and group 3 (G3), age- and gender-matched patients with neither tinnitus nor hearing loss who had been scanned for reasons other than otologic issues. G3 served as the control group for G1 and G2. While the bony inner ear structures were only measured in the affected ears of the subjects in G1, the bony inner ear structures were measured in the right ears of every subject in G3. Both ears of the patients in G2 were evaluated to compare the structures of both sides within the group. All patients in G1 and G2 also underwent magnetic resonance imaging (MRI) to exclude the presence of intracranial lesions, such as acoustic neuromas. Patients with any pathologies in the cerebellopontine angle or internal auditory canal were also excluded from the study.

Audiological Assessment

For the audiological evaluation, PTA was performed using the Orbiter 922° Clinical Audiometer (Madsen Electronics, Copenhagen, Denmark) for frequencies of 250, 500, 1000, 2000, 4000, and 8000 Hz. A 226-Hz tympanometry was performed using an AT235° impedance audiometer (Interacoustics, Copenhagen, Denmark) device. All patients were assessed by the same audiometrist. Subjects with a mean hearing threshold of <26 dB hearing level (dBHL) were considered to have normal hearing [5].

Radiological Evaluation

All patients were evaluated by the same radiologist who had been blinded to the clinical data. In total, 74 temporal bone CT examinations were performed for G1 and G2. For G3, 41 temporal bone

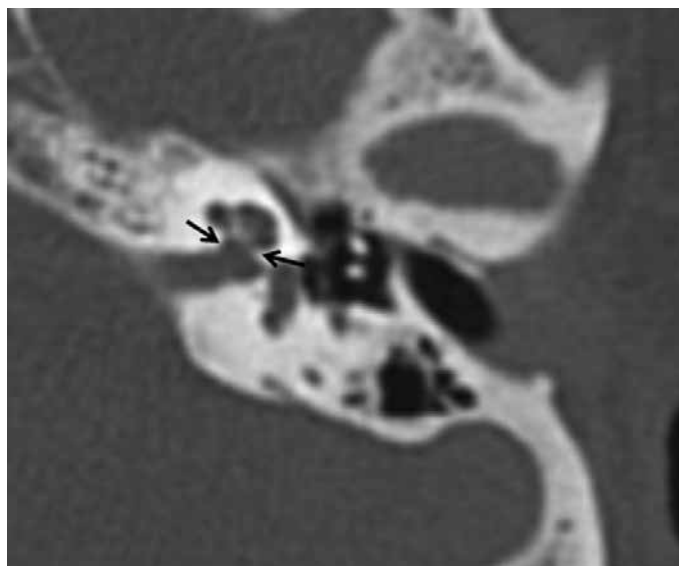


Figure 1. Measurement of BCNC

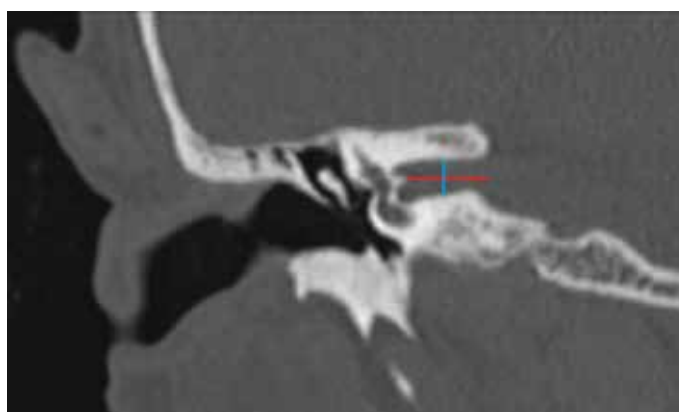


Figure 2. IAC length (red line) and width (blue line) measured from coronal reformat CT images

CT examinations were performed on 41 patients who had been scanned for head trauma. All CT scans were performed with a 16-row multi-detector CT scanner (Somatom Emotion; Siemens Healthcare, Forchheim, Germany). The CT parameters of the temporal bone scan included the following: 0.75 s of gantry rotation time, 110 kVp, 120 mA, 0.6 mm section thickness, 16×1.2 detector configuration, and 512×512 matrix size.

The bony cochlear nerve canal (BCNC) width was measured at the fundus level of internal acoustic canal (IAC) to the mid-modiolar cochlea in the axial images (Figure 1). IAC length was measured from the imaginary mid-point of the porus to the transverse crest, and IAC width was measured at the mid-canal level from the coronal reformat CT images of the temporal bones of the subjects (Figure 2). The IAC diameter at the porus acousticus internus (PAI) and the basal turn length of the cochleae were also measured using the axial images.

Statistical Analysis

Fisher's exact test and Pearson's chi-square test were used to compare the groups. For more than two groups, analysis of variance (ANOVA) was used to evaluate the significance of the differences in the averages between the groups. Statistical Package for Social Sci-

Table 1. Measurements of inner ear bony structures in all groups

	Bony cochlear nerve canal	IAC width (coronal)	IAC length (coronal)	Basal turn length	IAC diameter at porus
G1 (n=36)	1.21±0.31	4.07±0.94	11.02±2.24	8.29±1.02	6.19±1.30
G2 (n=38)	1.21±0.36	4.48±0.91	11.50±1.89	8.61±0.60	6.92±1.38
G3 (n=41)	1.98±0.41	4.24±0.78	11.64±2.20	8.74±0.70	7.09±1.16
p	<0.001*	0.138	0.417	0.053	0.007**

IAC: internal acoustic canal; ANOVA: analysis of variance

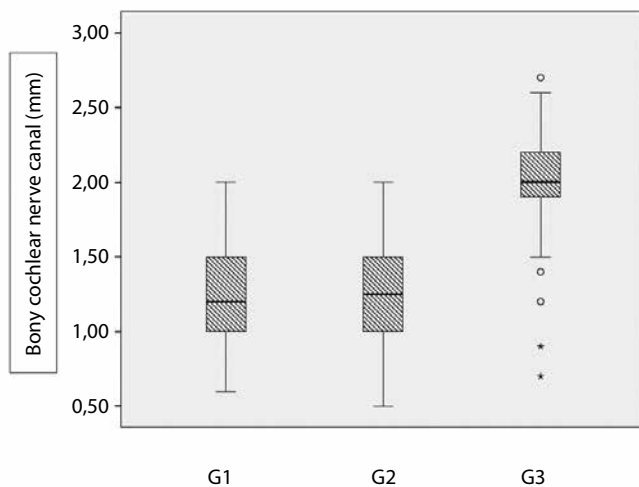
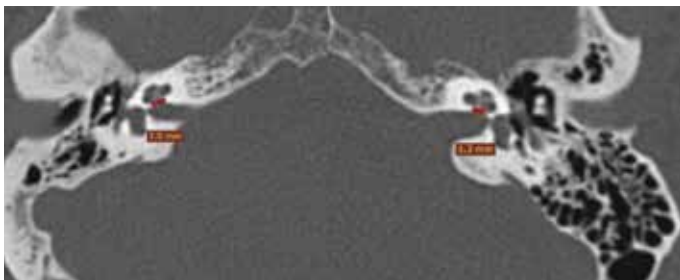
*Bony cochlear nerve canal length is significantly narrower in G1 and G2 compared with G3. **IAC diameter is significantly narrower in G1 compared with G2 and G3

Table 2. Measurements of inner ear bony structures in G2 patients

	Bony cochlear nerve canal	IAC width (coronal)	IAC length (coronal)	Basal turn length	IAC diameter at porus
Tinnitus	1.21±0.36	4.48±0.91	11.50±1.89	8.61±0.60	6.92±1.38
Control	1.62±0.49	4.46±0.88	11.94±1.71	8.66±0.70	7.19±1.35
p	<0.001*	0.416	0.714	0.812	0.573

IAC: internal acoustic canal

*: Statistically significant (paired t-test)

**Figure 3.** The mean BCNC width in G1, G2, and G3 patients**Figure 4.** BCNC measurements of both ears in a patient with tinnitus on the left side. See the hypoplastic BCNC on the left side (<1.4 mm)

ences version 15.0 for Windows (SPSS Inc.; Chicago, IL, USA) was used for all statistical analyses, and a p value of <0.05 was considered to be statistically significant.

RESULTS

The study included 115 patients. There were 36, 38, and 41 patients in G1, G2, and G3, respectively. No inner ear anomalies were detected in any of the groups. Because of the study criteria, one patient was excluded when an osteoma was found at the porus of IAC. Measurements of the IAC width and length, BCNC width, IAC diameter at PAI,

and basal turn length are summarized in Table 1. According to ANOVA, the mean BCNC width was significantly narrower in patients in G1 and G2 than in those in G3 ($p<0.001$) (Figure 3). The IAC diameter at PAI was also smaller in G1 than in G2 and G3 ($p=0.007$). The measurements of the IAC width and length and the basal turn length were similar between the groups.

Table 2 shows a comparison between the affected and unaffected ears of G2, wherein the unaffected ears serve as the control group for ears with tinnitus. According to Table 2, the BCNC width was significantly narrower in ears with tinnitus than in unaffected ears ($p<0.001$). The measurements of IAC diameter at PAI, IAC width and length, and basal turn length were similar between the affected and unaffected ears.

DISCUSSION

Because tinnitus remains to be one of the most common neurological disorders worldwide, numerous studies have been published to better understand its mechanisms and develop new strategies for its treatment. A small proportion of patients have exhibited few pathologies, such as glomus tumors and acoustic neuroma, which directly relate to tinnitus. Ruling out the limited number of patients who have had obvious pathologies, a vast majority of people with tinnitus remain untreated and undiagnosed. Because tinnitus' etiology is key to its accurate treatment, clinicians have focused on research that has investigated the disease's possible pathogenetic mechanisms. As a result, otological diseases have been studied alongside hormonal changes, physiological diseases, neurological disorders, cardiovascular diseases, intracranial pathologies, and temporomandibular joint disorders [6]. Regardless, a majority of patients have exhibited no obvious etiological explanations for tinnitus in spite of diagnostic testing. These patients have primarily been treated with oral betahistine, anti-depressants, or tinnitus retraining therapy.

During the evaluation of patients with tinnitus, most clinicians use algorithms that utilize radiological imaging technologies. The underlying reason for imaging such patients is to exclude any possible neurological or intracranial pathologies, such as cerebellopontine angle lesions. In this context, most otolaryngologists prefer to use

MRI. While MRI is a valuable diagnostic technique for assessing soft tissue, it has limited accuracy in its ability to evaluate bony structures. The most appropriate radiological imaging option for investigating bony inner ear structures is temporal bone CT. Evidence has suggested an association between SNHL and narrowed inner ear structures, such as BCNC [7, 8]. BCNC is described as a bony transition canal that is located between IAC and cochlear modiolus (Figure 4) [9]. In a radioanatomic study of BCNC by Stjernholm and Murren, a value of 1.4 mm was suggested to indicate hypoplasia of BCNC [10]. A similar value was determined in the present study.

By broadening this viewpoint so that it did not focus solely on BCNC, which is the narrowest point of the nerve course, we hypothesized that the compression of certain inner ear structures, such as IAC or PAI, may produce symptoms of tinnitus regardless of the presence of hearing loss. After excluding subjects who exhibited factors that may cause tinnitus, a group of patients who showed signs of unilateral subjective non-pulsatile tinnitus was formed. Subgroups were formed according to hearing status. The significant narrowness of BCNC in G1 and G2 might result in the dysfunction of the eighth cranial nerve. Because we asserted that a hypoplastic BCNC may be related to the development of SNHL, this relationship is referred to as the dysfunction of the eighth cranial nerve.

The coronal CT images revealed no differences in the IAC lengths and widths between the groups (Table 1). These values were also similar between the ears of patients in G2 (Table 2). The basal turn length was also similar between the groups. We measured this location because it is one of the most reliable markers that can indicate an anatomically normal cochlea. However, because the presence of a competent cochlea is essential to an intact acoustic pathway, we measured the basal turn length in all patients to evaluate their cochleae radiologically. Another remarkable structure in the cochlear nerve pathway is PAI. The IAC diameter at PAI was measured in all patients and was found to be wider in G2 and G3 than in G1. The narrowness of this structure in G1 was statistically significant, leading to the conclusion that the compression of the eighth cranial nerve at any point could result in tinnitus or related symptoms.

In recent years, there has been an increase in the number of studies that evaluate the association between cochlear nerve function and bony inner ear structures. For instance, Kumral et al. [11] found no anatomical differences in the etiology of tinnitus when they studied the inlet, mid-canal, and outlet measurements of IAC in patients who had and did not have tinnitus. In a study of 51 patients with unilateral SNHL, Yi et al. [9] found that the BCNC diameter was significantly smaller in ears with SNHL than in normal ears. They found narrow BCNCs in more than half of the ears with SNHL, which indicated a significant association between BCNC stenosis and cochlear hypoplasia. In the presence of normal cochleae, BCNC stenosis has also been reported to be a potential cause of congenital SNHL [12-14]. The studies that arrived at this conclusion typically referred to BCNC as a potential anatomical site for the evaluation of bony inner ear structures with temporal bone CT.

This study was consistent with existing literature because no correlation was found between tinnitus and IAC length and

width. The basal turn length was also similar between the study and control groups. According to this study's data, the mean BCNC diameter was significantly smaller in patients with tinnitus than in patients without tinnitus. This significance was present regardless of the patients' hearing status. Recent studies have indicated an association between SNHL and BCNC stenosis. By discussing the relationship between tinnitus and BCNC tinnitus, the results of this study will bring a new perspective to research on tinnitus.

The compression of neurovascular structures may cause various symptoms, such as neuralgia, hypoesthesia, and even phantom sensations. Although not all cases of neurovascular compressions are symptomatic, a number of clinical syndromes have been detected within the cranial nerves. These syndromes include hemifacial spasm, trigeminal neuralgia, vestibular paroxysmia, and glossopharyngeal neuralgia. The compression of neural structures, especially as they pass through the foramina and bony canals, may cause the abovementioned symptoms. The positive relationship between patients with tinnitus and narrow BCNCs may also be an example of this phenomenon [15].

This study was restricted by its limited number of participants. Further studies that contain larger groups and that match this study's criteria will provide more information about the relationship between tinnitus and bony inner ear structures. Auditory brainstem responses or otoacoustic emissions could have been performed to evaluate the integrity of the cochlear nerve and hair cell damage; however, because the vast majority of the study's subjects were adult patients who had normal hearing during childhood, PTA was found to be sufficient for the audiological assessment.

CONCLUSION

The findings of this study suggest that CT evaluation of the inner ear structures is important in patients with tinnitus, particularly for those who have experienced hearing loss. According to the results, narrow BCNCs may be related to dysfunction of the cochlear nerve, which in turn, may result in tinnitus. It is therefore recommended that clinicians evaluate BCNC carefully while assessing patients with tinnitus.

Ethics Committee Approval: Ethics committee approval was received for this study from Keçiören Clinic Research Ethics Committee (Approval Date: 12.04.2016/Approval No: 868).

Informed Consent: Written informed consent was obtained from patients who participated in this study.

Peer-review: Externally peer-reviewed.

Author contributions: Concept – E.O., B.A.; Design – E.O., D.K.; Supervision – B.A.; Resource – M.T., D.K., E.O.; Materials – D.K., E.O., M.T.; Data Collection and/or Processing – D.K., M.T.; Analysis and/or Interpretation – E.O., M.T.; Literature Search – B.A., D.K.; Writing – E.O., B.A.; Critical Reviews – E.O., B.A.

Conflict of Interest: No conflict of interest was declared by the authors.

Financial Disclosure: The authors declared that this study has received no financial support.

REFERENCES

- Atik A. Pathophysiology and treatment of tinnitus: an elusive disease. *Indian J Otolaryngol Head Neck Surg* 2014; 66: 1-5. [\[CrossRef\]](#)
- Henry JA, Dennis KC, Schechter MA. General review of tinnitus. Prevalence, mechanisms, effects and management. *J Speech Lang Hear Res* 2005; 48: 1204-35. [\[CrossRef\]](#)
- Shore SE, Roberts LE, Langguth B. Maladaptive plasticity in tinnitus - triggers, mechanisms and treatment. *Nat Rev Neurol* 2016; 12: 150-60. [\[CrossRef\]](#)
- Aksoy S, Firat Y, Alpar R. The Tinnitus Handicap Inventory: a study of validity and reliability. *Int Tinnitus J* 2007; 13: 94-8.
- Schlauch R, Nelson P. Pure tone evaluation. In: Robert Burkard, Linda Hood, eds. *Handbook of Clinical Audiology*. 6th edition. Baltimore, MA, USA: Lippincott Williams & Williams; 2009.p. 39-45.
- Levine RA, Oron Y. Tinnitus. *Handb Clin Neurol* 2015; 129: 409-31. [\[CrossRef\]](#)
- Kono T. Computed tomographic features of the bony canal of the cochlear nerve in pediatric patients with unilateral sensorineural hearing loss. *Radiat Med* 2008; 26: 115-9. [\[CrossRef\]](#)
- Fatterpekar GM, Mukherji SK, Alley J, Lin Y, Castillo M. Hypoplasia of the bony canal for the cochlear nerve in patients with congenital sensorineural hearing loss: Initial observations. *Radiology* 2000; 215: 243-6. [\[CrossRef\]](#)
- Yi JS, Lim HW, Kang BC, Park SY, Park HJ, Lee KS. Proportion of bony cochlear nerve canal anomalies in unilateral sensorineural hearing loss in children. *Int J Pediatr Otorhinolaryngol* 2013; 77: 530-3. [\[CrossRef\]](#)
- Stjernholm C, Muren C. Dimensions of the cochlear nerve canal: A radio-anatomic investigation. *Acta Otolaryngol* 2002; 122: 43-8. [\[CrossRef\]](#)
- Kumral TL, Yildirim G, Yilmaz HB, Ulusoy S, Berkiten G, Onol SD, et al. Is it necessary to do temporal bone computed tomography of the internal auditory canal in tinnitus with normal hearing? *ScientificWorldJournal* 2013; 26: 689087. [\[CrossRef\]](#)
- Quan Y, Wu L, Xu Z, Gong W, Gong R. Detection of hypoplasia of bony cochlear nerve canal by virtual endoscopy: a pilot study. *Acta Radiol* 2011; 52: 802-7. [\[CrossRef\]](#)
- Sennaroglu L, Saatci I. A new classification for cochleovestibular malformations. *Laryngoscope* 2002; 112: 2230-41. [\[CrossRef\]](#)
- Henderson E, Wilkins A, Huang L, Kenna M, Gopen Q. Histopathologic investigation of the dimensions of the cochlear nerve canal in normal temporal bones. *Int J Pediatr Otorhinolaryngol* 2011; 75: 464-7. [\[CrossRef\]](#)
- Lu AY, Yeung JT, Gerrard JL, Michaelides EM, Sekula RF Jr, Bulsara KR. Hemifacial spasm and neurovascular compression. *ScientificWorldJournal* 2014; 2014: 349319.