

## Case Report

# An Ameloblastoma in the Middle Ear

Takashi Yamatodani , Kiyoshi Misawa , Shiori Endo , Hiroshi Nakanishi , Seiji Hosokawa ,  
Hiroyuki Mineta 

Department of Otorhinolaryngology, Head and Neck Surgery, Hamamatsu University School of Medicine, Hamamatsu, Japan

ORCID IDs of the authors: T.Y. 0000-0003-2639-3466; K.M. 0000-0002-2450-5682; S.E. 0000-0002-0984-9428; H.N. 0000-0002-5028-1440; S.H. 0000-0003-4148-8279; H.M. 0000-0002-7496-3489.

Cite this article as: Yamatodani T, Misawa K, Endo S, Nakanishi H, Hosokawa S, Mineta H. An Ameloblastoma in the Middle Ear. J Int Adv Otol 2019; 15(1): 173–6.

An ameloblastoma is a locally aggressive odontogenic tumour that commonly develops from the odontogenic epithelium within the jawbone. Here we present for the first time a case of a rare primary ameloblastoma in the middle ear cavity, along with some consideration of its treatment and a new classification. A 65-year-old woman presented with a left middle ear cavity tumour. Pathological examination led to the diagnosis of an ameloblastoma. We resected the tumour along with an extensive part of the middle ear mucosa, which made it difficult to have an adequate margin. It is recommended that the remaining bone be ground 2–3 mm beyond the visible margin after resecting the gross tumour. Therefore, several cases are treated with conservative surgery, including physicochemical treatment. This factor should be considered when designing treatment strategies as good alternatives in cases where resection with an adequate margin is difficult.

**KEYWORDS:** Ameloblastoma, middle ear, odontogenic tumour

## INTRODUCTION

Ameloblastomas are common benign odontogenic neoplasms that exhibit locally aggressive behavior and originate from the odontogenic epithelium. They commonly develop inside the jawbone, whereas their occurrence outside the jawbone is very rare. A primary ameloblastoma in the middle ear cavity is considered very rare and, to our knowledge, has not been previously reported. A tumor in the middle ear cavity is often close to the internal carotid artery, facial nerve, or inner ear, and resection with an adequate margin of safety is difficult. Therefore, in many cases, it is necessary to consider appropriate treatment strategies. We report a rare case of a primary ameloblastoma in the middle ear cavity, along with tumor-specific treatment options and a suggestion for a new classification.

## CASE PRESENTATION

A 65-year-old woman was referred to our institute with a left middle ear cavity tumor. She developed a feeling of left ear fullness that persisted. She was subsequently admitted to a nearby general hospital. A tumor was suspected in her left middle ear cavity, and she was transferred to our institution for further examination and surgical treatment.

On initial investigation at our department, a hemorrhagic granulation-like tumor in the left middle ear cavity was revealed (Figure 1). The tympanic membrane could not be recognized. Pure tone audiometry demonstrated a loss of left conductive hearing with a mean air–bone gap of 33 dB. A biopsy of the tumor was performed at the outpatient department. On histopathological studies, a follicular pattern with a tumor island, peripheral palisading, and central cystic degeneration was revealed (Figure 2a). No malignant findings were found, and an ameloblastoma was diagnosed. Immunohistochemical studies were positive for epithelial markers, including p40, p63, AE1/AE3, and epithelial membrane antigen, and were negative for neuroendocrine markers, such as synaptophysin and chromogranin A (Figure 2b–g).

Computed tomography (CT) revealed a pervasive soft tissue shadow in the left middle ear cavity and thinning of the bony wall in front of the tympanic cavity (Figure 3a, b). The ossicles were almost preserved, and no enlargement of the lymph nodes in the neck was observed. Gd-enhanced magnetic resonance imaging (MRI) was performed, revealing a tumor-suspected area with a low signal

This study was presented at the “79<sup>th</sup> Annual Meeting of the Society of Practical Otolaryngology”, “July 7<sup>th</sup>, 2018”, “Shimonoseki, Japan”.

**Corresponding Author:** Takashi Yamatodani E-mail: ty@hama-med.ac.jp

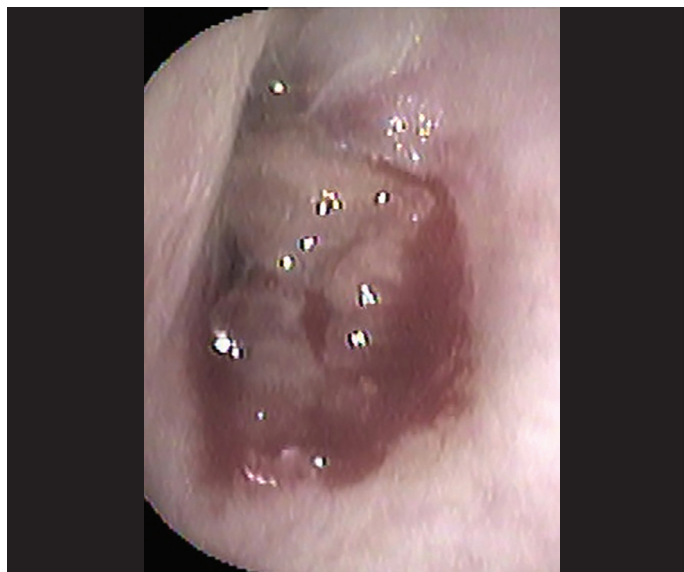**Submitted:** 22.03.2018 • **Revision Received:** 12.11.2018 • **Accepted:** 12.11.2018 • **Available Online Date:** 26.03.2019

Available online at [www.advancedotology.org](http://www.advancedotology.org)



Content of this journal is licensed under a  
Creative Commons Attribution-NonCommercial  
4.0 International License.

at T2 and an equal signal at T1 in the left tympanic cavity (Figure 3c). The tumor had progressed along the outside of the left carotid canal, and the mastoid antrum had a shadow suggestive of liquid effusion. Surgery was performed by using a retroauricular approach approximately 3 weeks after the initial diagnosis. The tumor was hemorrhagic-

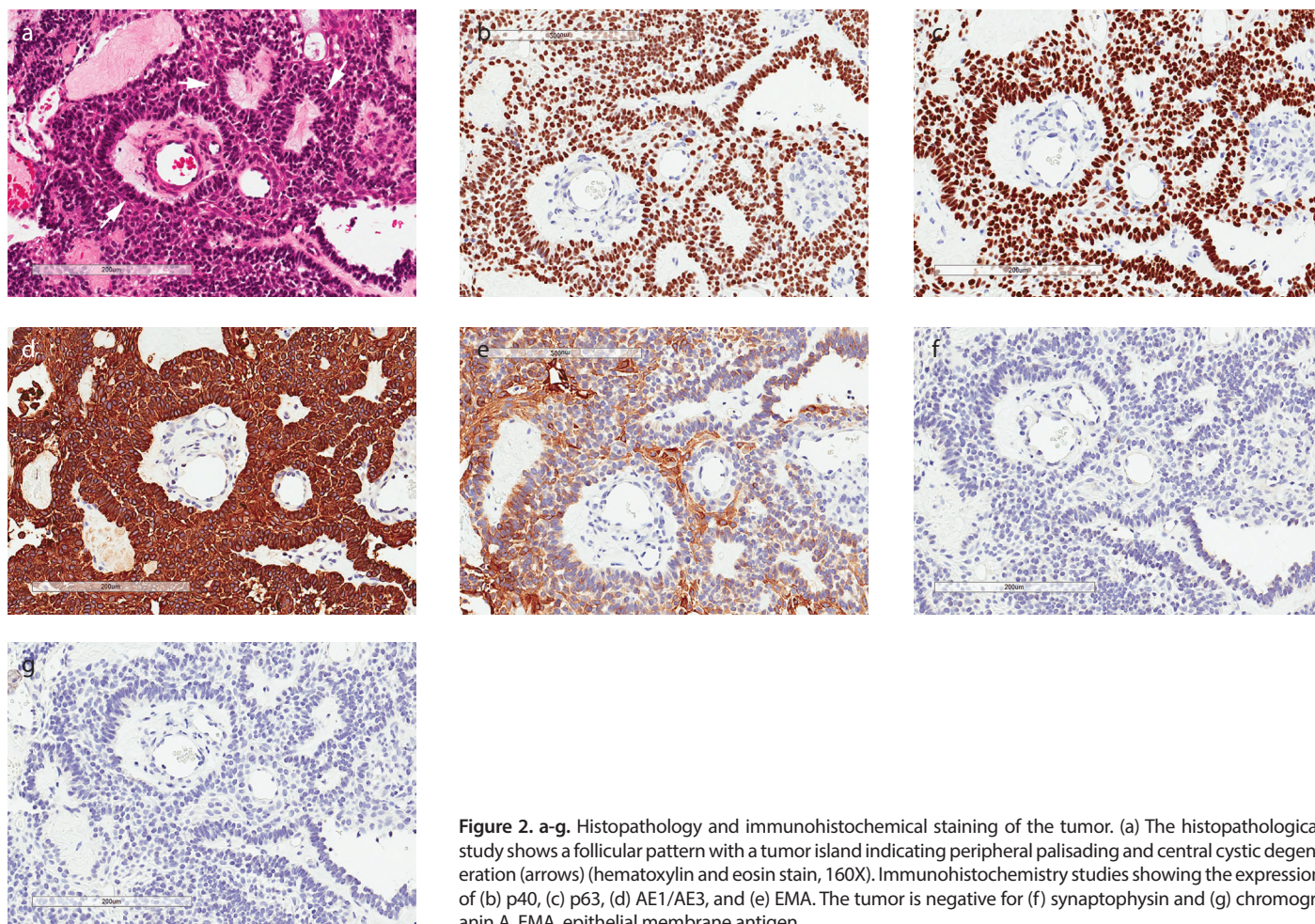


**Figure 1.** Tumor in the left middle ear cavity. A hemorrhagic granulation-like tumor was found in the left middle ear cavity.

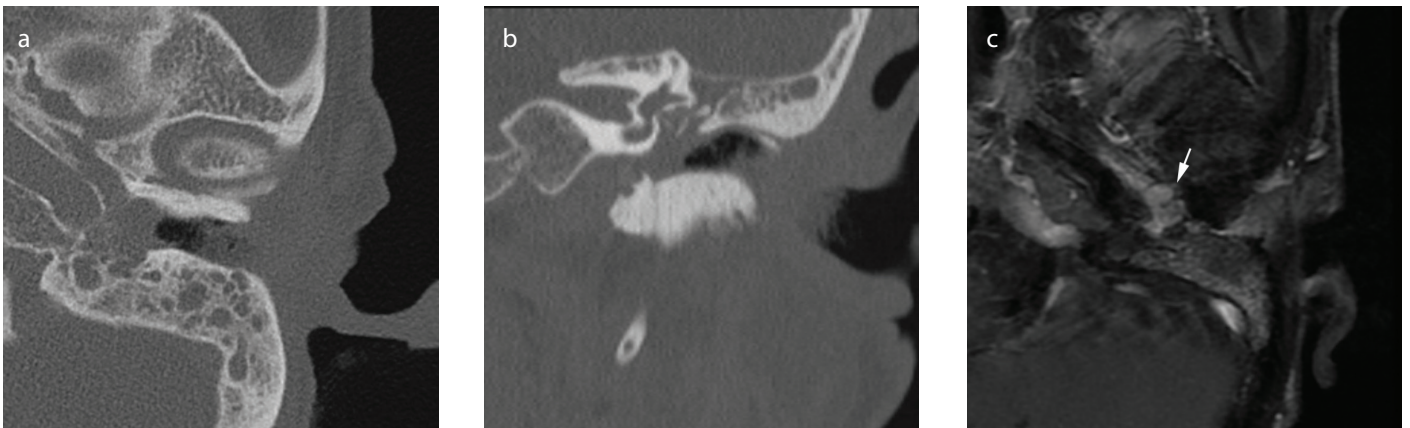
ic and fragile, pervasive in the tympanic cavity, and extended to the attic through the mastoid antrum. A mastoidectomy was performed, and the posterior wall of the external auditory canal was drilled to place the tympanic sinus under distinct view. Furthermore, the incudostapedial joint in the tumor was separated, and the incus was removed subsequently. Because the tumor adhered to the tympanic mucosa widely, it was removed together with the mucosa. The anterior lesion of the hypotympanum outside the carotid canal had the highest local infiltration of the tumor, and bone erosion suggested that this was the primary site. To prevent tympanic adhesion, we inserted a gelatin sponge and a gelatin film in the tympanum, and we also placed the columella, which was made with the auricular cartilage, on the stapes, to rebuild the sound conduction.

A pathological evaluation of the resected tumor did not yield any malignant findings, and histopathological studies confirmed the findings of the preoperative biopsy; thus, the tumor was diagnosed as an ameloblastoma. Because we removed the mucosa of the middle ear cavity during surgery, the postoperative middle ear cavity did not receive sufficient pneumatization; therefore, no improvement in the conductive hearing loss was observed (Figure 4a). The findings in the ear indicated that tympanic membrane epithelialization was completed in a dry state (Figure 4b).

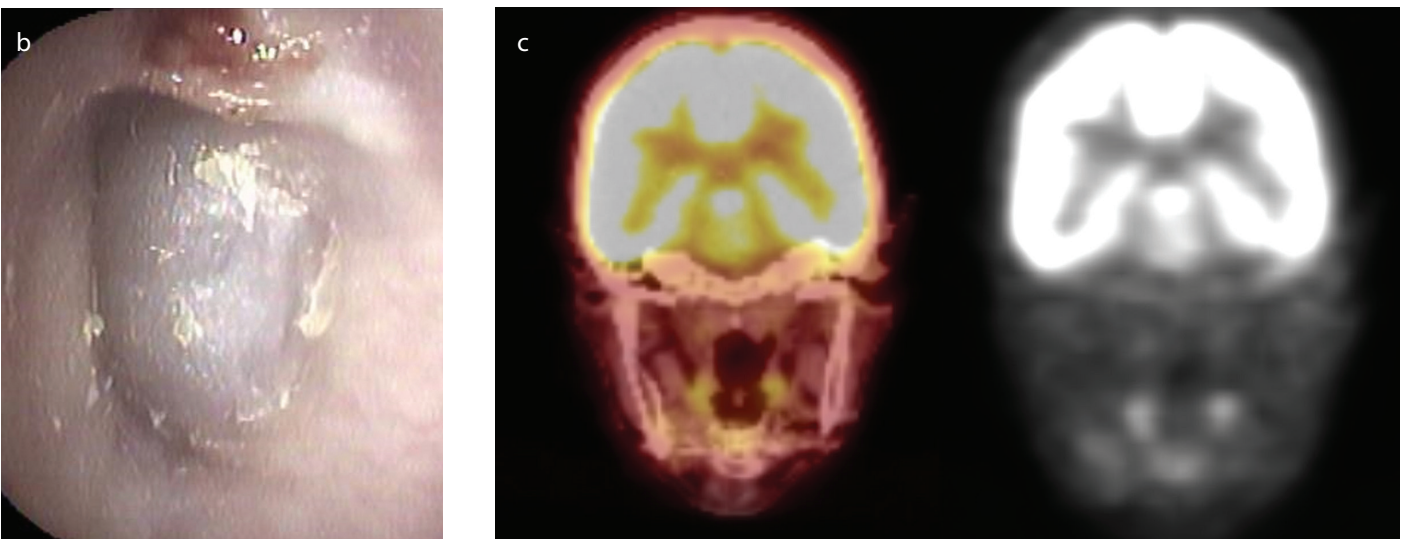
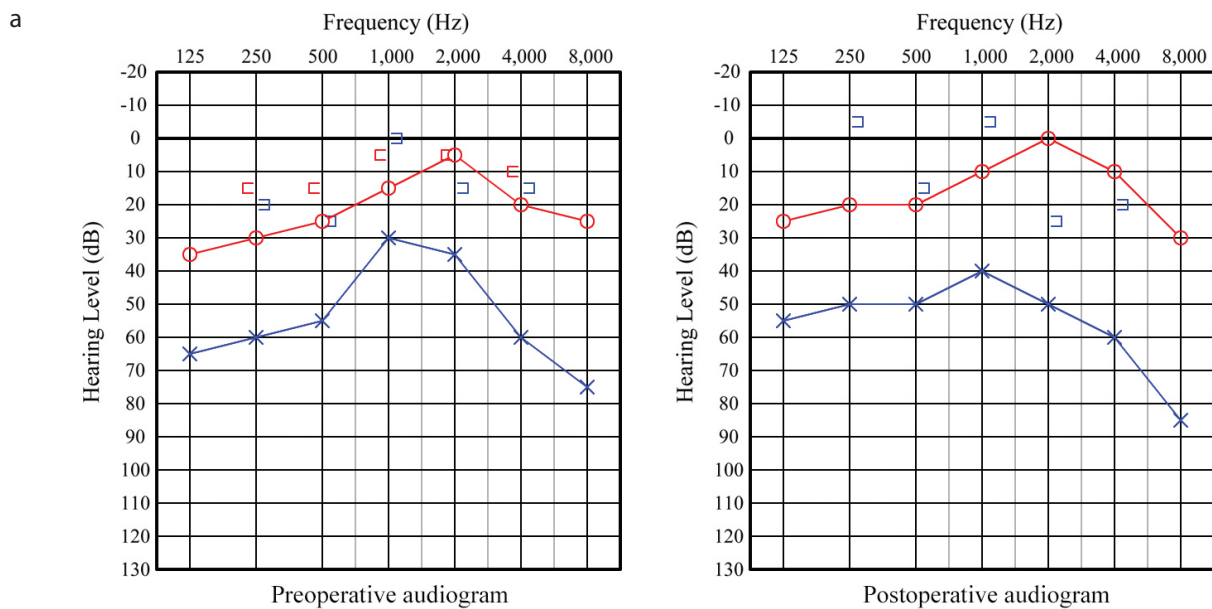
We have performed CT examinations for four months as part of the post-surgical follow-up, and pneumatization has not yet been ob-



**Figure 2. a-g.** Histopathology and immunohistochemical staining of the tumor. (a) The histopathological study shows a follicular pattern with a tumor island indicating peripheral palisading and central cystic degeneration (arrows) (hematoxylin and eosin stain, 160X). Immunohistochemistry studies showing the expression of (b) p40, (c) p63, (d) AE1/AE3, and (e) EMA. The tumor is negative for (f) synaptophysin and (g) chromogranin A. EMA, epithelial membrane antigen.



**Figure 3. a-c.** CT and MRI. a) axial, b) coronal, CT image. The soft tissue shadow is pervasive in the left middle ear cavity, and the thinning of the bony wall can be seen in the front of the tympanic cavity. (c) MRI. The Gd-enhanced signal (arrow) indicating a soft tissue tumor of the left tympanic cavity.  
CT: computed tomography; MRI: magnetic resonance imaging



**Figure 4. a-c.** Pre- and postoperative audiograms, view of the tympanum and image of the FDG-PET post-surgery. (a) Postoperatively, no improvement in the conductive hearing loss was observed. (b) After surgery for 8 months, the tympanic epithelialization is complete and in a dry state. (c) FDG-PET performed at the department of gastroenterology 6 months after surgery shows no malignant findings or signs of recurrence.  
FDG-PET: fluorodeoxyglucose positron emission tomography

served in the middle ear cavity. However, no enhanced mass in the middle ear cavity or bone destruction along the circumference has been observed. Fluorodeoxyglucose (FDG) positron emission tomography performed six months after surgery did not detect any abnormal accumulation of FDG in the middle ear cavity. Therefore, there is no reason to suspect a recurrence at the present time (Figure 4c). A year-and-a-half has elapsed since the surgery, and currently, no recurrence of tumor has been observed. However, owing to the high recurrence rate of ameloblastomas, follow-ups at short intervals of time are being conducted.

Written informed consent was obtained from the patient for publication of this case report and accompanying images.

## DISCUSSION

Ameloblastoma is one of the most common odontogenic tumors that develops from the odontogenic epithelium and primarily develops in the jawbone. According to Reichart et al.<sup>[1]</sup>, these tumors tend to commonly develop at the age of 10–20 years, in the molars, and the ascending ramus area of the mandible<sup>[1]</sup>. Ameloblastomas occurring outside the jawbone are known to be relatively rare, and although there are a certain number of reported cases, to the best of our knowledge, there are no reports that have primarily focused on its development in the middle ear cavity.

Ameloblastoma is a locally invasive tumor, and its malignant transformation and distant metastasis have been reported in the literature<sup>[2–4]</sup>, but it is considered to be a benign tumor according to the 2017 World Health Organization (WHO) classification. A typical ameloblastoma was regarded as a solid, multicystic type of tumor in the 2017 WHO classification and as a desmoplastic type in the 2005 WHO classification. Based on another subclassification, the tumor is considered to be of a unicystic, extraosseous, peripheral type. This classification is not based on histopathological features but on differences in macroscopic features. In addition, each tumor type is classified according to clinical epidemiological features, such as age distribution, common sites, image findings, and recurrence rates. A typical conventional ameloblastoma is often locally aggressive; therefore, various treatment regimens have been proposed. Because it often recurs locally, it is desirable to resect the peritumoral normal bones with a 1–2 cm margin of safety<sup>[5]</sup>. However, there are cases where the tumor forms change, and functional impairment is largely postoperatively. Frequently the primary site is difficult to resect with an adequate margin around the tumor, which is what happened to our case. Therefore, many cases are treated with conservative surgery, including curettage, physicochemical treatment with Carnoy's solution, or cryosurgery<sup>[6–9]</sup>. Resection of the tumor with a margin of 1–2 cm all around the normal bone could be considered either overtreatment or undertreatment. Therefore, following peripheral ostectomy, it is recommended to grind 2–3 mm of the remaining bone beyond the visible margin after resecting the gross tumor<sup>[10]</sup>. In our case, because we removed the tumor along with an extensive part of the middle ear mucosa, it was difficult to obtain an adequate margin. Moreover,

if the original tumor is in contact with the internal carotid artery, it is very difficult to add a margin, especially to that site. Therefore, we began conducting frequent follow-ups postoperatively at short time intervals, and to date, no findings of recurrence have been observed.

## CONCLUSION

We resected the tumor along with an extensive part of the middle ear mucosa, which made it difficult to have an adequate margin. It is recommended that the remaining bone be ground 2–3 mm beyond the visible margin after resecting the gross tumor. Therefore, several cases are treated with conservative surgery, including physicochemical treatment. This factor should be considered when designing treatment strategies as good alternatives in cases where resection with an adequate margin is difficult.

**Informed Consent:** Written informed consent was obtained from the patient who participated in this study.

**Peer-review:** Externally peer-reviewed.

**Author Contributions:** Concept – T.Y., H.M.; Design – T.Y., K.M.; Supervision – H.M., S.H.; Resource – T.Y., S.E.; Materials – H.N.; Data Collection and/or Processing – T.Y.; Analysis and/or Interpretation – K.M.; Literature Search – T.Y.; Writing – T.Y., K.M.; Critical Reviews – H.M., S.H.

**Conflict of Interest:** The authors have no conflict of interest to declare.

**Financial Disclosure:** The authors declared that this study has received no financial support.

## REFERENCES

1. Reichart PA, Philipsen HP, Sonner S. Ameloblastoma: biological profile of 3677 cases. *Eur J Cancer B Oral Oncol* 1995; 31B: 86–99. [\[CrossRef\]](#)
2. Baden E, Doyle JL, Petriella V. Malignant transformation of peripheral ameloblastoma. *Oral Surg Oral Med Oral Pathol* 1993; 75: 214–9. [\[CrossRef\]](#)
3. Jayaraj G, Sherlin HJ, Ramani P, Premkumar P, Natesan A, Ramasubramanian A, et al. Metastasizing ameloblastoma – a perennial pathological enigma? Report of a case and review of literature. *J Craniomaxillofac Surg* 2014; 42: 772–9. [\[CrossRef\]](#)
4. Luo DY, Feng CJ, Guo JB. Pulmonary metastases from an ameloblastoma: case report and review of the literature. *J Craniomaxillofac Surg* 2012; 40: 470–4. [\[CrossRef\]](#)
5. Carlson ER, Marx RE. The ameloblastoma: primary, curative surgical management. *J Oral Maxillofac Surg* 2006; 64: 484–94. [\[CrossRef\]](#)
6. Lee PK, Samman N, Ng IO. Unicystic ameloblastoma – use of Carnoy's solution after enucleation. *Int J Oral Maxillofac Surg* 2004; 33: 263–7. [\[CrossRef\]](#)
7. Sampson DE, Pogrel MA. Management of mandibular ameloblastoma: the clinical basis for a treatment algorithm. *J Oral Maxillofac Surg* 1999; 57: 1074–7. [\[CrossRef\]](#)
8. Curi MM, Dib LL, Pinto DS. Management of solid ameloblastoma of the jaws with liquid nitrogen spray cryosurgery. *Oral Surg Oral Med Oral Pathol Oral Radiol Endod* 1997; 84: 339–44. [\[CrossRef\]](#)
9. Pogrel MA, Montes DM. Is there a role for enucleation in the management of ameloblastoma? *Int J Oral Maxillofac Surg* 2009; 38: 807–12. [\[CrossRef\]](#)
10. Sachs SA. Surgical excision with peripheral ostectomy: a definitive, yet conservative, approach to the surgical management of ameloblastoma. *J Oral Maxillofac Surg* 2006; 64: 476–83. [\[CrossRef\]](#)