

Original Article

# Assessment of the Effectiveness of Quercetin on Cisplatin-Induced Ototoxicity in Rats

Ramazan Gündoğdu , Mustafa Erkan , Mesut Aydın , Mehmet Fatih Sönmez ,  
Alperen Vural , Kerem Kökoğlu , Derya Karabulut , Mehmet İlhan Şahin 

Department of Otolaryngology, Derince Training and Research Hospital, Kocaeli, Turkey (RG)

Department of Otolaryngology, Head and Neck Surgery, Erciyes University School of Medicine, Kayseri, Turkey (ME, AV, MİŞ)

Clinic of Otolaryngology, Kayseri City Hospital, Kayseri, Turkey (MA, KK)

Department of Histology, Erciyes University School of Medicine, Kayseri, Turkey (MFS, DK)

ORCID IDs of the authors: R.G. 0000-0002-8221-6862; M.E. 0000-0002-2441-9215; M.A. 0000-0001-8512-3306; M.F.S. 0000-0002-9811-5855; A.V. 0000-0002-1423-724X; K.K. 0000-0003-1749-7095; D.K. 0000-0001-5230-9286; M.İ.Ş. 0000-0002-9576-1448.

Cite this article as: Gündoğdu R, Erkan M, Aydın M, Sönmez MF, Vural A, Kökoğlu K, et al. Assessment of the Effectiveness of Quercetin on Cisplatin-Induced Ototoxicity in Rats. J Int Adv Otol 2019; 15(2): 229–36.

**OBJECTIVES:** This study aimed to evaluate the effect of quercetin on cochlear function and morphology, and its possible protective effect against acute cisplatin-induced ototoxicity in rats.

**MATERIALS and METHODS:** This prospective and controlled animal study was conducted on Wistar albino rats divided into four groups. Otoacoustic emission measures were performed three days after the first infiltration in Group 1 (saline), 2 (cisplatin), and 3 (quercetin). This interval was five days for Group 4 (cisplatin+quercetin). At the end of the study, the rats were decapitated with deep anesthesia, and histological changes in the cochleas were observed by light microscopy.

**RESULTS:** Group 2 (cisplatin) revealed significant differences between the first and second measures in all frequencies. When compared to other group, the difference of the changes in Group 2 statistically significantly decreased, especially in higher frequencies. Morphologically, there were no acute changes in Group 1 and Group 3. Outer hair cell loss and the degeneration of stria vascularis and spiral ganglion were observed in both Groups 2 and 4; the damages in the latter were lesser.

**CONCLUSION:** Quercetin does not have negative effect on cochlea, and it has protective effect on cisplatin-induced ototoxicity.

**KEYWORDS:** cisplatin, ototoxicity, antioxidants, flavonoids, quercetin

## INTRODUCTION

Cisplatin is a deoxyribonucleic (DNA) alkylating antineoplastic agent that is commonly used in the treatment of solid tumors such as of head and neck, testicle, ovary, breast, and lung <sup>[1]</sup>. Although cisplatin is an effective antineoplastic agent, it has serious side effects. Nephrotoxicity and ototoxicity are the most important dose-limiting factors. While nephrotoxicity can be controlled with hydration, irreversible ototoxicity is still a hindrance in cisplatin chemotherapy <sup>[2]</sup>.

The ototoxic effect that occurs after cisplatin use is a side effect that limits life quality and changes treatment strategies. Its use causes irreversible sensorineural hearing loss that involves both ears and affects especially the high frequencies <sup>[3]</sup>. Cochlear damage and loss of outer hair cells are related to a large number of chemical events. Reactive oxygen and nitrogen species that develop after cisplatin exposure are the primary reasons that cause ototoxicity by creating serious damage in hair cell membranes <sup>[2]</sup>.

The anti-inflammatory, anti-allergic, anti-viral, and anti-carcinogenic properties of quercetin, a derivative of bioflavonoids, have been shown in experimental studies. It has been reported to be a strong antioxidant that decreases the effects of reactive oxygen species <sup>[4]</sup>. This study aimed to investigate experimentally through otoacoustic emission tests and histopathological methods whether quercetin, which has a strong antioxidant effect, has ototoxic effects on the inner ear and protective effects from cisplatin treatment.

**Corresponding Address:** Kerem Kökoğlu E-mail: dr.kokoglu@gmail.com

**Submitted:** 07.08.2018 • **Revision Received:** 12.11.2018 • **Accepted:** 21.11.2018 • **Available Online Date:** 09.07.2019

Available online at [www.advancedotology.org](http://www.advancedotology.org)



Content of this journal is licensed under a  
Creative Commons Attribution-NonCommercial  
4.0 International License.

## MATERIALS AND METHODS

After obtaining approval from the local ethics committee for animal experiments (decision number 12/78) and convenient power analysis, 32 adult female Wistar albino rats with an average weight of 222 g (range: 190–269 g) were used in the study. All the rats were raised under equal conditions and with standard diet. Because it was an experimental animal study, informed consent was not needed. The rats were kept in an environment where they could freely get food and water, with light for 12 hours and dark for 12 hours, and a temperature of  $21^{\circ}\text{C} \pm 1^{\circ}\text{C}$ . All procedures conducted on the rats were in line with the Helsinki declaration and international animal research principles and guidelines.

In this study, 64 ears of 32 rats were included. Before the study, all the subjects were assessed in terms of external acoustic canals and tympanic membranes by otomicroscopic examination (Opmi 1, Zeiss, Germany). The animals with an external canal pathology such as hyperemia, edema, or infection, and those that showed indications of middle ear pathology such as dull appearing tympanic membrane and hyperemia, were excluded from the study. Rats that died during monitoring were excluded, and new rats were included to complete the numbers in the groups.

At the beginning of the study, the distortion product otoacoustic emissions (DPOAE) test was applied on both ears of all rats. Rats that did not respond to the DPOAE test before the procedures were excluded from the study. After all measurements were completed, decapitation was performed by placing the rats in deep anesthesia, and temporal bones were fixed in formalin for histological evaluation.

### Formation of the Groups

Four groups, each one consisting of eight rats, were formed for the study. The research groups were determined as follows:

1. **Control group (n=8):** To this group, 1.5 ml i.p. normal saline (NS) was given for three days.
2. **Cisplatin group (n=8):** To this group, one dose 16 mg/kg i.p. cisplatin (Cisplatin, Faulding Pharmaceuticals, Warwickshire, UK) was given to create acute ototoxicity [5].
3. **Quercetin group (n=8):** To this group, 50 mg/kg i.p. quercetin (Quercetin, Sigma Aldrich, Darmstadt, Germany) prepared in NS was given for three days.
4. **Cisplatin+quercetin group (n=8):** This group was given 50 mg/kg i.p. quercetin for two days + one dose 16 mg/kg i.p. cisplatin on the third day [5] + 50 mg/kg i.p. quercetin on the fourth and fifth days.

### Anesthesia

All rats were given intramuscular ketamine hydrochloride 50 mg/kg (Ketalar, Pfizer, Istanbul, Turkey), xylazine 5 mg/kg (Rompun 2%, Bayer, Kansas, USA) intraperitoneally, and applications were made after anesthesia.

### DPOAE Test Application

In this study, the DPOAE test was used to examine emissions. It was applied to both ears of the first three groups at the beginning of the

study and three days after the first measurement. The test was applied to the last group at the beginning of the study and five days after the first measurement. In the assessment of the test, the signal noise rate (SNR) was used, which was determined by extracting the distortion product in decibels from the environment noise emission rate. The DPOAE measurements were made using a newborn probe with a Madsen Capella (Otometrics; Taastrup, Denmark) otoacoustic emission measurement device. The rate between  $f_2$  and  $f_1$  frequencies ( $f_2/f_1$ ) was kept at 1.22. The difference between L1 and L2 levels was kept at 10 dB SPL (L1=65 dB SPL, L2=55 dB SPL). DPOAEs were measured at a frequency of  $2f_1-f_2$ . SNRs at 1500, 2000, 3000, 4000, 6000, and 8000 Hz in the geometrical averages of DPOAE,  $f_1$  and  $f_2$  were recorded.

### Histopathological Examination

Temporal bones were placed in 4% formaldehyde solution for 15 days. Subsequently, they were decalcified in 10% formic acid solution for 15 days. After decalcification, tissues were washed overnight in flowing tap water. The specimens were dehydrated by immersion in increasing concentrations of alcohol, and then cleared with multiple xylene washes. Tissue blocks were then embedded in paraffin wax. Sections 5–6  $\mu\text{m}$  thick were cut from the paraffin blocks and mounted on polylysine-coated slides. Sections were deparaffinized by heating in a dry oven at  $55^{\circ}\text{C}$ – $60^{\circ}\text{C}$  for 60 minutes, and then immersed for the third time in fresh xylene for 10 minutes. The sections were rehydrated by immersion in decreasing concentrations of alcohol. The sections were stained with hematoxylin (Merck; Darmstadt, Germany) and eosin (Merck; Darmstadt, Germany) (H&E) to evaluate general histological structure using a light microscope (Olympus; Center Valley, PA, USA).

### Statistical Analysis

The Statistical Package for the Social Sciences (SPSS) 22.0 program (IBM Corp.; Armonk, NY, USA) was used for statistical analysis. The Kruskal–Wallis method was used to test whether the rats in each of the four groups at the beginning of the study were random samples in terms of the DPOAE values. This method was also used to analyze whether there were significant differences between the right and left ears of the rats at the beginning of the study in terms of the DPOAE values. Paired t-test (Wilcoxon signed rank test) was used to test whether there were significant differences between DPOAE values at the beginning and later for each group and frequency level. The ANOVA test was used to compare the differences in changes between the first and second measurements of each group. The thickness of stria vascularis was analyzed with one-way ANOVA with post-hoc comparisons done using the Tukey HSD test. The value of  $p < 0.05$  was accepted as statistically significant.

## RESULTS

There was no wound infection. Four rats in Group 2 (cisplatin) and two rats in Group 4 (cisplatin+quercetin) died because of diarrhea, and they were excluded.

### Assessment of Results of DPOAE

Statistical analysis was started by finding the standard deviation averages of mean value and mean values. No statistically significant differences were found among the pre-study mean values of all groups ( $p > 0.05$ ). Similarly, no significant differences were found between

**Table 1.** Table showing the pre-medication and post-medication signal to noise rates of all the groups

Hz		Control group	Cisplatin group	Quercetin group	Cisplatin+quercetin group
2000	Pre-medication	6.138±0.831	4.313±0.810*	5.419±0.831	4.006±1.790
	Post-medication	7.087±0.769	0.194±1.42*	5.619±0.730	1.981±1.311
3000	Pre-medication	9.275±1.258	7.581±0.308*	8.706±0.590	8.969±1.306
	Post-medication	8.163±0.458	4.256±1.317*	7.613±0.925	6.019±0.924
4000	Pre-medication	6.406±1.582	7.169±0.638*	8.669±1.755	5.681±1.273
	Post-medication	6.056±1.223	-1.500±1.555*	9.031±1.438	5.194±1.067
6000	Pre-medication	6.681±0.928	7.025±1.071*	5.069±3.021	4.444±1.459
	Post-medication	6.956±0.956	-8.525±1.218*	7.988±1.904	1.719±1.349
8000	Pre-medication	5.688±0.841	4.913±1.000*	6.594±2.777	4.100±1.670
	Post-medication	6.919±0.923	7.675±1.301*	6.550±1.086	1.569±1.581

\*P values were significant statistically at all frequencies in cisplatin group.

the right ears and left ears of the samples ( $p>0.05$ ). Because the basal measurement values at 1500 Hz were low for each group in terms of both amplitude and SNR values, they were not included in the study (Table 1).

**Group 1 (Control group):** No statistically significant differences were found for all frequencies of this group, which was given NS between pre-medication and post-medication in terms of the DPOAE results ( $p>0.05$ ) (Figure 1).

**Group 2 (Cisplatin group):** When the post-medication SNR values were compared with the first measurement, a statistically significant drop was found for all frequencies of the group given one dose 16 mg/kg cisplatin ( $p<0.05$ ) (Figure 2).

**Group 3 (Quercetin group):** No statistically significant difference was found for all frequencies of the group given 50 mg/kg quercetin between pre-medication and post-medication in terms of the DPOAE results ( $p>0.05$ ) (Figure 3).

**Group 4 (Cisplatin+quercetin group):** When pre-i.p. injection and post-i.p. injection SNR values were compared, no statistically significant difference was found for all frequencies of the quercetin treatment group ( $p>0.05$ ) (Figure 4).

When each group was assessed within the group itself after i.p. injections, no significant differences were found between right ear and left ear ( $p>0.05$ ).

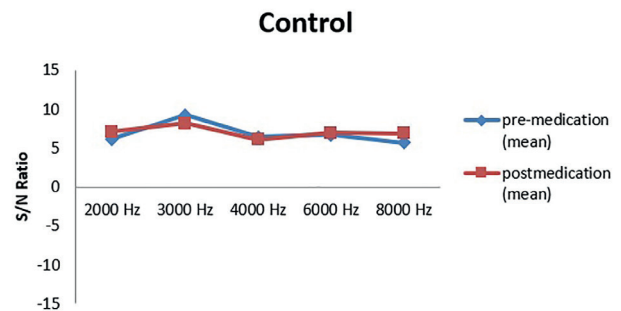
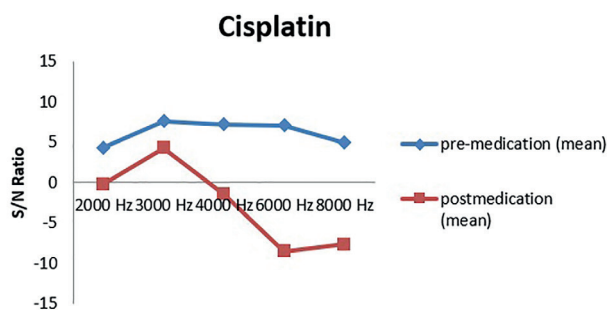
No significant differences were found for all frequencies between the first group (control group) and the third group (quercetin group) in terms of intergroup change after i.p. injections ( $p>0.05$ ). When the fourth group (cisplatin+quercetin group) was compared with the first and third groups in terms of differences in change, no significant differences were found at 2000, 3000, and 4000 Hz for both groups; while significant differences were found at 6000 Hz for the third group and at 8000 Hz for the first group. When the second group (cisplatin group) was compared with the other groups, no significant differences were found for all groups only at 3000 Hz ( $p>0.05$ ). In addition, for the second group, while no significant difference was found with the

**Table 2.** Thickness of stria vascularis

	Stria vascularis thickness ( $\mu$ m)
Control	23.27±0.33
Cisplatin	25.14±0.36* ( $p=0.002$ )
Quercetin	22.19±0.26
Cisplatin+quercetin	23.34±0.43

Values were given as mean±standard error of mean.

\* compared to control group  $p<0.05$

**Figure 1.** Graph showing the S/N ratios in the control group.**Figure 2.** Graph showing the S/N ratios in the cisplatin group.

fourth group at 2000 Hz in terms of differences in change, significant differences were found for all groups when compared with the other groups ( $p<0.05$ ) (Figure 5).

### Histopathological Examination Results

Stria vascularis, organ of Corti, and spiral ganglion were assessed with light microscopy. The analysis showed vacuolization in marginal cells of the stria vascularis, dilated and congested veins, and wall thickness in the group that was given cisplatin. In the cisplatin+quercetin group, while there was a decrease in these histopathological results, degeneration still continued. Normal stria vascularis structure was found in the control group and quercetin only group. Besides the degeneration, the thickness of stria vascularis of the cisplatin+quercetin group was similar to the control and quercetin only group ( $p>0.05$ ). The thickness of stria vascularis was found to be significantly increased only in the group given cisplatin ( $p=0.002$ ) (Table 2). The OHC loss was found in the organ of Corti in the group given cisplatin.

This loss was less in the group given cisplatin+quercetin. The quercetin only group was similar to the control group. Eosinophilic-dyed degenerated spiral ganglion cells were found in the cisplatin only group. In the cisplatin+quercetin group, there were degenerated ganglion cells; however, they were less in number. The quercetin only group was similar to the control group (Figures 6-7).

### DISCUSSION

Cisplatin is an effective antineoplastic agent that was introduced to clinical use in the 1970s. It is commonly used chemotherapeutically

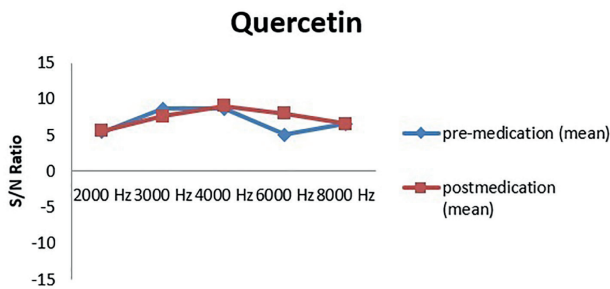


Figure 3. Graph showing the S/N ratios in the quercetin group.

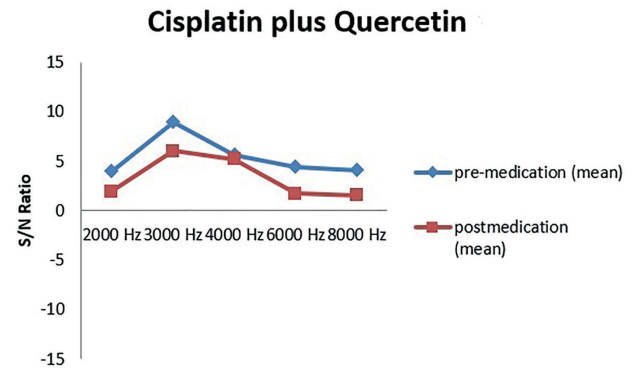


Figure 4. Graph showing the S/N ratios in the cisplatin+quercetin group.

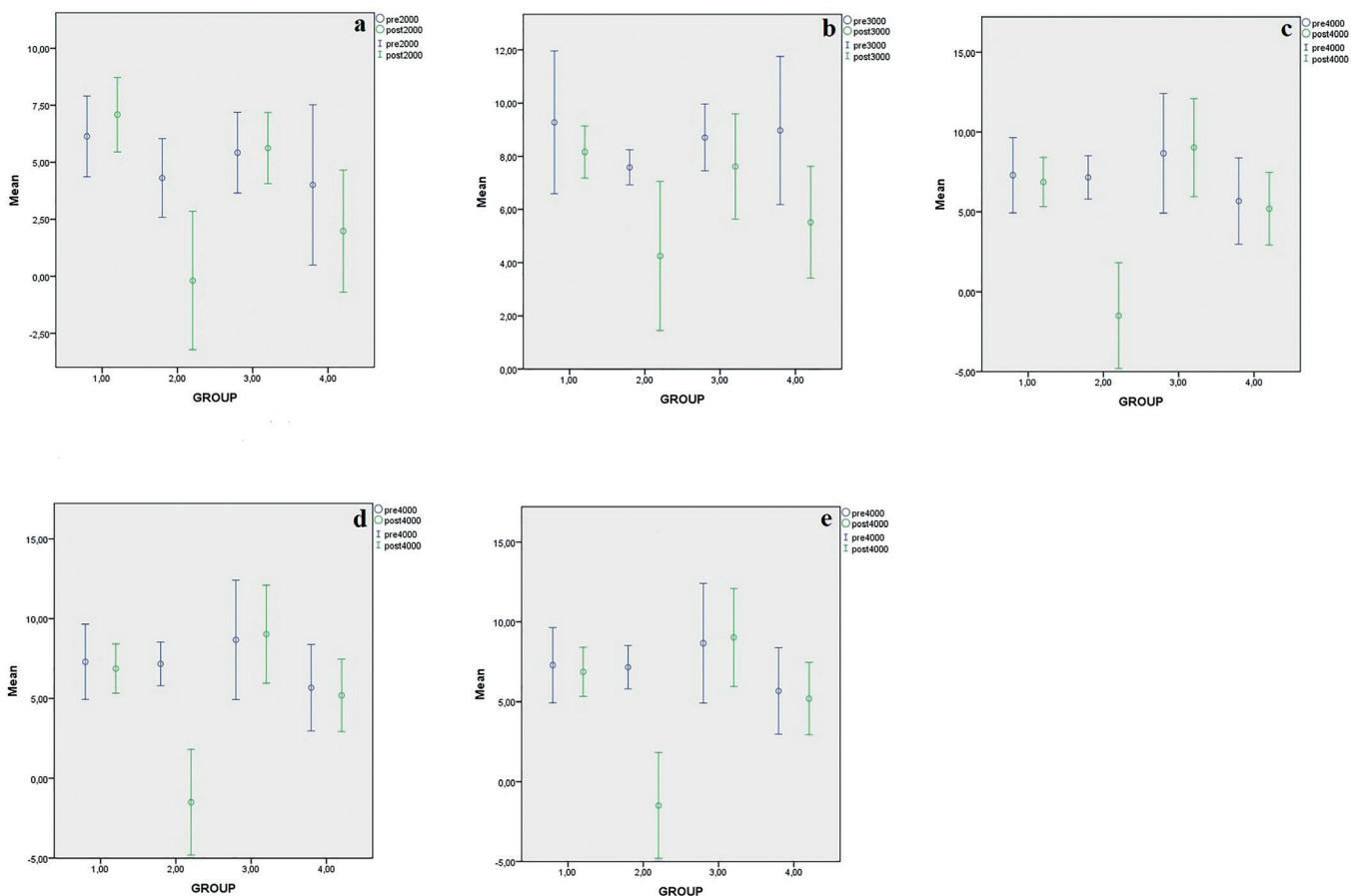


Figure 5. Distribution of data according to groups and frequencies. a: 2000 Hz, b: 3000 Hz, c: 4000 Hz, d: 6000 Hz, e: 8000 Hz.

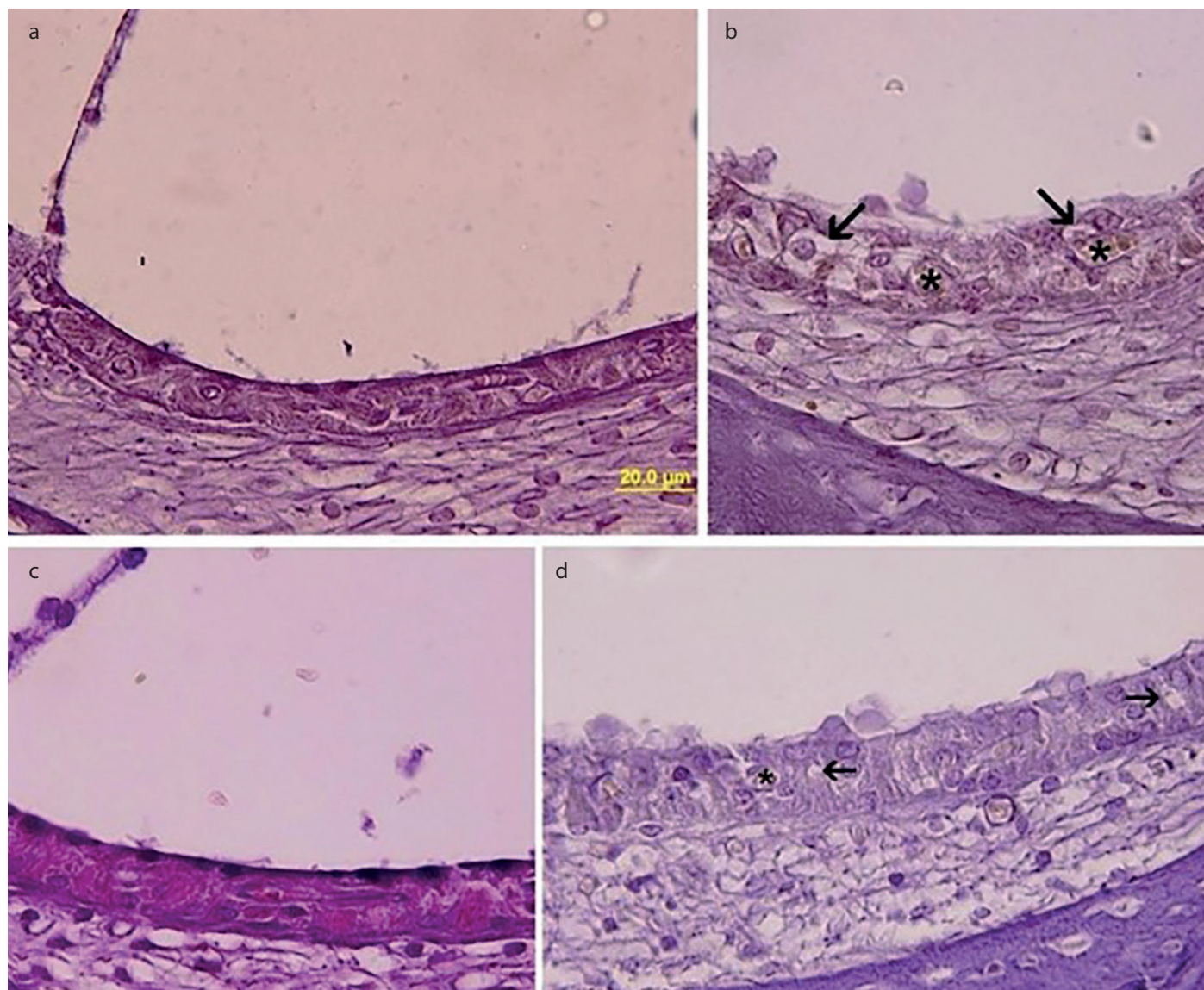


with neoadjuvant or concomitant palliative purposes. The ototoxic effect that occurs after cisplatin use is a side effect that affects the quality of life and changes the treatment strategy. Ototoxicity becomes obvious depending on the age and dose, and it may cause difficulty in learning and talking especially in children [6]. As a result of cisplatin use, a rise is observed in hearing threshold for 60%-80% of patients [7,8].

Frequently observed complaints are hearing loss, tinnitus, and otalgia [9]. Hearing loss due to cisplatin use is generally two-sided, and it starts first at high frequencies [10]. The ototoxic effect generally occurs on the second day of treatment [11]. In our study, a decrease in DPOAE responses was seen 72 hours after cisplatin use, which was more obvious at high frequencies.

Early and correct detection of cisplatin ototoxicity is very important. A large number of methods are used in ototoxicity monitoring. Both the ABR test and the OAE test are effectively used in ototoxicity monitor-

ing. Sockalingam et al. [12] reported OAE and ABR as sensitive diagnosis methods for cisplatin ototoxicity. Hatzoupolus et al. [13] argued in their study that although the ABR test is generally used in ototoxicity studies, the ABR responses are formed as a result of the integration of all nerve fibers, and thus OAE will be more effective in showing cochlear micro-mechanics in ototoxicity. In addition to these, OAE, an indicator of OHC functions, is a reliable and frequently used hearing test in ototoxicity studies. When OAEs are compared, DPOAE is superior to TOAE because of its high frequency selectivity [14]. In our study, we used the DPOAE test to show ototoxic effects because of its aforementioned characteristics. Studies conducted on ototoxicity have used DPOAE amplitude as an assessment parameter in the DPOAE analysis; however, for the assessment of DPOAE responses, the SNR rate is more reliable than the DPOAE amplitudes because emission amplitudes and noise threshold in measurements conducted at different times may change, and the DPOAE amplitudes may be influenced by respiratory sounds and noise in the environment [13,15]. By considering these factors, we preferred to use the SNR ratio in our study.



**Figure 6. a-d.** The appearance of stria vascularis. a) control, b) the group given cisplatin, congested dilated veins (\*) and vacuolization in marginal cells (arrow), c) only quercetine group d) cisplatin and quercetin group, congested dilated veins (\*) and vacuolization in marginal cells (arrow) less when compared with the cisplation group. (Hematoxylin&Eosin Scale bar=20  $\mu$ m).

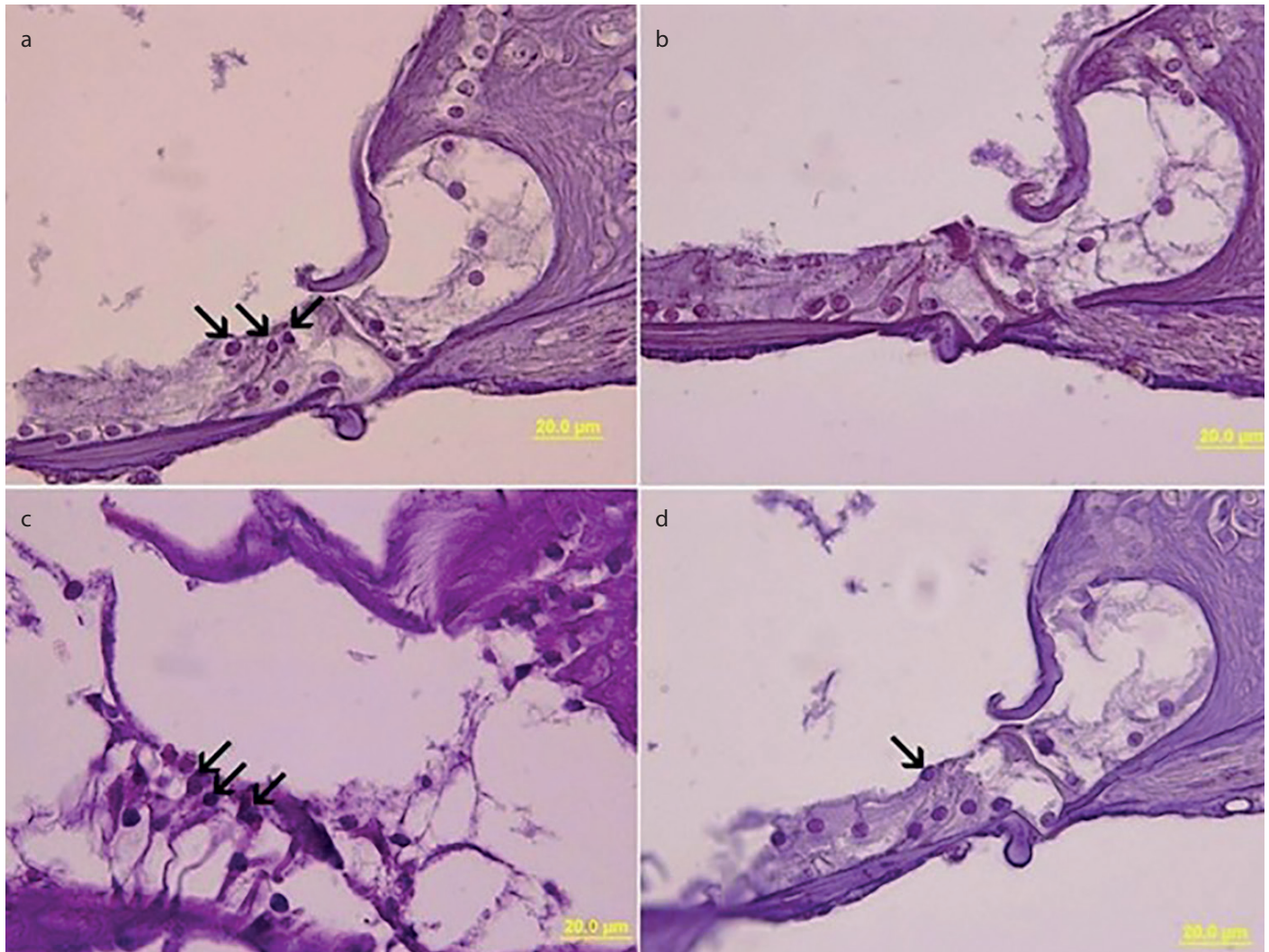
Although the histopathology of cisplatin ototoxicity is well defined, the underlying mechanism of hearing loss is not fully clear. Originally, morphological changes in the organ of Corti damage starts from the first-line OHCs at the basal fold of the cochlea, progresses to OHCs, and affects the inner hair cells. Cisplatin affects the spiral ganglion and stria vascularis as well as the organ of Corti [11, 16, 17]. Studies of cisplatin ototoxicity show that the main factor enabling the formation of ototoxicity is reactive oxygen products (ROPs) [11, 18, 19].

ROPs in the cochlea can develop because of reasons such as old age, ototoxic drugs, and noise. ROPs as a result of cisplatin ototoxicity causes an increase in the amount of malondialdehyde, which indicates lipid peroxidation, while causing a decrease in the amount of antioxidant enzymes [2]. Direct binding of cisplatin to sulfhydryl groups in the antioxidant enzyme structure, a decrease in the amount of copper and selenium, which are essential for superoxide dismutase and glutathione peroxidase activity, a decrease in glutathione and the cofactor nicotinamide adenine dinucleotide phosphate, which are essential for glutathione peroxidase and glutathione peroxidase activity, cause a decrease in cochlear antioxidant enzyme activity [2, 20]. Increase in nitric oxide synthesis because of cisplatin exposure also

has an important effect on ototoxicity. The peroxynitrite super radical, which consists of especially a superoxide and nitrite oxide combination, stimulates lipid peroxidation and causes hairy cell membrane damage. Lipid peroxidation increases the input of calcium to cochlear cells and causes apoptosis [2, 21, 22]. Whatever the reason, it is obvious that ROPs increase in cochlea after cisplatin exposure, and there is a change in the antioxidant protection system that will resist this.

The fact that quercetin used in our study has the potential to decrease the toxic effects of ROPs with its characteristics such as cleaning peroxy, superoxide, singlet oxygen, alkoxy and hydroxyl radicals, inhibiting superoxide anion production through xanthine oxidase, breaking the lipid peroxy chain, chelating transition metals such as iron and copper and decreasing calcium intake into cells, led us to consider that it could possibly be an effective antioxidant agent against cisplatin ototoxicity [23-26].

A large number of animal experiments have been conducted to investigate the pathology of cisplatin ototoxicity and to develop treatment plans. Antioxidant agents have been frequently used to overcome the negative effects of ROPs [27]. The quercetin used in our



**Figure 7. a-d.** Apperance of the organ of corti. a) control, outer hair cells (arrow) can be recognized, b) cisplatin group, OHC's cannot be recognized due to damage, c) only quercetine group, OHC's (arrow) can be recognized, d) cisplatin and quercetine group, one OHC (arrow) can be recognized, (Hematoxylin&Eosin dying. Scale bar=20 µm).



study is a flavonoid derivative, and it has been used in a large number of studies because of its strong antioxidant properties [23, 25]. Thus, it can be thought that damage through ROP can play an effective role in protection against a large number of diseases. The effects of quercetin on the inner ear and its possible protective effect from cisplatin exposure was a subject that had not been studied before when the literature was reviewed, except for a trial with zebra fish embryos [28]. Thus, our study is a preliminary study on this topic.

Quercetin has not only an antioxidant effect but also anti-cancer and anti-proliferative effects [29, 30]. It could probably contribute anti-tumor effect of cisplatin. Scambia et al. reported synergistic effect of cisplatin+quercetin on human ovarian cancer [31]. In the same way, Jacubowicz et al. showed that quercetin increased the pro-apoptotic effect of cisplatin [32]. It seems that quercetin has no negative impact on anti-tumor effect of cisplatin.

Both DPOAE responses and histological studies have shown quercetin to have no negative effects on the cochlea. The thickness and structure of the stria vascularis, the number of OHCs, and the spiral ganglion morphology were similar to those of the control group. At the same time, no significant differences were found in the DPOAE test between the two groups in terms of both pre-application and post-application SNR averages.

Quercetin becomes oxidized and turns to quercetin-quinone, which is an oxidation product and displays various toxic effect [33]. Although this effect was proven by in vitro methods, in vivo formation and possible toxicity of quercetin-quinone has not been demonstrated yet [34, 35]. It may be concluded that quercetin, at estimated dietary intake levels, would not produce adverse health effects [35].

In the group that was given cisplatin, there were morphological increases in stria vascularis thickness, stria edema, protrusion of marginal cells to endolymphatic space, vacuolization, and congested-dilated structures. Although these changes were also present in the group given cisplatin+quercetin, the amount of damage was less than in the group given cisplatin. In terms of the organ of Corti, the OHC loss was found to be greater in the group given cisplatin than in the treatment group given cisplatin+quercetin. Similarly, the nuclear degeneration rate in the spiral ganglion area was found to be greater than in the cisplatin group. In light of these results, we can say that quercetin provides protection, although partial, in three target areas that cause cisplatin ototoxicity.

Although there are no studies in the literature that have analyzed the effect of quercetin on cisplatin ototoxicity, the effects of a great number of antioxidant agents on cisplatin ototoxicity have been investigated. The agents that have been used in studies that used DPOAES as an assessment parameter have presented different results. While there are studies that have shown that different agents given with cisplatin prevent decreases in SNR rates at every frequency, there are also studies that reported negative results [13, 36-38]. In our study, when SNR values were analyzed, while there were decreases in all groups with cisplatin, especially at high frequencies, although the SNR values decreased in the cisplatin+quercetin group, no statistically significant difference was found when compared with the pre-application values. When intergroup change differences were compared, significant differences

were found in SNR values at 8000 Hz in the comparison of the cisplatin+quercetin treatment group, while a significant difference was found in SNR values at 4000 Hz and higher frequencies in the comparison of the cisplatin group with all the other groups. Although decreases were found at 8000 Hz when compared with the control group, it was found that the emission response was significantly protected when compared with the group that was given cisplatin.

The OHC damage seen in both groups that were given cisplatin was found to cause changes in the SNR values. Because high-dose cisplatin was applied in our group, the amount of damage was shown both morphologically and otoacoustically. Therefore, when compared with the cisplatin group, the protection provided by the treatment group in both otoacoustic emission tests and histopathology, especially similar thickness of stria vascularis between the cisplatin+quercetin and control group, indicates that quercetin was a good antioxidant that could be used in decreasing the negative effects of not only cisplatin but also other ototoxic agents, when the effective dose, time, and mode of application are taken into consideration [39].

In addition to these points, because we evaluated cisplatin toxicity in an acute stage in our study, we believe that it is necessary to assess the long-term results of cisplatin ototoxicity, and to plan and conduct electron microscopy studies that would better show morphology.

## CONCLUSION

Quercetin use alone does not have a negative effect on the inner ear. Cisplatin causes a decrease in the DPOAE responses that is more obvious especially at high frequencies. In light of DPOAE responses and morphological results, quercetin has been found to have a protective effect against ototoxicity induced by cisplatin.

**Ethics Committee Approval:** Ethics committee approval was received for this study from the Erciyes University Local Ethics Committee for Animal Experiments (Decision Number: 12/78).

**Informed Consent:** N/A.

**Peer-review:** Externally peer-reviewed.

**Author Contributions:** Concept – R.G., M.E., M.F.S.; Design – R.G., M.A., A.V.; Supervision – M.E., M.I.S., M.F.S.; Resource – R.G., D.K., K.K.; Materials – R.G., M.A., A.V.; Data Collection and/or Processing – R.G., A.V., K.K.; Analysis and/or Interpretation – R.G., M.F.S., D.K.; Literature Search – R.G., A.V., M.I.S.; Writing – R.G., M.A., K.K.; Critical Reviews – M.E., A.V., M.I.S.

**Conflict of Interest:** The authors have no conflict of interest to declare.

**Financial Disclosure:** This study was supported with by Erciyes University Scientific Research Projects Commission with the Project code number TSU-12- 4120.

## REFERENCES

1. Rybak L, Ramkumar V. Ototoxicity. *Kidney Int* 2007; 72: 931-5. [CrossRef]
2. Rybak LP, Husain K, Morris C, Whitworth C, Somani S. Effect of protective agents against cisplatin ototoxicity. *Am J Otol* 2000; 21: 513-20.
3. Brock P, Bellman S. Ototoxicity of cisplatin. *Br J Cancer* 1991; 63: 159-60. [CrossRef]
4. Middleton E, Kandaswami C, Theoharides TC. The effects of plant flavonoids on mammalian cells: implications for inflammation, heart disease, and cancer. *Pharmacol Rev* 2000; 52: 673-751.

5. Lynch ED, Gu R, Pierce C, Kil J. Reduction of acute cisplatin ototoxicity and nephrotoxicity in rats by oral administration of allopurinol and eb-selen. *Hear Res* 2005; 201: 81-9. [\[CrossRef\]](#)
6. Knight KRG, Kraemer DF, Neuwelt EA. Ototoxicity in children receiving platinum chemotherapy: underestimating a commonly occurring toxicity that may influence academic and social development. *J Clin Oncol* 2005; 23: 8588-96. [\[CrossRef\]](#)
7. Blakley BW, Gupta AK, Myers SF, Schwan S. Risk factors for ototoxicity due to cisplatin. *Arch Otolaryngol Head Neck Surg* 1994; 120: 541-6. [\[CrossRef\]](#)
8. Laurell G, Jungnelius U. High-Dose cisplatin treatment: Hearing loss and plasma concentrations. *Laryngoscope* 1990; 100: 724-34. [\[CrossRef\]](#)
9. Stringer S, Meyerhoff W, Wright C. Ototoxicity. *Otolaryngology* 1991; 2: 1653-70.
10. Fausti SA, Henry JA, Schaffer HI, Olson DJ, Frey RH, Bagby GC. High-frequency monitoring for early detection of cisplatin ototoxicity. *Arch Otolaryngol Head Neck Surg* 1993; 119: 661-6. [\[CrossRef\]](#)
11. van Ruijven MW, de Groot JC, Klis SF, Smoorenburg GF. The cochlear targets of cisplatin: an electrophysiological and morphological time-sequence study. *Hear Res* 2005; 205: 241-8. [\[CrossRef\]](#)
12. Sockalingam R, Freeman S, Cherny L, Sohmer H. Effect of high-dose cisplatin on auditory brainstem responses and otoacoustic emissions in laboratory animals. *Am J Otol* 2000; 21: 521-7.
13. Hatzopoulos S, Di Stefano M, Albertin A, Martini A. Evaluation of cisplatin ototoxicity in a rat animal model. *Ann NY Acad Sci* 1999; 884: 211-25. [\[CrossRef\]](#)
14. Lonsbury-Martin BL, Martin GK. Evoked otoacoustic emissions as objective screeners for ototoxicity. *Seminars in Hearing: Thieme Medical Publishers, Inc.*
15. de Freitas MR, da Silva VC, de Castro Brito GA, de Carvalho JV, Gomes RM, de Albuquerque Ribeiro R. Distortion-product otoacoustic emissions and auditory brainstem responses sensitivity assessment in cisplatin-induced ototoxicity in rats. *Braz J Otorhinolaryngol* 2009; 75: 476-84. [\[CrossRef\]](#)
16. Hinojosa R, Riggs LC, Strauss M, Matz GJ. Temporal bone histopathology of cisplatin ototoxicity. *Am J Otol* 1995; 16: 731-40.
17. Sluyter S, Klis SF, de Groot JC, Smoorenburg GF. Alterations in the stria vascularis in relation to cisplatin ototoxicity and recovery. *Hear Res* 2003; 185: 49-56. [\[CrossRef\]](#)
18. Kopke R, Allen KA, Henderson D, Hoffer M, Frenz D, van de Water T. A radical demise: toxins and trauma share common pathways in hair cell death. *Ann NY Acad Sci* 1999; 884: 171-91. [\[CrossRef\]](#)
19. Rybak LP, Whitworth CA, Mukherjee D, Ramkumar V. Mechanisms of cisplatin-induced ototoxicity and prevention. *Hear Res* 2007; 226: 157-67. [\[CrossRef\]](#)
20. Pigeolet E, Corbisier P, Houbion A, Lambert D, Michiels C, Raes M, et al. Glutathione peroxidase, superoxide dismutase, and catalase inactivation by peroxides and oxygen derived free radicals. *Mech Ageing Dev* 1990; 51: 283-97. [\[CrossRef\]](#)
21. Banfi B, Malgrange B, Knisz J, Steger K, Dubois-Dauphin M, Krause K-H. NOX3, a superoxide-generating NADPH oxidase of the inner ear. *J Biol Chem* 2004; 279: 46065-72. [\[CrossRef\]](#)
22. Dehne N, Lautermann J, Petrat F, Rauen U, De Groot H. Cisplatin ototoxicity: involvement of iron and enhanced formation of superoxide anion radicals. *Toxicol Appl Pharmacol* 2001; 174: 27-34. [\[CrossRef\]](#)
23. Bors W, Heller W, Michel C, Saran M. Radical chemistry of flavonoid antioxidants. *Antioxidants in therapy and preventive medicine: Springer*; 1990. p. 165-70. [\[CrossRef\]](#)
24. Casagrande R, Georgetti SR, Verri WA, Jabor JR, Santos AC, Fonseca MJ. Evaluation of functional stability of quercetin as a raw material and in different topical formulations by its antiperooxidative activity. *AAPS PharmSciTech* 2006; 7: E64-E71. [\[CrossRef\]](#)
25. de Groot H, Rauen U. Tissue injury by reactive oxygen species and the protective effects of flavonoids. *Fundam Clin Pharmacol* 1998; 12: 249-55. [\[CrossRef\]](#)
26. Moskaug JØ, Carlsen H, Myhrstad M, Blomhoff R. Molecular imaging of the biological effects of quercetin and quercetin-rich foods. *Mech Ageing Dev* 2004; 125: 315-24. [\[CrossRef\]](#)
27. Rybak LP, Whitworth CA. Ototoxicity: therapeutic opportunities. *Drug Discov Today* 2005; 10: 1313-21. [\[CrossRef\]](#)
28. Lee S, Oh K, Chung A, Park HC, Lee S, Kwon S, et al. Protective role of quercetin against cisplatin-induced hair cell damage in zebrafish embryos. *Hum Exp Toxicol* 2015; 34: 1043-52. [\[CrossRef\]](#)
29. Murakami A, Ashida H, Terao J. Multitargeted cancer prevention by quercetin. *Cancer Lett* 2008; 269: 315-25. [\[CrossRef\]](#)
30. Salucci M, Stivala L, Maiani G, Bugianesi R, Vannini V. Flavonoids uptake and their effect on cell cycle of human colon adenocarcinoma cells (Caco2). *Br J Cancer* 2002; 86: 1645-51. [\[CrossRef\]](#)
31. Scambia G, Ranelletti F, Benedetti PP, Bonanno G, De RV, Piantelli M, et al. Synergistic antiproliferative activity of quercetin and cisplatin on ovarian cancer cell growth. *Anticancer Drugs* 1990; 1: 45-8. [\[CrossRef\]](#)
32. Jakubowicz-Gil J, Paduch R, Piersiak T, Głowniak K, Gawron A, Kandefer-Szerszeń M. The effect of quercetin on pro-apoptotic activity of cisplatin in HeLa cells. *Biochem Pharmacol* 2005; 69: 1343-50. [\[CrossRef\]](#)
33. Kalyanaraman B, Premovic P, Sealy RC. Semiquinone anion radicals from addition of amino acids, peptides, and proteins to quinones derived from oxidation of catechols and catecholamines. An ESR spin stabilization study. *J Biol Chem* 1987; 262: 11080-7.
34. Boots AW, Haenen GR, Bast A. Health effects of quercetin: from antioxidant to nutraceutical. *Eur J Pharmacol* 2008; 585: 325-37. [\[CrossRef\]](#)
35. Harwood M, Danielewska-Nikiel B, Borzelleca J, Flamm G, Williams G, Lines T. A critical review of the data related to the safety of quercetin and lack of evidence of in vivo toxicity, including lack of genotoxic/carcinogenic properties. *Food Chem Toxicol* 2007; 45: 2179-205. [\[CrossRef\]](#)
36. Daldal A, Odabasi O, Serbetcioglu B. The protective effect of intratympanic dexamethasone on cisplatin-induced ototoxicity in guinea pigs. *Otolaryngol Head Neck Surg* 2007; 137: 747-52. [\[CrossRef\]](#)
37. Hatzopoulos S, Stefano MD, Campbell K, Falgione D, Ricci D, Rosignoli M, et al. Cisplatin Ototoxicity in the Sprague Dawley Rat Evaluated by Distortion Product Otoacoustic Emissions. *Audiology* 2001; 40: 253-64. [\[CrossRef\]](#)
38. Watanabe K-i, Hess A, Michel O, Yagi T. Nitric oxide synthase inhibitor reduces the apoptotic change in the cisplatin-treated cochlea of guinea pigs. *Anticancer Drugs* 2000; 11: 731-5. [\[CrossRef\]](#)
39. Sagit M, Korkmaz F, Gürgeç SG, Gundogdu R, Akcadag A, Özcan I. Quercetin attenuates the gentamicin-induced ototoxicity in a rat model. *Int J Pediatr Otorhinolaryngol* 2015; 79: 2109-14. [\[CrossRef\]](#)