

Original Article

Extra-Cochlear Insertion in Cochlear Implantation: A Potentially Disastrous Condition

Emine Deniz Gözen , Fırat Tevetoğlu , Haydar Murat Yener , Eyüp Kara , Ahmet Ataş , Sabri Şirolu , Osman Kızılkılıç , Harun Cansız , Emin Karaman 

Department of Otorhinolaryngology, İstanbul University-Cerrahpaşa, Cerrahpaşa School of Medicine, İstanbul, Turkey (EDG, FT, HMY, HC, EK)

Department of Audiology, İstanbul University, School of Health Science, İstanbul, Turkey (E.Kara, AA)

Department of Radiodiagnostic, İstanbul University-Cerrahpaşa, Cerrahpaşa School of Medicine, İstanbul, Turkey (SS, OK)

ORCID IDs of the authors: E.D.G.0000-0002-2586-3721; F.T.0000-0002-1744-6995; H.M.Y. 0000-0002-0932-2773; E.Kara. 0000-0002-4015-4560; A.A. 0000-0002-8673-6793; S.S. 0000-0002-8443-0838; O.K. 0000-0002-6620-8934; H.C. 0000-0002-1954-2067; E.K. 0000-0001-9035-861X.

Cite this article as: Gözen ED, Tevetoğlu F, Yener HM, Kara E, Ataş A, Şirolu S, et al. Extra-Cochlear Insertion in Cochlear Implantation: A Potentially Disastrous Condition. J Int Adv Otol 2019; 15(3): 358-63.

OBJECTIVES: Cochlear implantation is an increasingly used technique for auditory rehabilitation of pediatric and adult population. Safe implantation is achieved in most cases; however, intraoperative complications and misplacement of the electrode are observed in some. The aim of this presentation was to review the characteristics of patients with extra-cochlear electrode insertion, postoperative diagnostic methods, and considerations in revision surgery.

MATERIALS and METHODS: In total, 423 cases of cochlear implantation performed in our clinic between 2012 and 2018 were retrospectively analyzed and those of extra-cochlear implantation were evaluated.

RESULTS: Extra-cochlear insertion was found in 3 patients. The electrode was placed into the internal acoustic canal in the first case, superior semicircular canal in the second case, and internal carotid artery canal in the third case. Cochlear insertion was achieved in all cases with re-implantation, and no complication was observed.

CONCLUSION: This case series highlights that rare, but potentially serious, consequences of misplacement of the electrode in cochlear implantation can be successfully avoided and treated via a multidisciplinary approach.

KEYWORDS: Cochlear implant, extra-cochlear insertion, revision cochlear implantation, intraoperative complication

INTRODUCTION

Cochlear implantation is an effective intervention in the treatment of very advanced total hearing loss in particular ^[1]. The most important factors for successful implantation include assessment of the middle and inner ear structures with preoperative imaging, appropriate patient selection with advanced audiological evaluation, suitable surgical technique, and postoperative intense auditory rehabilitation. Results of cochlear implantation are quite satisfactory with low complication rates. The most common causes of revision are surgical site infections, malfunctioning of the device, and misplacement of the electrode ^[2]. Among these, problems pertaining to the surgical site are encountered in 0.26%-2.09% patients, whereas misplacement of electrode is observed in 0.17%-2.12% patients ^[3]. Extra-cochlear electrode is usually inserted into the hypotympanum owing to confusion with the round window, especially in the presence of a large hypotympanic or infralabyrinthine air cell, and into the semicircular canals owing to the incorrect angle of insertion ^[3,4].

Cochlear malformations constitute the most significant risk factor in extra-cochlear insertion, and the risk varies according to the type of malformation. Insertion into the internal acoustic canal is common in a malformed cochlea. Misplacement of the electrode can also be seen in ears without a malformation owing to a lack of experience and incorrect angle of insertion. Misplacement of the electrode, which can potentially lead to serious consequences, should be diagnosed immediately, and an experienced surgeon should achieve correct insertion by re-implantation.

This study was presented at the "National Turkish Otorhinolaryngology Congress", "Nov 07-11, 2018", "Antalya", "Turkey".

Corresponding Address: Emine Deniz Gözen E-mail: nazas39@hotmail.com

Submitted: 11.12.2018 • **Revision Received:** 04.03.2019 • **Accepted:** 05.03.2019 • **Available Online Date:** 24.07.2019

Available online at www.advancedotology.org



Content of this journal is licensed under a Creative Commons Attribution-NonCommercial 4.0 International License.

In this case series, cases of electrode misplacement will be described and patient characteristics, postoperative diagnostic methods, and appropriate revision surgery techniques will be discussed.

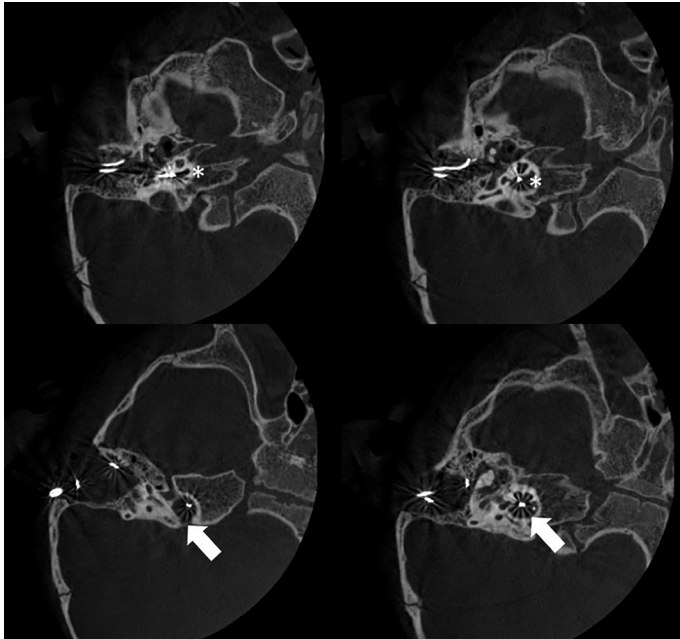


Figure 1. Axial view CT: cochlear implant electrodes reach the internal acoustic canal (white arrow) from the base of the cochlea (asterix).

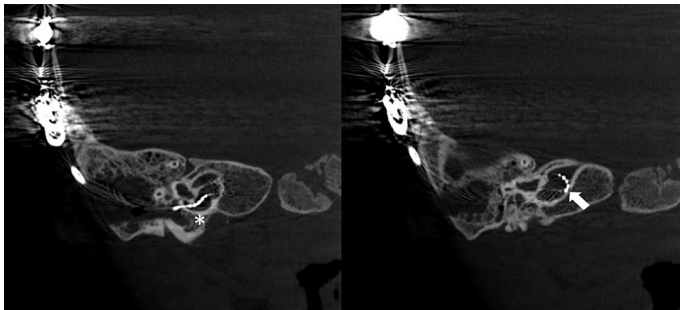


Figure 2. Coronal view CT: cochlear implant electrodes reach the internal acoustic canal (white arrow) from the base of the cochlea (asterix).

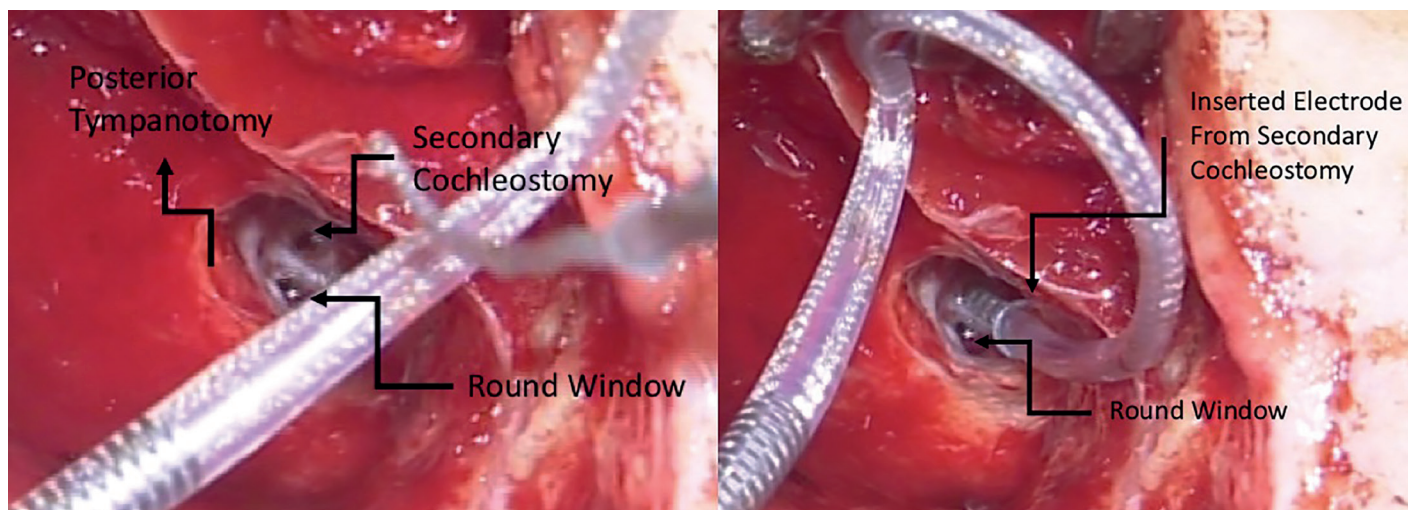


Figure 3. The electrode was inserted from round window directed into internal acoustic canal; therefore, insertion into the cochlea was successfully achieved through a second cochleostomy from anterior-inferior.

MATERIALS AND METHODS

Patient Evaluation

In total, 423 cases of cochlear implantation performed in our clinic between 2012 and 2018 were retrospectively analyzed, and cases with extra-cochlear implantation were evaluated. In this review, 3 patients with extra-cochlear insertion were detected. The study was performed with the approval of Ethics Committee. Written informed consent was obtained from all patients and patient families. Intra-operative neural response telemetry (NRT) measurements were performed with Med-El Maestro 6.0 (Med-El GmbH, Innsbruck, Austria) for case 1, in which MED-EL FORM 19 (Med-El GmbH, Innsbruck, Austria) was used. For cases 2 and 3, in which Nucleus slim straight electrode (Cochlear Co. Ltd., Sydney, Australia) was used, NRT was measured using Custom Sound 5.1 (Cochlear Co. Ltd., Sydney, Australia). Post-operative anteroposterior and lateral X-ray imaging (Optilux, Siemens, Erlangen, Germany) was performed. In addition, to visualize temporal bone and inner ear anatomy, cone-beam computerized tomography (AlluraClarity, Philips, Eindhoven, Netherlands) was used in cases 1 and 3, although high-resolution computerized tomography (Somatom Sensation, Siemens, Erlangen, Germany) was used in case 2.

Statistical Analysis

Demographics of the patients were calculated by MS Office Excel program.

RESULTS

Retrospective review of the charts revealed 3 cases of extra-cochlear implantation of the electrode.

Case 1: Internal Acoustic Canal Insertion

A 1.5-year-old patient with bilateral profound hearing loss was subjected to standard preoperative assessment, and cochlear implantation was decided. Preoperative imaging revealed incomplete partition (IP) type III, and necessary arrangements were made. The round window was visualized via standard mastoidectomy and facial recess approach. The round window niche was drilled, and membrane incision was performed. Cerebrospinal fluid (CSF) gusher was

encountered upon opening the membrane. The patient was placed in the appropriate position, and the electrode was inserted after the gusher decreased. The round window was obliterated with soft tissue and fibrin glue, and the operation was completed. NRT responses were not obtained intraoperatively, but this was thought to be the result of the gusher and/or electrode being in a large cavity owing to the malformation. Postoperative lateral and anteroposterior cranial X-rays revealed that the electrode seemed to be in correct position but was located deeper than the usual site of the base of the cochlea. Because the patient had a previously known cochlear malformation, misplacement of the electrode was suspected, and the position of the electrode was assessed via computerized tomography (CT). CT revealed that the electrode was located in internal acoustic canal (IAC), and the patient underwent revision surgery on day 2 (Figures 1 and 2). During revision surgery, repetitive interventions through the round window were performed, but NRT showed unsatisfactory response for each insertion. The electrode array was thought to be advancing into IAC as a result of the persisting CSF gusher. Therefore, a cochleostomy from approximately 2 mm anteroinferior to the round window was created as a secondary opening, and the electrode array was advanced through this cochleostomy (Figure 3). NRT revealed response from 8 electrodes, despite any response from apical electrodes (Figure 4). Postoperative CT confirmed the correct electrode position (Figure 5). No complications were observed in the postoperative period, and the patient was referred to rehabilitation after fitting.

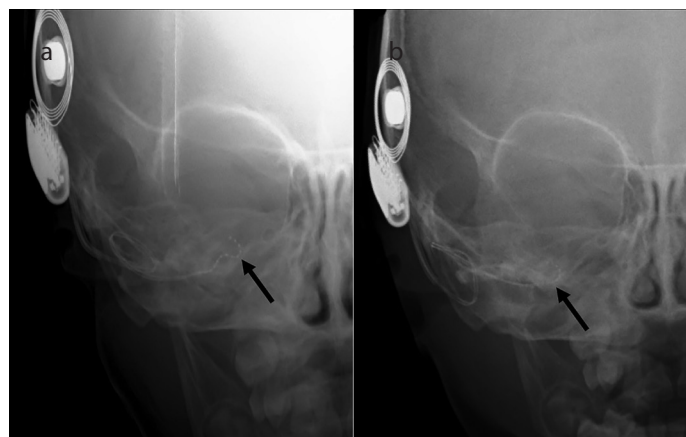


Figure 4. a, b. Electrode positions (black arrows) before (a) and after (b) revision surgery.

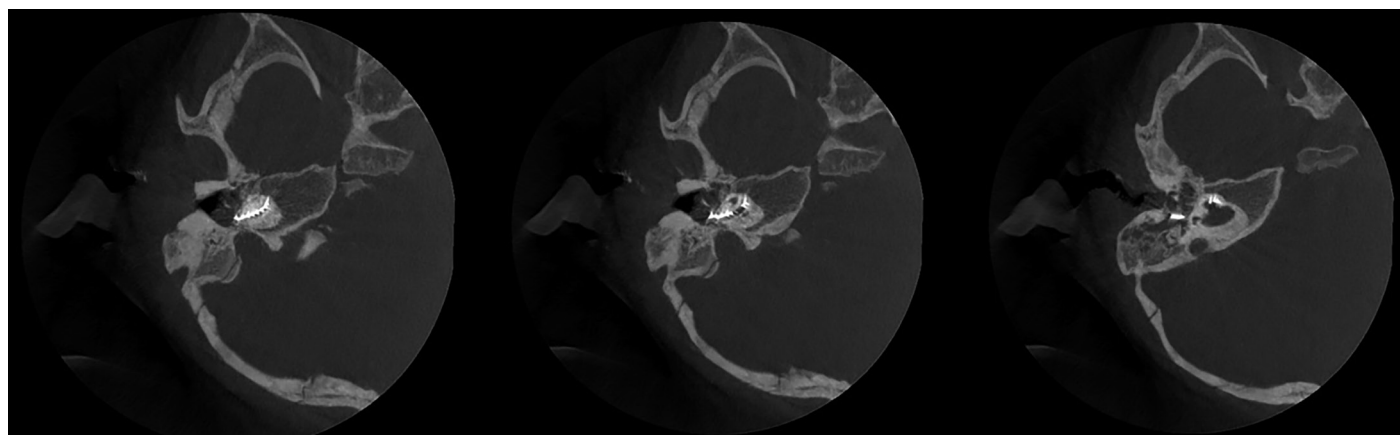


Figure 5. Axial view CT: electrodes within the cochlea after revision surgery.

Case 2: Superior Semicircular Canal Insertion

A 2-year-old female with diagnosis of bilateral profound hearing loss underwent audiological tests, preoperative thin-slice CT and magnetic resonance imaging, and speech and language evaluations; cochlear implantation was decided. No cochlear malformation was found on preoperative assessment. Right-ear cochlear implantation through the round window via standard mastoidectomy and facial recess approach was performed. No perioperative complications were encountered. Intraoperative electrophysiological measurements revealed normal impedance values. However, NRT tests yielded no response from apical electrodes. The patient had severe nausea, vomiting, and right-beating nystagmus in the postopera-

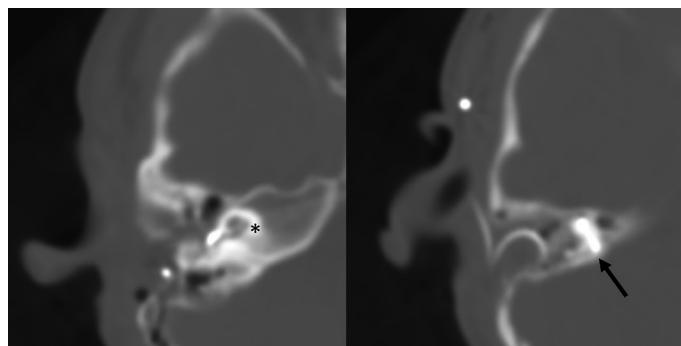


Figure 6. Cochlear implant electrode in superior semicircular canal (black arrow) in axial CT (asterix: cochlea).

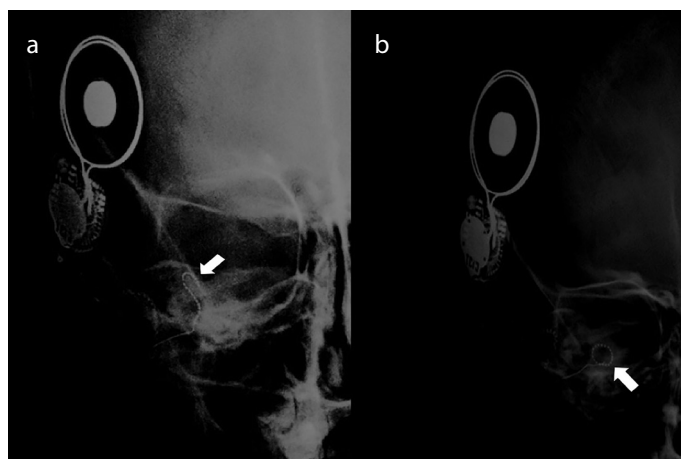


Figure 7. a, b. Anteroposterior X-ray showing electrode (white arrow) in superior semicircular canal before revision (a) and intracochlear electrode after revision (b).

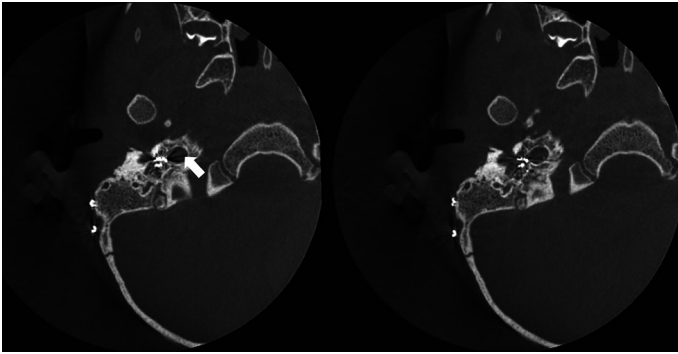


Figure 8. Axial CT showing electrodes directed into internal carotid canal (white arrow) instead of the cochlea.

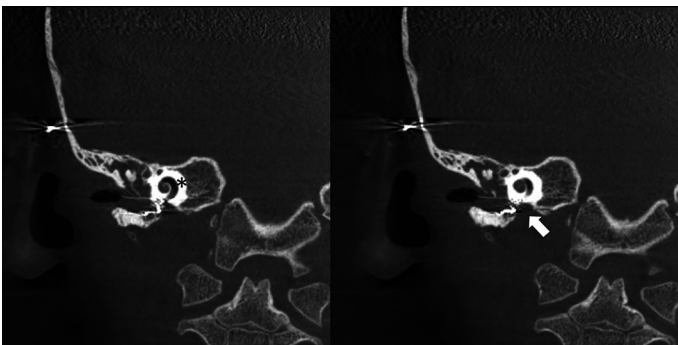


Figure 9. Coronal CT showing electrodes directed into internal carotid canal (white arrow) instead of the cochlea (asterix).

tive period. X-ray imaging revealed misplacement of the electrode, and a CT was performed. CT scans showed that the electrode was inserted into the superior semicircular canal (Figures 6 and 7). The patient underwent revision surgery on the same day. The electrode was removed, and the round window was enlarged. The basal turn of the cochlea was visualized, and successful cochlear insertion was achieved by directing the electrode inferiorly. Electrophysiological tests showed normal results. Anteroposterior X-ray confirmed the accurate electrode position (Figure 7). No postoperative complications were observed, and the patient was discharged on postoperative day 2 without complications.

Case 3: Internal Carotid Artery Canal Insertion

A 2-year-old male with bilateral total hearing loss went through standard preoperative assessment, and cochlear implantation was decided. The middle ear was visualized via standard mastoidectomy and facial recess approach. The round window niche could not be visualized, and a cochleostomy was performed. The opening created was considered as the basal turn of the cochlea, and the electrode was inserted. However, no NRT was achieved during intraoperative electrophysiological evaluation, and cochlear implantation surgery was terminated with a decision of performing early postoperative temporal bone CT; CT scans showed that the electrode was in the internal carotid canal in the hypotympanic area (Figures 8 and 9). Preoperative and recent radiologic images were thoroughly reviewed, and hypotympanic cells were observed to be dismissed preoperatively. Revision surgery was performed on postoperative day 3 by 2 experienced surgeons. Promontorium was visualized, and the electrode was observed to be advancing to the hypotympanum. The angle of the microscope and therefore the vision was revised to see the approximate location of the round window, cochlea was entered

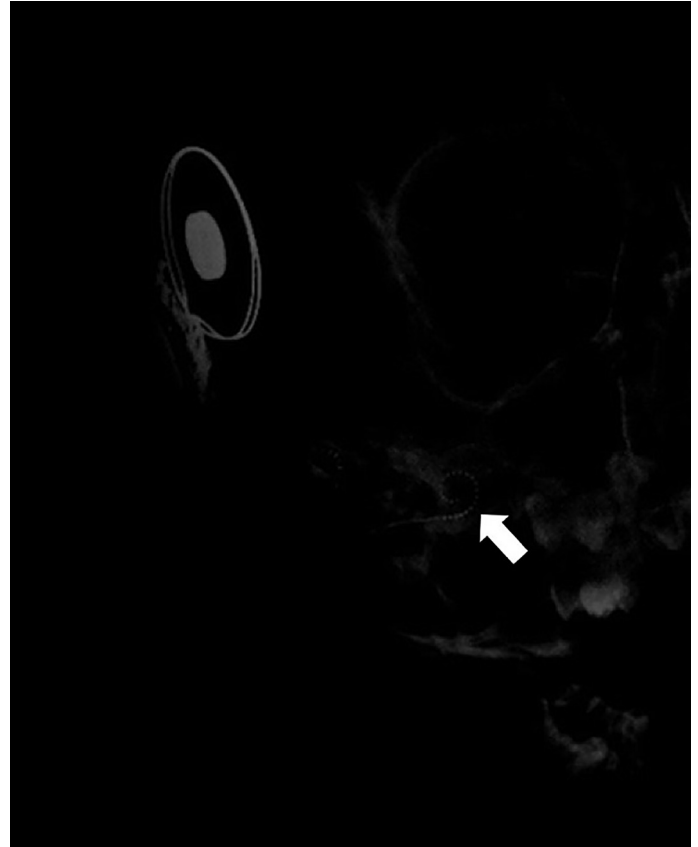


Figure 10. Intracochlear electrodes (white arrow) after revision surgery.

through the cochleostomy and the electrode was inserted. Electrophysiological evaluation demonstrated NRT from all electrodes and the operation was completed. Anteroposterior X-ray imaging confirmed the correct position of electrode (Figure 10). No postoperative complications were observed, and the patient was discharged on the day 2.

DISCUSSION

Standard surgical steps in cochlear implantation include visualization of the round window via facial recess approach and electrode insertion into the scala tympani through the round window. Insertion of the electrode in any place other than scala tympani is rare; it is observed in approximately 0.2%-5.8% of all cochlear implantation cases and leads to failure of postoperative auditory rehabilitation.^[5] Misplacement of the electrode may result in injury to neurovascular structures inside the IAC, facial nerve, and carotid artery^[5]. Recognizing the reference points, performing appropriate surgical techniques, and thoroughly evaluating images obtained via preoperative imaging lead to successful implantation in the scala tympani. The final position of the electrode is confirmed via electrophysiological tests and postoperative imaging.

Cochlear abnormalities are major risk factors for extra-cochlear insertion of the electrode, and the associated risks vary according to the type of malformation. Sennaroglu^[6] reported that the risk of IAC insertion is increased especially in cases with type I IP, type III IP, and common cavity. IAC insertion can be particularly observed in IP type III cases owing to irregular ossification of the basal turn of cochlea^[7,8]. The risk of CSF gusher is also increased in these patients. Cochlear mal-

formations can be diagnosed with preoperative imaging. Our first case was diagnosed with type III IP preoperatively, and necessary intraoperative precautions were taken owing to the risk of CSF gusher. However, irregular ossification of the basal turn and severe gusher led the electrode to be directed into IAC. IAC insertion is rare in the literature; it is difficult to advance the electrode into the cochlea, and this results in repetitive attempts of insertion^[9]. Similarly, normal insertion cannot be achieved despite many attempts during revision surgery. Incesulu et al.^[7] reported that withdrawal of the electrode may lead to successful implantation in these patients. Conversely, Wootten et al.^[8] stated that accurate position can be achieved by the drill-out technique, which had been previously described by Balkany^[9]. The drill-out technique is usually performed in ossified cochlea, where drilling is continued until a lumen is reached. If no lumen is encountered, cochleostomy is extended superiorly to check the patency of the scala vestibule, and if scala vestibuli is also ossified, the drill-out procedure should be conducted. In this technique, with the use of a 1-mm drill, the anterior part of the previously created tunnel, 8 mm distal to round window, is reached, and the basal turn of the cochlea is unroofed from that point. Drilling is continued anteriorly and superiorly along the basal turn, and then posteriorly and inferiorly through the second turn of the cochlea until a patent part of the cochlea is reached. Then, electrode is inserted through facial recess, cochleostomy, basal turn tunnel and patent part found in the second turn of the cochlea. By following the basal turn in this procedure, the misplacement of the electrode in anomalous inner ear may be prevented.

In IAC insertion cases, the electrode can direct to their previous incorrect position during re-implantation, and Todt et al.^[10] reported that this can be avoided by leaving the first electrode in its inaccurate place and inserting a second electrode during revision surgery. In our case, we opened a second cochleostomy to enable accurate insertion. With the help of this second cochleostomy, CSF gusher pressure was decreased, and the electrode was accurately inserted in a new direction.

Misplacement of the cochlear electrode can still be encountered in patients with normal inner ear anatomy. Electrode can be directed particularly into the superior or lateral semicircular canal throughout the vestibule^[3, 11]. Misplacement of the electrode usually occurs as a result of performing the cochleostomy at a wrong angle^[3]. Another mechanism is damaging the basilar membrane during cochleostomy and advancing the electrode into the vestibule through this damaged area^[12]. In our second case, the electrode was inserted into the superior semicircular canal even though the patient had no cochlear malformation. In this case, we believe that the angle of the round window caused misdirection of the electrode. In revision surgery, accurate insertion was achieved by widening the round window. Vestibular symptoms may be observed after cochlear implantation, but the possibility of intra-vestibular electrode insertion should not be ignored^[1, 13]. In our case, postoperative early vestibular symptoms and the presence of nystagmus led to the suspicion of vestibular insertion; therefore, temporal bone CT was performed, and CT revealed that the electrode was in the superior semicircular canal. Methods including widening of cochleostomy antero-inferiorly and canal-wall-down procedure can be performed in revision surgery for these patients^[14]. We achieved successful re-implantation by creating a more suitable angle via widening the round window anteroinferiorly.

In the literature, carotid canal insertion is reported very infrequently. Carotid canal insertion can result in very serious consequences owing to the risk of potential carotid artery damage. Carotid artery, by not being exactly adherent to the canal wall, can create a potential space within the canal. The bone between cochlea and carotid artery is thin, and the carotid can follow its course very closely to basal turn of cochlea (1.2 mm on average)^[15]. Also, the presence of hypotympanic air cell can be confused with the round window, causing interventions to this area^[16]. To avoid this complication, preoperative imaging should be performed and the scans should be carefully assessed, and the distance between the carotid artery and cochlea should be measured. In our case, misplacement occurred owing to misjudgment of the hypotympanic cell as a round window and the electrode being inserted into the carotid canal by widening this area. Images obtained via electrophysiological tests and postoperative X-ray imaging created the suspicion of extra-cochlear insertion and those obtained via CT revealed carotid canal insertion. In revision surgery, recognizing the normal anatomic guides provided the detection of the usual site of cochleostomy, and implantation was successfully achieved.

By presenting our cases of electrode malposition as a complication of cochlear implant surgery, we wish to underline the importance of postoperative imaging and electrophysiological assessment. Unusual symptoms or exaggeration of usual symptoms should arouse the suspicion of misplacement. It must be kept in mind that any suspicion necessitates detailed imaging, preferably with high-resolution CT because routine X-ray will not be sufficient for detecting malposition. We also wish to point out that especially in patients with cochlear abnormality, intraoperative confirmation of electrode position can be possible with mobile cone-beam CT, if available,^[17, 18] which was not available in our cases.

CONCLUSION

Even though complication rates of cochlear implant surgery are low, extra-cochlear electrode insertion can lead to potentially serious consequences. In these cases, intraoperative electrophysiological tests and postoperative X-ray images can indicate this inaccuracy and CT scans can confirm the diagnosis. In this paper, our experiences with IAC, superior semicircular canal, and carotid canal insertions were discussed. Following meticulous evaluation of postoperative imaging, we advise experienced surgeons to perform revision surgery for electrode misplacements.

Ethics Committee Approval: Ethics Committee Approval was received for this study from the Ethics Committee of Istanbul University-Cerrahpaşa, Cerrahpaşa School of Medicine.

Informed Consent: Written informed consent was obtained from the patients who participated in this study.

Peer-review: Externally peer-reviewed.

Author Contributions: Concept – E.D.G., H.M.Y., F.T.; Design – E.D.G., H.M.Y., E.Kara; Supervision – A.A., H.C., E.K., O.K.; Resource – E.D.G., S.S., F.T., E.Kara; Materials – E.D.G., O.K., H.C., E.K.; Data Collection and/or Processing – E.D.G., F.T., H.M.Y., S.S.; Analysis and/or Interpretation – H.M.Y., E.Kara; Literature Search – F.T., S.S.; Writing – E.D.G., H.M.Y., F.T.; Critical Reviews – H.M.Y., H.C., E.K.

Conflict of Interest: The authors have no conflict of interest to declare.

Financial Disclosure: The authors declared that this study has received no financial support.

REFERENCES

1. Mecca AM, WagleW, Lupinetti A, Parnes S. Complication of cochlear implantation surgery. *AJNR Am J Neuroradiol* 2003; 24: 2089-91.
2. Webb RL, Lehnhardt E, Clark GM, Laszig R, Pyman BC, Franz BK-HG. Surgical complications with the cochlear multiple-channel intracochlear implant: experience at Hannover and Melbourne. *Ann Otol Rhinol Laryngol* 1991; 100: 131-6. [\[CrossRef\]](#)
3. Tange RA, Grolman W, Maat A. Intracochlear misdirected implantation of a cochlear implant. *Acta Otolaryngol* 2006; 126: 650-2. [\[CrossRef\]](#)
4. Ramalingam R, Ramalingam KK, Padmaja HS. An unusual occurrence in cochlear implantation surgery: misplaced electrode. *J Laryngol Otol* 2009; 123: e4. [\[CrossRef\]](#)
5. Ying YL, Lin JW, Oghalai JS, Williamson RA. Cochlear implant electrode misplacement: incidence, evaluation, and management. *Laryngoscope* 2013; 123: 757-66. [\[CrossRef\]](#)
6. Sennaroglu L. Cochlear implantation in inner ear malformations-a review article. *Cochlear Implants Int* 2010; 11: 4-41. [\[CrossRef\]](#)
7. Incesulu A, Adapinar B, Kecik C. Cochlear implantation in cases with incomplete partition type III (X-linked anomaly). *Eur Arch Otorhinolaryngol* 2008; 265: 1425-30. [\[CrossRef\]](#)
8. Wootten CT, Backous DD, Haynes DS. Management of cerebrospinal fluid leakage from cochleostomy during cochlear implant surgery. *Laryngoscope* 2006; 116: 2055-9. [\[CrossRef\]](#)
9. Balkany T, Bird PA, Hodges AV, Luntz M, Telischi FF, Buchman C. Surgical technique for implantation of the totally ossified cochlea. *Laryngoscope* 1998; 108: 988-92. [\[CrossRef\]](#)
10. Todt I, Rademacher G, Ernst A. Identification and revision of a displaced cochlear implant electrode in the internal auditory canal. *Cochlear Implants Int* 2013; 14: 236-9. [\[CrossRef\]](#)
11. Pau H, Parker A, Sanli H, Gibson WP. Displacement of electrodes of a cochlear implant into the vestibular system: intra- and postoperative electrophysiological analyses. *Acta Otolaryngol* 2005; 125: 1116-8. [\[CrossRef\]](#)
12. Pau H, Parker A, Sanli H, Gibson WPR. Displacement of electrodes of a cochlear implant into vestibular system: intra- and postoperative electrophysiological analyses. *Acta Otolaryngol* 2005; 125: 1116-8. [\[CrossRef\]](#)
13. Sorrentino T, Coté M, Eter E, Laborde ML, Cochard N, Deguine O, et al. Cochlear reimplantations: technical and surgical failures. *Acta Otolaryngol* 2009; 129: 380-4. [\[CrossRef\]](#)
14. Muzzi E, Boscolo-Rizzo P, Santarelli R, Beltrame MA. Cochlear implant electrode array misplacement: a cautionary case report. *J Laryngol Otol* 2012; 126: 414-7. [\[CrossRef\]](#)
15. Young RJ, Shatzkes DR, Babb JS, Lalwani AK. The cochlear-carotid interval: anatomic variation and potential clinical implications. *AJNR Am J Neuroradiol* 2006; 27: 1486-90.
16. Woolford TJ, Saeed SR, Boyd P, Hartley C, Ramsden RT. Cochlear reimplantation. *Ann Otol Rhinol Laryngol Suppl* 1995; 166: 449-53.
17. Bloom JD, Rizzi MD, Germiller JA. Real-time intraoperative computed tomography to assist cochlear implant placement in the malformed inner ear. *Otol Neurotol* 2009; 30: 23-6. [\[CrossRef\]](#)
18. Yamamoto N, Okano T, Yamazaki H, Hiraumi H, Sakamoto T, Ito J, et al. Intraoperative Evaluation of Cochlear Implant Electrodes Using Mobile Cone-Beam Computed Tomography. *Otol Neurotol* 2019; 40: 177-83. [\[CrossRef\]](#)