



Original Article

Impact of Routine Plain X-ray on Postoperative Management in Cochlear Implantation

Mehmet Çelik , Kadir Serkan Orhan , Erkan Öztürk , Hakan Avcı , Beldan Polat ,
Yahya Güldiken

Department of Otorhinolaryngology, Istanbul University School of Medicine, Istanbul, Turkey (MÇ, KSO, EÖ, HA, BP, YG)

ORCID IDs of the authors: M.Ç. 0000-0003-3575-9167; K.S.O. 0000-0002-5125-2035; E.Ö. 0000-0002-6671-2911; H.A. 0000-0003-0703-4978; B.P. 0000-0002-7908-8329; Y.G. 0000-0002-8541-8101.

Cite this article as: Çelik M, Orhan KS, Öztürk E, Avcı H, Polat B, Güldiken Y. Impact of Routine Plain X-ray on Postoperative Management in Cochlear Implantation. J Int Adv Otol 2018; 14(3): 365-9.

OBJECTIVES: To determine the benefit of a routine plain radiography (X-ray) for confirming the optimal electrode position in cochlear implant surgery.

MATERIALS and METHODS: In total, 245 patients (135 males and 111 females) who underwent cochlear implantation in a single tertiary referral center were included in this study. Postoperative plain X-ray findings and electrophysiological tests were retrospectively analyzed.

RESULTS: The mean age was 11.4 ± 14.6 years (range, 1–70 years). Overall, 196 (80%) patients were pediatric patients (age, <18 years) and 49 (20%) were adults (age, ≥ 18 years). The mean rotation of electrode arrays was 1.03 ± 0.17 turns. The plain X-ray revealed that electrode misplacement was present in 5 patients (2%); incomplete insertion in 3 patients, and tip rollover and electrode migration in 1 patient each. A revision was performed for the last patient who had an extracochlear electrode position in the plain X-ray.

CONCLUSIONS: Postoperative imaging is mostly used to confirm the electrode array position after cochlear implant surgery. In addition, intraoperative evaluations have low positive predictive value and sensitivity. Thus, this study revealed that postoperative radiological imaging should be considered even when all intraoperative electrophysiological measures and surgical reports are normal.

KEYWORDS: Cochlear implant, electrodes, radiography

INTRODUCTION

Cochlear implants (CIs) are electronic hearing devices that transform mechanical sound energy into electrical signals and enable hearing by directly transmitting the signals to the cochlear nerve via an electrode array inserted in the cochlea.

The most suitable position of the electrode to provide more acceptable clinical outcomes is in the scala tympani ^[1-3]. To confirm the intrascalar placement, a plain radiography (X-ray) scan is generally preferred as a standard method by many CI centers. The modified Stenvers' view, in which the central beam in the temporal bone is positioned 45° posteriorly and 12° caudally ^[4], is often preferred to check the position and insertion depth of the electrodes ^[5].

Furthermore, the other choice for the corroboration of appropriate electrode placement is electrically evoked compound action potentials (ECAPs), which have proven to be an efficient method in the intraoperative and postoperative periods ^[6]. The evoked stapedius reflex (ESR) and impedance are other objective measures that can be intraoperatively or postoperatively performed ^[7, 8]. Alternatively, electrophysiological measurements do not substitute radiological imaging to identify the cases of device failure that is due to displaced or migrated electrode.

Electrode array misplacement is a rare complication with incidence rates between 0.2% and 5.8% ^[9-13]. In this case, plain X-ray can be an easy and useful diagnostic method ^[14].

This study was presented at the Instructional Workshop European Academy of Otolaryngology and Neurotology, 18-21 January 2017, Izmir, Turkey.

Corresponding Address: Kadir Serkan Orhan E-mail: ksorhan@gmail.com

Submitted: 02.07.2017 • Revision Received: 27.11.2017 • Accepted: 28.01.2018 • Available Online Date: 02.08.2018

©Copyright 2018 by The European Academy of Otolaryngology and Neurotology and The Politzer Society - Available online at www.advancedotology.org

Radiological imaging is a golden standard method to confirm the electrode positions in CI. However, to avoid radiation exposure, some surgeons advocate performing routine X-ray only in cases with abnormal anatomy or inappropriate intraoperative findings; for example, an increased resistance during electrode insertion. In this study, we aimed to determine the value of routine postoperative plain X-ray in retrospective cases with CI.

MATERIALS and METHODS

Subjects

Patients who underwent CI owing to bilateral profound sensorineural hearing loss in the Department of Otorhinolaryngology of a tertiary hospital between October 2011 and October 2015 were considered for the study. All demographic data of the patients were obtained from clinical records. The patients who underwent primary CI surgery were included in the study. The patients with a cochlear anomaly and revision surgeries were excluded. The study was approved by the local Institutional Review Board (ref number: 2016/92). Written informed consent was obtained from the patients who participated in this study and from the parents of the patients who were <18 years of age.

Surgical technique

Subperiosteal pocket technique was used in all CIs. Mastoidectomy and a posterior tympanotomy were performed, and a round window or anteroinferior cochleostomy approach into the scala tympani was applied to access the cochlea. The fat or fascia grafts were used for packing around the electrode at the cochleostomy site in most cases. All CIs were performed by three different surgeons in a single center.

Intraoperative assessment

An audiologist was routinely present during each operation; he measured the impedance levels for all electrodes during the closure of the incision and before ECAP measurements using the manufacturers' default modes. The impedance levels between 1 and 30 kilohms (Short circuit [SC] <1 kilohms and open circuit [OC] >30 kilohms) were considered to be normal. ECAP and ESR were evaluated on three different parts of the array: apical, middle, and basal. If no response was obtained in all parts, it was considered to be an abnormal ECAP. Further, if a response was not received at any part of the electrode, it was considered to be a partial ECAP abnormality. Additionally, it was assumed as negative ESR when ESR was not visualized on three different impulses.

In addition to these parameters, the surgeon's suspicion of misplacement (i.e., uncertain or difficult insertions) or intraoperative estimation of array insertion were noted.

Radiologic assessment

At our clinic, a plain Stenvers' view X-ray is routinely performed for all patients on the first postoperative day. All plain radiographies are evaluated for possible electrode misplacement by a blinded radiologist. In our study, radiologic images were retrospectively analyzed to assess the placement, position, and depth of insertion using the digital radiology Picture Archiving and Communication System (ExtremePACS; Ankara, Turkey). Additionally, archived written reports of the radiographies were retrospectively investigated.

The rotating electrode array along the cochlea was categorized as follows: 0.5, 0.75, 1, 1.25, and 1.5 turns (Figure 1).

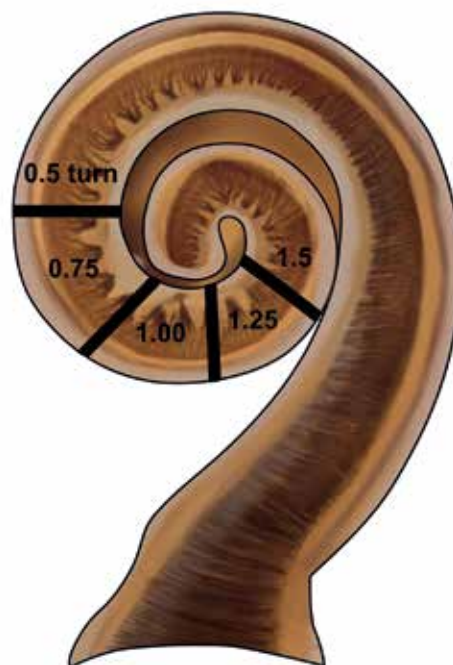


Figure 1. The rotating degree of electrode array along cochlea is defined with black lines on diagram (from the base to apex of the cochlea).

Statistical Analysis

The Statistical Package for the Social Sciences 20.0 (IBM Corp, Armonk, NY, USA) software was used for all statistical analyses. Mean, standard deviation, and median values were calculated for all quantitative measures. The sensitivity and specificity, positive and negative predictive values of surgical suspicion, and electrophysiological tests for radiological imaging were calculated.

RESULTS

In total, 245 patients (134 males and 111 females) were included in the study. The mean age was 11.4 ± 14.6 years. In total, 196 (80%) patients were pediatric patients (age, <18 years) and 49 (20%) were adults (age, ≥ 18 years). Further, 214 patients received implants on the right side and 31 on the left side. Overall, 189 (77.1%) implants were from Cochlear (Cochlear Ltd., Sydney, Australia), 32 (13%) from Med-El (Med-El, Innsbruck, Austria), and 24 (9.7%) from Advanced Bionics (California, USA) companies. The electrode insertions were performed via a round window and cochleostomy approaches in 235 patients (95.9%) and 10 patients (4.1%), respectively.

The findings of intraoperative electrophysiological tests and postoperative plain X-ray were compared (Table 1). The rates of rotating electrode array along the cochlea were as follows: 0.5 turns in 3 patients (1.2%), 0.75 turns in 18 patients (7.3%), 1.00 turn in 182 patients (74.2%), 1.25 turns in 17 patients (6.9%), and 1.5 turns in 25 patients (10.2%). The mean rotation of the electrode was 1.03 ± 0.17 turns.

The postoperative plain X-ray revealed that electrode misplacement was present in 5 patients (2%). The electrode array seemed to be partially inserted on the postoperative images of 3 patients (1.2%). In these patients, the ECAP measurements were abnormal on the basal segments of the electrode and the impedance levels were <1 kilohms; no revision surgery was performed in these patients. The

Table 1. Comparison of radiological and electrophysiological tests

POSTOPERATIVE PLAIN X-RAY RADIOGRAPHY FINDINGS (N:256)	MANUFACTURER	INTRAOPERATIVE ESTIMATION OF ARRAY INSERTION	INTRAOPERATIVE IMPEDANCE LEVELS	INTRAOPERATIVE ECAP	INTRAOPERATIVE ESR
0.5 TURN (1.2%) (N:3)	C:3 M:- AB:-	Partial insertion in 3 patients	SC on basal electrode in 3 patients	Basal electrode abnormality in 3 patients	2 normal 1 negative
0.75 TURN (7.3%) (N:18)	C:16 M:- AB:2	Full insertion	17 normal SC on basal electrode in 1 patient	All normal	16 positive 2 negative
1.00 TURN (74.2%) (N:182)	C:143 M:25 AB:14	Extracochlear misplacement in 1 patient	180 normal OC on middle electrode in 2 patients	All normal in 176 patients Mid-basal electrode abnormality in 6 patients	176 positive 6 negative
1.25 TURN (6.9%) (N:17)	C:8 M:5 AB:4	Full insertion	All normal	All normal in 16 patients Mid-apical electrode abnormality in 1 patient	15 positive 2 negative
1.5 TURN (10.2%) (N:25)	C:19 M:2 AB:4	Full insertion	24 normal OC middle electrode in 1 patient	All normal in 24 patients Mid-basal electrode abnormality in 1 patient	25 positive

ECAP: Evoked compound action potential, ESR: Evoked stapedius reflex, C: Cochlear (Cochlear Ltd., Sydney, Australia), M: Med-El (Med-El, Innsbruck, Austria), AB: Advanced Bionics (California, USA), SC: Short circuit, OC: Open circuit, N: number

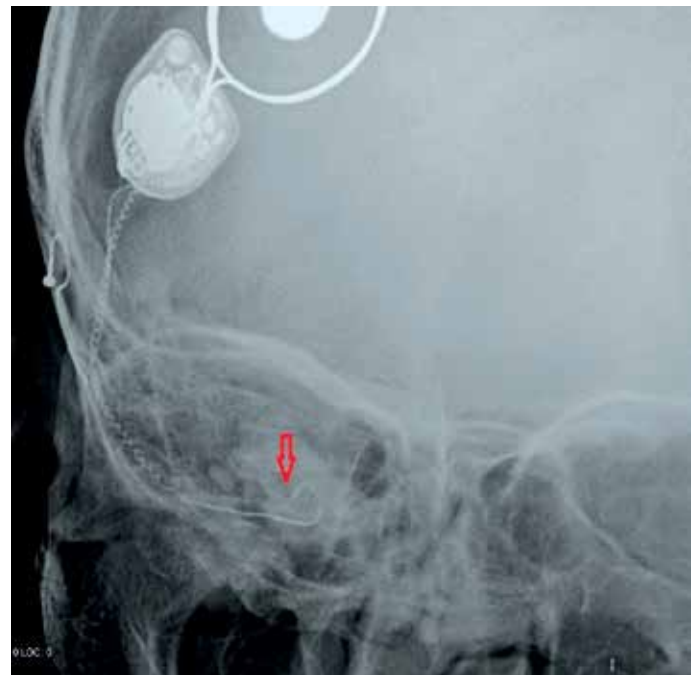Table 2. Value of surgeon's suspicion and intraoperative electrophysiological tests versus radiological imaging

	PPV (%)	NPV (%)	Specificity (%)	Sensitivity (%)
Surgeon's suspicion	75	99.1	99.5	60
ECAP	66.6	99.5	96.6	80
ESR	10	98.2	95.8	20
Impedance	42.8	99.1	98.3	60

ECAP: evoked compound action potential, ESR: evoked stapedius reflex, PPV: positive predictive value, NPV: negative predictive value

postoperative plain X-ray showed tip rollover of the electrode array in the cochlea for only 1 patient (0.4%; Figure 2). In this patient, the impedance levels and ESR were found to be normal, but a partial response (present only on basal arrays) was recorded in ECAP and no revision was required. In another patient, the postoperative plain X-ray revealed that the whole electrode seemed to be out of the cochlea (0.4%), whereas all intraoperative electrophysiological tests (ECAP, ESR, and impedance) were found to be normal (Figure 3). This patient underwent revision surgery on the first postoperative day, and the findings in the revision surgery showed that the misplacement was due to posterior migration of the internal receiver in the subperiosteal pocket, resulting in electrode displacement (Brand name and model was Cochlear (Cochlear Ltd., Sydney, Australia)-straight banded array CI422).

The surgeons suspected an inappropriate position of the electrode array in four patients. In three of these patients, the X-ray showed the partial insertion as a 0.5 turn of the electrode array. The postoperative plain X-ray showed complete and proper insertion in only one suspected case. The positive and negative predictive values of surgical suspicion in electrode placement were 75% and 99.1%, respec-

**Figure 2.** Red arrow indicates tip rollover of electrode array, which does not require immediate revision surgery.

tively. Moreover, the sensitivity and specificity of surgical suspicion were 60% and 99.5%, respectively (Table 2).

DISCUSSION

Many studies have reported on the misplacement and migration of the CI electrode array [9–13, 15]. The average incidence rate of extracochlear misplacement is 0.37% [16] based on various possible causes such as inner ear malformations, temporal bone fracture, otosclerosis, labyrinthitis ossificans, or lack of surgeon experience [11, 16–18].

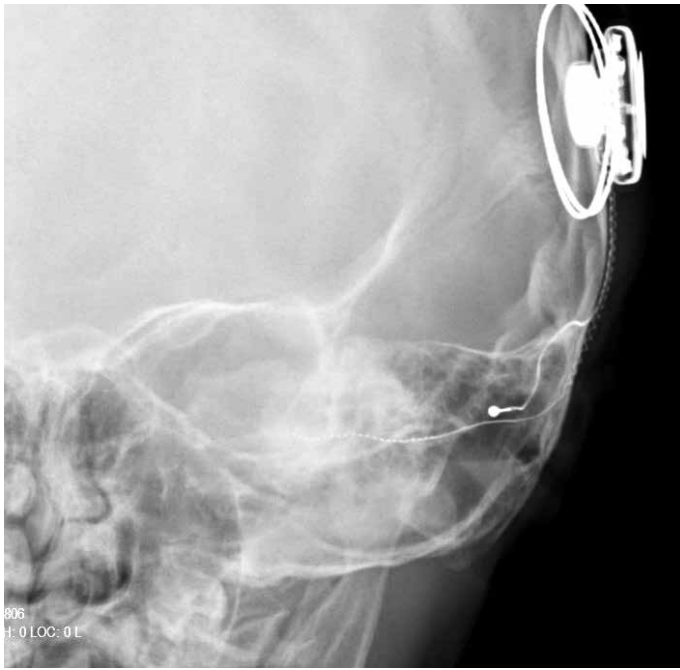

Figure 3. X-ray graph of the patient in whom the electrode does not rotate along the cochlea.

Furthermore, intraoperative difficulties, including the poor visualization of anatomical landmarks or limited access, may increase the surgeon's suspicion of incorrect placement. Thus, a combination of intraoperative electrophysiological tests and radiological imaging are used to confirm proper electrode placement, although no standard procedure has yet been accepted.

One of the common objective measurements used to intraoperatively and postoperatively evaluate the device and electrode function is impedance, which is a measure of resistance to current flow. The impedance measurements are influenced by the electrode-tissue interface, the resistance in the fluid/tissue environment, and the resistance of the electrode contact and lead wires [19]. The sensitivity and specificity of impedance for identifying electrode functions in CI users were reported to be 91.7% and 97.9%, respectively [20]. Impedance abnormalities, including SC (low impedance, approximately ≤ 1 kilohm) or OC (high impedance, usually >30 kilohms) are not uncommon findings in the intraoperative or postoperative periods. These abnormalities may adversely affect the performance of the implant and should be defined at the earliest for proper clinical management [8]. Goehring et al. [8] reported that the total incidence of the devices with a minimum of 1 abnormal electrode impedance value was 12.4% and 8.2% at the intraoperative and postoperative intervals, respectively. It was assumed that the abnormalities were caused by the air bubbles that were solved between the surgery and activation.

Intraoperative or postoperative plain X-ray is another common application to confirm the appropriate placement of the electrode array in the cochlea [2, 3, 25]. Additionally, it acts as a reference in the future of electrode migration and provides the surgeon with feedback on the intracochlear position of the array [25]. There is no universally accepted protocol for imaging, but postoperative plain X-ray is routinely performed as a part of CI.

Coombs et al. [26] reported that 70% of 20 patients with incomplete insertion of the electrode array on postoperative plain X-ray had normal intraoperative impedances at all electrodes. A study of 277 CI patients by Cosetti et al. [24] reviewed intraoperative electrical impedance, ECAP, and plain X-ray. Only X-ray altered decision making and patient management. However, Gnagi et al. [2] reported that intraoperative imaging during CI had no benefit or alteration in management based on imaging findings in 203 (98%) of 207 patients. Furthermore, Dirr et al. [27] intraoperatively performed radiographic position checks only in patients with an increased resistance during electrode insertion and found that X-ray only had a sensitivity of 55% and a specificity of 88% for predicting radiographically confirmed electrode misplacements. Another study showed that intraoperative plain X-ray changed intraoperative management in only 1 out of 79 cases, despite multiple imaging in 23% of the cases [28]. In our study, the postoperative plain X-ray altered management due to electrode migration in only 1 patient who had normal intraoperative electrophysiological tests (0.4%). A revision was performed on the first postoperative day, and the intraoperative findings showed the posterior migration of the internal receiver due to a wide subperiosteal pocket. The short electrode may lead to extracochlear migration of the electrode array. The other minor, improper intracochlear images did not change the postoperative management. In our study, we found that the sensitivity of surgeon's suspicion or electrophysiological tests to postoperative plain X-ray was quite low although the specificity of these evaluations were $>95\%$. This evidence means that most patients with electrode misplacement would be disregarded if we did not use routine postoperative plain X-ray.

The average skin radiation exposure dose was reported as 1.69–7.25 mGray for plain skull X-ray [29–31]. Nevertheless, since a minimum of 1000 X-rays would be required to reach 1 gray (malignancy risk level), it seems very difficult to reach the minimum amounts for complications in CI patients. Additionally, in an era of decreasing reimbursements, the cost and labor requirements of plain X-ray are not insignificant. In our country, the cost of a single skull X-ray ranges from approximately 10 to 30 \$. Therefore, this application seems to be an area in which some health care cost savings may be realized. However, many surgeons believe that the implications of overlooking extracochlear electrode misplacement are too high to justify neglecting a relatively simple, low radiation exposure and cost saving [26].

The limitations of the study are the retrospective design of the study and the lack of information on the postoperative device performance.

CONCLUSION

Postoperative imaging is often used to confirm the electrode array position after CI surgery. Although some authors propose to perform routine X-ray only in cases with abnormal anatomy or inappropriate intraoperative findings, this study showed early electrode migration in one case with normal anatomy despite normal intraoperative electrophysiological tests and a surgical note stating full insertion. Therefore, radiological imaging should be used in all cases after CI surgery because of intraoperative non-radiological evaluations that have high specificity but low sensitivity.

Ethics Committee Approval: Ethics committee approval was received for this study from the ethics committee of Istanbul Faculty of Medicine (No: 2016-92).

Informed Consent: Written informed consent was obtained from the patients who participated in this study and from the parents of the patients who were <18 years of age.

Peer-review: Externally peer-reviewed.

Author Contributions: Concept – K.S.O., M.Ç., E.Ö.; Design – K.S.O., B.P., M.Ç.; Supervision – K.S.O., Y.G.; Resources – K.S.O., Y.G., B.P.; Materials M.Ç., K.S.O., H.A., E.Ö.; Data Collection and/or Processing E.Ö., H.A., M.Ç.; Analysis and/or Interpretation – M.Ç., K.S.O., B.P.; Literature Search M.Ç., E.Ö., H.A.; Writing Manuscript – M.Ç., K.S.O., E.Ö.; Critical Review – K.S.O., Y.G., B.P.

Conflict of Interest: No conflict of interest was declared by the authors.

Financial Disclosure: The authors declared that this study has received no financial support.

REFERENCES

- Balkany TJ, Dreisbach JN, Seibert CE. Radiographic imaging of the cochlear implant candidate: preliminary results. *Otolaryngol Head Neck Surg* 1986; 95: 592-7. [CrossRef]
- Gnagi SH, Baker TR, Pollei TR, Barrs DM. Analysis of intraoperative radiographic electrode placement during cochlear implantation. *Otol Neurotol* 2015; 36: 1045-7. [CrossRef]
- Rosenberg RA, Cohen NL, Reede DL. Radiographic imaging for the cochlear implant. *Ann Otol Rhinol Laryngol* 1987; 96: 300-4. [CrossRef]
- Marsh MA, Xu J, Blamey PJ, Whitford LA, Xu SA, Silverman JM, et al. Radiologic evaluation of multichannel intracochlear implant insertion depth. *Am J Otol* 1993; 14: 386-91.
- Jain R, Mukherji SK. Cochlear implant failure: imaging evaluation of the electrode course. *Clin Radiol* 2003; 58: 288-93. [CrossRef]
- Dillier N, Lai WK, Almqvist B, Frohne C, Muller-Deile J, Stecker M, et al. Measurement of the electrically evoked compound action potential via a neural response telemetry system. *Ann Otol Rhinol Laryngol* 2002; 111: 407-14. [CrossRef]
- Caner G, Olgun L, Gültekin G, Balaban M. Optimizing fitting in children using objective measures such as neural response imaging and electrically evoked stapedius reflex threshold. *Otol Neurotol* 2007; 28: 637-40. [CrossRef]
- Goehring JL, Hughes ML, Baudhuin JL, Lusk RP. How well do cochlear implant intraoperative impedance measures predict postoperative electrode function? *Otol Neurotol* 2013; 34: 239. [CrossRef]
- Cohen NL, Hoffman RA, Stroschein M. Medical or surgical complications related to the Nucleus multichannel cochlear implant. *Ann Otol Rhinol Laryngol Suppl* 1988; 135: 8-13. [CrossRef]
- Roland J. Complications of cochlear implant surgery. *Cochlear Implants* New York: Thieme 2000: 170-7.
- Tange RA, Grolman W, Maat A. Intracochlear misdirected implantation of a cochlear implant. *Acta Otolaryngol* 2006; 126: 650-2. [CrossRef]
- Windmill IM, Martinez SA, Nolph MB, Eisenmenger BA. Surgical and non-surgical complications associated with cochlear prosthesis implantation. *Am J Otol* 1990; 11: 415-20.
- Woolford TJ, Saeed SR, Boyd P, Hartley C, Ramsden RT. Cochlear reimplantation. *Ann Otol Rhinol Laryngol Suppl* 1995; 166: 449-53.
- Todd NW, Ball TL. Interobserver agreement of coiling of Med-El cochlear implant: plain x-ray studies. *Otol Neurotol* 2004; 25: 271-4. [CrossRef]
- Brown KD, Connell SS, Balkany TJ, Eshraghi AE, Telischi FF, Angeli SA. Incidence and indications for revision cochlear implant surgery in adults and children. *Laryngoscope* 2009; 119: 152-7. [CrossRef]
- Ying YL, Lin JW, Oghalai JS, Williamson RA. Cochlear implant electrode misplacement: incidence, evaluation, and management. *Laryngoscope* 2013; 123(3): 757-66. [CrossRef]
- Rotteveel LJ, Proops DW, Ramsden RT, Saeed SR, van Olphen AF, Mylanus EA. Cochlear implantation in 53 patients with otosclerosis: demographics, computed tomographic scanning, surgery, and complications. *Otol Neurotol* 2004; 25: 943-52. [CrossRef]
- Lehnhardt E. Intracochlear placement of cochlear implant electrodes in soft surgery technique. *HNO* 1993; 41: 356-9.
- Clark G. Preoperative selection. *Cochlear Implants: Fundamentals and Applications* New York: Springer 2003: 550-85. [CrossRef]
- Hughes ML, Brown CJ, Abbas PJ. Sensitivity and specificity of averaged electrode voltage measures in cochlear implant recipients. *Ear Hear* 2004; 25: 431-46. [CrossRef]
- Shalloo JK. Objective electrophysiological measures from cochlear implant patients. *Ear Hear* 1993; 14: 58-63. [CrossRef]
- Jerger J, Fifer R, Jenkins H, Mecklenburg D. Stapedius reflex to electrical stimulation in a patient with a cochlear implant. *Ann Otol Rhinol Laryngol* 1986; 95: 151-7. [CrossRef]
- Botros A, van Dijk B, Killian M. AutoNRT™: An automated system that measures ECAP thresholds with the Nucleus® Freedom™ cochlear implant via machine intelligence. *Artif Intell Med* 2007; 40: 15-28. [CrossRef]
- Cosetti MK, Troob SH, Latzman JM, Shapiro WH, Roland JT, Jr., Waltzman SB. An evidence-based algorithm for intraoperative monitoring during cochlear implantation. *Otol Neurotol* 2012; 33: 169-76. [CrossRef]
- Shpizner BA, Holliday RA, Roland JT, Cohen NL, Waltzman SB, Shapiro WH. Postoperative imaging of the multichannel cochlear implant. *Am J Neuroradiol* 1995; 16: 1517-24.
- Coombs A, Clamp PJ, Armstrong S, Robinson PJ, Hajioff D. The role of post-operative imaging in cochlear implant surgery: A review of 220 adult cases. *Cochlear Implants Int* 2014; 15: 264-71. [CrossRef]
- Dirr F, Hempel JM, Krause E, Müller J, Berghaus A, Ertl-Wagner B, et al. Value of routine plain x-ray position checks after cochlear implantation. *Otol Neurotol* 2013; 34: 1666-9. [CrossRef]
- Copeland BJ, Pillsbury HC, Buchman CA. Prospective evaluation of intraoperative cochlear implant radiographs. *Otol Neurotol* 2004; 25: 295-7. [CrossRef]
- Etemadinezhad S, Rahimi SA. Patient exposure dose for chest and skull radiographies in Mazandaran hospitals. *J Xray Sci Technol* 2010; 18: 87-91.
- Muhogora W, Nyanda A. The potential for reduction of radiation doses to patients undergoing some common X ray examinations in Tanzania. *Radiat Prot Dosimetry* 2001; 94: 381-4. [CrossRef]
- Papadimitriou D, Perris A, Molfetas M, Panagiotakis N, Manetou A, Tsourouflis G, et al. Patient Dose, Image Quality and Radiographic Techniques for Common X ray Examinations in Greece and Comparison with the European Guidelines. *Radiat Prot Dosimetry* 2001; 95: 43-8. [CrossRef]