



Case Report

Intraoperative Facial Nerve Monitoring Revealed the Origin of Rapidly Progressing Schwannoma in the Cerebellopontine Angle: A Case of Large Intermediate Nerve Schwannoma

Makoto Hosoya , Naoki Oishi , Masaru Noguchi , Kento Kasuya , Takanori Nishiyama , Toru Ishikawa , Ken Kasahara , Hidemi Miyazaki , Kaoru Ogawa

Department of Otolaryngology, Head and Neck Surgery, Keio University School of Medicine, Tokyo, Japan (MH, NO, MN, KK, TN, TI, K.KASAHARA, KO)
Department of Otolaryngology, Tokyo Women's Medical University Medical Center East, Tokyo, Japan (HM)

ORCID IDs of the authors: M.H. 0000-0003-0331-3670; N.O. 0000-0001-8204-9518; M.N. 0000-0002-4272-255X; K.K. 0000-0002-1345-420X; T.N. 0000-0002-7136-531X; T.I. 0000-0002-4626-0831; K.Kasahara 0000-0001-7120-069X; H.M. 0000-0003-1381-695X; K.O. 0000-0002-2461-4125.

Cite this article as: Hosoya M, Oishi N, Noguchi M, Kasuya K, Nishiyama T, Ishikawa T, et al. Intraoperative Facial Nerve Monitoring Revealed the Origin of Rapidly Progressing Schwannoma in the Cerebellopontine Angle: A Case of Large Intermediate Nerve Schwannoma. J Int Adv Otol 2018; 14(3): 488-92.

Schwannoma arising from the intermediate nerve is very rare, with only a few cases reported in the literature. Here, we report a rare case of a rapidly growing schwannoma that originated from the intermediate nerve in a 17-year-old woman. We performed tumor resection using the translabrynthine approach with continuous intraoperative monitoring, in which the facial nerve root was used to evoke muscle action potential. The monitoring revealed the tumor origin and enabled complete surgical resection with the preservation of facial nerve motor function. The facial nerve root evoked muscle action potential-based continuous monitoring revealed the origin of the rare intermediate nerve schwannoma. Appropriate surgery using this monitoring system could spare facial nerve function even in this rare case and retain the patient's quality of life.

KEYWORDS: Intermediate nerve schwannoma, facial nerve schwannoma, facial nerve root evoked muscle action potential, intraoperative facial nerve monitoring

INTRODUCTION

Intermediate nerve schwannoma is a rare disease, with five symptomatic ^[1-4] and some asymptomatic cases described in the literature ^[5].

Recently, an intraoperative continuous nerve monitoring system was implemented for assessing the facial nerve ^[6,7]. Evoked electromyogram (EMG) of the orbicularis oculi and oris muscles was continuously monitored during surgery using a particular stimulant electrode placed on the root exit zone of the facial nerve; the resulting electrical potential was deemed the facial nerve root evoked muscle action potential (FREMAP) ^[8]. FREMAP monitoring has been reported to improve the preservation of facial nerve function during acoustic neuroma surgery ^[7].

Herein, we report a very rare case of rapidly growing schwannoma, which originated from the intermediate nerve and caused prominent temporal bone destruction near the geniculate portion of the facial nerve.

CASE PRESENTATION

A 17-year-old female patient presented to our department because of hearing loss and tinnitus in the right ear. Upon auditory examination, she presented with severe hearing loss in the right ear (Figure 1a). Magnetic resonance imaging (MRI) revealed a mass distributed along the internal ear canal from the porus to the geniculate ganglion (Figures 1b and c). At this point, we selected the "wait and scan" policy. However, during the 5-year follow-up, the patient completely lost her hearing (Figure 1d) and suffered from

Corresponding Address: Naoki Oishi E-mail: oishin@keio.jp

Submitted: 27.04.2018 • **Accepted:** 05.07.2018 • **Available Online Date:** 27.11.2018

©Copyright 2018 by The European Academy of Otolaryngology and Neurotology and The Politzer Society - Available online at www.advancedotology.org

dizziness. Follow-up imaging revealed increase in the tumor size with an accompanying cystic change causing brainstem compression. (Figures 1e and f). Finally, we decided to perform tumor resection owing to the rapid growth of the tumor.

Preoperative MRI revealed intact cisternal segment of the facial nerve (Figure 2a) and the tumor involvement of the cisternal portion of the auditory nerve (Figure 2b). Preoperative computed tomography revealed the enlargement of the inner ear canal and prominent temporal bone destruction near the geniculate portion of the facial nerve (Figures 2 c-f). While there was no apparent facial nerve paralysis, electroneurography (ENoG) revealed lower amplitude on the right side (45%), suggesting hidden facial nerve disturbance (Figure 3). The ice-water caloric test produced no response on the right side.

We performed an inner ear canal tumor resection using the translabyrinthine approach under continuous monitoring using FREMAP electrodes [7]. After opening the dura, the tumor was identified, and a FREMAP electrode was placed on the facial nerve root. After the resection of the cisternal portion of the tumor, we confirmed that the facial nerve root was intact from the brainstem to the porus of the inner ear canal. The tumor extended to the vestibular ampulla, and it was hard to distinguish the tumor from the vestibulocochlear nerve; however, we could easily resect the tumor from the main trunk of the facial nerve (Figures 4a and b). As indicated by preoperative imaging, the tumor had aggressively extended to the geniculate gan-

glion. Finally, we removed this portion of the tumor, and achieved 99% tumor resection with the preservation of facial nerve function. During the operation, the amplitude of FREMAP was maintained at a level of at least 65% of its initial value except when the resection of geniculate ganglion tumor portions was performed (57%). The final amplitude of FREMAP was over 80% in both the orbicularis oculi and orbicularis oris muscles (Figure 5).

The final histopathology report confirmed a schwannoma with palisading pattern. On the basis of these findings, intermediate nerve schwannoma was diagnosed.

Following surgery, the patient presented with temporary partial facial nerve palsy (House–Blackmann, grade 3) and taste disorder. However, her facial nerve palsy recovered (House–Blackmann, grade 2) during the 1-month postsurgical observation period, with an almost complete recovery of the remaining slight eye-closure weakness at 3 months. The taste disorder recovered during the 3-month postsurgical observation period. MRI at 3 months after surgery confirmed complete resection of the tumor. The patient provided written informed consent.

DISCUSSION

The geniculate ganglion is the most common region affected by facial nerve schwannomas [9] and has been previously reported in a patient with intermediate neuron schwannoma that also affected the facial nerve [2]. In this case, the tumor developed in the genicu-

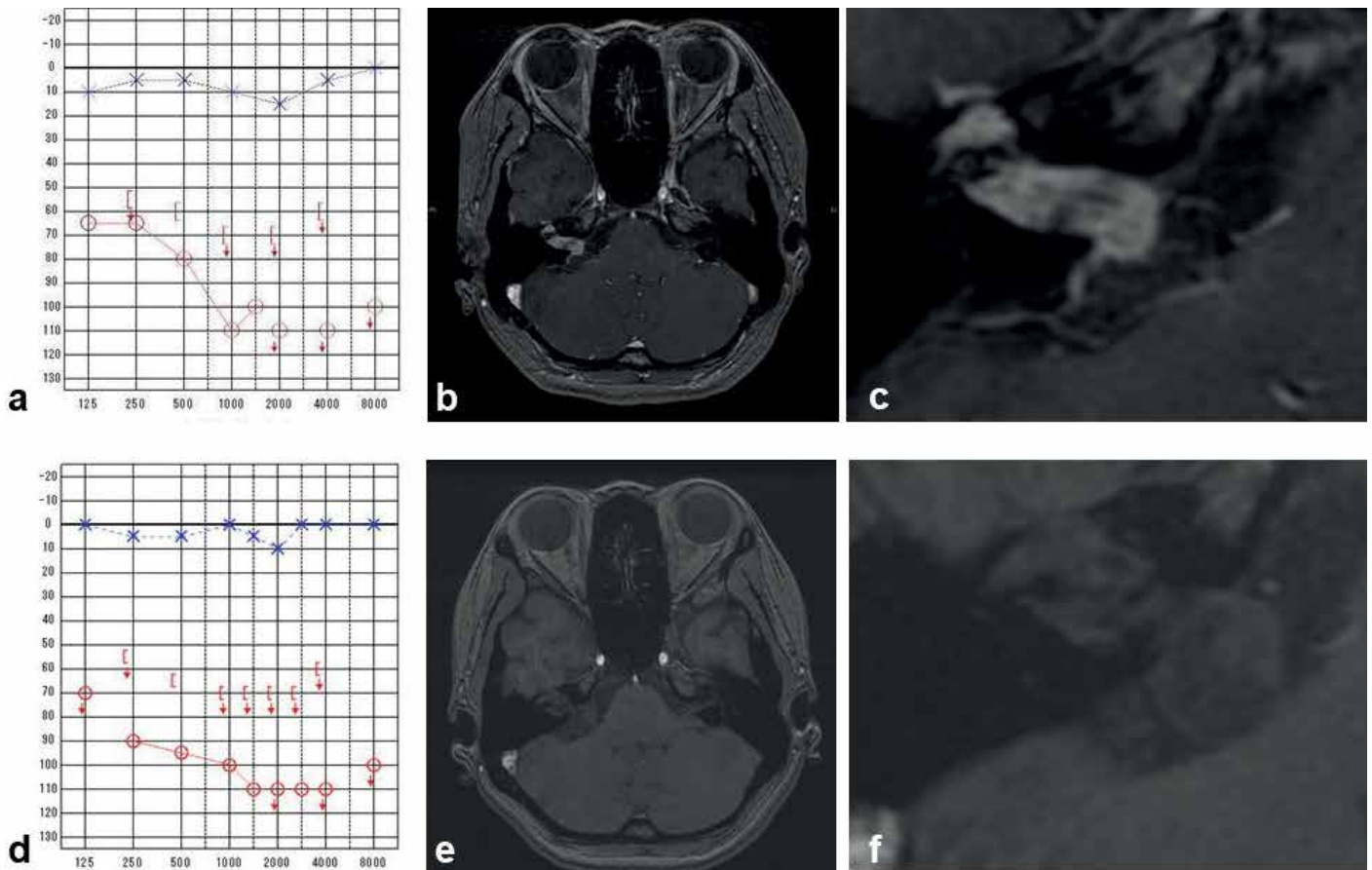


Figure 1. a-f. Preoperative course of audiogram and MRI imaging. Preoperative course of audiogram and MRI during the 5-year preoperative observation period, during which the patient completely lost her hearing (a, d). Tumor protruding into the cerebellopontine angle. The mass grew to 22 mm and extended from the cerebellopontine angle to the geniculate ganglion (b, c, e, f).

late ganglion. However, when focusing on the cisternal portion, MRI findings revealed intact facial nerve and entrapped auditory nerve. These findings contradicted the concept that this tumor originated from the intermediate nerve as it extended near the auditory nerve at the proximal segment and united with the facial nerve at the distal segment^[10]. However, preoperative imaging suggested that the present tumor was more likely to be an intermediate nerve schwannoma. This is the first case describing imaging results indicative of intermediate nerve schwannoma, and the findings are consistent with surgical findings in a previous case^[2].

Facial nerve schwannoma that affects the geniculate ganglion has a high risk of facial nerve paralysis, particularly in women and cases with large tumors^[9]. In the present case, the patient presented with no facial nerve paralysis or spasm. The clinical course is comparable to that in a previous case of intermediate nerve schwannoma in which facial nerve symptoms were few. Our patient exhibited profound ipsilateral hearing loss. Pathological cases of incidental intermediate nerve schwannomas presenting with significantly reduced spiral ganglion neurons and decreased hair cells without facial weakness have been reported in the literature^[5]. Moreover, of the five previ-

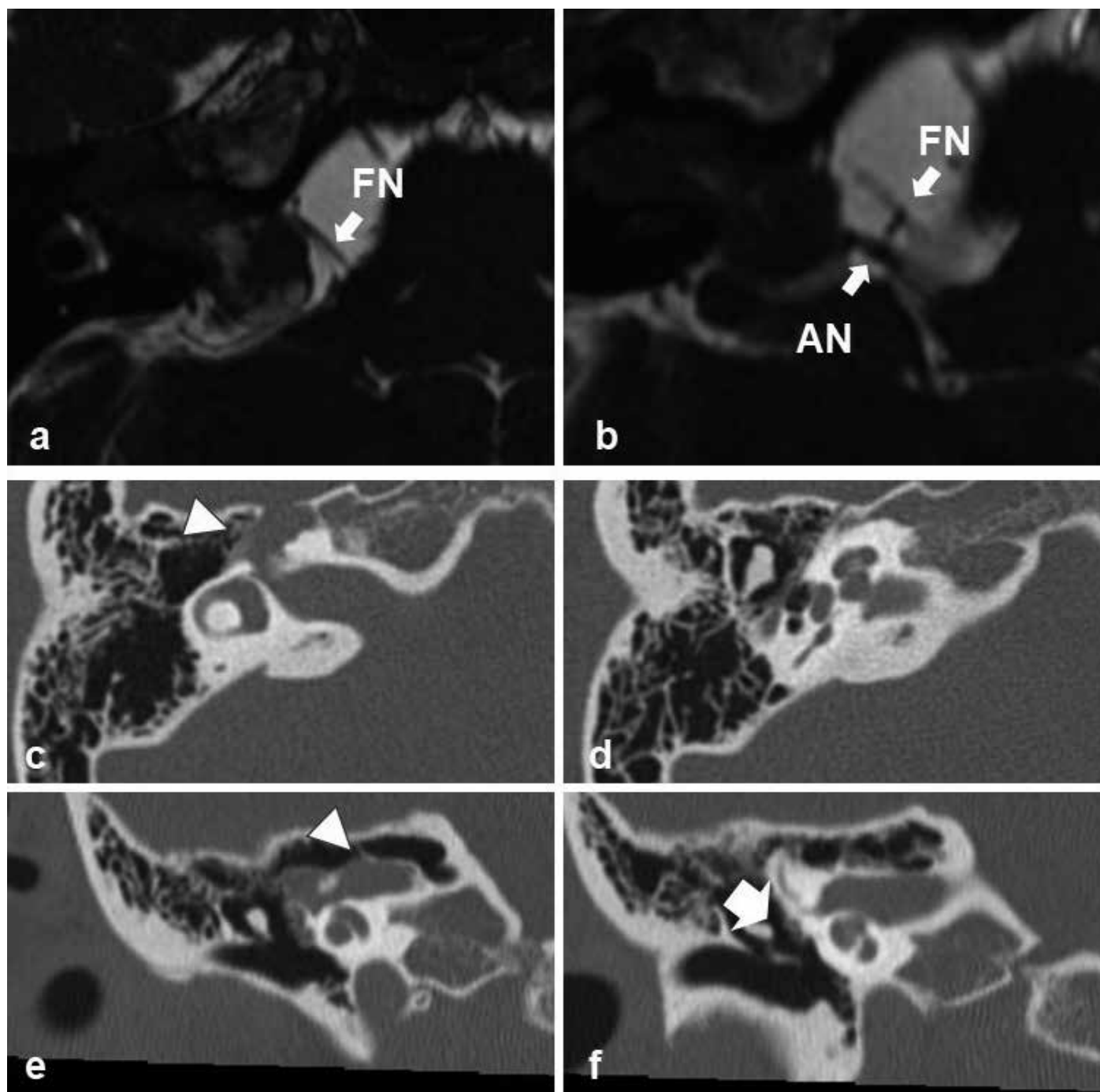


Figure 2. a-f. Preoperative imaging findings. Preoperative MRI revealed that the cisternal portion of the facial nerve (FN) remained intact and was not involved in tumor, while the auditory nerve (AN) was completely encompassed (a, b). Preoperative CT revealed that the bone surrounding the geniculate ganglion was disrupted by the tumor (arrowhead) (c, e). The bone surrounding the cochlea was undamaged (d), and the vertical portion of the facial nerve was not involved in tumor (f).

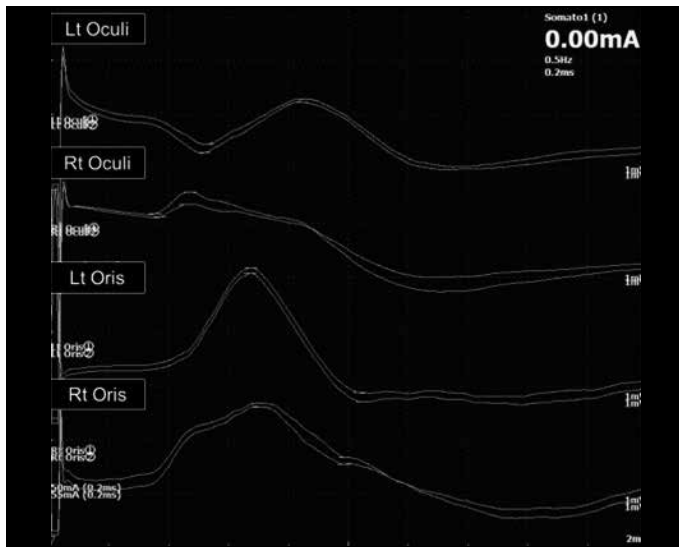


Figure 3. Preoperative ENoG revealed lower amplitude on the right side.

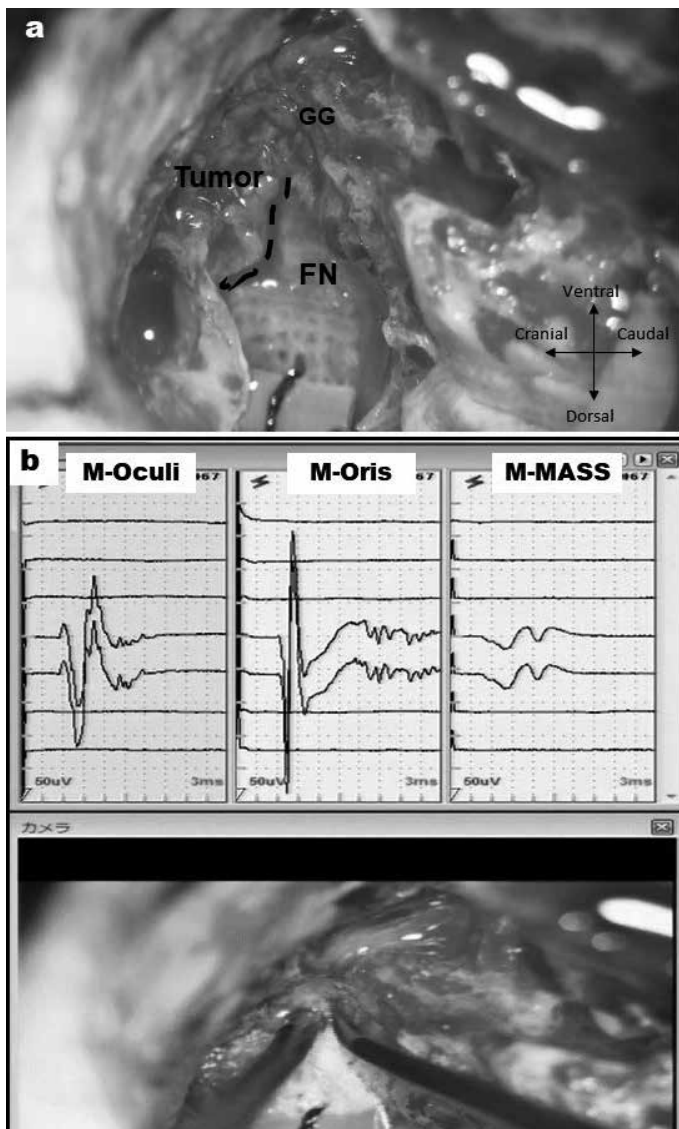


Figure 4. a, b. Intraoperative findings. Tumor was easily dissected from the labyrinthine portion of the facial nerve (a); this tract was confirmed by the stimulator electrode (b).

ous cases, only one has been reported to present with facial spasms, while the other four have been reported to experience hearing loss. These findings suggest that intermediate nerve schwannoma could more severely affect hearing than facial nerve motor function, which is consistent with our findings.

EMG is generally used for facial nerve monitoring. In our case, we used a more prominent facial nerve monitoring using FREMAP, which enabled us to continuously stimulate the facial nerve, with high sensitivity for intraoperative facial nerve damage. With intermittent EMG using the NIM (Nerve Integrity Monitor) system, it is difficult to intraoperatively diagnose schwannoma originating from the intermediate nerve since the electrostimulation of the intermediate nerve can cause the reaction of the facial nerve motor trunk, leading to an erroneous result. Under this condition, surgeons would be hesitant to resect the corresponding tumor portion. However, using FREMAP-based facial nerve monitoring, surgeons can debulk tumors by monitoring facial nerve motor function in the real-time since FREMAP waveforms are not affected by the resection of intermediate nerve schwannoma. Thus, FREMAP-based facial nerve monitoring makes tumor resection straightforward in cases of intermediate nerve schwannoma and is useful for the diagnosis of this rare tumor.

CONCLUSION

At present, intermediate nerve schwannoma cannot be distinguished from facial nerve schwannoma preoperatively. However, the present and a previously reported case suggest that the absence of facial nerve symptoms, presence of large tumors extending from the geniculate ganglion to the cerebellopontine angle, and absence of contact with the cisternal portion of the facial nerve are indicative of tumors originating from the intermediate nerve. In such patients,

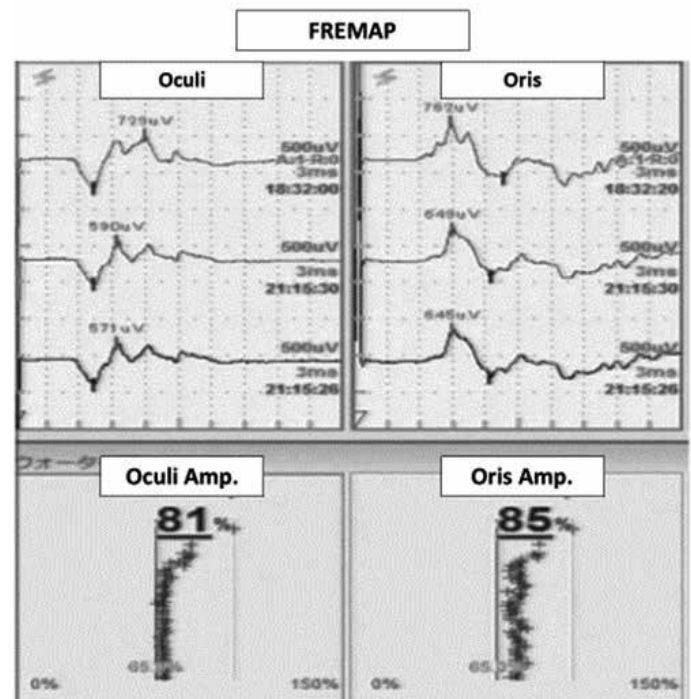


Figure 5. Intraoperative FREMAP monitoring. During the operation, FREMAP monitoring was used after the electrode was placed on the facial nerve root. After tumor resection, the amplitudes of the orbicularis oculi and oris were maintained over 80% compared with the initial amplitude.

surgery using FREMAP-based continuous facial nerve monitoring could spare facial nerve function. Moreover, compared with cases of facial nerve motor trunk schwannomas, surgery for intermediate nerve schwannoma should be considered at an earlier stage before the appearance of facial nerve palsy.

Informed Consent: Written informed consent was obtained from the patient who participated in this study.

Peer-review: Externally peer-reviewed.

Author Contributions: Concept – M.H., N.O.; Design – M.H., N.O.; Supervision – H.M., K.O.; Resource – M.H., N.O., M.N., K.Kasuya, T.N., T.I., K.Kasahara; Materials – M.H., N.O., M.N., K.Kasuya, T.N., T.I.; Data Collection and/or Processing – M.H., N.O., M.N., K.Kasuya, T.N., T.I.; Analysis and/or Interpretation – M.H., N.O., M.N., K.Kasuya, T.N., T.I.; Literature Search – M.H., N.O.; Writing – M.H., N.O.; Critical Reviews – N.M., K.O.

Conflict of Interest: The authors have no conflict of interest to declare.

Financial Disclosure: This work was supported by JSPS KAKENHI.

REFERENCES

1. Sherman JD, Dagnew E, Pensak ML, van Loveren HR, Tew JM Jr. Facial nerve neuromas: report of 10 cases and review of the literature. *Neurosurgery* 2002; 50: 450-6. [\[CrossRef\]](#)
2. Scheller C, Rachinger J, Prell J, Kornhuber M, Strauss C. Schwannoma of the intermediate nerve. *J Neurosurg* 2008; 109: 144-8. [\[CrossRef\]](#)
3. Kudo A, Suzuki M, Kubo N, Kuroda K, Ogawa A, Iwasaki Y. Schwannoma arising from the intermediate nerve and manifesting as hemifacial spasm. Case report. *J Neurosurg* 1996; 84: 277-9. [\[CrossRef\]](#)
4. Mowry S, Hansen M, Gantz B. Surgical management of internal auditory canal and cerebellopontine angle facial nerve schwannoma. *Otol Neurotol* 2012; 33: 1071-6. [\[CrossRef\]](#)
5. Remenschneider AK, Gaudin R, Kozin ED, Ishai R, Quatela O, Hadlock TA, et al. Is the cause of sensorineural hearing loss in patients with facial schwannomas multifactorial? *Laryngoscope* 2017; 127: 1676-82. [\[CrossRef\]](#)
6. Amano M, Kohno M, Nagata O, Taniguchi M, Sora S, Sato H. Intraoperative continuous monitoring of evoked facial nerve electromyograms in acoustic neuroma surgery. *Acta Neurochir (Wien)* 2011; 153: 1059-67. [\[CrossRef\]](#)
7. Nakatomi H, Miyazaki H, Tanaka M, Kin T, Yoshino M, Oyama H, et al. Improved preservation of function during acoustic neuroma surgery. *J Neurosurg* 2015; 122: 24-33. [\[CrossRef\]](#)
8. Magnan J, Parikh B, Miyazaki H. 3. Nerve Monitoring for Cerebellopontine Angle Surgery, in *Functional Surgery of Cerebellopontine Angle by Minimally Invasive Retrosigmoid Approach*. Jaypee Brothers Medical Pub; 2013. [\[CrossRef\]](#)
9. Carlson ML, Deep NL, Patel NS, Lundy LB, Tombers NM, Lohse CM, et al. Facial nerve schwannomas: review of 80 cases over 25 years at mayo clinic. *Mayo Clin Proc* 2016; 91: 1563-76. [\[CrossRef\]](#)
10. Rhoton AL Jr, Kobayashi S, Hollinshead WH. Nervus Intermedius. *J Neurosurg* 1968; 29: 609-18. [\[CrossRef\]](#)