



Case Report

Canal Wall-Down Mastoidectomy plus Meatoplasty for Extensive Verruca Vulgaris in the Ear Canal and Mastoid Bone

Hyeon Sik Oh, Eun Sub Lee, Tae Young Han, Hyun Joon Shim 

Department of Otorhinolaryngology-Head and Neck Surgery, Eulji University, Eulji Medical Center, Seoul, Korea (HSO, ESL, HJS)
Department of Dermatology, Eulji University, Eulji Medical Center, Seoul, Korea (TYH)

ORCID ID of the author: H.J.S. 0000-0001-9719-6959.

Cite this article as: Oh HS, Lee ES, Han TY, Shim HJ. Canal Wall-Down Mastoidectomy plus Meatoplasty for Extensive Verruca Vulgaris in the Ear Canal and Mastoid Bone. J Int Adv Otol 2018; 14(3): 501-3.

Verruca vulgaris is commonly seen on the hands, feet, and face, but rarely in the external auditory canal. We report the case of a 57-year-old woman with a huge papillary mass filling the entire external auditory canal, with destruction of the posterior canal wall and excavation into the mastoid bone. We performed en bloc resection of the whole region affected by verruca vulgaris, including the external auditory canal, mastoid skin, and tympanic membrane using canal wall-down mastoidectomy plus meatoplasty. There was no evidence of recurrence 12 months post-operatively. Complete surgical removal by mastoidectomy is a promising option for wide-spread verruca vulgaris in the external auditory canal.

KEYWORDS: Verruca vulgaris, ear canal, mastoid, mastoidectomy

INTRODUCTION

Verruca vulgaris is induced by infection with the human papilloma virus (HPV), and it commonly occurs on the hands, feet, and face ^[1]. Over 100 genotypes of HPV have been sequenced, and the common clinical lesions vary depending on genotype; type 1 induces deep plantar and palmar warts, types 6 and 11 induce anorectal warts and cervical condylomata, and types 2, 4, and 19 induce common warts ^[1]. HPV infection occurs through inoculation of the virus into the viable epidermis through breaks in the epithelial barrier; therefore, skin maceration is an important predisposing factor ^[1].

There have been few reported cases of verruca vulgaris in the external auditory canal (EAC). Two of these cases were confined to EAC ^[2,3], and one case extended to the tympanic membrane ^[4]. In the present case, verruca vulgaris invaded into EAC skin, tympanic membrane and the overlying skin of the exposed mastoid bone by self-destruction of the posterior EAC. The space available in EAC was limited for topical treatment; therefore, we performed complete surgical excision using the canal wall-down mastoidectomy plus meatoplasty.

CASE PRESENTATION

A 57-year-old female presented with right ear fullness and intermittent otalgia. She had experienced frequent otorrhea and progressive hearing loss in the right ear over the previous 50 years. Her medical history was unremarkable, except for hypertension. Endoscopic examination revealed a huge papillary mass filling the entire EAC, with destruction of the posterior wall and excavation into the mastoid bone (Figure 1). Verruca vulgaris was diagnosed from a preoperative biopsy. Computed tomography of the temporal bone revealed a defect in the lateral wall of the mastoid bone. The middle ear cavity was filled with soft tissue density, and ossicles were not observed (Figure 2). Profound right ear hearing impairment was diagnosed by audiometry. The pure-tone audiometry threshold in the right ear was 88 dB with air conduction and 76 dB with bone conduction (Figure 3).

Under general anesthesia, an EAC skin incision was made with a safety margin from the entrance of EAC, and the tympanomeatal skin flap was elevated. A postauricular approach was performed for mastoidectomy; after mastoidectomy that involved removing the canal wall, the papillary mass over the mastoid skin, tympanic membrane, and EAC skin were removed en bloc. Meatoplas-

Corresponding Address: Hyun Joon Shim E-mail: eardoc11@naver.com

Submitted: 30.11.2017 • **Revision Received:** 20.02.2018 • **Accepted:** 05.03.2018 • **Available Online Date:** 04.12.2018

©Copyright 2018 by The European Academy of Otolaryngology and Neurotology and The Politzer Society - Available online at www.advancedotology.org

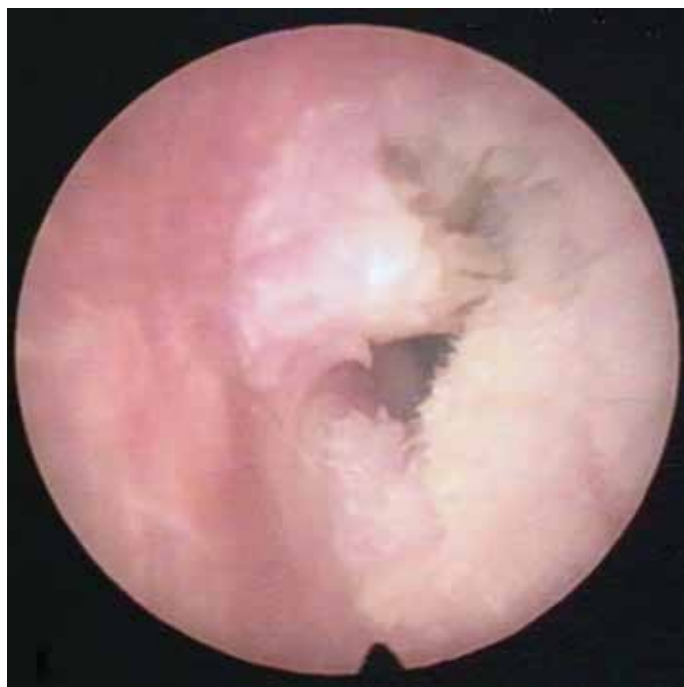

Figure 1. Preoperative endoscopic findings in the right ear showing a papillary mass filling the entire external auditory canal.

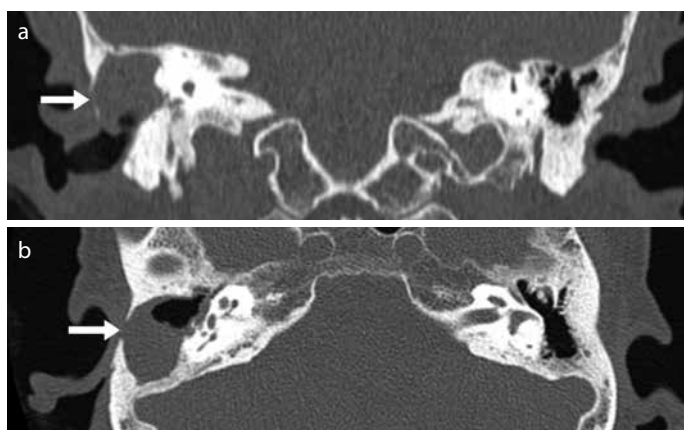


Figure 2. a, b. High-resolution computed tomography axial (a) and coronal (b) images showing a defect in the lateral wall of the mastoid bone (arrow). The middle ear cavity was filled with soft tissue density, and ossicles were not observed.

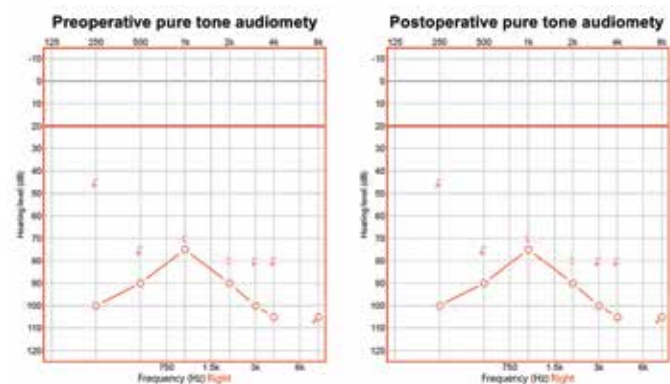


Figure 3. Pure-tone audiogram revealed a profound hearing impairment of the right ear. Postoperative test demonstrated the same thresholds as the preoperative test.

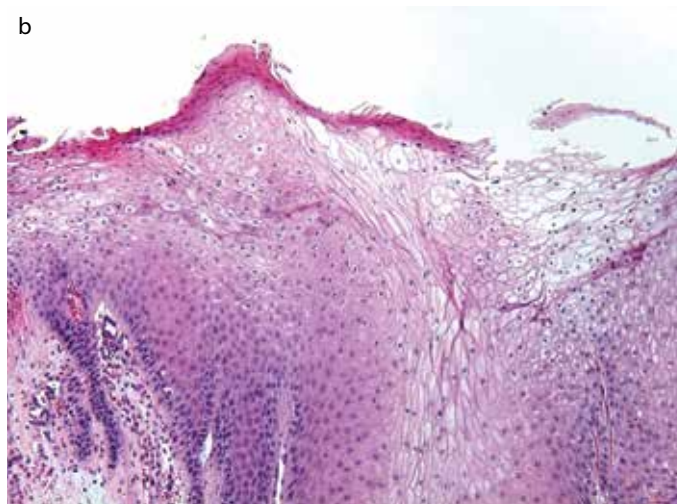
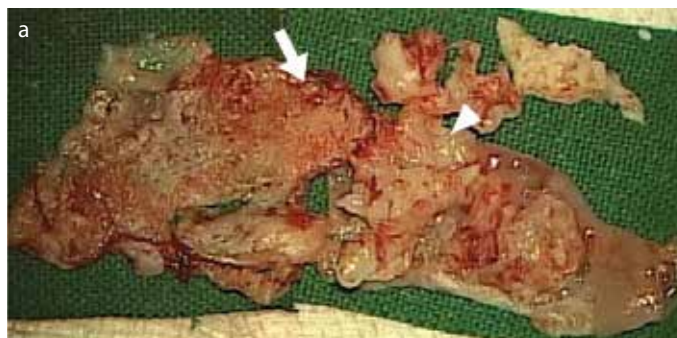


Figure 4. a, b. Postoperative specimen showing a papillary mass over the entire external auditory canal (arrowhead), tympanic membrane, and mastoid skin (arrow) (a). Parakeratosis, acanthosis, and papillomatosis were noted. There were groups of large, vacuolated cells with small pyknotic nuclei (koilocytes) in the upper layers of the epidermis. Prominent papillary dermal small blood vessels were shown (b, hematoxylin and eosin, $\times 100$).

ty was performed with a split-thickness skin graft on the denuded anterior EAC bony wall and a temporalis muscle fascia graft on the tympanic membrane and mastoid bone. The final histopathological examination confirmed verruca vulgaris (Figure 4). There was good epithelization on the anterior EAC and the mastoid cavity (Figure 5). There was no evidence of recurrence 12 months postoperatively. We obtained verbal informed consent from the patient for publication of the report.

DISCUSSION

Verruca vulgaris does not generally invade or erode bone; however, the current case had extensive destruction of the mastoid bone. Furthermore, destruction of the posterior EAC was considered to have been induced by the long-term mass effect of accumulated keratin, as the proliferated verruca vulgaris hindered the migration and evacuation of keratin into the stenosed EAC. Similarly, a previous case report had described partial destruction of the EAC wall caused by verruca vulgaris [2].

Treatment for plantar and palmar warts usually involves intralesional bleomycin injection, cryotherapy, or laser therapy; however, it is difficult to apply preexisting treatment modalities for verruca vulgaris in EAC because of the limited approach in EAC and the risk of damage to the inner ear structure. Mastoidectomy with removal the posterior

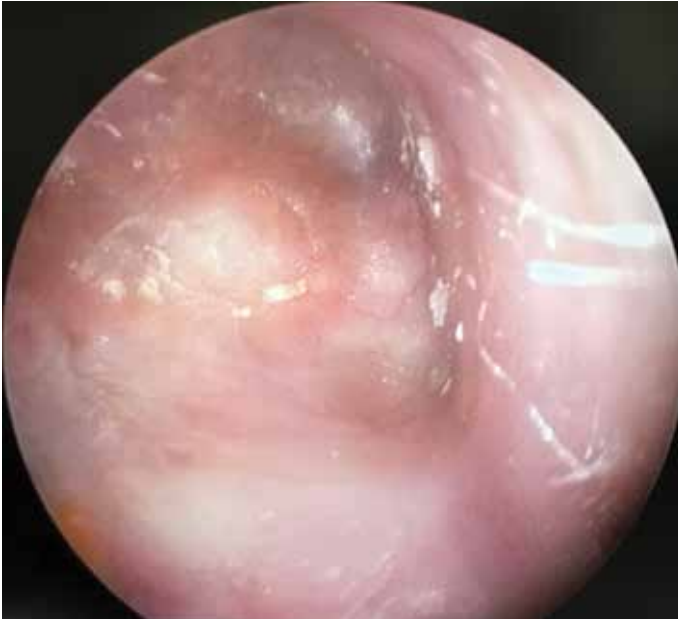

Figure 5. Postoperative endoscopic findings in the right ear showed good take-up of the skin graft of the anterior external auditory canal and well-epithelized mastoid skin.

wall of EAC provide a large field of view and this technique could be useful for the complete excision of wide-spread verruca vulgaris in the narrow space of the EAC and mastoid cavity. However, surgical excision has potential disadvantages such as scarring, high recurrence rate, and recurrence at the periphery of the treatment site^[5]. To minimize the risk of recurrence, we performed en bloc resection of the whole region affected by verruca vulgaris, including the EAC, mastoid skin, and tympanic membrane. Once the whole epithelial skin and mucosa is removed in the deaf ear, otologic surgeons usually consider filling the dead space with abdominal fat and obliterating the EAC orifice to prevent future infection. However, we conducted meatoplasty by reconstructing EAC with a skin graft and temporalis muscle fascia graft to monitor the recurrence of verruca vulgaris. There was no evidence of recurrence after 12 months of observation, but careful observation is needed in the future due to the high recurrence rate.

CONCLUSION

The current case is the most wide-spread and well-controlled case of verruca vulgaris of the ear reported to date. The lesion involved the EAC, tympanic membrane, and automastoidectomized mastoid skin, except for the entrance of EAC. Although there are currently no treatment guidelines for verruca vulgaris in EAC, we believe that complete surgical removal by canal wall-down mastoidectomy plus meatoplasty is a promising option in wide-spread cases. To minimize the risk of disseminating the wart particles, en bloc resection similar to the surgery for malignant tumor is needed.

Informed Consent: Written informed consent was obtained from patients who participated in this study.

Peer-review: Externally peer-reviewed.

Author Contributions: Concept - H.J.S.; Design - H.J.S.; Supervision - H.J.S.; Resources - T.Y.H., H.J.S.; Materials - T.Y.H., H.J.S.; Data Collection and/or Processing - E.S.L., H.S.O.; Analysis and/or Interpretation - E.S.L., H.S.O.; Literature Search - H.S.O.; Writing Manuscript - H.S.O.; Critical Review - H.J.S.

Conflict of Interest: The authors have no conflict of interest to declare.

Financial Disclosure: The authors declared that this study has received no financial support.

REFERENCES

1. Androphy EJ, Kirnbauer R. Human papilloma virus infections. In: Goldsmith LA, Katz SI, Gilchrist BA, Paller AS, Leffell DJ, Wolff K, editors. *Fitzpatrick's dermatology in general medicine*. 8th ed. New York: McGraw-Hill; 2012. p. 2421-33.
2. Kim J, Lee DH, Cho KJ, Lee SY. Huge verruca vulgaris (wart) of the external auditory canal. *Otolaryngol Head Neck Surg* 2008; 139: 865-6. [\[CrossRef\]](#)
3. Lee JH, Burm JS, Yang WY, Kang SY, Byun SW. Treatment of verruca vulgaris in both external auditory canals using bleomycin injections. *Clin Exp Otorhinolaryngol* 2015; 8: 295-7. [\[CrossRef\]](#)
4. Shangkuan WC, Lin MY. Verruca vulgaris of tympanic membrane treated with topical immunotherapy. *Am J Otolaryngol* 2014; 35: 242-5. [\[CrossRef\]](#)
5. Micali G, Dall'Oglio F, Nasca MR, Tedeschi A. Management of cutaneous warts: an evidence-based approach. *Am J Clin Dermatol* 2004; 5: 311-7. [\[CrossRef\]](#)