

ORIGINAL ARTICLE

Comparative Analysis of the Proliferative Activity of Cholesteatoma Epithelium

Jerzy Kuczkowski, E. Izicka-Swieszewska, Alicja Bakowska

Department of Otolaryngology (J. Kuczkowski) Department of Pathomorphology (E. Izicka-Swieszewska) Department of Immunopathology (A. Bakowska) Medical University of Gdańsk/Poland

Correspondent Author:

Jerzy Kuczkowski
80-211 Gdańsk, Debinki 7. Poland

E-mail: jerzyk@amg.gda.pl

Submitted: May 27, 2008

Revised: August 8, 2008

Accepted: September 10, 2008

Mediterr J Otol 2008; 148-151

Copyright 2005 © The Mediterranean Society of Otolaryngology and Audiology

BACKGROUND: The histopathological characteristics of cholesteatoma are hyperproliferation and differentiation of the epithelium. The proliferative capacity of cholesteatoma was studied through the kinetics of the epithelium of cholesteatoma. The present study was undertaken to compare the rate of proliferation and apoptosis using immunohistochemistry with PCNA antigen and p53 protein in cholesteatoma and skin of external auditory canal.

MATERIAL AND METHODS: The expression and location of tissue PCNA and p53 were investigated in 29 samples of cholesteatoma and 8 skin specimens obtained during ear surgery. The tissues were fixed in formalin and embedded in paraffin for immunohistochemistry carried out using antibodies to PCNA and p53.

RESULTS: Strong expression of PCNA was observed in spinous and granular layer of the epithelium in 41.4% cases of the cholesteatomas (mean positive rate 7.6 ± 3.4). In the skin, PCNA was present only in single cells of the epidermis. Protein p53 was present in 14.7% of investigated samples of cholesteatoma (mean positive rate 13.8 ± 2.2). The strongest expression of p53 was observed in the nucleus of the keratinocytes in granular layer of cholesteatoma epithelium. Presence of p53 in the skin was shown only in single cells of the epidermis.

CONCLUSIONS: Cholesteatoma epithelium is characterized by increased expression of p53 and PCNA. Proliferative activity is mainly observed in the granular layer of the epithelium of cholesteatoma. We observed an increase in the rate of proliferation and dysregulation in the cholesteatoma epithelium when compared with normal skin of auditory canal.

Chronic otitis media with cholesteatoma causes mostly considerable hearing loss and may lead to severe complications. Cholesteatoma is of cystic form in microscopic structure, it resembles greatly skin, composed of squamous cell epithelium (matrix), stroma (perimatrix) and desquamated epidermis ^[1]. The presence of squamous cell epithelium producing keratin is very characteristic for cholesteatoma ^[1, 2, 3]. Most of acquired cholesteatomas are the result of migration of the squamous cell epithelium or hiperplasia of the basal cells of tympanic membrane ^[1,4]. Growth of keratinocytes depends on controlled coordination of cell proliferation and programmed cell death ^[4]. Proliferating cells in cholesteatoma epithelium are dislocated. Immunohistochemical methods using antibodies specific to cell-cycle related antigens are used as means for assessing various aspects of proliferation in cholesteatoma. Proliferating cell nuclear antigen (PCNA) is non-histone nuclear protein whose level of synthesis has been found to correlate directly with rates of DNA synthesis and cellular proliferation. PCNA-positive cells have been identified in normal tissue compartments known to contain proliferating cells (basal layer of the skin, germinal centers of the lymph nodes, in benign epithelial disorders, lymphomas and solid tumors) ^[5, 6]. The p53 protein has been identified as a product of a tumor supressor gene. Protein p53 inhibits, as it was described, the conversion from phase G2 to phase M of the cell growth cycle. This protein regulates the cell growth cycle ^[1, 7, 9]. P53 protein is an important marker of apoptosis and initiation of mitosis ^[4]. The purpose of the present study was to analyze cholesteatoma epithelium for presence and distribution of p53 and PCNA protein and to compare it to normal skin.

MATERIAL AND METHODS

Material consisted of 29 samples of acquired cholesteatoma (15 epitympanum and 14 sinus tympani) obtained from patients during primary ear surgery for chronic otitis media with cholesteatoma,

performed at the Department of Otolaryngology Medical University of Gdańsk in period from 2002 to 2007. Eight specimens of skin of the bone portion of the external auditory canal were collected from each patient operated for cholesteatoma and employed as the control. There were 18 men and 11 women at the age from 20 to 64 years (mean age was 37.5). The control samples were 8 skin specimens from external auditory canal obtained from patients during ear surgery. Specimens were immediately fixed in 10% solution of formalin and embedded in paraffin. For immunohistochemical assay, 4 µm paraffin-embedded tissue sections were prepared and placed on the adhesive slides (covered with 10% solution of poly-L-lysine; Sigma N0 P8920 USA). For enhanced antigen retrieval in formalin-fixed, paraffin-embedded tissues we used the microwave-oven heating method. The monoclonal antibodies to p53 (Dako, Code M7001, 1:50) and PCNA (Novocastra, Code NCL-PCNA, 1:80) were used for immunohistochemical staining of the sections. The streptavidin-biotin horseredish kit (Dako, LSAB2, Kit 0675, USA) was used for immunohistochemical staining (detection of bounded antibodies). Endogenous peroxidase of each section was inhibited with 0,3% solution hydrogen peroxidate in methanol for 30 minutes. Each section was immunoreacted with 5% solution of calf-fetal serum for 1 hour. The sections were washed with phosphate buffer solution (PBS) to prevent from drying. The negative control were specimens treated with non-immunological serum. Specimens were dehydrated in alcohol and xylol, and embedded in Canada balsam. Dense staining areas were selected under the light microscope. Stained tissue sections were independently examined by two pathologists (Drs I.E, B.A.). The number of cells positive for p53 or PCNA was estimated by counting deeply stained nuclei and at high magnification in five folds for each case. The percentages of p53 or PCNA positive staining cells were expressed in terms of \pm SD (number of p53 or PCNA positive cells/total number of keratinocytes in matrix x 100%).

Student t test was applied for the comparison between two groups. P values less than 0.05 were considered statistically significant.

RESULTS

Immunohistochemical staining of cholesteatoma specimens showed expression of p53 in 4 of 29 (13.8%) cases in the nuclei of the keratinocytes in the granular layers. The intensity of p53 staining was increased in the suprabasal layer of the epithelium. The expression of p53 in the cholesteatoma epithelium was greater in the cells of granular layers. The normal meatal skin staining was very weak in the basal layer of epidermis. The mean p53-positive rate was $13.8\% \pm 2.2\%$. Analysis of obtained results by Student t-test showed, that there was no significant difference in p53 positive-staining rate between normal skin and cholesteatoma epithelium ($p=0.56$). (Fig. 1a, Fig.1b)

Immunohistochemical staining for PCNA in acquired cholesteatoma showed positive cells in the basal and subbasal layer of epithelium in 12 of the 29 patients, particularly in its granular layer. The presence of PCNA positive cells was not observed in suprabasal cells, but only in some cells in basal layer of meatal skin and the intensity was smaller. The PCNA-positive rate was $7.6\% \pm 3.4\%$, and the mean value was significantly higher than that of the control skin ($p<0.05$). (Fig. 2a, Fig.2b).

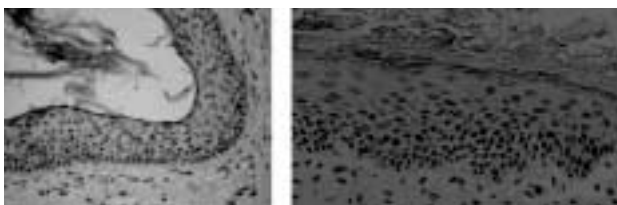


Figure-1: P53 protein immunostaining. **Fig. 1a.** Acquired cholesteatoma epithelium. Positive staining of p53 protein was observed in the nuclei of keratinocytes in the granular layer of cholesteatoma epithelium. **Fig.1b.** Control p53 staining of the meatal skin (original magnification x 200).

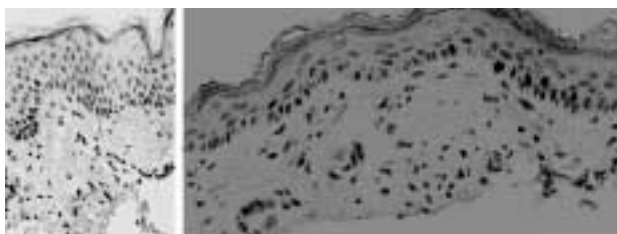


Figure-2: Proliferating cell nuclear antigen (PCNA) immunostaining. **Fig. 2a.** Acquired cholesteatoma. PCNA cells were observed in the suprabasal layers of the epithelium. **Fig.2b.** Control PCNA staining of the meatal skin (original magnification x 200).

DISCUSSION

Keratinocytes constitute more than 95% of the epidermal cells and in the basal and suprabasal layers of epidermis show the increased level of proliferation^[1, 6]. Proliferation and differentiation of epithelium is a pathologic feature of cholesteatoma. Accumulation of keratin debris in the middle ear is characteristic for cholesteatoma and this is the result of increased rate of keratinocytes death. The basal keratinocytes migrate into more superficial layers, where they lose their proliferative capacity^[4, 5]. The cholesteatoma is characterized by a high percentage of proliferating cells in basal and suprabasal layers of epithelium.^[2, 7]

Furthermore, PCNA and p53 protein may participate in the growth and development of cholesteatoma. A p53 protein plays an important role in negatively controlling cell proliferation. This cellular tumor suppressor most often produces growth arrest at the cell cycle G1/S boundary. Huisman et al. showed that increased cell proliferation in cholesteatoma is not compensated by apoptosis, but may be associated with cell cycle arrest^[4]. One of the major goals of this study was to estimate proliferative potential of the cholesteatoma epithelium. In many studies, several nuclear proteins expressed in proliferating cells of the cholesteatoma have been described. Immunohistochemical studies indicated that p53 protein was localized in the nuclei of the epithelium in the granular layer of cholesteatoma^[2, 7, 8]. Albino et al.^[1] proved the high expression of p53 protein in cholesteatoma, over a dozen times higher than observed in the skin or tympanic membrane. The increased expression of p53 in cholesteatoma is not associated with genetic instability^[1, 2, 8]. It means, that probability of p53 mutation in cholesteatoma is very small. Proliferating cell nuclear antigen (PCNA) is an antigen of autoantibody that specifically responds to proliferating cell nucleus^[3, 4, 6]. PCNA is detected in the G0 phase of the cell cycle; it appears in the nucleus from the G1 through the S and disappears in the S phase. From these findings, PCNA is involved in DNA

synthesis and cell proliferation^[5, 8]. Recent studies have shown an increase in the expression of p53 protein that is involved in proliferation^[2, 5, 6]. Tanaka et al^[9] observed PCNA-positive cells in basal and suprabasal layers in almost all specimens of cholesteatoma (PCNA-positive rate was 19.9±12.6%). Comparing the staining pattern of PCNA expression of cholesteatoma epithelium with that of normal meatal skin we showed that in cholesteatoma the suprabasal layer has the ability to undergo cell division. In the meatal skin, the process of differentiation begins after the cells are detached from the basal layer. The pattern of PCNA expression appears to be similar to that found with other proliferation markers, such as Ki67^[6]. Our study demonstrates that cell proliferation in cholesteatoma epithelium is characterized by increased PCNA expression and p53 concentration which suggests a halt to proliferation in stadium G1. These results might be caused by a disfunction of p53 protein, indicating a transcriptionally active p53 protein^[4]. This indicates that in acquired cholesteatomas apoptosis may not be required as a cellular protection mechanism^[4]. In our study we have demonstrated that increased proliferation in acquired cholesteatomas is not compensated by apoptosis, but may be associated with cell cycle arrest.

CONCLUSIONS

The p53 protein and PCNA were present in the nucleus of keratinocytes in the granular layer of cholesteatoma epithelium. The epidermis of the meatal skin was slightly stained in the basal layer. The present findings suggest that p53 protein and PCNA have a role in epithelium proliferation and differentiation in the cholesteatoma. Proliferative activity is mainly observed in the suprabasal layers of the cholesteatoma epithelium. Our findings indicate that PCNA is a good marker for proliferation, showing that cholesteatoma epithelium proliferates at a higher rate compared to normal epidermis of skin.

REFERENCES

1. Albino A P, Reed JA, Bogdany J K, Sassoon J, Desloge RB, Parisier SC. Expression of p53 protein in human middle ear cholesteatomas. Pathogenetic implications. *Am J Otol* 1998; 19: 30-36.
2. Bayazit Y, Bakir K, Kanlikama M, Ozer E, Mumbuc S, Desikirik I et al. Expression of the p53 and nm23 genes in cholesteatoma. *Acta Otolaryngol* 2002; 122: 726-729.
3. Bujia J, Sudhoff H, Holly A, Hildmann H, Kastenbauer E. Immunohistochemical detection of proliferating cell nuclear antigen in middle ear cholesteatoma. *Eur Arch Otorhinolaryngol* 1996; 253: 21-24.
4. Hassmann-Poznan_ska, E, Skotnicka B, Dzi_cio_, J. Markers of epidermal proliferation in middle ear cholesteatoma *Otolaryngol Pol* 2003;57:505-511.
5. Kojima H, Tanaka Y, Tanaka T, Miyazaki H, Shiwa M, Kamide Y. et al. Cell proliferation and apoptosis in human middle ear cholesteatoma. *Arch Otolaryngol Head Neck Surg* 1998; 124: 261- 264.
6. Kuczkowski J. Etiopathogenesis of chronic otitis media in histopathological, immunohistochemical and molecular assessment. *Ann Acad Med Gedan* 2004; 34:1-205.
7. Olszewska, E, Chodynicky S, Chyczewski L. Evaluation of epithelial proliferation and apoptosis in cholesteatoma of adults. *Otolaryngol Pol.* 2003;57: 85-89.
8. Shinoda H, Huang C. Expression of c-jun and p53 proteins in human middle ear cholesteatoma: relationship to keratinocyte proliferation, differentiation and programmed cell death. *Laryngoscope* 1995; 105: 1232-1237.
9. Tanaka Y, Shiwa M, Kojima H, Miyazaki H, Kamide Y, Moriyama H. A study on epidermal proliferation ability in cholesteatoma. *Laryngoscope* 1998; 108: 537-542.