

Original Article

The Effect of Auricular Graft Donor Site on Morbidity and Cosmetic Appearance in Cartilage Tympanoplasties

Aydın Hüseyinoğlu , Cem Uzun , Ahmet Koder , Recep Yağız , Erol Benlier ,
Erdoğan Bulut 

Clinic of Otorhinolaryngology, Ağrı State Hospital, Ağrı, Turkey (AH)

Department of ORL, Trakya University School of Medicine, Edirne, Turkey (CU, RY)

Clinic of Otorhinolaryngology, Düzce Atatürk State Hospital, Düzce, Turkey (AK)

Department of Plastic Reconstructive and Aesthetic Surgery, Trakya University School of Medicine, Edirne, Turkey (EB)

Department of Audiology, Trakya University School of Health Sciences, Edirne, Turkey (E.Bulut)

ORCID iDs of the authors: A.H. 0000-0001-6115-0692; C.U. 0000-0003-3233-7049; A.K. 0000-0003-4348-8109; R.Y. 0000-0003-2004-2139; E.B. 0000-0001-7016-3735; E.Bulut 0000-0003-2036-6870.

Cite this article as: Hüseyinoğlu A, Uzun C, Koder A, Yağız R, Benlier E, Bulut E. The Effect of Auricular Graft Donor Site on Morbidity and Cosmetic Appearance in Cartilage Tympanoplasties. J Int Adv Otol 2020; 16(1): 67-72.

OBJECTIVES: The aim of the present study was to compare the postoperative morbidity and cosmetic results between the use of the scapha and the use of the tragus as the auricular cartilage graft donor site in patients who had undergone cartilage tympanoplasty. The fascia graft was used as the control.

MATERIALS and METHODS: The patient's visual symmetry, cosmetic satisfaction, and anthropometric measurements were studied to objectively evaluate the cosmetic condition. The formation of skin scar changes, pigmentation changes, and sensory changes as clinical criteria were compared.

RESULTS: A total of 234 patients and their 257 operated ears were included in the study. Forty prospectively operated ears with preoperative findings were also included. All patients (100%) felt that their results were good, as indicated by the visual analog scale, and the anthropometric ear measurements used to reinforce the data showed no significant differences between the groups. A significant difference with respect to clinical sensory changes was found between the groups only in patients undergoing unilateral surgery via the retro auricular approach ($p < 0.05$). There was no difference between the scapha and tragus groups with respect to scar formation or skin pigmentation change.

CONCLUSION: Neither scapha nor tragus use for graft retrieval led to dissatisfaction or cosmetic problems in the postoperative period. Sensory changes in the skin on clinical evaluation were less common in patients in whom the scapha donor site was preferred than in cases in which the tragus was used.

KEYWORDS: Tympanoplasty, cartilage, cosmetic, graft, scapha, tragus

INTRODUCTION

The use of the cartilage in tympanic membrane reconstruction surgery is not new. Although a fascia graft is usually used in tympanoplasty, the use of a cartilage graft has been preferred in tympanoplasty in recent years due to high rates of success and good hearing reconstruction results ^[1-6], especially in the long term ^[7] and in the ears with poor tubal function ^[8]. In addition to its higher graft intake rate, cartilage tympanoplasty provides similar or better hearing results than fascia grafting ^[7-10]. Cartilage tympanoplasty can also provide similar tympanometric findings as fascia grafting ^[11]. Thus, the cartilage is used as a successful graft material in many challenging middle ear conditions (e.g., active infection, cholesteatoma, and tympanosclerosis) due to its slow metabolism, lack of capillaries, supply via diffusion, resistance to infection, and durability ^[7-14]. Additionally, it is the most appropriate choice as a graft material in high-risk perforations, such as anterior membrane perforations, ear discharge during surgery, perforation of >50%

This study was presented at the 2nd Meeting of European Academy ORL&HNS and CEORL-HNS, 2013, Nice, France.

Corresponding Address: Cem Uzun E-mail: cemuzun@yahoo.com

Submitted: 19.02.2018 • **Revision Received:** 10.07.2018 • **Accepted:** 31.07.2019 • **Available Online Date:** 30.09.2019

Available online at www.advancedotology.org



Content of this journal is licensed under a
Creative Commons Attribution-NonCommercial
4.0 International License.

of the eardrum, cholesteatoma, chronic tubal dysfunction, tympano-sclerotic plaque perforations, burn perforations, atrophic membrane perforations, revision tympanoplasty, tympanic adhesions, retraction pockets, and partial or complete atelectatic membranes [9-14].

The cartilage in middle ear surgery was first used in 1959 for a retraction pocket repair [15]. Currently, the two most common cartilage tympanoplasty techniques are the cartilage island technique and the palisade technique [9, 10, 16]. Cartilage grafts are usually harvested from the tragus and concha sites of the auricle for cartilage tympanoplasty. Cartilage graft retrieval from the triangular fossa and cyma sites has also been reported [6, 10, 12, 13]. A cartilage graft can also be obtained from the scapha region (Figure 1). Uzun [17] described the technique of harvesting a graft from the scapha for cartilage tympanoplasty, and Tos [18] published the details of this technique. An incision (0.5-1.5 cm, depending on the need of cartilage graft and size of the scapha) is made posterior to the scapha between the helix and the crura keeping them intact. An ellipsoid shape cartilage is cut while preserving the anterior skin of the scapha intact [17, 18]. Harvesting cartilage from the scapha is as easy as harvesting cartilage from the tragus by taking almost similar surgical time [17].

The effect of auricular graft donor site on morbidity and cosmetic appearance in patients who had undergone cartilage tympanoplasty was investigated.

MATERIALS AND METHODS

Patients and Groups

A total of 257 ears of 234 patients who underwent middle ear surgery (myringoplasty, tympanoplasty, or tympanoplasty-mastoidectomy) with cartilage tympanoplasty at Trakya University Hospital's Department of Otorhinolaryngology between January 2004 and February 2012 for which cartilage graft or fascia was used, a minimum of 6 months of follow-up was recorded, and the study criteria were met were included in the study. The patients underwent clinical evaluation of the ear, assessment via the visual analog scale (VAS), and anthropometric measurements.

Since there were only six patients for which the concha or cyma was used for cartilage graft, precluding a healthy comparison for these graft donor sites, these patients were excluded from the study. When comparing the scapha and tragus as the site of the cartilage graft, the fascia group was used as the control group to obtain more accurate results. Therefore, a comparative analysis was conducted between the scapha, tragus, and fascia groups. The groups were also compared by considering the surgical approach (retroauricular, transcanal, and endaural). Additionally, postoperative findings were compared with preoperative values in 40 patients for whom preoperative anthropometric measurements were available. Patients aged >2 years for whom the scapha and tragus or fascia was used as a graft and middle ear surgery was performed with at least 6 months of follow-up were included in the study. Patients who had non-surgery-related traumatic or malformation-related deformity in the ear, asymmetry of the face, or a history of perichondritis were excluded from the study. Patients whose cartilage grafts were obtained from the concha, cyma, or fossa triangularis were also excluded. Patients who met the inclusion criteria and agreed to participate underwent

clinical evaluation of the ear, together with the VAS and anthropometric measurements.

The study was approved by the Trakya University Medical Faculty Ethics Committee. Each patient was informed in detail regarding the study to be performed. Informed consent was obtained from all of the patients before the examination.

Clinical Assessment

In the clinical examination, scarring due to skin contraction at the donor site, clinical sensory changes (hypoesthesia, anesthesia, and hyperesthesia), and skin pigmentation changes (hypopigmentation and hyperpigmentation) were evaluated (19). In the evaluation of scarring due to contractions and skin pigmentation changes (hypopigmentation and hyperpigmentation), a total of 257 diseased graft donor ears were included, regardless of whether single or double ears were operated. With respect to the cartilage graft (scapha and tragus) groups, to evaluate skin scarring and pigmentation changes, the graft donor site was compared with the adjacent skin. For clinical sensory changes (hypoesthesia, anesthesia, and hyperesthesia), only 211 patients for whom a single ear was treated were evaluated. In the clinical evaluation of sensory changes, in the scapha and tragus groups, comparisons were made with the same donor site in the opposite ear; however, in the fascia group, since no additional incision was made for graft removal, only the skin regions adjacent to the surgical approach incision were compared with the healthy ear.

Visual Analog Scale

Symmetry and cosmetic satisfaction of the patient were evaluated using the VAS by Bhatti and Donovan (20). The scores varied between 1 and 10. A score of 7-10 was accepted as a good result, and a score of <7 was accepted as a poor result. Since the VAS is performed by comparing the patient's operated ear with the non-operated ear, this evaluation could only be performed in the 211 patients with unilateral surgery.

Anthropometric Measurements

Anthropometric measurements were performed to detect ear morphology changes due to cartilage removal. These measurements were performed on 211 ears that had undergone unilateral surgery, and these were then compared with measurements of the healthy ear. Following Weerda [21], auricle length and width, ear protrusion (auricle-mastoid plane angle), eye lateral canthus-ear helix outer border, and eye lateral canthus-ear antihelix crura lateral border distances were calculated. The auricle-mastoid plane angle was measured from the outer border of the ear helix to the point of the mastoid accepted as the highest point. The distance from the lateral canthus to the ear helix outer border on the horizontal plane was measured, followed by the distance from the lateral canthus to the ear antihelix outer border, which was measured without changing the position of the measuring device. The ear length was accepted as the measurement from the most superior and lateral point of the ear to the most inferior and lateral point of the ear in the vertical plane perpendicular to the measurement between the lateral canthus and the ear helix outer border. The ear width was accepted as the distance between the most protruding point of the tragus, called the tip, and the ear helix outer border, parallel to the lateral canthus to the helix outer border measurement.

Statistical Analysis

The Statistica 7.0 (StatSoft, Inc., Tulsa, OK, USA; serial number: AXF003C775430FAN2) software program was used for statistical analyses. The results of our study were first evaluated with respect to their compliance with a normal distribution in statistical analysis. One-way ANOVA was used for intergroup comparisons, the paired sample T-test for within-group comparisons, and the independent sample T-test for comparison of two independent groups. The chi-square test was used to evaluate the symmetry, cosmetic satisfaction, and clinical scar–pigmentation–sensory changes on the skin between the groups. A p value <0.05 was accepted as significant.

RESULTS

There was no difference between the scapha, tragus, and fascia groups with respect to age or gender distribution ($p>0.05$). Furthermore, there was no difference between the groups with respect to these parameters in the 40 patients (subgroup) with preoperative and postoperative measurement records ($p>0.05$). The graft was harvested from the scapha in 137 (53%) operated ears, the tragus in 74 (29%) operated ears, and the fascia in 46 (18%) operated ears. In the 40 operated ears included in the subgroup, the graft was obtained from the scapha in 26 (65%) ears, the tragus in 10 (25%) ears, and the fascia in 4 (10%) ears. The retroauricular approach was used in 208 (80%) ears, the transcanal approach in 41 (16%) ears, and the endaural approach in 8 (4%) ears. Since the endaural approach was used in only a few patients, it was not taken into account in the comparison by approach. However, there was no significant difference between the groups (or in the subgroup analysis) when the retroauricular and transcanal approaches were compared ($p>0.05$). The VAS results for ear symmetry and cosmetic satisfaction for the 211 patients with unilateral surgery in

all three groups varied from 7 to 10, indicating a good result. Skin contraction-related scar formation was observed in 9 (7%) ears in the scapha group and 5 (7%) ears in the tragus group. There was no difference between the groups with respect to scar formation ($p>0.05$), and there was no significant difference in comparisons between the groups by approach ($p>0.05$) (Table 1). Clinical sensory changes (hypo/hyperesthesia) were found in 8 (6%) ears in the scapha group, 9 (12%) ears in the tragus group, and none in the fascia group (Table 1). Comparison within the approach groups revealed a significant difference between the tragus and fascia groups with respect to sensory changes in the ears subjected to a retroauricular approach ($p<0.05$), with hypoesthesia or hyperesthesia being more common in the tragus group. There was no significant difference in other comparisons (Table 1).

Pigmentation changes in the skin (hypo/hyperpigmentation) were found in 17 (12%) ears in the scapha group and 11 (15%) ears in the tragus group ($p>0.05$). Comparison within the approach groups revealed a significant difference between the tragus and fascia subgroups with respect to pigmentation changes in the ears subjected to a retroauricular approach ($p<0.05$). There was no significant difference in other comparisons (Table 1).

Anthropometric measurements can differ according to the approach; thus, patients were compared separately by approach. However, there were no significant differences between the groups in any comparison ($p>0.05$) (Table 2).

There was no significant difference with respect to the parameters evaluated in the subgroup (40 ears) for which preoperative and postoperative measurements were compared ($p>0.05$).

Table 1. Clinical assessment regarding approach and graft donor site

Approach	Graft donor site	n (%)	Skin contraction scar		Skin appearance (hypo/hyperpigmentation)		Single ear operated	Sensory change (hypo/hyperesthesia)	
			n (%)	p*	n (%)	p*		n (%)	p*
RA	Scapha	118 (57)	6 (5)	>0.05**	15 (13)	>0.05**	93 (54)	7 (8)	>0.05**
	Tragus	57 (27)	3 (5)	>0.05***	9 (16)	<0.05***	49 (28)	8 (16)	<0.05***
	Fascia	33 (16)	0 (0)	>0.05****	0 (0)	<0.05****	30 (18)	0 (0)	>0.05****
	Total	208 (100)	9 (4)		24 (12)		172 (100)	15 (9)	
TK	Scapha	19 (46)	3 (16)	>0.05**	2 (11)	>0.05**	15 (45)	1 (6)	>0.05**
	Tragus	15 (37)	2 (13)	>0.05***	1 (7)	>0.05***	13 (40)	1 (7)	>0.05***
	Fascia	7 (17)	0 (0)	>0.05****	0 (0)	>0.05****	5 (15)	0 (0)	>0.05****
	Total	41 (100)	5 (12)		3 (7)		33 (100)	2 (6)	
EA	Scapha	0 (0)	0 (0)	None	0 (0)	None	0 (0)	0 (0)	None
	Tragus	2 (25)	0 (0)	>0.05***	1 (50)	>0.05***	1 (17)	0 (0)	None
	Fascia	6 (75)	0 (0)	None	0 (0)	None	5 (83)	0 (0)	None
	Total	8 (100)	0 (0)		1 (13)		6 (100)	0 (0)	
Grand total	257	14 (5)		28 (11)		211	17 (8)		

*, Chi-square test, **: scapha versus tragus, ***: tragus versus fascia, ****: scapha versus fascia. Significant differences were also outlined in bold.

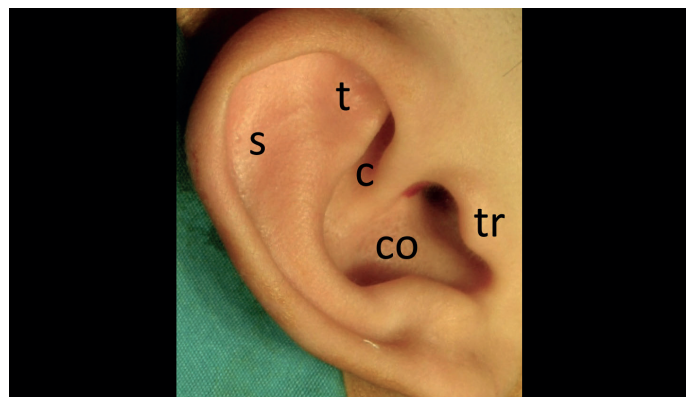
N: number of patients; RA: retroauricular; TK: transcanal; EA: endaural.

Table 2. Anthropometric measurements regarding approach and graft donor site

Approach (n)	Graft donor site	Ear	Auriculo-mastoid angle (°)	Lateral canthus–helix outer side (mm)	Lateral canthus–antihelix outer side (mm)	Auricular height (mm)	Auricular width (mm)
RA (172)	Scapha	Mean	23.01	108.56	95.87	63.55	24.94
		N	93	93	93	93	93
		p*	>0.05**	>0.05**	>0.05**	>0.05**	>0.05**
	Tragus	Mean	23.04	108.93	95.93	63.40	24.53
		N	49	49	49	49	49
		p*	>0.05***	>0.05***	>0.05***	>0.05***	>0.05***
	Fascia	Mean	23.03	109.76	97.00	64.73	24.90
		N	30	30	30	30	30
		p*	>0.05****	>0.05****	>0.05****	>0.05****	>0.05****
TK (33)	Scapha	Mean	23.80	106.60	93.60	61.46	25.53
		N	15	15	15	15	15
		p*	>0.05**	>0.05**	>0.05**	>0.05**	>0.05**
	Tragus	Mean	22.21	104.78	91.42	60.92	24.71
		N	13	13	13	13	13
		p*	>0.05***	>0.05***	>0.05***	>0.05***	>0.05***
	Fascia	Mean	24.80	106.60	94.60	63.00	24.40
		N	5	5	5	5	5
		p*	>0.05****	>0.05****	>0.05****	>0.05****	>0.05****
EA (6)	Scapha	Mean	None	None	None	None	None
		N	0	0	0	0	0
		p*	None	None	None	None	None
	Tragus	Mean	24.00	116.00	100.00	70.00	27.00
		N	1	1	1	1	1
		p*	None	None	None	None	None
	Fascia	Mean	22.40	110.00	97.00	65.40	25.80
		N	5	5	5	5	5
		p*	None	None	None	None	None

*: Independent variable t-test, **: scapha versus tragus, ***: tragus versus fascia, ****: scapha versus fascia.

N: number of patients; RA: retroauricular; TC: transcanal; EA: endaural.

**Figure 1.** Auricular cartilage graft donor sites.

s: scapha; t: triangular fossa; c: cymba; co: concha; tr: tragus.

DISCUSSION

A constructive study was performed on the effect of auricular graft donor site on morbidity and cosmetic appearance, as this effect has not been adequately investigated in previous studies. Uzun^[17], the senior author, reported the technique of harvesting scaphal cartilage, which was also detailed in a publication by his mentor Tos^[18]. Harvesting cartilage from the scapha is not popular; however, it is an easy technique, and the cartilage graft from the scapha is clean (has very little soft tissue) and smooth. It would be interesting to investigate scaphal graft donor site morbidity. Thus, 257 operated ears of 234 patients were included in the study to properly contribute data on this subject and ensure an adequate sample size. We believed it would be possible to predict the morbidity or cosmetic problems that could arise following ear surgery with such a comprehensive

study and aimed to detect any morbidity or cosmetic problems by comparing cartilage graft with fascia graft.

Bhatti and Donovan ^[20] used a cartilage scoring technique following prominent ear repair surgery by sutureless autoplasty in 34 patients with a minimum of 3 (3-6) months of follow-up. They followed the patients with respect to the possible results (residual or recurrent prominent ear) and the development of complications (hematoma, infection, keloid, hypertrophic scar, or anterior skin necrosis). They used the VAS to evaluate the cosmetic appearance and symmetry of the ear and used a scale ranging from 1 to 10, with 1 being the worst result and 10 being the best result possible. There was no hematoma or hypertrophic scarring observed in any of the patients, and only one patient was not satisfied with the cosmetic appearance in their study ^[20]. The morbidity and cosmetic effect of the graft donor site in the auricle for cartilage tympanoplasties were analyzed in our study. The VAS (between 1 and 10) scores reflecting symmetry and cosmetic satisfaction, clinical examination of the graft donor site (skin contraction scarring, sensory changes consisting of hypo/hyperesthesia, and skin pigmentation changes consisting of hypo/hyperpigmentation), and anthropometric measurements (auriculo-mastoid angle, lateral canthus-helix outer border, lateral canthus-antihelix outer border, ear length, and ear width) were also used to evaluate patients for a minimum follow-up duration of 6 months and a mean follow-up duration of 30 (6-96) months. There were no complications, such as hematoma or hemorrhage, observed during the early postoperative period or afterward in any patient. VAS scores of ≥ 7 were obtained for symmetry and cosmetic satisfaction in all the patients. VAS scores of 7-10 were graded as good, 4-6 as moderate, and 0-3 as poor. Therefore, all patients had good symmetry and cosmetic satisfaction. There was no dissatisfaction with respect to graft donor site (scapha, tragus, or fascia) in any of the patients.

In the study by Robert et al. ^[19] on donor site morbidity in ear cartilage autografts from 52 patients with at least 3 months of follow-up, grafts were obtained from the concha, scapha, and tragus. Subjective complaints, clinical examination of the donor site (scarring, sensory changes, and skin pigmentation changes), and anthropometric measurements were recorded for the patients. In cases of cartilage removal, there were 4 (6.7%) patient ears that exhibited hematoma development, which is an early postoperative complication, of which 2 (3.3%) were from the concha and the other 2 (3.3%) were from the tragus. One of the two patients with tragus cartilage removal was on a continuous acetylsalicylic acid drug due to factor C deficiency. When long-term postoperative findings (at least 3 months) were evaluated for the conchal graft site, hypoesthesia in 3 (9.7%) patients' ears, hyperesthesia in 1 (3%) patient's ear, hypopigmentation in 1 (3%) patient's ear, hyperpigmentation in 1 (3%) patient's ear, and scarring in 1 (3%) patient's ear due to skin contraction were observed. There was no significant morbidity in the diseased ears when long-term postoperative findings (at least 3 months) were evaluated. Anthropometric values were compared between single-side operated diseased ears and non-operated healthy ears, and there was no significant difference ($p>0.05$).

Although hypopigmentation on any skin incision is an expected finding, almost all of our patients with skin pigmentation changes had hypopigmentation. This pigmentation change on the skin was not sufficiently severe to create visual discomfort in the patients. The

presence of a significant difference with the retroauricular approach with respect to clinical sensory changes at the tragal graft donor site showed the scapha to be a safe donor site with respect to postoperative clinical problems, even in patients in whom an incision behind the ear was used as the scapha donor site incision. The fact that all (100%) patients had good symmetry and cosmetic satisfaction results indicates that the cartilage grafts obtained for cartilage tympanoplasty are as successful as surgery using the fascia with respect to patient satisfaction. There was no significant difference between the anthropometric measurements obtained from all (100%) of our patients to objectively evaluate their satisfaction regarding symmetry and cosmetic satisfaction, reinforcing our results. None of the patients had moderate or severe symptoms. The symptoms were mild, and none of the patients had visual or clinical problems that could have resulted in cosmetic dissatisfaction.

CONCLUSION

In general, scapha and tragus donor sites for cartilage graft in tympanoplasty do not cause morbidities that lead to postoperative dissatisfaction or aesthetically important problems. Visual assessment of symmetry and aesthetic satisfaction yielded good postoperative results in all of the graft site groups. There was no dissatisfaction after surgery in any of the patients who had cartilage or fascia removal. Even in the retroauricular approach, the scapha was more reliable than the tragus, thereby indicating that if the cartilage graft in the scapha side is preferred in tympanoplasties, the problems and complaints of the patients that may arise from clinical sensory changes in the postoperative period will be minimized. Of course, here, as in Tos' scaphal cartilage removal technique, the helix and crura should be left intact, and the graft should be obtained in a watermelon-slice shape limited only to the eminencia of scapha ^[17, 18].

As the morbidity rates are very low, there are generally no postoperative cosmetic problems in patients who undergo tympanoplasties with auricular graft removal, regardless of whether the cartilage is obtained from the scapha or tragus.

Ethics Committee Approval: Ethics committee approval was received for this study from the Ethics Committee of Trakya University.

Informed Consent: Informed consent of each participant has been taken during the study.

Peer-review: Externally peer-reviewed.

Author Contributions: Concept – A.H., C.U., E.B.; Design – C.U., E.B., A.H., R.Y., A.K., B.E.; Supervision – C.U., E.B., R.Y.; Resource – A.H., C.U., E.B., E.B., A.K.; Materials – A.H., C.U., E.B., A.K.; Data Collection and/or Processing – A.H., C.U., E.B., R.Y., A.K., E.B.; Analysis and/or Interpretation – C.U., A.H., A.K., E.B., E.B.; Literature Search – C.U., A.H., E.B.; Writing – A.H., A.K., C.U.; Critical Reviews – C.U., R.Y., E.B.

Conflict of Interest: The authors have no conflict of interest to declare.

Financial Disclosure: The authors declared that this study has received no financial support.

REFERENCES

1. Amedee RG, Mann WJ, Riechelmann H. Cartilage palisade tympanoplasty. *Am J Otol* 1989; 10: 447-50. [[Crossref](#)]

2. Heermann J, Heermann H, Kopstein E. Fascia and cartilage palisade tympanoplasty: nine years' experience. *Arch Otolaryngol* 1970; 91: 228-41. [\[Crossref\]](#)
3. Duckert LG, Mueller J, Makielski KH, Helms J. Composite autograft 'shield' reconstruction of remnant tympanic membranes. *Am J Otol* 1995; 16: 21-6.
4. Dornhoffer JL. Hearing results with cartilage tympanoplasty. *Laryngoscope* 1997; 107: 1094-9. [\[Crossref\]](#)
5. Gerber MJ, Mason JC, Lambert PR. Hearing results after primary cartilage tympanoplasty. *Laryngoscope* 2000; 110: 1994-9. [\[Crossref\]](#)
6. Dornhoffer J. Cartilage tympanoplasty: Indications, techniques and outcomes in a 1000-patient series. *Laryngoscope* 2004; 113: 1844-56. [\[Crossref\]](#)
7. Caye-Thomasen P, Andersen J, Uzun C, Hansen S, Tos M. Ten-year results of cartilage palisades versus fascia in eardrum reconstruction after surgery for sinus or tensa retraction cholesteatoma in children. *Laryngoscope* 2009; 119: 944-52. [\[Crossref\]](#)
8. Uzun C, Caye-Thomasen P, Andersen J, Tos M. Eustachian tube patency and function in tympanoplasty with cartilage palisade or fascia after cholesteatoma surgery. *Otol Neurotol* 2004; 25: 864-72. [\[Crossref\]](#)
9. Yang T, Wu X, Peng X, Zhang Y, Xie S, Sun H. Comparison of cartilage graft and fascia in type 1 tympanoplasty: systematic review and meta-analysis. *Acta Otolaryngol* 2016; 136: 1085-90. [\[Crossref\]](#)
10. Jalali MM, Motasaddi M, Kouhi A, Dabiri S, Soleimani R. Comparison of cartilage with temporalis fascia tympanoplasty: A meta-analysis of comparative studies. *Laryngoscope* 2017; 127: 2139-48. [\[Crossref\]](#)
11. Uzun C, Caye-Thomasen P, Andersen J, Tos M. A tympanometric comparison of tympanoplasty with cartilage palisades or fascia after surgery for cholesteatoma in children. *Laryngoscope* 2003; 113: 1751-7. [\[Crossref\]](#)
12. Uzun C, Yagiz R, Tas A, Kutoglu T, Ada S, Karasalioglu AR. [Thickness of external ear cartilage structures according to the anatomical region]. 28. National Turkish Otorhinolaryngology and Head and Neck Surgery Congress, 21-26 May 2005, Belek, Antalya. Abstract book: 145. [Turkish]
13. Uzun C. [Cartilage Palisade Tympanoplasties]. In: Uzun C, ed. [Basic Tympanoplasty (Third Edition)]. Edirne, Turkey: Eser Ofset Digital; 2011. p. 77-83. [Turkish]
14. Abdelhameed W, Rezk I, Awad A. Impact of cartilage graft size on success of tympanoplasty. *Braz J Otorhinolaryngol* 2017; 83: 507-11. [\[Crossref\]](#)
15. Utech H. Ueber diagnostische und therapeutische Moeglichkeiten der tympanotomie bei Schalleitungsstoerungen. *Laryngol Rhinol* 1959; 38: 212-21.
16. Zahnert T, Huttenbring KB, Murbe D, Bornits M. Experimental investigations of the use of cartilage in tympanic membrane reconstruction. *Am J Otol* 2000; 21: 322-8. [\[Crossref\]](#)
17. Uzun C. [Technique of harvesting scaphal cartilage]. In: Uzun C, ed. [Videos of basic tympanoplasty (1st edition)]. Edirne, Turkey: Gulsah 2008 (CD). [Turkish]
18. Tos M. Cartilage tympanoplasty. Approaches and harvesting of cartilage (1st ed.). Stuttgart: Thieme; 2009.p.30-51. [\[Crossref\]](#)
19. Robert AM, Catarina DH, Matthias S, Max JZ. Donor-site morbidity of ear cartilage autografts. *Am Soc of Plas Surg* 2008; 121: 79-87. [\[Crossref\]](#)
20. Bhatti AZ, Donovan DO. Sutureless otoplasty by scoring of the cartilage: A study in 34 patients. *Br J Oral and Maxillofac Surg* 2007; 45: 217-20. [\[Crossref\]](#)