

Original Article

Correlation of Preoperative Computerized Tomography Scoring System and the Surgical Encounters in Cochlear Implantation

Saad Elzayat¹, Mahmoud Mandour², Haitham Elfarargy¹, Rasha Lotfy³, Islam Soltan¹, Ali Mahrous⁴

¹Department of ENT, Kafrelsheikh University, Egypt

²Department of ENT, Tanta University, Egypt

³Department of Radiology, Tanta University, Egypt

⁴Department of ENT, Al-Azhar University, Egypt

Cite this article as: Elzayat S, Mandour M, Elfarargy H, Lotfy R, Soltan I, Mahrous A. Correlation of preoperative computerized tomography scoring system and the surgical encounters in cochlear implantation. *J Int Adv Otol*. 2021;17(3):200-206.

OBJECTIVE: To propose a numerical radiological scoring system of the pre-operative high-resolution computed tomography scan aiming to predict the surgical difficulty during cochlear implantation.

METHODS: This was a retrospective study of 272 pediatric patients who underwent cochlear implantation in 3 tertiary referral centers from April 2017 to August 2019. The correlation was attempted between our proposed scoring system (consisting of 8 radiological features) and the intra-operative surgical difficulty both objectively and subjectively.

RESULTS: our proposed scoring system showed a statistically significant correlation with surgical difficulty and also the duration of surgery. Scoring 5 or more predicted the surgical difficulty with a sensitivity of 80.85% and a specificity of 92.13%. The absence of air cells around the facial recess was the most independent predictor of difficulty (P value = .002).

CONCLUSION: This proposed radiological scoring system is a simple reliable method to predict the difficulty which we may encounter during CI surgery. Scoring of 5 or more would predict intraoperative difficulty as opposed to less scoring which would predict a straightforward surgery.

KEYWORDS: Cochlear implant, score, intraoperative difficulty, CT scan

INTRODUCTION

Predictions of surgical encounters beforehand are at the forefront of modern surgical practice. Not only would it help in readiness to deal with the consequences during surgery but also it would minimize potential complications and plan the surgical time.

As the surgical corridor to reach the cochlea within the context of cochlear implant (CI) surgery is primarily bony, the computed tomography (CT) scan would be the best radiological modality to address predicting the anatomical and pathological surgical encounters in advance.^{1,2} To get successful access to the round window or cochlea, 2 surgical steps should be performed to reach the target. The first step is the cortical mastoidectomy, which is meant to expose the mastoid antrum, the lateral semicircular canal (LSCC), and the short process of the incus.³ The second step is posterior tympanotomy (PT), aiming at reaching the posterior meso-tympanum of the middle ear. It was first described by Jansen in 1958. PT is undertaken by drilling the bone in the facial recess. The latter is a triangular area bounded laterally by the chorda tympani nerve and tympanic annulus, medially by the mastoid segment of the facial nerve and superiorly by fossa incudis.^{4,5}

Many anatomic variations could be encountered, like anteriorly displaced sigmoid sinus, poorly pneumatized mastoid and facial recess, abnormal position of the mastoid segment of the facial nerve, and narrow facial recess.^{6,7} These variations may hinder access to the cochlea, generating different levels of surgical difficulties. Also, they may potentially increase the risk of some complications such as facial nerve trauma, chorda tympani nerve injury affecting taste sensation which is a major problem for some people like

chefs, injury of the wall of EAC, or even injury of the annulus resulting in tympanic membrane perforation.^{8,9}

Many studies have been conducted to detect the anatomical variations predicting the difficulties during cochlear implantation through pre-operative high-resolution CT scan (HRCT). Many of their radiological criteria are complex and difficult to be practically applied. Not only that but most of these studies did not include all the anatomical variants or pathology which may hinder the access to the cochlea with its subsequent impact on the surgical ease or difficulty.

In our study, we proposed a numerical scoring system of various radiological features avoiding the aforementioned shortfalls of the previous studies.

MATERIALS AND METHODS

Ethics

Our institutional review board (IBR) approval has been obtained prior to the inception of our study. Also, we got the consent of the patients' guardian allowing usage of their data in our research.

Study Design

This was a retrospective study of CI surgeries performed at our 3 tertiary referral hospitals through the national cochlear implant program during the period from April 2017 to August 2019.

Inclusion and Exclusion Criteria

We included 272 pediatric patients who underwent CI surgery through the PT approach. We only included those where both pre-operative HRCT scans (computerized and hard copy forms), as well as their unedited surgical video, were available. We excluded cases with previous ear surgeries, congenital cochleovestibular anomalies, preoperative facial nerve paralysis, cholesteatoma, other approaches for CI, or revision CI surgery.

CT Protocol

Radiological imaging was performed using an HRCT machine (Toshiba Ct Aquilion one 320 multi-slice). The temporal bone images were obtained with sub-millimeter slice thickness (0.7 mm). The CT scan data were acquired at 120 kVp, 200 mA, and the imaging matrix of 512 × 512. The axial and coronal images were obtained parallel to the orbito-meatal baseline and viewed in the standard bone window settings.

CT Reviewing

HRCT images were reviewed and judged by the senior CI surgeon and the senior radiologist who is sub-specialized in temporal bone radiology. Reviewing of each case was done by the 2 experts simultaneously with an agreement on the final decision of pre-operative radiological scoring to minimize the inter-observer variability.

The Scoring System

Our proposed score consists of 10 marks for 8 items (Table 1).

(1) Site of the Sigmoid Sinus (SS)

The position of the SS was evaluated in the axial plane by measuring the distance from the anterior edge of the sigmoid sinus to the posterior bony wall of the external auditory canal (Figure 1)

Table 1. The Proposed Score

N	Item	Variations	Score
1	Site of the sigmoid sinus	Normal	0
		Anterior displaced	1
2	Site of the tegmen	Normal	0
		Low	1
3	Koerner septum	No	0
		Present	1
4	Opacification of middle ear cleft	No	0
		Present	1
5	Pneumatization of the mastoid	Reasonable pneumatization	0
		Poor pneumatization	1
6	location of the facial nerve	Normal	0
		Compromised	2
7	Width of the PT	Reasonable wide	0
		Narrow	1
8	Presence of Sentinel cell in the facial recess	Yes	0
		No	2
Score of maximum difficulty			10

- If the distance was > 9 mm, this meant a good position of SS and was marked 0 in the score.
- If the distance was < 9 mm, this meant an anteriorly displaced position of the SS and was marked 1.

(2) Site of the Tegmen

The level of the Tegmen was evaluated in the coronal plane by measuring the distance between the line that tangent the lowest point of the temporal lobe in the mastoid and the line that tangent the upper edge of the petrous bone (Figure 2)

- If the distance less was than 7 mm, this meant the good position of the tegmen and was marked 0 in the score.
- If the distance was more than 7 mm, this meant a low position of the tegmen and was scored 1.

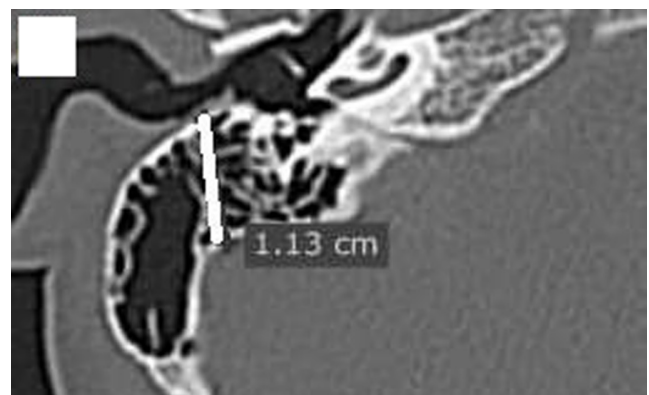


Figure 1. Axial cut of right temporal bone HRCT, showing the distance (11.3 mm) between the anterior edge of the sigmoid sinus and the posterior wall of the EAC, indicating the normal position of the sigmoid sinus (it was scored 0 marks). HRCT, high-resolution CT scan.

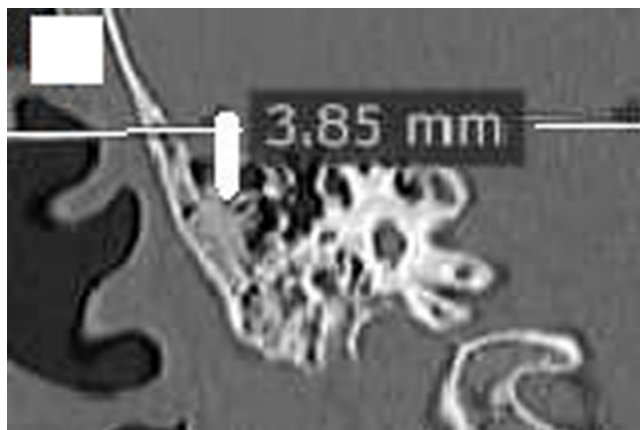


Figure 2. Coronal cut of right temporal HRCT, showing the vertical distance (3.85 mm) between the lower edge of the temporal lobe in the mastoid, and a line passing through the upper edge of the petrous bone, indicating a good position of the Tegmen (it was scored 0 marks). HRCT, high-resolution CT scan.

(3) Presence of Koerner Septum

We evaluated the presence of the Koerner septum in the axial plane (Figure 3)

- Absent: this was marked 0.
- Present: this was given 1.

(4) Opacification of the Middle Ear Cleft

We evaluated the opacification of the middle ear cleft in the axial plane (Figure 4)

- Not opacified: this was marked 0.
- Opacified: this was given 1.

(5) Pneumatization of the Mastoid

We evaluated the pneumatization of the mastoid in the axial plane in relation to an imaginary line that passed through the maximum anterior bulge of the sigmoid sinus (Figure 5)

- If the pneumatization extended medial to that line, this meant reasonable pneumatization of the mastoid and was marked 0.
- If the pneumatization was limited to that line, this was regarded as poor pneumatization of the mastoid and was given 1.

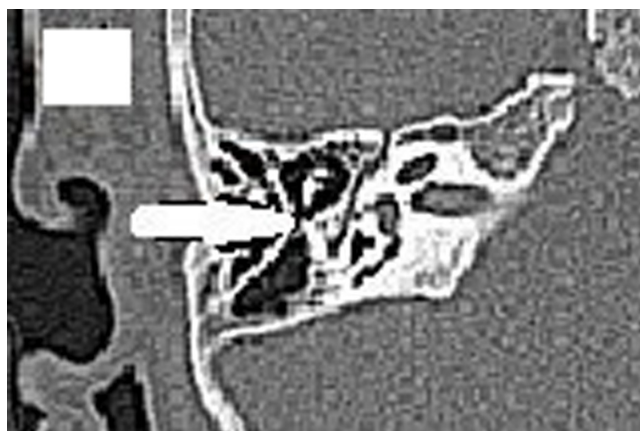


Figure 3. An axial cut of the right temporal bone HRCT, showing Koerner septum (it was scored 1 mark). HRCT, high-resolution CT scan.

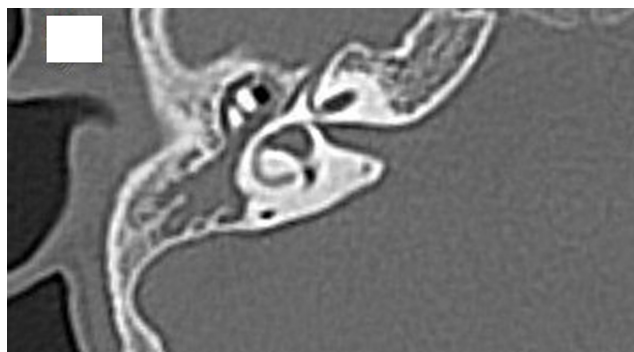

Figure 4. An axial cut of right temporal bone HRCT, showing opacification of the middle ear cleft (it was scored 1 mark). HRCT, high-resolution CT scan.

(6) Location of the Facial Nerve (FN)

This was evaluated in the coronal plane by drawing 2 vertical lines, 1 was tangential to the most lateral part of the bony LSCC, while the other was tangential to the most lateral aspect of the mastoid segment of the FN (Figure 6).

- If the 2 lines were at the same level or the FN line was medial to the LSCC line, this meant a good position of the facial nerve and was marked 0.
- If the facial nerve line was lateral to the LSCC line, this was regarded as a compromised location of the FN and was given 2.

(7) Width of the PT

This was evaluated in the axial plane by measuring the perpendicular distance between the antero-lateral aspect of the mastoid segment of the FN and the bony annulus of the posterior wall of the EAC (Figure 7).

- If the distance was 4 mm or more, this was regarded as a reasonable width of the PT and was marked 0.
- If the distance was less than 4mm, this meant narrow PT and was given 1.

(8) Presence of Sentinel Air Cells in the Facial Recess

This was evaluated in the axial plane by the presence of air cells around the mastoid segment of the FN (Figure 8)

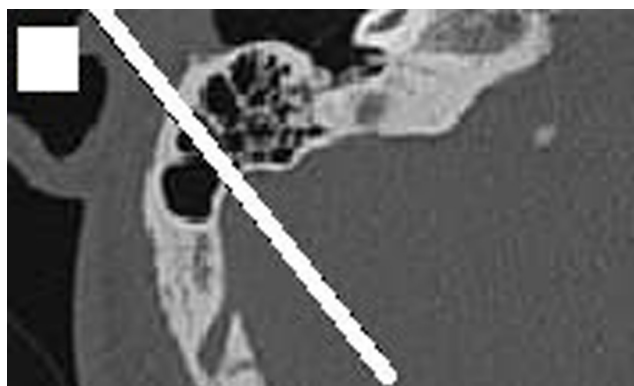


Figure 5. An axial cut of the right temporal bone HRCT, showing reasonable pneumatization of the mastoid as the air cells extend beyond the line passing through the anterior bulge of the sigmoid sinus (it was scored 0 marks). HRCT, high-resolution CT scan.

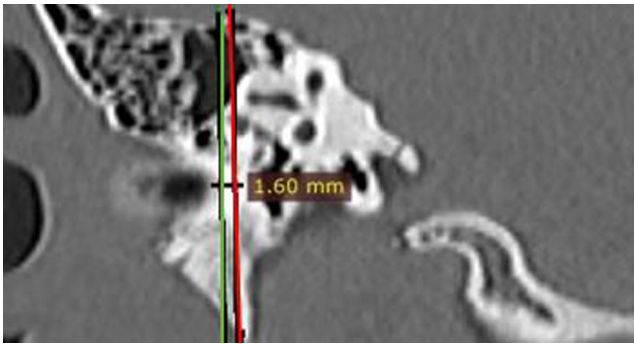


Figure 6. A coronal cut of right temporal bone HRCT, the right red vertical line passes through the lateral bony aspect of the LSCC, while the left green line passes through the lateral aspect of the mastoid segment of the facial nerve, indicating the lateral displacement of the facial nerve (it was scored 2 marks). HRCT, high-resolution CT scan.

- If present: this was marked 0.
- If absent: this was given 2.

After evaluating the scores by the 2 experts, we collected the marks to get the final score whose maximum limit was 10 marks and the minimum was 0 marks.

We considered radiological scoring of 5 or more as suggestive of difficult surgery as opposed to scoring less than 5 which was regarded as suggestive of a straightforward surgery.

Surgical Observation

Two senior CI surgeons who were blinded to the aforementioned HRCT scoring results, reviewed and judged the unedited surgical video of each patient focusing on the surgical steps including cortical mastoidectomy and PT from the start of mastoid drilling till reaching complete PT. Complete PT was defined as (Figure 9):

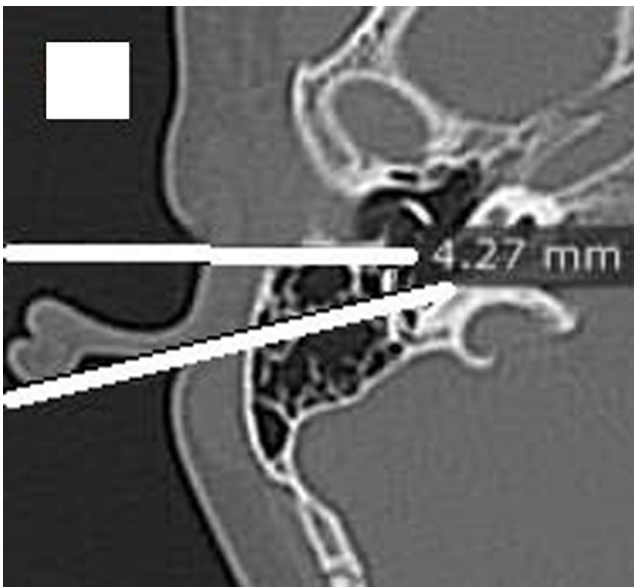

Figure 7. An axial cut of right temporal bone HRCT, showing the distance between the anterolateral surface of the mastoid segment of the facial nerve and the bony annulus of the posterior wall of the EAC (posterior tympanotomy width), was 4.27 which meant wide PT (it was scored 0 marks). HRCT, high-resolution CT scan.

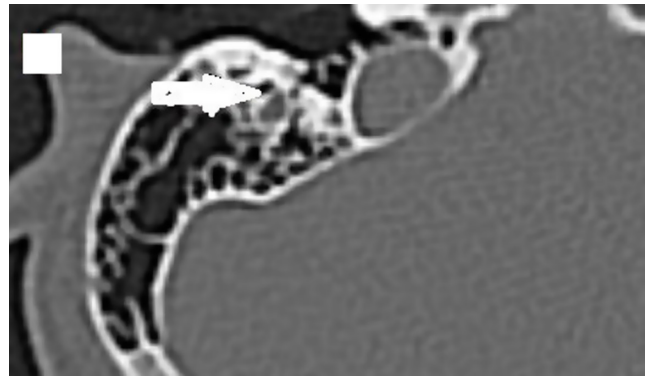


Figure 8. An axial cut of right temporal bone HRCT showing the presence of the Sentinel air cell around the facial recess (it was scored 0 marks). HRCT, high-resolution CT scan.

- Complete removal of the bone lateral to the FN.
- Complete skeletonization of the FN leaving a small incudal buttress.
- Complete skeletonization of Chorda tympani nerve till reaching its take-off point from FN.
- Clear visualization of the stapedial tendon.

This unedited surgical video review was done simultaneously by 2 senior CI surgeons who were asked to agree about the answer to a very specific question after watching the unedited video: was the surgery difficult or a straightforward one by ticking a box. Straightforward meant the usual expected surgical steps, while difficult surgery was regarded otherwise. This is to avoid intra as well as inter-observer variability.

The surgical time on the unedited surgical video was calculated from the start of mastoidectomy till reaching complete PT by using a stopwatch for every CI recipient.

Statistical Analysis

Statistical analysis was done using SPSS v25 (IBM© Inc., Chicago, IL, USA). The normality of data was checked with the Shapiro-Wilks test. Numerical variables with normal distribution were presented as mean and standard deviation (SD). Numerical variables with abnormal distribution were presented as median and range. Categorical variables were presented as frequency and percentage (%). Spearman correlation was done between the score and other variables. Stepwise multivariate logistic regression analysis was done to show the independent predictors of difficult surgery.

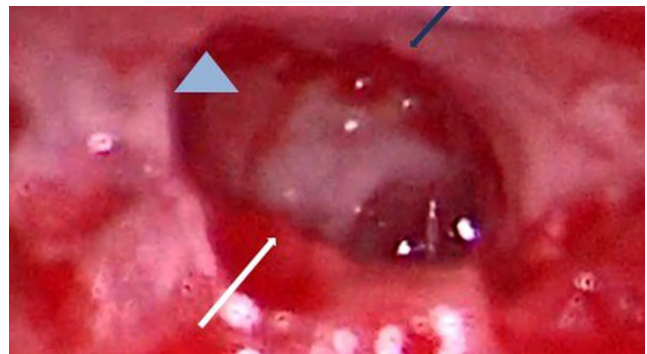

Figure 9. Right complete posterior tympanotomy, white arrow points to the mastoid segment of the facial nerve, the blue arrow refers to the chorda tympani nerve and the pale blue arrowhead is directed to the stapedial tendon.

Table 2. The Results of Different Score Items in Our Cohort

Site of the sigmoid sinus	Normal	176 (64.7%)
	Anterior displaced	96 (35.3%)
Site of the dura	Normal	202 (74.3%)
	Low	70 (25.7%)
Koerner septum	No	128(47.1%)
	Present	144 (52.9%)
Opacification of middle ear cleft	No	190 (69.9%)
	Present	82 (30.1%)
Pneumatization of the mastoid	Reasonable pneumatization	142(52.2%)
	Poor pneumatization	130 (47.8%)
Lateral displacement of the facial nerve	No	248 (91.18%)
	Yes	24 (8.82%)
Width of PT	Wide	154 (56.6%)
	Narrow	118 (43.4%)
Presence of Sentinel cell in facial recess	Yes	172 (63.24%)
	No	100 (36.76%)

P value < .05 was considered significant. Sample size calculation was done by G*Power 3.1.9.2 (Univesitat Kiel, Germany), with an 80% power, 5% confidence limit. The expected area under the curve (AUC) of the receiver operating characteristic curve was at least 0.7 and the null hypothesis was 0.5, so at least 228 patients should be included in this study.

RESULTS

In our study, we reviewed the pre-operative HRCT and the unedited surgical videos of 272 patients who underwent CI surgery. We implanted 244 patients (89.7%) on the right side and 28 patients (10.3%) were implanted on the left side. All of them had prelingual severe to profound sensorineural hearing loss and did not benefit from a trial of hearing aid for at least 6 months. The age ranged from 2.1 years to 7.1 years old with the mean \pm SD was 4.29 ± 1.18 years. They were 174 males (63.97%) and 98 females (36.03%).

According to the evaluation of the pre-operative HRCT, the sigmoid sinus was in normal position in 176 (64.7%) cases, while it was anteriorly displaced in 96 (35.3%) cases. The tegmen was in normal position in 202 (74.3%) cases, and was in a low position in 70 (25.7%) cases. Koerner septum was present in 144 (52.9%) cases and absent in 128(47.1%) cases. Middle ear cleft was opacified in 82 (30.1%) cases. The mastoid was reasonably pneumatized in 142(52.2%) cases, and was poorly pneumatized in 130 (47.8%) cases. The FN was lateralized in 24 (8.82%) cases. The PT was reasonably wide in 154 (56.6%) cases and it was regarded as narrow in 118 (43.4%) cases. The Sentinel air cells were present in the facial recess in 172 (63.24%) cases and were absent in 100 (36.76%) cases. The final score in our cohort ranged

Table 3. Correlation Between the Score of Surgical Difficulty and Other Parameters

		Age	Sex	Difficulty of Surgery	Duration of Surgery
Score	R	−0.054	0.024	0.771	0.908
	P value	.533	.777	<.001*	<.001*

from zero to 8 marks and the median was 3 marks (Table 3). According to the intraoperative difficulty evaluation, the surgery was regarded as straightforward in 178 (65.44%) cases, and was considered as difficult in 94 (34.56%) cases (Table 2).

The duration needed to complete PT ranged from 14 to 72 minutes with the mean \pm SD was 34.99 ± 16.92 min. The duration of what is considered as a straightforward surgery ranged from 14 to 41 min with the mean \pm SD was 24.13 ± 6.63 min, while the duration of what is regarded as difficult surgery ranged from 38 to 72 min with the mean \pm SD was 55.55 ± 9.82 min. This was statistically significant (P value <.001). The score had a significant correlation with the difficulty of surgery and its duration (P value <.001) (Table 3).

At cut-off 5 or more of the score, the sensitivity was 80.85%, specificity was 92.13%, positive predictive value was 84.4%, negative predictive value was 90.1%, the AUC was 0.963, and P value <.001 (Figure 10). The absence of Sentinel cell in facial recess was the strongest independent predictor of surgical difficulty with a P value = .002 (Table 4).

DISCUSSION

Cortical mastoidectomy and PT are 2 surgical key steps during routine CI surgery. Many anatomical variations and pathology have been shown to affect these surgical steps which may imply difficulty during the operation.^{1,2}

HRCT is the standard radiological modality to detect the bony anatomical variants which may predict the difficulty during surgery.^{10,11}

Previous studies have shown a relationship between intraoperative difficulty and certain CT findings. Park et al.¹² concluded that mastoidectomy difficulty was related to the level of pneumatization of the mastoid and the tegmen level, and not related to the sigmoid sinus level. It also concluded that aeration around the facial recess was associated with easy PT. Nevertheless, their study was mainly on the adult group population (mean age 58), in addition to its small sample size (only 57 patients). Its method to detect aeration of the mastoid was not clear, and the methods to detect Sigmoid Sinus and the tegmen levels were complex.¹² In addition, It did not focus on chronic otitis media with effusion which is common in the pediatric population and results in new bone formation making

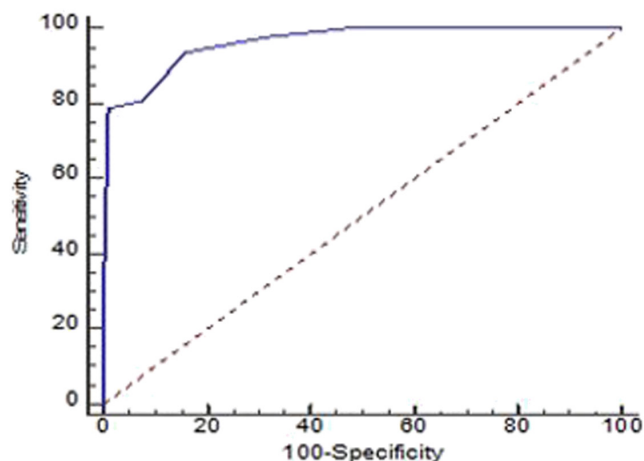
**Figure 10.** ROC curve of the score of maximum difficulty for prediction of difficult surgeries.

Table 4. Diagnostic Accuracy of Score of Maximum Difficulty for Prediction of Difficult Surgery

Variable	Coefficient	Standard Error	Wald	P Value	Odds Ratio (95% CIs)
Absence of sentinel cell in the facial recess	2.95	0.959	9.47	.002*	19.1 (2.9-125.3)
Constant	-2.14	0.748	8.20	.004*	

the mastoid and facial recess sclerotic thus increases the difficulty level.¹³ Park et al.¹² also ignored the FN position which is an essential landmark during CI surgery. These shortfalls had more or less coincided with M. Sarafraz et al. study.¹⁴

Mandour et al.¹⁵ study concluded that the level of surgical difficulty was related to the contracted mastoid and the anteriorly displaced sigmoid sinus. Its conclusion about the aeration around the facial recess coincided with Park et al. However, its sample size was small (47 patients) and its method to detect sigmoid sinus level was a relatively complex one. It did not include other factors which might affect the surgical difficulty like chronic otitis media and Koerner septum. Another study was done by Elzayat et al.,¹⁶ it tried to detect difficulties during PT without involving the cortical mastoidectomy or middle ear opacification.

Our work was based on the aforementioned studies, avoiding its associated pitfalls, involving most of the factors which might affect the surgical difficulty.

During our pre-operative attempt to evaluate the radiological scoring, we tried as much as we can to use simple valid radiological features as using Pereira et al. maneuvers to evaluate the site of the sigmoid sinus and the level of tegmen.¹⁷ We simplified the maneuver of Han et al. to evaluate the pneumatization of the mastoid process by choosing only the main central line.¹⁸ Regarding the site of the FN in the facial recess, we detected its lateralization by using Telmesani et al. maneuver.¹⁹ We also included the presence of opacification of middle ear cleft which may suggest Otitis Media with Effusion. The latter may have an impact on the surgical difficulty as it may predispose to the sclerotic mastoid and facial recess. In addition, it may increase bleeding intraoperatively and possibly FN surgical complications. Koerner septum was added due to its impact on the identification of the antrum.²⁰

During the evaluation of the intra-operative difficulty, we objectively looked at the length of the operative time as well.

According to our study, the absence of Sentinel air cell around the facial recess was the strongest independent predictor of the intraoperative difficulty which coincided with Park et al., and Mandour et al. results.^{12,15}

CONCLUSION

This proposed radiological scoring system is a simple reliable method to predict the difficulty which we may encounter during CI surgery. Scoring 5 or more had predicted intraoperative difficulty as opposed to less scoring which had predicted a straightforward surgery.

Ethics Committee Approval: The research was approved by the ethics committee of the involved universities following Helsinki protocol.

Informed Consent: Written informed consent was obtained from the patients who participated in this study.

Peer-review: Externally peer-reviewed.

Author Contributions: Concept – S.E., A.M.; Design – S.E., A.M.; Supervision – S.E.; Literature Search – H.E., R.L.; Writing – M.M.; Critical Reviews – S.E., A.M.

Conflict of Interest: The authors declare no conflicts of interest or any financial issues to be disclosed.

Financial Disclosure: The authors declared that this study has received no financial support.

REFERENCES

1. El-Anwar MW, ElAassar AS, Foad YA. Non-mastoidectomy cochlear implant approaches: a literature review. *Int Arch Otorhinolaryngol*. 2016;20(2):180-184. [\[CrossRef\]](#)
2. Hanafi MG, Saki N, Bahmani S. Investigating the effect of cochlear size in insertion of electrode depth in patients with cochlear implantation evaluated by CT-scan. *Int J Pediatr*. 2019;7:9207-9213.
3. Weber PC. Iatrogenic complications from chronic ear surgery. *Otolaryngol Clin N Am*. 2005;38(4):711-722. [\[CrossRef\]](#)
4. Lee DH, Kim JK, Seo JH, Lee BJ. Anatomic limitations of posterior tympanotomy: what is the major radiologic determinant for the view field through posterior tympanotomy? *J Craniofac Surg*. 2012;23(3):817-820. [\[CrossRef\]](#)
5. Jako GJ. The posterior route to the middle ear: posterior tympanotomy. *Laryngoscope*. 1967;77(3):306-316. [\[CrossRef\]](#)
6. Sun DI, Lee DH, Jang KH, et al. A suggested new classification system for the anatomic variations of the sigmoid sinus: a preliminary study. *Int Adv Otol*. 2009;5:1-5.
7. Calli C, Pinar E, Oncel S, Tatar B, Tuncbilek MA. Measurements of the facial recess anatomy: implications for sparing the facial nerve and chorda tympani during posterior tympanotomy. *Ear Nose Throat J*. 2010;89(10):490-494.
8. Green JD, Shelton C, Brackmann DE. Iatrogenic facial nerve injury during otologic surgery. *Laryngoscope*. 1994;104(8 Pt 1):922-926. [\[CrossRef\]](#)
9. Echternach M, Maurer CA, Mencke T, et al. Laryngeal complications after thyroidectomy: is it always the surgeon? *Arch Surg*. 2009;144(2):149-153; discussion 153. [\[CrossRef\]](#)
10. Cohen D, Blinder G, Perez R, Raveh D. Standardized computed tomographic imaging and dimensions of the round-window niche. *Int Tinnitus J*. 2005;11(2):158-162.
11. Bettman RH, Van Olphen AF, Zonneveld FW, Huizing EH. Preoperative imaging protocol for cochlear implant candidates. *Acta Otolaryngol*. 2004;124(9):1028-1032. [\[CrossRef\]](#)
12. Park E, Amoodi H, Kuthubutheen J, et al. Predictors of round window accessibility for adult cochlear implantation based on pre-operative CT scan: a prospective observational study. *J Otolaryngol Head Neck Surg*. 2015;44:20. [\[CrossRef\]](#)
13. Luntz M, Teszler CB, Shpak T, Feiglin H, Farah-Sima'an A. Cochlear implantation in healthy and otitis-prone children: a prospective study. *Laryngoscope*. 2001;111(9):1614-1618. [\[CrossRef\]](#)
14. Sarafraz M, Heidari M, Bayat A, et al. Role of HRCT imaging in predicting the visibility of Round window (RW) on patients underwent cochlear

- implant surgery. *Clin Epidemiol Glob Health*. 2020;8(2):432-436. [\[CrossRef\]](#)
15. Mandour MF, Tomoum MF, El Zayat S, Hamad H, Amer MH. Surgeon oriented preoperative radiologic evaluation in cochlear implantation – our experience with a proposed checklist. *Int Arch Otorhinolaryngol*. 2019;23(2):137-141. [\[CrossRef\]](#)
 16. Elzayat S, Mandour MF, Lotfi R. The role of preoperative computerized tomography in a safe posterior tympanotomy for cochlear implant surgery. *Egypt J Otolaryngol*. 2017;33(3):569-572. [\[CrossRef\]](#)
 17. Pereira AR, Júnior PSD, Vieira de Castro JD, et al. Mastoidectomy: anatomical parameters x surgical difficulty. *Int Arch Otorhinolaryngol*. 2012;16(01):57-61.
 18. Han SJ, Song MH, Kim J, Lee WS, Lee HK. Classification of temporal bone pneumatization based on sigmoid sinus using computed tomography. *Clin Radiol*. 2007;62(11):1110-1118. [\[CrossRef\]](#)
 19. Telmesani LM, Alrammah MK. Telmesani radiological classification of the location of the vertical segment of the facial nerve: impact on surgical approach in cochlear implants surgery. *Otol Neurotol*. 2017;38(9):e335-e338. [\[CrossRef\]](#)
 20. Karaca CT, Toros SZ, Noseri HK. Analysis of anatomic variations in temporal bone by radiology. *Int Adv Otol*. 2012;8:239-243.