

Case Report

Behavioral Therapy for Muscular Objective Tinnitus in Forceful Eyelid Closure Syndrome (FECS): A Case Report

Nobumichi Maeyama¹ , Takefumi Kamakura^{1,2} , Masato Nishimura³ , Kayoko Kawashima⁴ ,
Chisako Masumura¹ , Toshimichi Yasui¹ 

¹Department of Otorhinolaryngology, Otemae Hospital, Otemae, Chuo-ku, Osaka, Japan

²Department of Otorhinolaryngology-Head and Neck Surgery, Osaka University Graduate School of Medicine, Yamadaoka, Suita, Osaka, Japan

³Nishimura ENT Clinic, Tanimachi, Chuo-ku, Osaka, Japan

⁴Department of Otorhinolaryngology, Osaka Prefectural Hospital Organization, Osaka Habikino Medical Center, Habikino, Osaka, Japan

ORCID IDs of the authors: N.M. 0000-0003-0336-948X; T.K. 0000-0002-6491-443X; M.N. 0000-0003-3090-7706; K.K. 0000-0002-6236-8367; C.M. 0000-0001-9397-5613; T.Y. 0000-0002-1943-5157

Cite this article as: Maeyama N, Kamakura T, Nishimura M, Kawashima K, Masumura C, Yasui T. Behavioral therapy for muscular objective tinnitus in forceful eyelid closure syndrome (fecs): A case report. *J Int Adv Otol*. 2021;17(3):278-280.

This report presents the case of a patient with forceful eyelid closure syndrome (FECS) who did not have an otologic history of facial paresis. The patient was an 11-year-old girl. She complained of a click noise in the left ear simultaneous with eyelid closure and was referred to our department. A microphone in the external auditory canal captured a click noise simultaneously with eye blinking. Impedance audiometry of the left ear showed a slight compliance reduction simultaneously with eye blinking, whereas a pure-tone audiogram, tympanogram, computed tomography (CT), magnetic resonance imaging (MRI), and movement of the palate and pharynx were normal. Her previous otologic history was unremarkable and did not include facial paresis. She was diagnosed with FECS due to contraction of the tensor tympanic muscle.

Treatment with an anticonvulsant for 2 months showed no effects on her tinnitus and she was bothered by her drowsiness and dizziness. Behavioral therapy (BT) was started, and the tinnitus was remarkably reduced in 7 months. BT for patients with muscular tinnitus, including FECS, may be a preferred choice rather than surgical procedure and medication including an anticonvulsant and muscle relaxant.

KEYWORDS: Objective tinnitus, forceful eyelid closure syndrome, behavioral therapy

INTRODUCTION

Tinnitus is classified into 2 major groups. One originates from the sensorineural auditory system, and the other from parauditory structures such as myogenic or vascular sources, or the middle ear muscles.¹ The tensor tympani muscle, one of the middle ear muscles, may cause objective tinnitus.² Objective tinnitus due to dysfunction of the middle ear muscle is very rare, whereas sensorineural tinnitus is common.³⁻⁷

Forceful eyelid closure syndrome (FECS), which represents objective tinnitus, has been reported in the Proceedings of the Second International Tinnitus Seminar in 1983.¹⁻⁹ The symptoms of FECS include a muscular tinnitus related to forced eyelid closure.⁴ FECS is very rare and has been reported to be usually seen in pediatric patients.⁴ Although there are several previous reports concerning FECS, there are very few descriptions concerning behavioral therapy (BT) for FECS to date. A patient who experienced muscular tinnitus of FECS was treated with BT in the current report, and an effective favorable outcome was obtained. Details of clinical history, examination, and treatment of the current case are presented herein.

CASE PRESENTATION

An 11-year-old girl visited an ENT clinic complaining of a click noise in the left ear, which occurred only when she blinked. She could not concentrate on studying due to the noise, and was referred to our department. On examination, it was found that the auricles

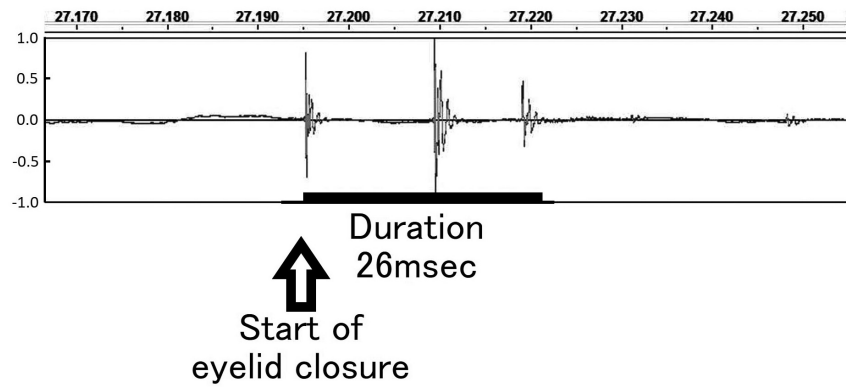


Figure 1. Acoustic waveform of a click noise in the current case, captured by a microphone in the left external auditory canal. The waveform showed 3 spiking shapes in 1 eyelid closure in 26 ms.

and external auditory canals were normal bilaterally. The movement of the palate and pharynx was normal. Although the right tympanic membrane was normal, the left tympanic membrane was remarkably retracted simultaneously with eyelid closure. Computed tomography (CT) and magnetic resonance imaging (MRI) of the middle and inner ear were unremarkable. A pure-tone audiogram was bilaterally normal. A tympanogram was bilaterally A-type. Impedance audiometry of the left ear showed a slight reduction in compliance, simultaneously with eye blinking. As shown in Figure 1, a microphone in the left external auditory canal simultaneously captured a click noise with eye blinking and retraction of the tympanic membrane. A frequency spectrum showed that the peaks of the frequencies were observed around 1 and 3 kHz (Figure 2). Her previous otologic history was unremarkable and did not include facial paresis. She was stressed due to her studies. She was diagnosed with objective tinnitus due to FECS, and the plausible cause was thought to be the tensor tympanic muscle rather than the stapedius muscle, because retraction of the tympanic membrane was remarkable compared to the slight reduction in compliance in impedance audiometry. She was prescribed an anticonvulsant for 2 months, which had no effect on her tinnitus, and she was bothered by drowsiness and dizziness. She stopped the medication and started BT. BT was provided as shown in Figure 3. It was postulated that when a signal of eye blinking or eyelid closure was sent through the facial nerve, an abnormal cross-talk of the signal between the facial and trigeminal nerves induced contraction of the tensor tympanic muscle. This was hypothesized to generate muscular tinnitus, which induces more stress and anxiety, and reduces concentration. BT was provided with an aim to relieve

her from overconcentration and stress on tinnitus, reassure her to lessen her stress and anxiety against tinnitus, and achieve avoidance of voluntary eye closure (Figure 3).

One month after BT initiation, the tinnitus became was remarkably decreased when blinking but showed no changes when the eyelids were strongly closed. The Visual Analog Scale (VAS) score was reduced from 74 to 22. Six months after BT initiation, the tinnitus had almost disappeared, and the microphone in the left ear could not capture the noise. The BT and observation were then ended. The final VAS score was 10.

DISCUSSION

Forceful eyelid closure syndrome (FECS)

FECS is very rare, and only a few cases have been reported since 1983.¹⁻⁹ In previous reports, more than half of the affected patients were under 20 years old,^{4,9} and approximately two-thirds were female.⁹ In some patients with synkinesis after facial paresis, stapedial muscle contraction due to facial spasm has been known to induce muscular tinnitus.^{1,10} However, no FECS patients with a history of facial paresis have been reported,^{1-4,7,9} and no history of facial

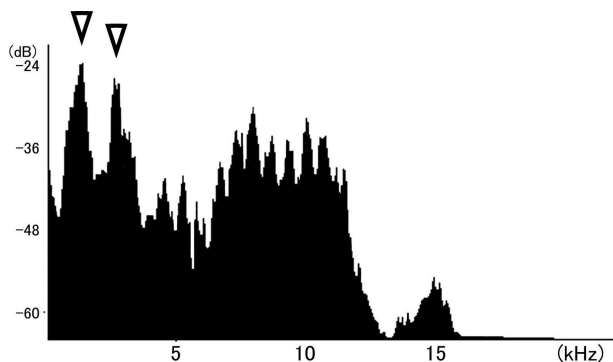


Figure 2. Frequency spectrum of a click noise in the current case, captured by a microphone in the left external auditory canal. The peaks of the frequencies were observed around 1 and 3 kHz (arrowheads).

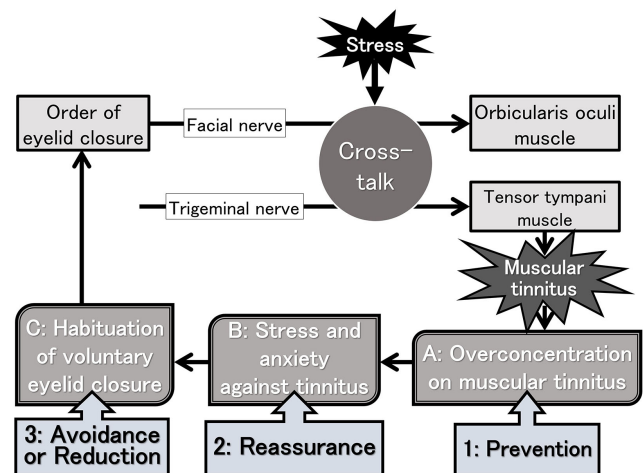


Figure 3. Estimated tinnitus-worsening mechanism and BT in the current case. The points of tinnitus-worsening mechanisms are (A) Overconcentration on muscular tinnitus, (B) Stress and anxiety against tinnitus, and (C) Habituation of voluntary eyelid closure. The points of BT are (1) Prevention of overconcentration on tinnitus, (2) Reassurance to lessen her stress and anxiety against tinnitus, and (3) Avoidance or reduction of voluntary eye closure.

paresis was included in the current case. FECS has been hypothesized to be due to an abnormal crosstalk between the facial nerve and trigeminal nerve.^{2,4,9} The tensor tympanic and/or stapedius muscles are involved in objective tinnitus in the FECS.^{2,4,9} Palatal myoclonus may also induce objective tinnitus,^{1,9} and Kaffenberger et al.⁹ reported that the involvement of the tensor veli palatini muscle was hypothesized in a patient diagnosed with FECS. The tensor tympani and tensor veli palatini muscles are innervated by the mandibular branch of the trigeminal nerve, and the orbicularis oculi and stapedius muscle by the facial nerve.^{2,4,9}

Some children with FECS have been reported to have stress factors that might cause FECS,⁴ and the current case also involved stress. Such stress factors might influence young neural plasticity, and forceful eyelid closure was suggested to induce an abnormal crosstalk between the facial nerve and the trigeminal nerve.⁴ Consequently, objective tinnitus might occur simultaneously with eyelid closure.

Treatment for FECS

Medications such as muscle relaxants and/or anticonvulsants have often been used to treat FECS.⁹ Although these medicines have been effective in some patients with FECS in previous reports,^{4,9} an anticonvulsant showed no effect in the current case. An anticonvulsant sometimes induces side effects such as drowsiness and dizziness, which were also observed in the current case.

Lee et al.⁴ introduced BT to treat FECS, and demonstrated its efficacy. The mechanism by which the tinnitus worsens, and the strategy to solve this problem using BT, have been carefully considered in the current case (Figure 3), and we intervened in voluntary eyelid closure and overconcentration on tinnitus and told her to refrain from tinnitus-worsening behaviors. These interventions using BT were suggested to avoid the behaviors and consequently reduce objective tinnitus in the current case, without side effects. Together with the previous report published by Lee et al.,⁴ BT is suggested to be an effective treatment, especially for young patients with FECS, and should be the first line of treatment followed by medications such as muscle relaxants and anticonvulsants.

Kaffenberger et al.⁹ reported that intra-palatal botulinum toxin injection was effective for a patient with FECS. In the case, the tensor veli palatini muscle was thought to be involved in objective tinnitus.⁹ Watanabe et al.¹⁰ reported that resection of the middle ear tendon was effective in patients with tinnitus due to the stapedial muscle, for those who were resistant to medication. Lee et al.⁴ included surgical resection in their treatment algorithm for FECS. As indicated in previous studies,^{1,4} middle ear tendon resection is preferable as the final treatment option for patients who do not respond to conservative treatments such as medication and BT.

CONCLUSION

A patient with FECS without an otologic history of facial paresis has been presented herein. Tinnitus has been remarkably reduced by BT,

which aims to prevent tinnitus-worsening behaviors. Although medications including an anticonvulsant and/or surgical resection of the middle ear muscle are often prescribed to treat patients with muscular tinnitus including FECS, BT may be a preferred treatment rather than the others, with less side effects and lower invasion.

Informed Consent: Informed consent has been obtained from the patient and her family.

Peer Review: Externally peer-reviewed.

Author Contributions: Concept – N.M., T.K.; Design – N.M., T.K.; Supervision – M.N., K.K., C.M., T.Y.; Materials – N.M., K.K.; Data Collection and/or Processing – N.M., K.K.; Analysis and/or Interpretation – N.M., M.N., T.K.; Literature Review – N.M., T.K., T.Y.; Writing – N.M., T.K.; Critical Review – N.M., T.K., M.N., K.K., C.M., T.Y.

Acknowledgments: The authors would like to thank Editage (www.editage.com) for English language editing.

Conflict of Interest: The authors have no conflicts of interest to declare.

Financial Disclosure: The authors declared that this study has received no financial support.

REFERENCES

- Ohki M, Kato H. Idiopathic tinnitus concomitant with eye closure. *Otol Neurotol*. 2012;33(2):267-269. [CrossRef]
- Rock EH. Objective tinnitus and the tensor tympani muscle. *Int Tinnitus J*. 1995;1(1):30-37. (PMID:[CrossRef])
- Rajah V. Tinnitus related to eyelid blinking. *J Laryngol Otol*. 1992;106(1):44-45. [CrossRef]
- Lee GH, Bae SC, Jin SG et al. Middle ear myoclonus associated with forced eyelid closure in children: diagnosis and treatment outcome. *Laryngoscope*. 2012;122(9):2071-2075. [CrossRef]
- Kim BG, Bang MY, Kim DH, Moon IS. Tinnitus related to eyelid blinking. *Auris Nasus Larynx*. 2013;40(5):518-520. [CrossRef]
- Park SN, Bae SC, Lee GH et al. Clinical characteristics and therapeutic response of objective tinnitus due to middle ear myoclonus: a large case series. *Laryngoscope*. 2013;123(10):2516-2520. [CrossRef]
- Kim TH, Jang HJ, Park SH, Nam SI. Objective tinnitus concomitant with eye blinking: a case report. *J Audiol Otol*. 2015;19(2):101-103. [CrossRef]
- Rock E. Forceful eyelid closure syndrome. In: Shulman A, ed. *Proceedings of the Second International Tinnitus Seminar*. New York; 1983:165-169.
- Kaffenberger TM, Mandal R, Schaitkin BM, Hirsch BE. Palatal botulinum toxin as a novel therapy for objective tinnitus in forced eyelid closure syndrome. *Laryngoscope*. 2017;127(5):1199-1201. [CrossRef]
- Watanabe I, Kumagami H, Tsuda Y. Tinnitus due to abnormal contraction of stapedial muscle. an abnormal phenomenon in the course of facial nerve paralysis and its audiological significance. *ORL J Otorhinolaryngol Relat Spec*. 1974;36(4):217-226. [CrossRef]