

Review

Middle Ear Neuroendocrine Tumor: A Case Report and Review of the Literature in Pediatric Population

Mariapaola Guidi¹, Annamaria Buccoliero², Franco Trabalzini¹

¹Department of Otorhinolaryngology, Head and Neck Surgery, Meyer Children's Hospital, Florence, Italy

²Pathology Unit, Meyer Children's Hospital, Florence, Italy

ORCID IDs of the authors: M.G. 0000-0001-9751-8639; A.B. 0000-0003-0749-4229; F.T. 0000-0003-3207-1535

Cite this article as: Guidi M, Buccoliero A, Trabalzini F. Middle Ear Neuroendocrine Tumor: A Case Report and Review of the Literature in Pediatric Population. *J Int Adv Otol*. 2021; 17(2): 150-5.

A rare pediatric case report of middle ear neuroendocrine tumor and review of the pediatric cases reported in the literature. A 16-year-old female showed a lesion occupying the posterosuperior part of the medial third of the right external auditory canal confirmed by computed tomography scan, without clear evidence of bone erosion. The patient underwent canal wall tympanoplasty in 1 stage. No residual pathology was present after 1 month, 3-6 months, and after 1 year. There are few known pediatric cases of this disease, there is no statistically significant data for this population regarding the risk of recurrence or metastasis. Middle ear neuroendocrine tumors are rare above all in children. They are slow aggressive tumors but they can recur and rarely give local metastasis. Only 4 pediatric cases have been published. We have completely removed the tumor in our patient, using a conservative surgical treatment in a single stage.

KEYWORDS: Pediatric middle ear tumor, neuroendocrine tumor, canal wall up tympanoplasty

INTRODUCTION

Middle ear neuroendocrine tumors represent <2% of primary ear tumors in the adult population and they are extremely rare in pediatric patients.^{1,2}

In the middle ear cavity, typical presenting symptoms of this type of tumor are hearing loss, aural fullness, and tinnitus. Physical examination may reveal a mass behind the tympanic membrane. The imaging and histologic characteristics of these tumors can mimic those of paragangliomas.^{3,4}

These tumors show dual endocrine and exocrine differentiation: since 1976 many classifications have been proposed.^{1,3,5-8} Since 2017 there has been the tendency to call all middle ear tumors middle ear adenomas.¹ Despite being considered slow aggressive tumors, these neoplasms can recur (up to 4%) and give local metastasis.^{1,2,9}

computed tomography (CT) and magnetic resonance imaging (MRI) techniques are useful but only by combining histopathology and immunohistochemistry is it possible to define the correct diagnosis.^{5,10-12}

In this paper, we discuss a rare pediatric case report of middle ear neuroendocrine tumor and review the pediatric cases reported in the literature.

METHODS

The clinical presentation and histopathological features of the middle ear neuroendocrine tumor were discussed. The literature was reviewed to further characterize this pathology and to assess management strategies.

A literature review in PubMed was conducted using the search terms middle ear tumor in combination with a neuroendocrine tumor in children. A total of 4 reports were found and the abstracts were evaluated.

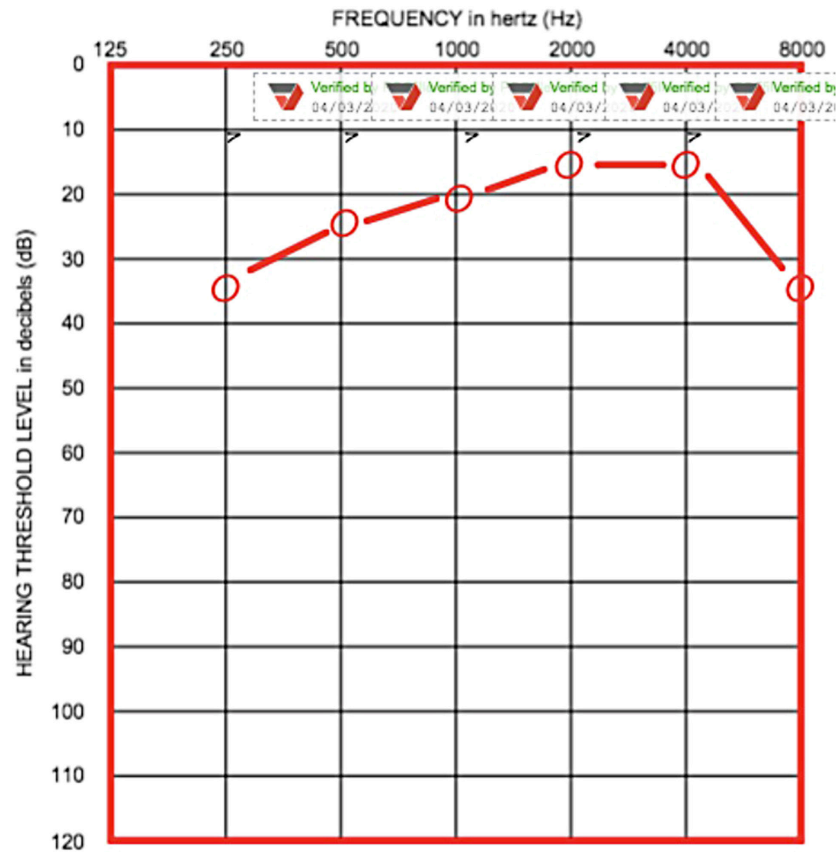


Figure 1. Right side: pre-operative tonal audiometry.

Case

A female patient, 16 years old, was referred to our department due to mild conductive hearing loss and aural fullness on the right side for at least 1 year; no otalgia, tinnitus, vertigo, otorrhea, or other related symptoms were present. The patient did not refer to a history of recurrent otitis nor familiarity with ear disease. Her grandfather was marrow transplanted for acute myeloid leukemia in November 2016.

A micro-otoscopic evaluation revealed a lesion occupying the posterosuperior part of the medial third of the right external auditory canal. The mass was not pulsating and covered by normal skin. The only accessible inferior half of the tympanic membrane was normal at otoscopy. Pure tone audiometry showed a mild conductive hearing loss on the right side at low frequencies (Figure 1) and tympanometry was shifted to negative values (type C).

The high-resolution CT of the temporal bone revealed a mass in the middle ear and mastoid cavity on the right side, extended to the external auditory canal without clear evidence of bone erosion.

MAIN POINTS

- Middle ear neuroendocrine tumors rarely occur in children.
- Very few cases are reported in the literature.
- Due to a rather high recurrence rate, the recommended treatment is total resection with the conservative surgical approach.

The patient underwent canal wall-up mastoidectomy with tympanoplasty. A retroauricular approach was performed and the lesion was exposed. The mass completely involved the ossicular chain and was extended medial to it. The stapes were completely embedded in the mass. Complete eradication of the disease was achieved microscopically after incus removal. Ossiculoplasty was performed with autologous incus and autologous concha cartilage over it. Miringoplasty with underlay technique was carried out with autologous temporal muscle fascia graft.

Postoperatively the patient complained of mild unsteadiness, which resolved spontaneously after a few days.

The removed mass appeared well capsulated, with stretch-elastic consistency, and grayish-white in color.

Histological examination showed a neuroendocrine tumor of the middle ear (Figure 2A–D).

The tumor was composed of cells with plasmocytoid aspects organized in trabecular patterns, solid areas mixed with glandular regions. An immunohistochemical evaluation revealed positivity for AE1/AE3, synaptophysin, NSECD56, chromogranin, and S-100 and negativity for neurofilament, desiminin, and actin 1A4, HHf35, and CD99. The cell mitotic activity was not significant and the cell growth rate evaluated with the immunohistochemical technique was 4%.

The surgical specimen (multiple fragments measuring about $1 \times 0.5 \times 0.3$ cm) was routinely fixed in neutral buffered formol and

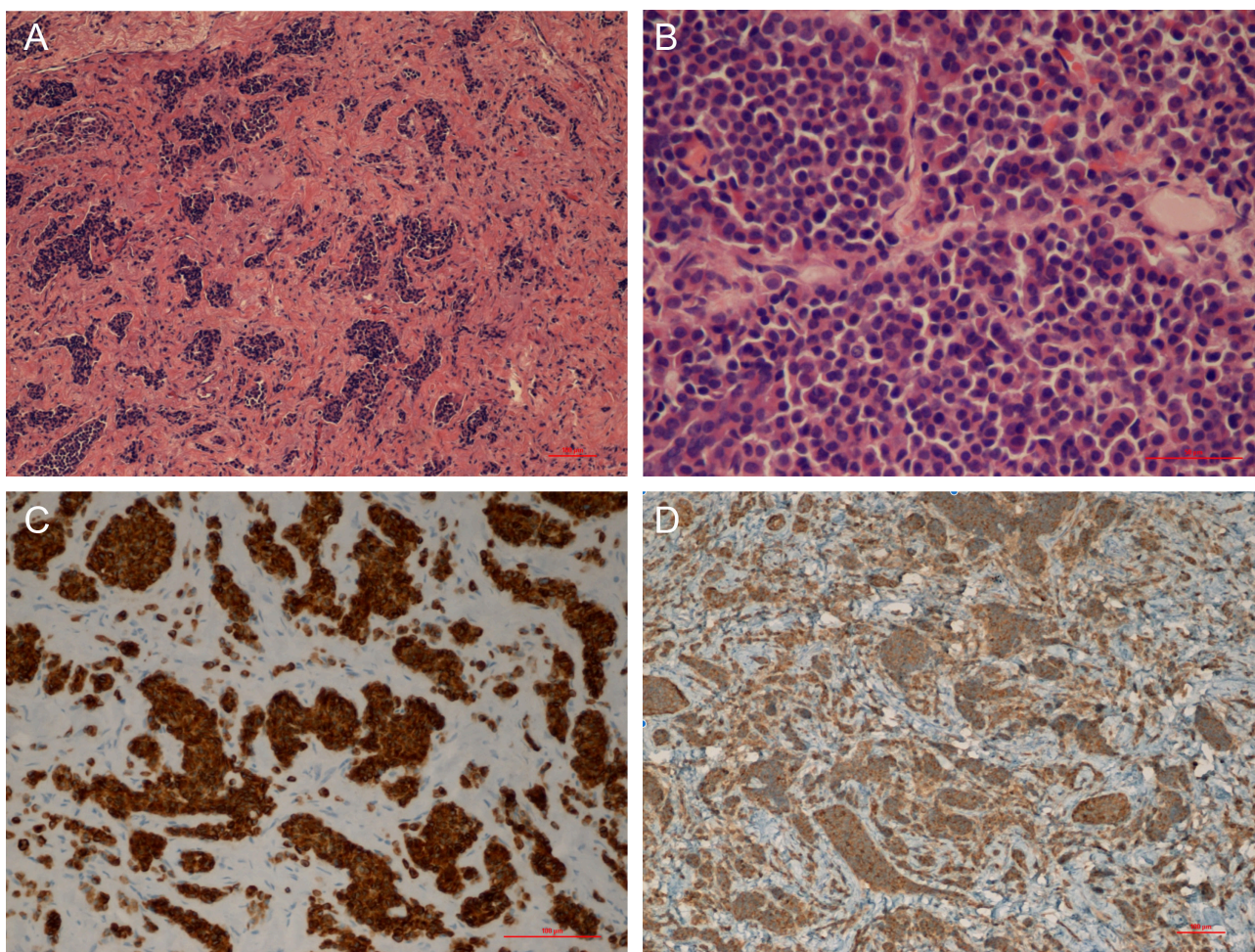


Figure 2. A. Plasmocytoid cells organized in trabeculae, glandular like structures and solid areas focally distributed within a fibrotic background; Original magnification: A: X10 o 10X. B. Plasmocytoid cells organized in trabeculae, glandular like structures and solid areas focally distributed within a fibrotic background; Original magnification: B: 40X. C. Positive AE1/AE3. Original magnification: 20X. D. Positive synaptophysin. Original magnification: 10X.

paraffin embedded. Five-micrometer sections were stained with hematoxylin and eosin, whereas additional sections were mounted on electrostatic slides and used for immunohistochemical studies using the standard streptavidin-biotin technique and commercially available antibodies.

On microscopic examination, the lesion was composed of plasmocytoid cells organized in trabeculae, glandular-like structures and solid areas focally distributed within a fibrotic background (Figures 2A, 2B).

The neoplastic cells demonstrated positive immunostaining for AE1/AE3 (Figure 2C), synaptophysin (Figure 2D), NSE, CD56, chromogranin and S-100, and negativity for neurofilament, desimin, actins (1A4, HHF35), and CD99. The proliferative index, determined by estimating the percentage of the Ki-67-positive neoplastic cells in the total of the tumor cells, was about 4%.

Morphologic features along with immunohistochemical results were consistent with the diagnosis of a neuroendocrine tumor of the middle ear. The detailed histology of all cases reported in the literature is shown in Table 1.

The post-operative tonal audiometry is reported below (Figure 3).

The patient was evaluated microscopically after 1 month, after 3-6 months, and after 1 year. No residual pathology was present.

In the literature, 4 cases of neuroendocrine tumor of the middle ear in pediatric age (<18 years old) have been published. The first case, in 1988, concerned a 16-year-old boy, in 2006 a 16-year-old boy, in 2009 a 13-year-old boy, and in 2017 the patient was a 15-year-old girl with the diagnosis of unilateral middle ear neuroendocrine tumor. All these patients presented unilateral mild conductive hearing loss as the main symptom. Three of them showed a history of chronic otitis media during early childhood.¹⁶⁻¹⁸ All published cases were studied and a summery of which is shown in Table 2.

DISCUSSION

Saliba and Evrard, in 2009, classified the middle ear glandular tumor into 3 types: neuroendocrine adenoma with positive immunohistochemical markers and negative metastases (type I), middle ear adenoma with negative immunohistochemical markers and negative metastases (type II), and carcinoid tumor with positive immunohistochemical markers and metastases (type III).⁶ All these tumors were named as adenomas with neuroendocrine features by the World Health Organization's (WHO) 2017 report.⁷

Table 1. All Cases Reported in Literature with detailed histology

Study	Histology
Kambayashi et al. 1988	<ul style="list-style-type: none"> - Alcian blue and PAS-positive mucin was seen in lumen of the glandular structure. - Most of the tumor cells had argyrophilic granules in the cytoplasm. Argentaffin reaction was negative. - Most of the cells reacted to chromogranin and glicetin. Stain for serotonin and methionine-enkephalin was focally positive.
Jiang et al. 2006	<ul style="list-style-type: none"> - Trabecular and glandular profiles of cells with uniform nuclei and speckled chromatin. - Stains were positive for pancytokeratin and synaptophysin, with focal positivity for chromogranin.
Dogru et al. 2009	<ul style="list-style-type: none"> - Positive for S-100, synaptophysin (Figure 4), pankeratin antibody (Figure 5), and chromogranin staining. - A neuron-specific enolase stain was negative.
Sterreri et al. 2017	<ul style="list-style-type: none"> - Strong positivity for synaptophysin and negativity for chromogranin. - CD56 showed moderate to strong positivity and Ki-67 strong positivity in occasional cells.

The average age of tumor presentation is 50 years.¹³ The most frequent symptom is unilateral conductive hearing loss, followed by ear fullness, tinnitus, dizziness, otorrhea, otalgia, and facial nerve palsy. Otoscopic evaluation rarely reveals perforation of the tympanic membrane with extension into the external auditory canal.^{3,5,13}

CT shows an avascular soft tissue density without bone erosion while MRI is indicated if there is an extension to the posterior fossa.^{12,15}

In none of the cases reported in literature (Table 1) octreotide scintigraphy or neuroendocrinological exams have been requested after surgery. In only 1 case octreotide scan was performed to confirm recurrence in a radical cavity but when the ear was evaluated microscopically the radical cavity was re-epithelialized without any doubt of recurrence.¹⁷

In the literature, the risk of recurrence is reported without distinction between pediatric and adult populations, as associated with the type of surgical treatment used; a radical intervention seems to be correlated with less chance of recurrence. The overall recurrence rate is 22%, 9% of patients present regional metastases with the involvement of cervical lymph nodes or parotid gland.^{3,17}

A proper microscopic evaluation of the ear seems to be more sensible and accurate than radiological images to diagnose recurrence or residual middle ear neuroendocrine tumor.¹⁷ The use of scintigraphy with octreotide is indicated in metastatic disease and long-term observation is necessary because of the late presentation of recurrence and metastasis.³

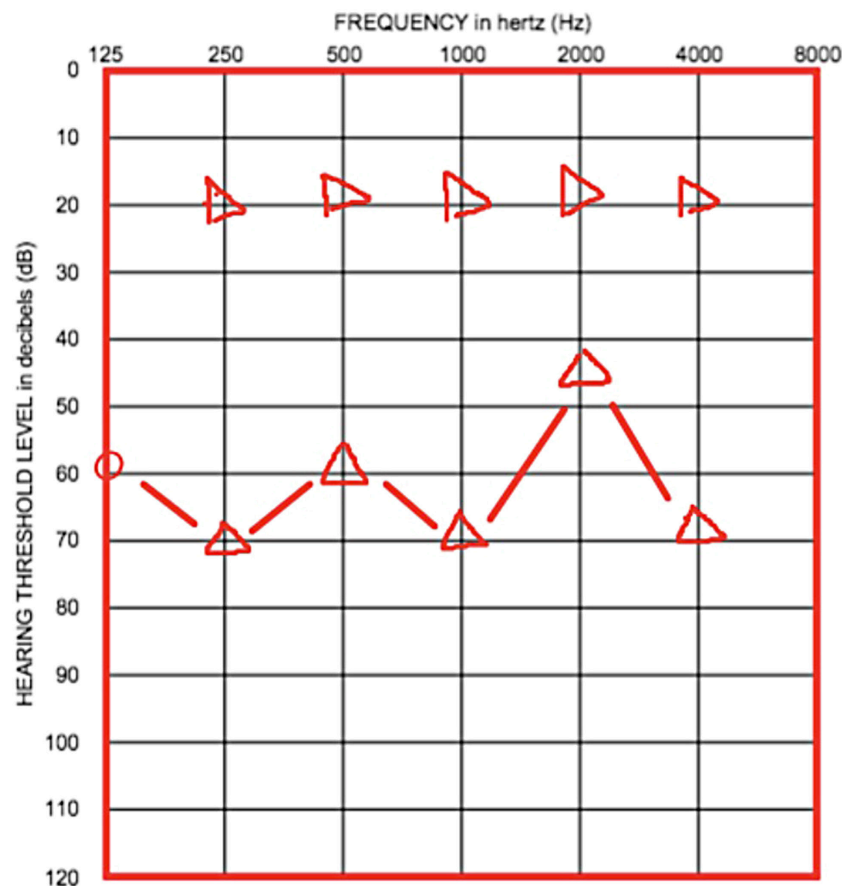
**Figure 3.** Right side: post-operative tonal audiometry.

Table 2. Summary of Case Reports

Study	Age (years)	Sex	Otoscopic Evaluation	Symptoms	Side	Strategy
Kambayashi et al. 1988	16	M	Grayish-white swelling	mild conductive HL	LEFT	- Tympanotomy - Radical mastoidectomy
Jiang et al. 2006	16	M	Slowly enlarging mass	mild conductive HL	LEFT	Canal wall up tympanoplasty
Dogru et al. 2009	13	M	- COM with effusion and TM attic perforation. - Posterior-superior white mass.	mild conductive HL Otorrhea, tinnitus, aural fullness.	LEFT	- Biopsy and myringoplasty - Tympanotomy - Canal wall up tympanoplasty
Sterrer et al. 2017	15	F	Bulging of posterior superior TM.	mild conductive HL Tympanogram flat.	RIGHT	Atticoantrotomymastoidectomy + surgical revision

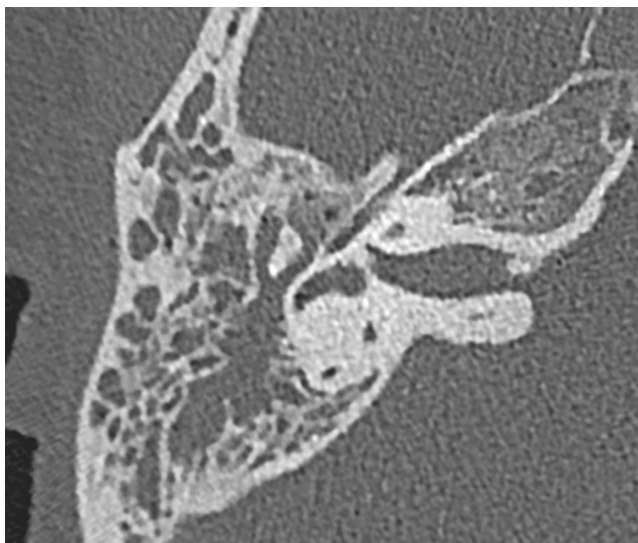
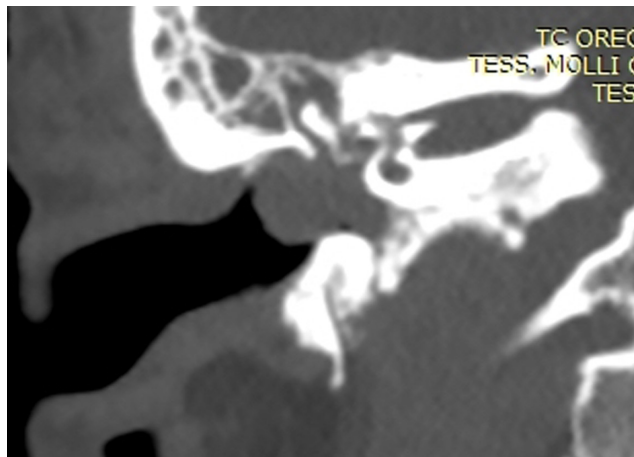
M, male; F, female. COM, chronic otitis media; TM, tympanic membrane.

Due to a rather high recurrence rate, a total resection is recommended. In case of recurrent disease, a more aggressive treatment is indicated such as extensive temporal bone surgery.^{2,19,20}

The case report presented in this paper could be classified as middle ear neuroendocrine tumor type I, in accordance with the Saliba classification (2009), but on the basis of the WHO guidelines of 2017, it is simply an ear adenoma with neuroendocrine features. In fact, to our knowledge, this case is the first presented after unification under the term of middle ear adenoma (2017). Other possible diseases that could be confused with neuroendocrine tumor were discussed in other studies and excluded for our case based on histological evaluation; immunohistochemical evaluation was positive for synaptophysin, chromogranin, and S-100.^{1,2}

Scintigraphy with octreotide was not performed because metastasis was not suspected. In 2017, Hou et al. presented the results of biodistribution analysis and dosimetry calculations for children who received ^{99m}Tc-HYNIC-TOC injections for the diagnosis of neuroendocrine tumors. They showed that absorbed doses in children were higher than those in adults, while no significant correlation was found between the children's doses and their ages.²¹

Unlike other cases reported in literature, our patient did not show any history of recurrent chronic otitis media.

**Figure 4.** Right Ear: CT scan axial view.**Figure 5.** Right Ear: CT scan coronal view.

The 2 pediatric cases reported in the literature subjected to canal wall-up tympanoplasty (2009 and 2016) showed recurrence after 1 year and 15 months, respectively. In the other case, published in 2006, data about follow-up were not reported, while in the 1988 case no recurrence after 3 years from a radical mastoidectomy was observed.

According to the literature, the recommended treatment for ear neuroendocrine tumors is total resection with a conservative surgical approach, as in our case report.^{2,19,20}

CONCLUSION

Middle ear neuroendocrine tumor is extremely rare in a pediatric population. Apart from the case presented here, only 4 pediatric cases have been published. Three of them underwent multiple surgeries before removing the disease completely.

We have completely removed the tumor in our patient, using a conservative surgical treatment in a single stage; at 1-year follow-up, no evidence of recurrence or local metastasis or residual disease in middle ear cleft or mastoid was found.

As there are few known pediatric cases of this disease, there is no statistically significant data for this population regarding the risk of recurrence or metastasis. Therefore, additional cases and studies on the pediatric population are mandatory in order to determine the best treatment for these patients.

Peer-review: Externally peer-reviewed.

Author Contributions: Concept – M.G., F.T.; Design – M.G.; Supervision – F.T.; Resource – M.G., A.B.; Materials – M.G., A.B.; Data Collection and/or Processing – M.G., A.B.; Analysis and/or Interpretation – M.G., A.B., F.T.; Literature Search – M.G.; Writing – M.G., A.B.; Critical Reviews – F.T.

Conflict of Interest: The authors have no conflict of interest to declare.

Financial Disclosure: The authors declared that this study has received no financial support.

REFERENCES

1. Katabi N. Neuroendocrine neoplasm of the ear. *Head Neck Pathol.* 2018;12(3):362-366. [\[CrossRef\]](#)
2. Dogru S, Wilkinson EP, Robinson RA, Smith RJ. Middle ear adenoma with neuroendocrine differentiation (MEA-ND) in the pediatric population. *Int J Pediatr Otorhinolaryngol.* 2009;73(6):895-898. [\[CrossRef\]](#)
3. Ramsey MJ, Nadol JB, Pilch BZ, McKenna MJ. Carcinoid tumor of the middle ear: clinical features, recurrences and metastases. *Laryngoscope.* 2005;115(9):1660-1666. [\[CrossRef\]](#)
4. Khanna G, O'Dorisio SM, Menda Y, et al. Gastroenteropancreatic neuroendocrine tumors in children and young adults. *Pediatr Radiol.* 2008;38(3):251-259, quiz 358. [\[CrossRef\]](#)
5. Torske KR, Thompson LD. Adenoma versus carcinoid tumor of the middle ear: a study of 48 cases and review of the literature. *Mod Pathol.* 2002;15(5):543-555. [\[CrossRef\]](#)
6. Saliba I, Evrard AS. Middle ear glandular neoplasms: adenoma, carcinoma or adenoma with neuroendocrine differentiation: a case series. *Cases J.* 2009;2:6508. [\[CrossRef\]](#)
7. El Naggar AK, Chan JKC, Takata T, Sliotweg PJ. *WHO Classification of the Head and Neck Tumors.* IARC Press; 2017.
8. Marinelli JP, Cass SP, Mann SE, et al. Adenomatous neuroendocrine tumors of the middle ear: a multi-institutional investigation of 32 cases and development of a staging system. *Otol Neurotol.* 2018;39(8):e712-e721. [\[CrossRef\]](#)
9. Mills SE, Fechner RE. Middle ear adenoma. A cytologically uniform neoplasm displaying a variety of architectural patterns. *Am J Surg Pathol.* 1984;8(9):677-685.
10. Vilain J, Degols JC, Ledeghen S. Recurrent adenomatous neuroendocrine tumor of the middle ear: a diagnostic challenge. *Case Rep Otolaryngol.* 2018;8619434.
11. Zan E, Limb CJ, Koehler JF, Yousem DM. Middle ear adenoma: a challenging diagnosis. *Am J Neuroradiol.* 2009;30(8):1602-1603. [\[CrossRef\]](#)
12. Cardoso FA, Monteiro EMR, Lopes LB, Avila MND, Scarioli BO. Adenomatous tumors of the middle ear: a literature review. *Int Arch Otorhinol.* 2017;21(3):308-312. [\[CrossRef\]](#)
13. Pelosi S, Koss S. Adenomatous tumors of the middle ear. *Otolaryngol Clin North Am.* 2015;48(2):305-315. [\[CrossRef\]](#)
14. Wenig B. *Atlas of Head and Neck Pathology.* 3rd ed. Amsterdam: Elsevier; 2016.
15. Bell D, El-Naggar AK, Gidley PW. Middle ear adenomatous neuroendocrine tumors: a 25 year experience at MD Anderson Cancer Center. *Virchows Arch.* 2017;471(5):667-672. [\[CrossRef\]](#)
16. Jiang W, Hill DA, Lieu JE. Pathology quiz case 1. Diagnosis: carcinoid tumor of the middle ear. *Arch Otolaryngol Head Neck Surg.* 2006;132(10):1156-1158.
17. Sterrer E, Windisch F, Frey K, Rettensteiner K, Loader B. Middle ear adenoma with neuroendocrine differentiation. A pediatric case report. *Wien Klin Wochenschr.* 2017;129(5-6):208-211. [\[CrossRef\]](#)
18. Kambayashi J, Ishidoya M, Urae T, et al. A case of carcinoid tumor of the middle ear producing peptide hormones. *Auris Nasus Larynx.* 1988;15(3):155-163. [\[CrossRef\]](#)
19. Devaney KO, Ferlito A, Rinaldo A. Epithelial tumours of the middle ear-are middle ear carcinoids really distinct from middle ear adenomas? *Acta Otolaryngol.* 2003;123(6):678-682. [\[CrossRef\]](#)
20. Manni JJ, Faverly DR, Van Haelst UJ. Primary carcinoid tumors of the middle ear. Report on four cases and a review of the literature. *Arch Otolaryngol Head Neck Surg.* 1992;118(12):1341-1347. [\[CrossRef\]](#)
21. Hou X, Birkenfeld B, Piwowarska-Bilska H, Celler A. Patient-specific dosimetry of ^{99m}Tc -HYNIC-Tyr³ – octreotide in children. *EJNMMI Phys.* 2017;4(1):24.