

## Review

# The Third Mobile Window Effects in Otology/Neurotology

**Ichiro Ota, Masaharu Sakagami, Tadashi Kitahara**

Department of Otolaryngology-Head and Neck Surgery, Nara Medical University, Kashihara City, Nara, Japan

Cite this article as: Ota I, Sakagami M, Kitahara T. The third mobile window effects in otology/neurotology. *J Int Adv Otol*. 2021; 17(2): 156–61.

It has been revealed that the pure-tone audiometry demonstrates large air-bone gaps at low pitches due to the presence of inner ear fistulae. When a third mobile window resulting from an inner ear fistula is present, in addition to the 2 normally present windows consisting of the oval window and the round window, a portion of the air-conducted waves escape from the scala vestibuli through the inner ear fistula. On the other hand, bone-conducted waves traveling to the scala vestibuli are reduced by an inner ear fistula; however, bone-conducted waves traveling to the scala tympani are not affected by an inner ear fistula. This results in a larger gap than usual in compliance between both perilymphatic spaces and leads to a decrease in the bone conduction threshold.

This phenomenon, so-called the third mobile window effects, sometimes may lead otology/neuro-otology surgeons to misunderstand the reason why large air-bone gaps still exist after ossicular reconstruction in tympanoplasty. This review article gives good examples regarding the third mobile window effects in otology/neuro-otology diseases and surgeries.

**KEYWORDS:** Otology, neurotology, inner ear, third mobile window, low-tone air-bone gaps

## INTRODUCTION

### The Third Mobile Window Effects and Theory

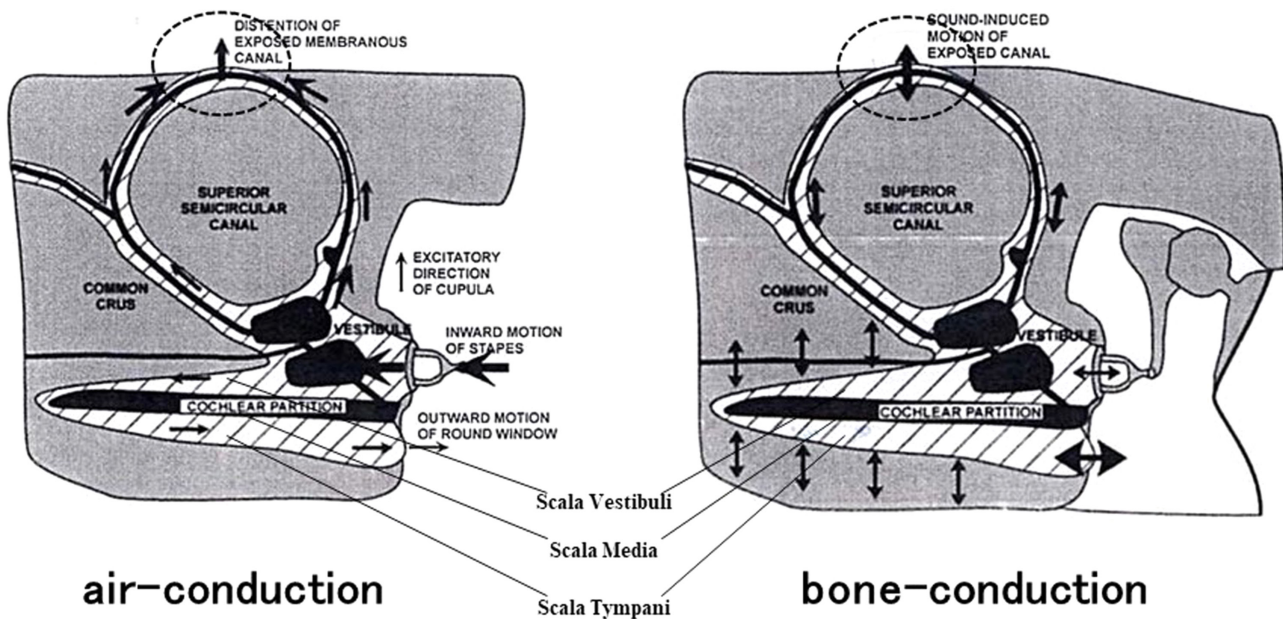
Recently, findings from pure-tone audiometry performed due to the presence of inner ear fistulae have been getting focused on, because they demonstrated that large air-bone gaps may occur at low pitches.<sup>1,2</sup> In 1980s, Bess et al. who described 3 such patients,<sup>3</sup> stated that House et al had observed at least ninety similar patients in their clinical practices.<sup>4</sup> Schuknecht speculated that the incidence of such “otologic mysteries” maybe 1 in 3000 procedures.<sup>5</sup> The air-bone gaps in these patients with unexplained conductive hearing loss are generally ascribed to putative lesions in the inner ear that are hypothesized to result in an “inner ear conductive hearing loss.”<sup>3–5</sup>

This phenomenon is referred to as the third mobile window effect and has been explained by the following hypothesis.<sup>1,2</sup> When a third mobile window resulting from an inner ear fistula is present, in addition to the 2 normally present windows consisting of the oval window and the round window, a portion of the air conducted waves escape from the scala vestibuli through the inner ear fistula. This leads to an increase in the air conduction threshold at low pitches, resulting in a stiffness curve. On the other hand, bone-conducted waves traveling to the scala vestibuli are reduced by an inner ear fistula; however, bone-conducted waves traveling to the scala tympani are not affected by an inner ear fistula. This results in a larger gap than usual in compliance between both perilymphatic spaces and leads to a decrease in the bone conduction threshold. Consequently, apparent large air-bone gaps are considered to occur at low pitches. Some of the studies, in which the hypothesis for the third mobile window effects has been proven, found acoustic changes when a fistula was created in the inner ear or the fistula was closed in the inner ear of small animals and cadavers.<sup>6</sup>

## THE THIRD MOBILE WINDOW EFFECTS

### The Third Mobile Window Effects in Otology/Neurotology Diseases

Superior canal dehiscence syndrome (Figure 1) and large vestibular aqueduct syndrome are common examples of diseases in which the third mobile window effects cause an air-bone gap at low pitches.<sup>7–9</sup> Superior canal dehiscence syndrome is a medical condition in which the superior semicircular canal protrudes anatomically into the middle cranium, and sudden decreases



**Figure 1.** Schematic representations of mechanism of air-bone gaps in superior canal dehiscence syndrome (modified from Ref.<sup>2</sup>). As for the air conduction, it is hypothesized that a third window in the superior semicircular canal allows a portion of the acoustic energy entering the vestibule through the motion of the stapes to be shunted away from the cochlea. The shunting occurs primarily at low frequencies, resulting in hearing loss by air conduction. As for the bone conduction, a third window increases the difference between the impedance on the scala vestibuli side and the scala tympani side of the cochlear partition by lowering the impedance on the vestibuli side, thereby improving the cochlear response to bone conduction. The mechanism of low-tone air-bone gaps in superior canal dehiscence syndrome is a combination of an increase in air conduction thresholds combined with an improvement in bone conduction thresholds.

in abdominal pressure and increases in cerebrospinal fluid pressure are transmitted through the dehiscence to cause dizziness and vertical nystagmus. The bone defect of the superior semicircular canal is thought to become the third mobile window. The mechanism of low-tone air-bone gaps in superior canal dehiscence syndrome is a combination of an increase in air conduction thresholds combined with an improvement in bone conduction thresholds. Merchant and Rosowski summarized multiple dehiscences of semicircular canals in their review paper.<sup>1,2</sup>

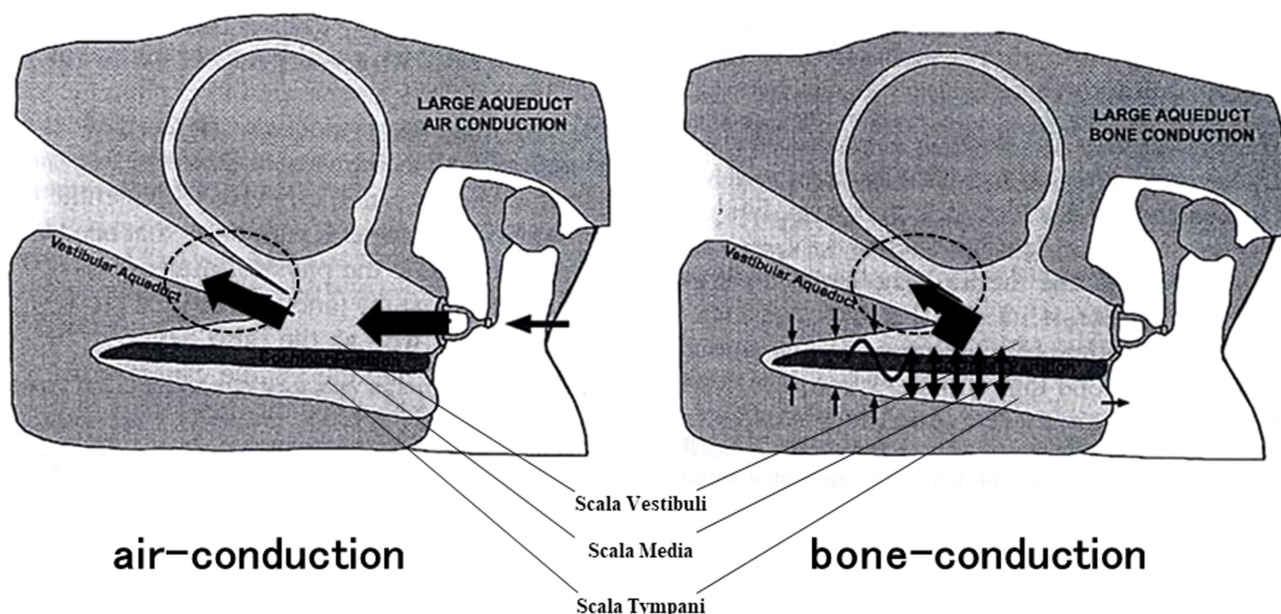
Large vestibular aqueduct syndrome (Figure 2) is a medical condition in which the vestibular aqueduct enlarges and hearing loss progresses following vertigo triggered by head injury or other

causes.<sup>10,11</sup> The enlarged vestibular aqueduct probably provides a pathologically large communication between the bony vestibule and the cranial cavity, resulting in an air-bone gap, similar to that observed in superior canal dehiscence syndrome. Therefore, no abnormality will be found in the tympanic cavity, even if exploratory tympanotomy is performed to investigate the conductive hearing loss of an unknown cause. Therefore, such cases require caution at the surgery.

A Harvard University group mentioned Paget's disease of the bone, in addition to the aforementioned medical conditions, as a disease that leads to third mobile window effects.<sup>2,12</sup> Paget's disease of the bone is a disease in which abnormal local bone remodeling causes changes in the bone microstructure, morphological enlargement, and deformity of the bone and is accompanied by decreased local bone strength. It is relatively common with a reported prevalence of 0.1%-5% in the United States and Europe. However, it is a rare disease in Japan, and there are few studies on hearing loss in Japanese cases of Paget's disease of the bone. The types of hearing loss can be diverse, ranging from conductive hearing loss caused by the deformed ossicular chain to sensorineural hearing loss caused by the inner ear becoming sponge-like, with mixed hearing loss in between. According to the Harvard University group, the presence of low-tone air-bone gaps derived from microfistulae in the inner ear cannot be ruled out. In fact, as shown in Figure 3, we experienced 2 patients who were sisters with Paget's disease of the bone and who presented with bilateral conductive hearing loss.<sup>13</sup> Both sides of both cases underwent tympanoplasty after long-term observation. Although their hearing showed a significant improvement postoperatively, the low-tone air-bone gap remained. It would be very interesting if this low-tone air-bone gap, which persisted after surgery, could be attributed to third mobile window effects.

## MAIN POINTS

- The third mobile window theory has been generally accepted to cause low-tone air-bone gaps. However, mechanisms in the theory has not been completely proven.
- In otology/neurotology diseases such as superior semicircular canal deficiency, enlarged vestibular aqueduct, Paget's disease of the bone and endolymphatic sac tumors, the third mobile window effects sometimes demonstrate low-tone air-bone gaps.
- In otology/neurotology surgeries such as BPPV occlusion surgery, endolymphatic sac drainage surgery and cholesteatoma fistula surgery, the third mobile window effects sometimes lead low-tone air-bone gaps after surgery.
- Physicians in otology/neurotology should always pay attention to the low-tone air-bone gaps due to the third mobile window effects. This phenomenon possibly gives us important information in the inner ear pathology and the surgical site condition.

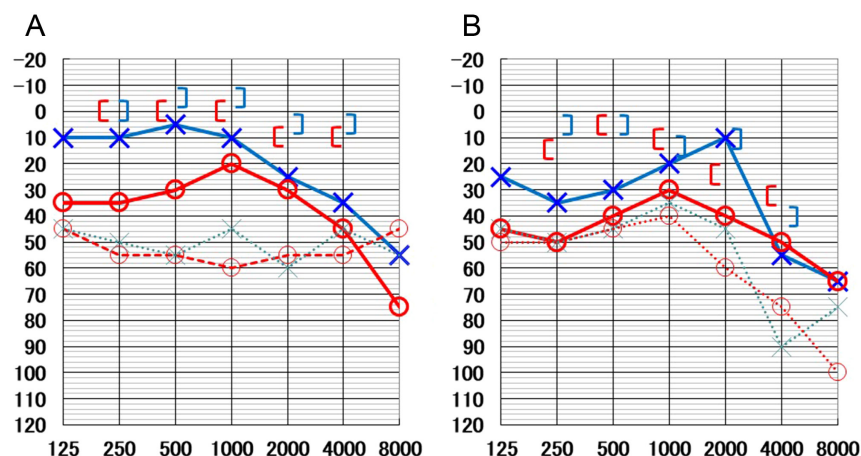


**Figure 2.** Schematic representations of the mechanism of air-bone gaps in enlarged vestibular aqueduct syndrome (modified from Ref.<sup>2</sup>). As for the air conduction, it is hypothesized that a third window in the enlarged vestibular aqueduct allows a portion of the acoustic energy entering the vestibule through the motion of the stapes to be shunted away from the cochlea. The shunting occurs primarily at low frequencies, resulting in hearing loss by air conduction. As for the bone conduction, a third window increases the difference between the impedance on the scala vestibuli side and the scala tympani side of the cochlear partition by lowering the impedance on the vestibuli side, thereby improving the cochlear response to bone conduction. The enlarged vestibular aqueduct probably provides a pathologically large communication between the bony vestibule and the cranial cavity, resulting in an air-bone gap, similar to that observed in superior canal dehiscence syndrome.

We have also seen 2 other cases with endolymphatic sac tumors.<sup>14</sup> One patient had a papillary adenoma on histopathology and the other had an inflammatory granulation pseudotumor. When the duration of the disease is prolonged, the tumor pressure promotes thinning of the posterior semicircular canal bone, which sometimes develops the third mobile window even if a tumor is benign on histopathology. The diagnosis of Meniere's disease is based on 3 symptoms, tinnitus, loss of hearing, and vertigo; however, an endolymphatic sac tumor should be suspected if an unexplained low-tone air-bone gap is found.<sup>14,15</sup> If the tumor is found to be malignant on histopathology, direct invasion into the inner ear causes obvious sensorineural hearing loss.

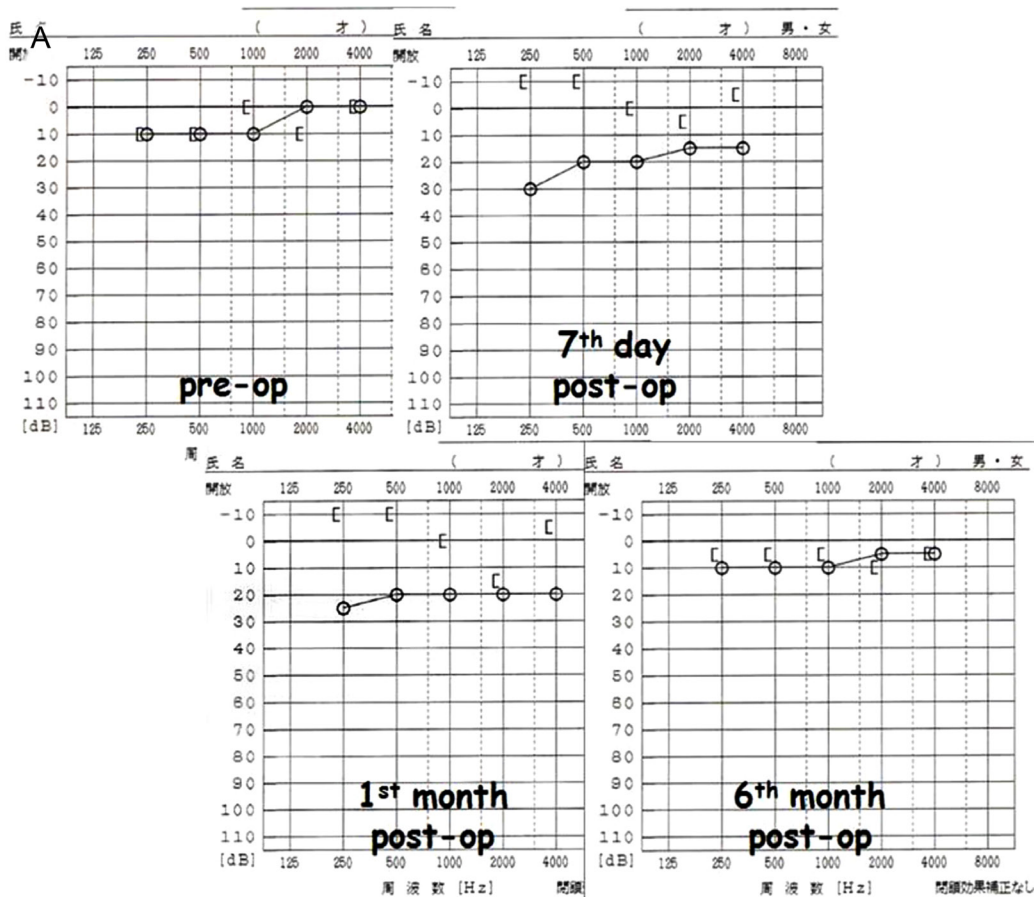
### Third Mobile Window Effects in Otology/Neurotology Surgeries

We recently reported that large air-bone gaps occur at low pitches after canal occlusion surgery for intractable benign paroxysmal positional vertigo (BPPV)<sup>16</sup> and endolymphatic sac drainage surgery for intractable Meniere's disease.<sup>17</sup> Canal occlusion surgery is a treatment for BPPV in which a semicircular canal fistula is surgically created and then filled with bone putty and fascia.<sup>18</sup> The low-tone air-bone gap occurs immediately after surgery and resolves over several months (Figure 4).<sup>16</sup> This suggests that low-tone air-bone gaps represent unstable occlusions and that an occluded site of the semicircular canal functions as the third mobile window.



**Figure 3.** Pure tone audiograms in 2 cases with Paget's disease of the bone (modified from Ref.<sup>13</sup>). Two patients with Paget's disease who were sisters of the bone demonstrated bilateral conductive hearing loss. Both sides of both cases underwent ossiculoplasty, Wullstein type-IVc. Although their hearing showed a significant improvement postoperatively, the low-tone air-bone gap remained. It would be very interesting, if this low-tone air-bone gap could be attributed to third mobile window effects. A, A younger sister; B, A older sister; ○, right ear; ×, left ear; dotted line, before surgery; solid line, 6 months after surgery; bone conductive hearing levels, 6 months after surgery.





**Figure 4.** A case with the posterior type of BPPV showing transient low-tone air-bone gaps after canal plugging surgery (modified from Ref.<sup>16</sup>). (A) A case with the posterior type of BPPV (pBPPV) had transient low-tone air-bone gaps (ABGs) in the right ear just for 1 month after canal occlusion surgery (7<sup>th</sup> day and 1<sup>st</sup> month post-op). There were no ABGs anymore 6 months after surgery (6<sup>th</sup> month post-op). (B) CT scan showed no remarkable findings in the right tympano-mastoid cavity around the posterior semicircular canal and fixed materials of connective tissues and bone tips there (an arrow) 1 month after surgery (1<sup>st</sup> month post-op).

We discussed the fact that this is similar to the third mobile window effects of superior canal dehiscence syndrome in the first half of the previous section.<sup>7-9</sup>

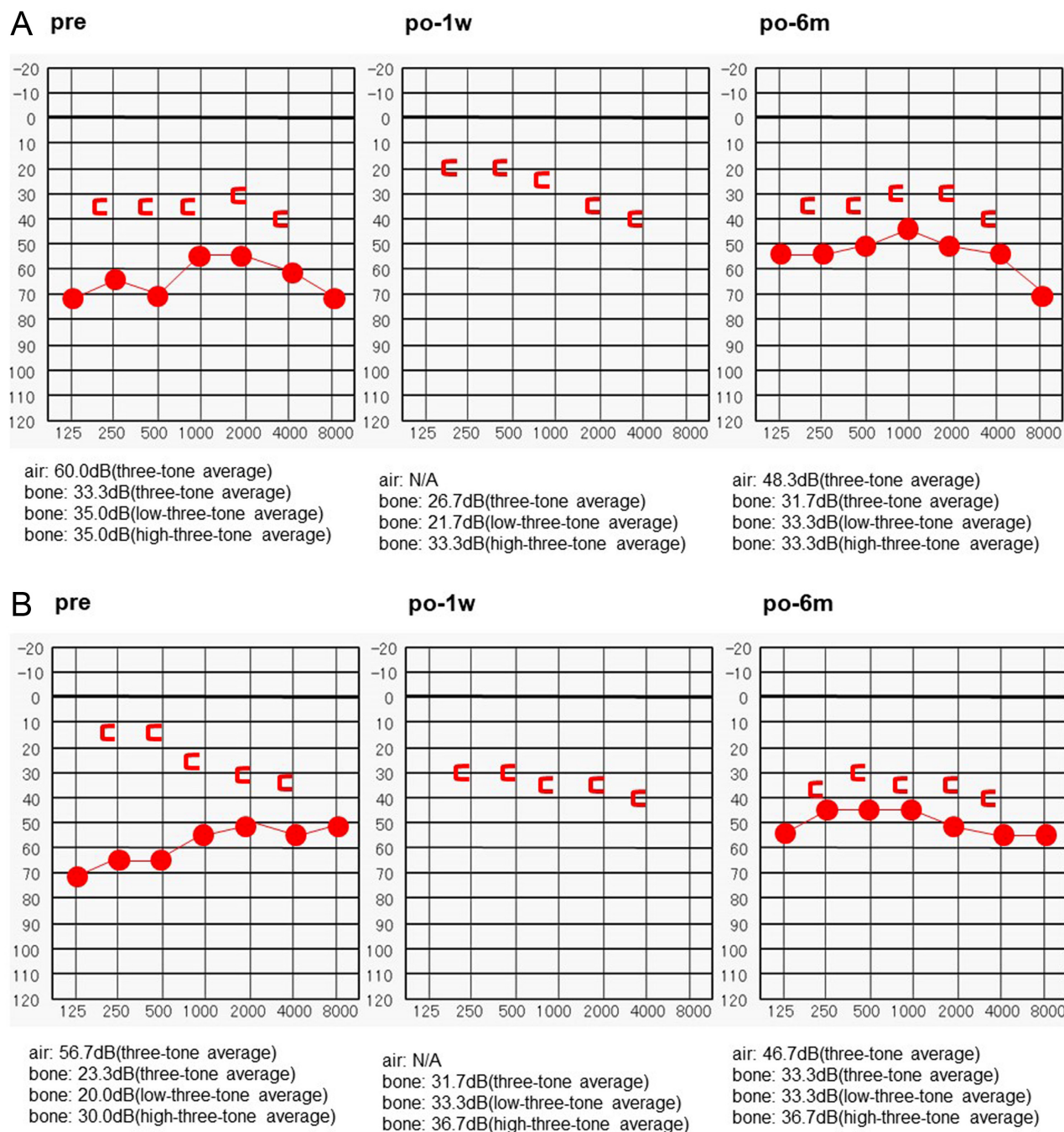
Endolymphatic sac drainage surgery is a treatment for Meniere's disease, in which the bone around the endolymphatic sac is removed as much as possible and the endolymphatic sac is opened into the mastoid cavity to be drained.<sup>19</sup> Based on results in which patients with larger low-tone air-bone gaps after surgery show a better outcome for hearing improvement, post-operative low-tone air-bone gaps are considered to represent "large openings made appropriately near the vestibular aqueduct."<sup>17,20</sup> This is similar to the third mobile window effects for large vestibular aqueduct syndrome, as discussed in the previous section.<sup>10,11</sup>

Finally, we considered the mechanisms of this unique type of audiographic upward and downward shift of the bone conduction threshold from the point of view of the third mobile window theory (Figure 5A and B). Because an inner ear fistula that becomes a complete perilymph fistula causes severe sensorineural hearing loss, the story is limited to an inner ear fistula within type IIa of Dornhoffer and Milewski classifications for cases in which there is no leakage of the perilymph.<sup>21</sup> The inner ear fistula that creates a cholesteatoma is considered to occur, roughly speaking, in 2 patterns; therefore, it

should be simple to understand the changes in the bone conduction threshold seen before and after surgery.<sup>22</sup> One pattern is when the inner ear fistula that creates the cholesteatoma has not functioned yet as the third mobile window before surgery and the other one is when it has already at the surgery.

If the inner ear fistula has not functioned yet as the third mobile window before tympanoplasty, it functions as the third mobile window when the cholesteatoma is removed by the surgery. The inner ear fistula again loses its function when it is closed up completely by bone fragments and fascia. The bone conduction threshold at low pitches appears to improve immediately after the surgery but stabilizes to a level similar to the preoperative level after a period of time (Figure 5A). Eventually, this kind of postoperative rapid upward shift and gradual downward shift would not be clinically problematic, because there were no significant differences between the preoperative and postoperative bone conduction thresholds.

If the inner ear fistula has already functioned as the third mobile window at tympanoplasty, it loses its function and the bone conduction threshold at low pitches appears to worsen when the cholesteatoma is removed by the surgery and the inner ear fistula is closed with bone fragments and fascia (Figure 5B). The latter



**Figure 5.** A case of cholesteatoma with canal fistula showing the postoperative audio-graphic shift of low-tone bone conduction threshold (modified from Ref.<sup>22</sup>). (A) A cholesteatoma case with type IIa of the lateral semicircular canal fistula in the right ear showed better bone conduction threshold at the postoperative 1 week (po-1w) and then gradual audio-graphic shift-down to the preoperative level (po-6m). (B) A cholesteatoma case with type IIa of the lateral semicircular canal fistula in the right ear showed postoperative audio-graphic shift-down of bone conduction threshold at the postoperative 1 week (po-1w) and then no recovery to the preoperative level (po-6m).

situation requires clinical caution to take the informed consent with such patients. When the preoperative bone conduction threshold demonstrates a better level than the actual level, improvement in the air conduction threshold by conductive reconstruction should not be expected because of this bone conduction threshold. When the bone conduction threshold apparently worsens at low pitches after surgery, a detailed preoperative explanation should be given to the patients so that they will not consider this as a surgical side effect.

## CONCLUSION

So-called the third mobile window effects, sometimes may lead otology/neuro-otology surgeons to misunderstand the reason why large air-bone gaps still exist after ossicular reconstruction in tympanoplasty. This review article gives good examples regarding the third mobile window effects in otology/neuro-otology diseases and surgeries.

Peer-review: Externally peer-reviewed.

**Author Contributions:** Concept – T.K.; Design – T.K.; Supervision – T.K.; Resource – T.K.; Materials – M.S.; Data Collection and/or Processing – M.S.; Analysis and/or Interpretation – I.O.

**Acknowledgments:** The authors wish to thank Dr. Masashi Choubi, a registered statistician (certificate number: 622017) for helpful advice on statistical analyses.

**Conflict of Interest:** The authors have no conflict of interest to declare.

**Financial Disclosure:** This study was supported in part by JSPS KAKENHI Grant (2020–2022), AMED under Grant Number 18dk0310092h000a and Health and Labour Sciences Research Grant for Research on Rare and Intractable Diseases (R02-Nanchito (Nan)-Ippan-004) from the Ministry of Health, Labour and Welfare of Japan.

## REFERENCES

1. Merchant SN, Rosowski JJ, McKenna MJ. Superior semicircular canal dehiscence mimicking otosclerotic hearing loss. *Adv Otorhinolaryngol*. 2007;65:137–145. [\[CrossRef\]](#)
2. Merchant SN, Rosowski JJ. Conductive hearing loss caused by third-window lesions of the inner ear. *Otol Neurotol*. 2008;29(3):282–289. [\[CrossRef\]](#)
3. Bess FH, Miller GW, Glasscock ME, Bratt GW. Unexplained conductive hearing loss. *South Med J*. 1980;73(3):335–338. [\[CrossRef\]](#)
4. House JW, Sheehy JL, Antunez JC. Stapedectomy in children. *Laryngoscope*. 1980;90(11 Pt 1):1804–1809. [\[CrossRef\]](#)
5. Schuknecht HF. Otologic mystery. *Am J Otol*. 1987;8(2):182–183.
6. Rosowski JJ, Songer JE, Nakajima HH, Brinsko KM, Merchant SN. Clinical, experimental and theoretical investigations of the effect of superior semicircular canal dehiscence on hearing mechanisms. *Otol Neurotol*. 2004;25(3):323–332. [\[CrossRef\]](#)
7. Minor LB, Carey JP, Cremer PD, et al. Dehiscence of bone overlying the superior canal as a cause of apparent conductive hearing loss. *Otol Neurotol*. 2003;24(2):270–278. [\[CrossRef\]](#)
8. Halmagyi GM, Aw ST, McGarvie LA, et al. Superior semicircular canal dehiscence simulating otosclerosis. *J Laryngol Otol*. 2003;117(7):553–557. [\[CrossRef\]](#)
9. Mikulec AA, McKenna MJ, Ramsey MJ, et al. Superior semicircular canal dehiscence presenting as conductive hearing loss without vertigo. *Otol Neurotol*. 2004;25(2):121–129. [\[CrossRef\]](#)
10. Nakashima T, Ueda H, Furuhashi A, et al. Air-bone gap and resonant frequency in large vestibular aqueduct syndrome. *Am J Otol*. 2000;21(5):671–674.
11. Merchant SN, Nakajima HH, Halpin C, et al. Clinical investigation and mechanism of air-bone gaps in large vestibular aqueduct syndrome. *Ann Otol Rhinol Laryngol*. 2007;116(7):532–541. [\[CrossRef\]](#)
12. Monsell EM. The mechanism of hearing loss in Paget's disease of bone. *Laryngoscope*. 2004;114(4):598–606. [\[CrossRef\]](#)
13. Kitahara T, Sakagami M. The third mobile window effects in neuro-otology diseases and surgeries. *Pract Oto Rhinolaryngol*. 2018;111(9):587–592. [\[CrossRef\]](#)
14. Kitahara T, Maekawa C, Kizawa K, et al. Endolymphatic sac tumor with overexpression of V2 receptor and inner ear hydrops. *Acta Otolaryngol*. 2011;131(9):951–957. [\[CrossRef\]](#)
15. Butman JA, Kim HJ, Baggenstos M, et al. Mechanisms of morbid hearing loss associated with tumors of the endolymphatic sac in von Hippel-Lindau disease. *JAMA*. 2007;298(1):41–48. [\[CrossRef\]](#)
16. Uetsuka S, Kitahara T, Horii A, et al. Transient low-tone air-bone gaps during convalescence immediately after canal plugging surgery for BPPV. *Auris Nasus Larynx*. 2012;39(4):356–360. [\[CrossRef\]](#)
17. Kitahara T, Horii A, Mishiroy Y, et al. Low-tone air-bone gaps after endolymphatic sac surgery. *Auris Nasus Larynx*. 2011;38(2):178–184. [\[CrossRef\]](#)
18. Agrawal SK, Parnes LS. Human experience with canal plugging. *Ann NY Acad Sci*. 2001;942:300–305. [\[CrossRef\]](#)
19. Sood AJ, Lambert PR, Nguyen SA, Meyer TA. Endolymphatic sac surgery for Meniere's disease: a systemic review and meta-analysis. *Otol Neurotol*. 2014;35(6):1033–1045. [\[CrossRef\]](#)
20. Kitahara T, Yamanaka T. Identification of operculum and surgical results in endolymphatic sac surgery. *Auris Nasus Larynx*. 2017;44(1):116–118. [\[CrossRef\]](#)
21. Dornhoffer JL, Milewski C. Management of the open labyrinth. *Otolaryngol Head Neck Surg*. 1995;112(3):410–414. [\[CrossRef\]](#)
22. Kitahara T, Kamakura T, Ohta Y, et al. Chronic otitis media with cholesteatoma with canal fistula and bone conduction threshold after tympanoplasty with mastoidectomy. *Otol Neurotol*. 2014;35(6):981–988. [\[CrossRef\]](#)