

ORIGINAL ARTICLE

The Value of Vestibular Neurotomy in the Course of Bilateral Meniere's Disease

Stavros Mavroidakos, Hani El Garem, Arnaud Deveze, Ioannis Vathilakis, Jacques Magnan

University Aix Marseille II, Hopital Nord, Otolaryngology Department Marseille, France,

Objective; The aim of this study is to determine the effect of vestibular neurotomy in the evolution of unilateral Meniere's disease towards bilaterality and in hearing preservation in such selected patients.

Materials & Methods; Retrospective chart review of 328 incapacitating Meniere's disease patients who underwent retrosigmoid vestibular neurotomy between 1993 to 2006. The main duration of the follow up time was 4 years (1 to 15 years).

Results; Out of 328 patients, 18 (5,5 %) presented a bilateral disease with the following group distribution.

Group I : 5 patients (1,6 %) developed bilateral Meniere after unilateral vestibular neurotomy. On the operated side, hearing was preserved in 60 % (3/5) and worsened in 40 % (2/5).

Group II : 11 bilateral Meniere's disease patients before vestibular neurotomy on the active side. On the operated side, hearing was preserved in 73 % (8/11) and worsened in 27 % (3/11).

Groupe III : 2 patients with bilateral vestibular neurotomy.

Conclusion; Vestibular neurotomy is not only an effective procedure to control vertigo but also for reducing both the rate of developing Meniere's disease in the uninvolved ear (5 out 315 patients, 1,6 %) and the rate of hearing impairment on the operated ear.

Submitted : 12 December 2008

Accepted : 03 January 2009

Meniere's disease is a nosologic entity, described by Prosper Meniere^[1] in 1861. It appears with episodic vertigo, fluctuating hearing loss in low frequencies, tinnitus and aural fullness at the same ear. Although a large number of studies have been carried out, the real etiology of the disease is still unknown. Many factors, different and uncorrelated to each other have been implicated as the cause of it (endocrine disorders, unbalance of autonomic nervous system, allergy, infections, vascular disorders, autoimmune disorders, ototropic viruses). A combination of them could be the pathogenetic basis of the disease.

The diagnosis remains so far based on the clinical observation. Instrumental and imaging results (audiogram, ABR, ECoG, vestibular investigation, MRI, CT scan) are used to confirm a peripheral and not a retrocochlear involvement. A combination of multiple medical treatment as strict salt restriction and drugs like betahistidine, diuretics (mannitol, glycerol, hydrochlorothiazide), vasoactive drugs (trimetazidine, cynarizine), steroids and aminoglycosides I.V. or intratympanic (for the two last categories of drugs) have been used. This kind of treatment is efficient to reduce the number and the severity of the attacks of Meniere's disease, but not to support a complete

Corresponding address:

Pr Jacques MAGNAN

University of Aix Marseille II Hôpital Nord ORL. Dept.

13915 Marseille cedex 20 - France

E-mail: Jmagnan@ap-hm.fr

Copyright 2005 © The Mediterranean Society of Otolaryngology and Audiology

eradication of them. So their effect in the control of the disease is unanimously controversial. In cases of patients with incapacitating vertigo, refractory to this medical treatment, several conservative (endolymphatic sac shunt, vestibular neurotomy) and destructive (labyrinthectomy, vestibulo-cochlear neurotomy, translabyrinthine vestibular neurotomy, intratympanic gentamycin) surgical procedures have been used to provide definitive control of vertigo. In decision making of performing a destructive surgical procedure in such a patient with loss of hearing in the selected ear, the surgeon must always have in mind the potential risk of the bilateral involvement of the disease.

According to the literature, bilaterality presents an incidence between 2-78% in the total number of reports, with the most of them between 10-35%^[2-14]. This wide variation is indebted to the different criteria the authors use for bilaterality, or the different duration of the follow-up interval. All the studies suggest an increased percentage of bilateral involvement over time^[4,14,15,16]. So, it is obvious the importance of a conservative procedure to produce a total loss of afferent input from the peripheral vestibular disorder, with the simultaneous preservation of the hearing function, against the risk that the uninvolved ear would develop a hearing loss in the future. Between the above mentioned surgical procedures, a selective vestibular neurotomy (VN) is, according to the literature^[17,18,19,20], the most efficient to succeed control of vertigo while preserving hearing, and support more benefit to patients with Meniere's disease than other non-Meniere vestibulopathies^[21, 22, 23]. Several surgical approaches for vestibular neurotomy have been extensively described. It is able to be performed via retrolabyrinthine (RLVN), infralabyrinthine (IFLVN), middle fossa (MFVN) and retrosigmoid (RSVN) approaches.

The aim of this study is to demonstrate the efficiency of RSVN in the control of vertigo and hearing preservation in unilateral Meniere's disease as well as its effect in the evolution of unilateral Meniere's

disease towards bilaterality, and in hearing preservation in patients with bilateral involvement.

Patients & Method

Three hundred and twenty eight (328) patients with Meniere's disease underwent RSVN from 1993 to 2006 in the ENT department of Nord hospital. All the patients suffered from intractable and incapacitating vertigo and had failed medical therapy. Eighteen (5.5%) of these 328 patients presented with a bilateral disease, ten women (55,5%) and eight men (44,5%), with the age from 39 to 75 years and the mean age for the women at 58,7 years and for the men at 56,2 years and the total average at 57,6 years. The age of onset of the disease was between 25 and 58 years with the average value at 41,11 years (42,1 for the women and 39,8 for the men). The mean time from onset to bilaterality was 10,72 years and the mean age of bilateral involvement was 50,7 years (53 years for the women and 48 years for the men). Two of them (2/18) presented bilaterality at the onset of the disease. In addition, eleven of these patients (11/18) were bilaterally affected before surgery, which means a total number of thirteen patients (13/18) with bilateral involvement preoperatively. The remaining five patients (5/18) had an unilateral disease at the time of surgery and the other side was affected postoperatively, representing 27 % of our bilateral patients and 1,6 % of the total 315 patients, with unilateral involvement at the time of surgery. The mean duration of the follow-up time was 4 years (from 1 year to 15 years).

An MRI was performed to all patients to exclude retrocochlear lesions. A pure tone audiogram (PTA) and a videonystagmogram were done preoperatively. The first postoperative audiogram (1 week to 1 month after surgery) and that of the last follow-up (over 1 year to 15 years) were used for the evaluation of hearing. As hearing level was considered the mean threshold of 5 frequencies (250, 500, 1000, 2000, 4000Hz). Difference in PTA more than 10db was regarded as significant (>-10db→worsening,

>+10db→improved). In any other case hearing was contemplated as unchanged.

The RSVN is done through a minimal retrosigmoid craniotomy. After opening of the dura and gentle retraction to the cerebellum, the vestibulocochlear bundle is identified. There is often a difference in color between the vestibular nerve (slightly greyer in color) and the cochlear nerve (whiter in color). A small vessel is often seen at the demarcation line between the vestibular and cochlear nerve. The facial nerve is identified by the electric stimulator just medially to the vestibulocochlear bundle. A separating plan is created and section of the vestibular nerve superiorly is performed by microscissors. The cut edges of the nerve are retracted.

Results

From the 328 patients with Meniere's disease who underwent RSVN, 12 (3.6%) patients presented bilateral disease 1-24 months before surgery (mean time 8,25 months). Of the remaining 315 patients who were unilaterally affected at the time of surgery, 5 (1.6%) patients presented bilateral involvement from 2 months to 22 years after surgery (mean time 5,85 years). The presenting symptoms in these 18 patients were vertigo in all of them (100%), hearing loss in 16 patients (88,8%), tinnitus in 17 patients (94,4%), fluctuation of hearing in 8 patients (44,5%) and sensation of aural fullness in 8 patients (44,5%). Two of the patients had already a surgical decompression of the endolymphatic sac, one patient had a revision of the VN which was performed two years earlier in another medical center, one patient had 2 intratympanic injections with Gentamycin preoperatively, one patient suffered from Arnold-Chiari syndrome. There were no complications postoperatively except one case with CSF leakage, which was controlled after two efforts, one by local and one under general anesthesia. Out of these 18 bilateral Meniere's disease patients complete control of vertigo was achieved in 17 patients (94,45%) at the last follow up.

Three different groups of patients can be defined according to their evolution: (Table 1)


- a) Group I, includes 5 patients with unilateral involvement of the disease at the time of surgery who presented bilaterality postoperatively,
- b) Group II, includes 11 patients with bilateral involvement of the disease before surgery, and
- c) Group III, includes 2 patients with bilateral involvement, who were operated in both ears.


For the Group I with the 5 patients (No 2, No 4, No 7, No 8, No 13) operated for unilateral Meniere's disease who presented bilaterality postoperatively, the PTA threshold of the operated ear was 54db (19db-76db) preoperatively and 56,6db (27db-88db) postoperatively, difference 2,6db. At the last control the PTA threshold was 65db (61db-72db) which means a difference of 11db from the preoperative status. In other words 40% of these patients (2/5) had worsening and 60% (3/5) had a preservation of hearing (2/5 unchanged and 1/5 improved) immediately postoperatively. During the last follow-up, 60% had preservation (3/5) and 40% had worsening of hearing (2/5). All of them had complete control of vertigo (100%).


For the 11 patients of Group II (No 1, No 3, No 5, No 6, No 9, No 10, No 11, No 12, No 14, No 16, No 17) with the preoperative bilateral involvement and unilateral vestibular neurectomy, the PTA threshold on the operated side, preoperatively was 60db (22db-99db) and immediately postoperatively 63db (23db-99db) showing a difference of 3db. During the last follow up, it was 70db (45db-102db), a difference of 10db in comparison with the preoperative hearing. A percentage of 72,73% of the patients (8/11) had preservation (7 unchanged and 1 improved) and the rest 27,27% had worsening of hearing postoperatively (3/11). The corresponding values for the last control were 72,73% unchanged (8/11) and 27,27% worsened hearing (3/11) respectively. About 91% of the patients (10/11) presented complete control of vertigo and 9% (1/11) continued to suffer from vertigo attacks till the follow up. One of these patients (No 16) had the

Table 1. Change of PTA threshold in bilaterally affected patients treated by RSVN in a long follow-up time

No	Name	Operated ear (PTA in db)			Contralateral ear (PTA in db)		
		Preop	Postop	Last follow up	preop	postop	last follow up
1	B.C.	43	42 (U)	45 (U)	14	11	32
2	C.D.	60	72 (W)	68 (U)	34	60	59
3	R.J.	59	58 (U)	74 (W)	32	32	62
4	R.R.	45	45 (U)	61 (W)	23	20	34
5	D.Y.	92	79 (I)	102 (U)	36	39	48
6	G.D.	55	58 (U)	54 (U)	27	23	25
7	P.M.	76	88 (W)	72 (U)	38	31	53
8	M.P-Y.	19	27 (U)	62 (W)	11	20	20
9	R.R.	40	52 (W)	54 (W)	19	24	24
10	S.S.	99	90 (U)	100 (U)	87	78	89
11	F.R.	36	54 (W)	41 (U)	55	23	41
12	P.A.	76	77 (U)	66 (U)	43	38	41
13	R.F.	70	51 (I)	62 (U)	23	22	78
14	A.J-P.	47	61 (W)	54 (U)	39	39	57
15	M.A.	R44 L77	R51 (U) L80 (U)	R76 (W) L87 (U)	R58 L68	R58 L74	R87 L76
16	L.C.	22	23 (U)	80 (W)	100	100	100
17	B.C.	91	99 (U)	100 (U)	46	26	37
18	D.C.	92	91 (U)	100	100	100	100
Average PTA of 2nd group		60	63	70	45,27	39,36	50,54


GROUP I
 (unilateral at the time
 surgery→bilateral
 after surgery)


GROUP II
 (bilateral at the time
 of surgery)


GROUP III
 (bilateral patients with
 VN in both ears)

PTA=Pure Tone Average, U=Unchanged, W=Worsened, I=Improved, preop=preoperatively, postop=postoperatively.

contralateral ear deaf before surgery and he is now a candidate for cochlear implantation (7 years postoperatively).

Group III is constituted of two patients who underwent a bilateral RSVN. The first patient is a man (No 15), who presented bilaterality before surgery. He was first operated at the right ear (better hearing but worse vestibular function than the left). PTA threshold

preoperatively was 44db, immediately postoperatively, 51db (difference 7db) and at the last follow up (6 years later) 76db (difference 32db). Two years later he presented an aggravation of the vestibular function at the contralateral ear. Two trials with intratympanic Gentamycin injection were without satisfactory result. Six months later, a RSVN at the second (left) ear was performed. The preoperative PTA of this ear was 77db

preoperatively, 80db (difference 3db) immediately postoperatively and 87db (difference 10db) at the last follow up (3years later). Vertigo was completely controlled at the follow-up time. Preservation of hearing was achieved in both operated ears at the first postoperative examination (100%), and in the left ear during the last control follow-up (50%). The second patient of Group III, who underwent bilateral VN, is a woman (No 18). At the beginning she was operated for incapacitating vertigo due to Meniere's disease at the right side. A transcochlear vestibulocochlear neurectomy was performed at this side in another hospital. Twenty two years later she presented contralateral involvement with refractory vertigo, resistant to the medical treatment. A RSVN in the left side was performed (the right ear was already deaf). The preoperative PTA of this ear was 92db and immediately postoperatively 91db (difference of 1db). Using a hearing aid, she succeeded a satisfactory result in hearing for a long time but 8 years later the ear was almost totally deaf and the hearing aid was not useful. Then, a cochlear implant was placed at in the left ear . She has no vertigo and only unsteadiness in the dark.

Discussion

According to the literature Wazen et al.^[24] reported preservation of hearing in 73% of patients treated with VN followed for ^[12-40] months postoperatively. Texico and Wiet^[24] reported a percentage of 72% in preservation of hearing. Rosenberg et al.^[15] presented

34% worsening, 32% improvement and 34% with no change of hearing (66%) in 47 patients followed for 18 to 24 months. Hillman et al.^[25] reported 28% worsening of hearing, 23% improvement and 49% unchanged hearing in 39 patients followed for 12 months postoperatively. Pappas et al.^[9] reported 68% preservation and 32% worsening of hearing postoperatively and 50% preservation with 50% worsening of hearing in a mean follow up time of 6 years in 19 patients with Meniere's disease. In one of our previous study^[26], we have reported 9% improvement , 75% stabilization and 16% worsening of hearing in 283 patients of Meniere's disease who underwent RSVN and were controlled for a five years follow-up period. The factor that may influence post operative hearing preservation after vestibular neurectomy is the transection of the efferent cochlear fibers within the vestibular nerve ^[26]. In this present series the hearing results of the 18 bilateral patients in the first postoperative follow up are 61,11% unchanged (11/18), 11,11% improved (2/11) and 27,77% with worse hearing (5/11). That means a preservation of hearing at the level of 72,22% (Figure 1). During the last follow-up 67% of the patients (12/18) preserved their hearing and 33% had worsening of hearing (6/18). These percentages confirm the positive effect of VN in the bilateral affected patients as well as in the patients with unilateral involvement.

The diagnostic criteria we used for bilaterality of Meniere's disease are the presence of three of the typical symptoms of the disease at one side and a

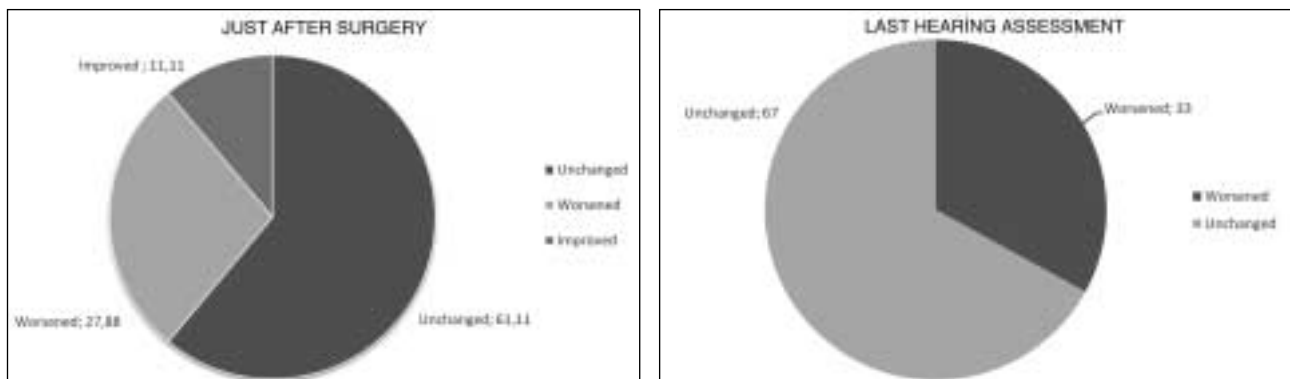


Figure 1. Hearing results in of the bilaterally affected patients during the follow-up time.

fluctuating or not, sensorineural low-frequency hearing loss at the contralateral side simultaneously. That means that we consider bilaterality when there is evolution of a typical Meniere's disease in one side and impairment of hearing at the opposite side with or without vertigo. In fact, in bilaterality the main incapacitating symptom is not equilibrium trouble but hearing loss. Candidates for surgical treatment were only those patients with bilateral disease, who presented incapacitating vertigo. In our policy, recurrent vertigo was the unique indication for surgery whatever the hearing threshold.

Bilaterality is reported to present a wide variation of incidence (2-78%) in the natural outcome of the disease, with the most of them to be between 10% and 35%. In the literature^[13,15,27], the corresponding percentage for surgically treated patients with VN, is between 0% and 5,7%. In our study, the incidence of bilaterality in the 315 unilateral affected patients, operated by RSVN, is 1,6 % (5/315), which is in complete agreement with that in the literature. This incidence is so much different and inferior than that of the natural history of the disease with medical treatment. This low number leads us to the conclusion that VN has a beneficial effect in reducing the bilateral involvement of the disease. Regarding the drastic decreasing in bilaterality after VN, a question arises. What is the explanation of the role of VN in this reduction? We have no definite answer for this question, but we can make a hypothesis. This hypothesis is related to the functional recovery achieved by the central vestibular compensation, which is a neurological phenomenon induced by the VN. Vestibular compensation modifies the neurologic pattern by central sensory substitution for a regenerating neuronal activity in the deafferented vestibular nuclei, and also by adaptation of function in the vestibular nuclei on the intact side, thanks to new connection of the peripheral vestibular system with the vestibular nuclei.

The decrease in bilaterality of Meniere's disease in surgically treated patients could be some analogy to sympathetic ophthalmia, and bilateral Meniere's disease

characteristics have led many authors to suggest an autoimmune cause^[14, 28, 29]. But, after vestibular neurotomy the affected inner ear is still intact, and consequently the potential immune responses. The prophylactical effect of corticosteroids in the course of Meniere's disease is still controversial.

In the operated cases on the side with the better PTA threshold (cases No 11, No 15, No 16, No 18), preservation of hearing was succeeded in 75% of the patients (3/4) at the first postoperative follow up and in 50% of them (2/5) at the last follow-up (mean time 5,7 years). It is important to comment on the fact of preservation of hearing when the better ear is operated. When there is an indication of VN for incapacitating vertigo in patients with bilateral involvement of Meniere's disease and the operated ear presents the best hearing function or when it is the only hearing ear (due to contralateral deafness caused from the disease), surgery classically is not ill-advised. The hearing results in after VN demonstrate both, that there is no intraoperative injury of the auditory function and represent the most efficient procedure in hearing preservation in a very high percentage of these selected patients with bilateral sensorineural hearing loss.

Tokumasu et al.^[8] reported in an article on the natural course of hearing of bilateral affected medical treated patients that the deterioration of the PTA threshold in seven patients was 31,6db (25,53db→57,14db) for the right ear and 23db (30,53db→53,57db) for the left ear in a follow-up period of 10,11 years. In our study the corresponding thresholds in the second group (bilateral patients operated by VN) are -10db (60db→70db) for the operated ear and -5,27db (45,27db→50,54db) for the contralateral ear for a follow-up time of 3,87 years. Bilateral affected patients operated by RSVN, present a lower rate in aggravation of hearing in the operated ear as well as the contralateral one. RSVN seems to be efficient in decreasing the deterioration of hearing in both ears of the bilateral patients operated on one side compared with those of the natural outcome. This observation warrants further investigation in the future

for the extraction of safer conclusions, because of the limited number of patients and the different follow-up time.

Conclusion

It is well established that vestibular nerve section via retrosigmoid approach is a safe and effective surgical procedure for the control of vertigo and hearing preservation in intractable Meniere's disease, with a low rate of complications. In addition, our study shows the positive effect of VN in reducing the incidence of bilaterality among the unilateral operated patients (1,6 %), in compare with the natural outcome of Meniere's disease (10-35%). In patients with bilateral involvement of the disease, unilateral VN on the active side (fluctuating hearing and fluctuating vestibular response), presents a beneficial effect in reducing the rate of hearing impairment on both the operated and the contralateral side.

References

1. Ménière P. Mémoire sur des lésions de l'oreille interne donnant lieu à des symptômes de congestion cérébrale apoplectiforme. *Gaz Med Paris* 1861; 16 (suppl13):597-601.
2. Greven AJ, Oosterveld WJ. The contralateral ear in Meniere's disease. *Arch Otolaryngol*. 1975; 101:608-12.
3. Kitahara M, Matsubara H, Takeda T, Yazawa Y. Bilateral Meniere's disease. *Adv Otorhinolaryngol*. 1979; 25:117-21.
4. Paparella MM, Griebie MS. Bilaterality of Meniere's disease. *Acta Otolaryngol*. 1984; 97:233-7.
5. Palaskas CW, Dobie RA, Snyder JM. Progression of hearing loss in bilateral Meniere's disease. *Laryngoscope*. 1988; 98: 287-90.
6. Kodama A, Kitahara M, Kitanishi T. Clinical findings in Meniere's disease with bilateral fluctuant hearing loss. *Acta Otolaryngol Suppl*. 1995; 519:227-9.
7. Lee CS, Paparella MM, Margolis RH, Le C. Audiological profiles and Meniere's disease. *Ear Nose Throat J*. 1995; 74:527-32.
8. Tokumasu K, Fugino A, Naganuma H, Hoshino I, Arai M. Initial symptoms and retrospective evaluation of prognosis in Meniere's disease. *Acta Otolaryngol Suppl*. 1996; 524:43-9.
9. Pappas DG Jr, Pappas DG Sr. Vestibular nerve section: long-term follow-up. *Laryngoscope*. 1997; 107:1203-9.
10. Conlon BJ, Gibson WP. Meniere's disease: the incidence of hydrops in the contralateral asymptomatic ear. *Laryngoscope*. 1999; 109:1800-2.
11. Salvinelli F, Trivelli M, Greco F et al., Meniere's disease : is it a bilateral disease? *Eur Rev Med Pharmacol Sci*. 1999; 3:129-33.
12. Friedrichs I, Thornton AR. Endolymphatic hydrops in asymptomatic ears in unilateral Meniere's disease. *Laryngoscope*. 2001; 11:857-60.
13. Perez R, Chen JM, Nedzelski JM. The status of the contralateral ear in established unilateral Meniere's disease. *Laryngoscope*. 2004; 114:1373-6.
14. House JW, Doherty JK, et al., Meniere's disease: prevalence of contralateral ear involvement. *Otol Neurotol*. 2006; 27:355-61.
15. Rosenberg SI, Silverstein H, Hoffer ME, Thaler E. Hearing results after posterior fossa vestibular neurectomy. *Otolaryngol Head Neck Surg*. 1996; 114:32-7.
16. Stahle J, Friberg U, Svedberg A. Long-term progression of Meniere's disease. *Acta Otolaryngol Suppl*. 1991; 485:78-83.
17. Rosenberg S, Silverstein H, Flanzer J, Wanamaker H. Bilateral Meniere's disease in surgical versus non surgical patients. *Am J Otol*. 1991; 12:336-40.
18. Silverstein H, Smouha E, Jones R. Natural history vs. surgery for Meniere's disease. *Otolaryngol Head Neck Surg*. 1989; 100:6-16.
19. Kubo T, Doi K, et al., Assessment of auditory and vestibular functions after vestibular neurectomy for Meniere's disease. *Acta Otolaryngol*. 1995; 115:149-53.

20. Silverstein H, Norrell H, Haberkamp T. A comparison of retrosigmoid IAC, retrolabyrinthine, and middle fossa vestibular neurectomy for treatment of vertigo. *Laryngoscope*. 1987; 97:165-73.
21. Boyce SE, Mischke RE, Goin DW. Hearing results and control of vertigo after retrolabyrinthine vestibular nerve section. *Laryngoscope*. 1988; 98:257-61.
22. Molony TB. Decision making in vestibular neurectomy. *Am J Otol*. 1996; 17:421-4.
23. Van de Heyning PH, Verlooy J, Schatteman I, Wuyts FL. Selective vestibular neurectomy in Meniere's disease: a review. *Acta Otolaryngol Suppl*. 1997; 526:58-66.
24. Wazen JJ, Spitzer J, Kasper C, Anderson B. Long-term hearing results following vestibular surgery in Meniere's disease. *Laryngoscope*. 1998; 108:1470-3.
25. Hillman TA, Chen DA, Arriaga MA. Vestibular nerve section versus intratympanic Gentamycin for Meniere's disease. *Laryngoscope*. 2004; 114:216-22.
26. Magnan J., Chays A., Bruzzo M., Broder L. Long-term hearing results after retrosigmoid vestibular neurotomy. *Proceedings of the 4th International Symposium on Meniere's Disease*. Edit. By Sterkers O, et al., Kugler Publications, The Hague, The Netherlands, Update 2000, pp.799-802.
27. Gosku N, Yimaz M, Bayramoglu I, Bayazit YA. Combined retrosigmoid retrolabyrinthine vestibular nerve section: results of our experience over 10 years. *Otol Neurotol*. 2005; 26:481-3.
28. Harris J., Ryan A. Fundamental immune mechanisms of the brain and inner ear. *Otolaryngology. Head and Neck Surgery* 1995, 112:639-53.
29. Shin S., Billings P., Keithley F., et al. Comparison of anti-heat shock protein 70 and anti -68- kDa Inner Ear Protein in the sera of patients with Meniere's disease . *Laryngoscope* 1997; 107:222-27.