

Case Report

Diagnosis of Patients Presenting with Vertigo, Headache, and Epileptic Seizure: Evaluating Vestibular Patients by Using Cervical Vestibular Evoked Myogenic Potential and Auditory Middle Latency Responses in the Clinical Setting

Hiroko Monobe¹, Wakako Nakahishi², Wayo Kawawaki³, Yukiko Tsuda⁴

Department of Otolaryngology, Japanese Red Cross Medical Center, Tokyo, Japan

ORCID IDs of the authors: H.M. 0000-0001-7817-7154, W.N. 0000-0002-1386-0208, W.K. 0000-0002-9191-9754, Y.T. 0000-0003-1256-4578.

Cite this article as: Monobe H, Nakahishi W, Kawawaki W, Tsuda Y. Diagnosis of patients presenting with vertigo, headache, and epileptic seizure: evaluating vestibular patients by using cervical vestibular evoked myogenic potential and auditory middle latency responses in the clinical setting. *J Int Adv Otol*. 2023;19(1):61-65.

Migraine and vertigo are common complaints seen in clinical practice, and in a few such cases, we also find epileptic manifestations, including migraine-triggered seizures. Currently, patients presenting with vertigo and headache are diagnosed according to established diagnostic criteria for Meniere's disease, vestibular migraine, or vestibular migraine/Meniere's disease overlapping syndrome. In addition to using those diagnostic criteria and the patient's history, cervical vestibular evoked myogenic potential and auditory middle latency responses are useful tools to better understand the physiological background of these patients and also to confirm the diagnosis. Here we report 2 cases: 1 of vestibular migraine/Meniere's disease overlapping syndrome and 1 of vestibular migraine with epileptic manifestations. Each patient showed potentiation (lack of habituation) in auditory middle latency response, and each showed endolymphatic hydrops in cervical vestibular evoked myogenic potential. The potentiation in auditory middle latency response might be attributable to neuronal hyperexcitability in those patients with migraine or epilepsy, and neurogenic inflammation caused by migraine episodes might affect inner ear function.

KEYWORDS: Migraine, epilepsy, Meniere's disease, vestibular evoked myogenic potential, auditory mid-latency potential

INTRODUCTION

Migraine and vertigo are common complaints seen in clinical practice. Not only can they coincide in an individual patient just by chance but also there are numerous patients whose vestibular symptoms are brought on by migraine.¹ In some cases, vestibular migraine (VM) may be indistinguishable from Meniere's disease (MD) on the basis of the patient's history and symptoms.²

Recently, by using cervical vestibular evoked myogenic potential (cVEMP) slope as an index of endolymphatic hydrops (EH) in the saccule, Murofushi et al³ reported a new clinical syndrome whereby the signs or symptoms of MD occur simultaneously with the signs or symptoms of VM. They referred to the syndrome as VM/MD overlapping syndrome (VM/MD-OS).

Another tool used in the clinical setting is auditory mid-latency response (AMLR) which is used to investigate habituation to repetitive stimuli in VM patients with MD.⁴

By using these physiological testing tools, diagnoses such as MD or VM can now be made not only on the basis of a patient's history but also on a pathophysiological basis. Furthermore, migraine and epilepsy have some clinical and pathophysiological overlaps.^{5,6} Here, we present two patients in whom cVEMP and AMLR were used for diagnosis: 1 patient was diagnosed with VM/MD-OS and 1 with VM, both with clinical epileptic manifestations.

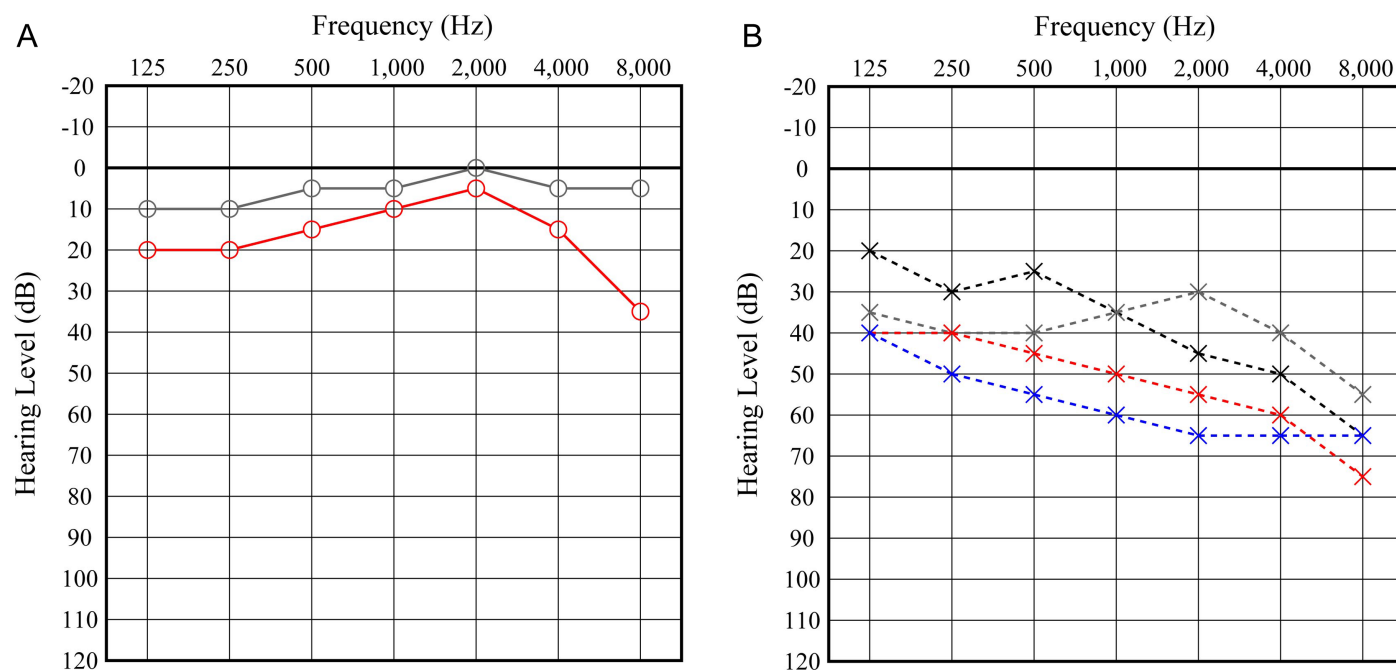


Figure 1. Change in hearing level. Case 1. (A) Right pure tone audiometry. Her right hearing level deteriorated 1 year after the first visit. Gray line indicates her hearing at the first visit, red line indicates after 1 year. (B) Left pure tone audiometry. Black dotted line indicates her hearing at the first visit, gray indicate after using intratympanic steroid, red indicates 6 months after the first visit and blue indicates 12 months after the first visit. The patient's left hearing level deteriorated despite various treatments.

CASE PRESENTATION

Case 1: 37-Year-Old Woman

This patient visited our outpatient clinic complaining of left hearing loss, fullness in her left ear, and vertigo lasting for several hours on a daily basis. She had been diagnosed as having left sudden

hearing loss and was treated with steroids and hyperbaric oxygen 1 year earlier at another clinic. From her clinical history, we diagnosed her as having left MD and treated her with intratympanic steroids; consequently, her vertigo resolved. But 7 months after this treatment, she again experienced vertigo lasting for 6-12 hours, deterioration of left hearing (Figure 1), left phonophobia, and severe left

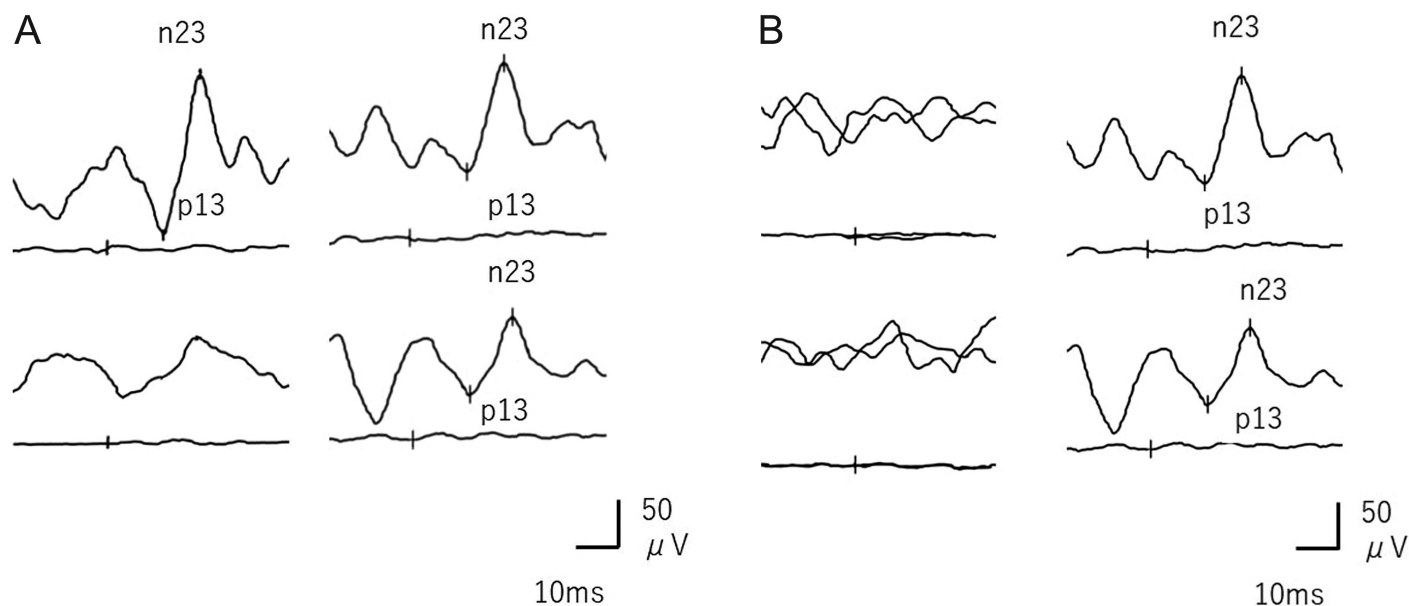


Figure 2. Change in cVEMP, Case 1. (A, B) Left-hand panel=500Hz cVEMP, right-hand panel=1,000Hz VEMP, upper panel=right, lower panel=left. (A) 1 year after first visit. The patient's right cVEMP slope was -9.32 , suggesting that she did not have right saccular endolymphatic hydrops; her left cVEMP was absent in response to the 500-Hz short tone burst (STB), but it was clearly present in response to the 1000-Hz STB. Asymmetry ratio (AR) for 500-Hz and 1000-Hz cVEMP was 20.4 and 14.0 respectively, non-indicative of unilateral saccular dysfunction. $AR = 100 \times (CAu - CAa) / (CAu + CAa)$. CAa: normalized amplitude (p13-n23) of the affected side; CAu: normalized amplitude (p13-n23) of the unaffected side; $AR > 41.6$ is indicative of unilateral saccular dysfunction.⁴ (B) 2 years after first visit. The patient's cVEMP was bilaterally absent in response to the 500-Hz short tone burst, but was clearly present in response to the 1000-Hz STB, indicating saccular endolymphatic hydrops on both sides.

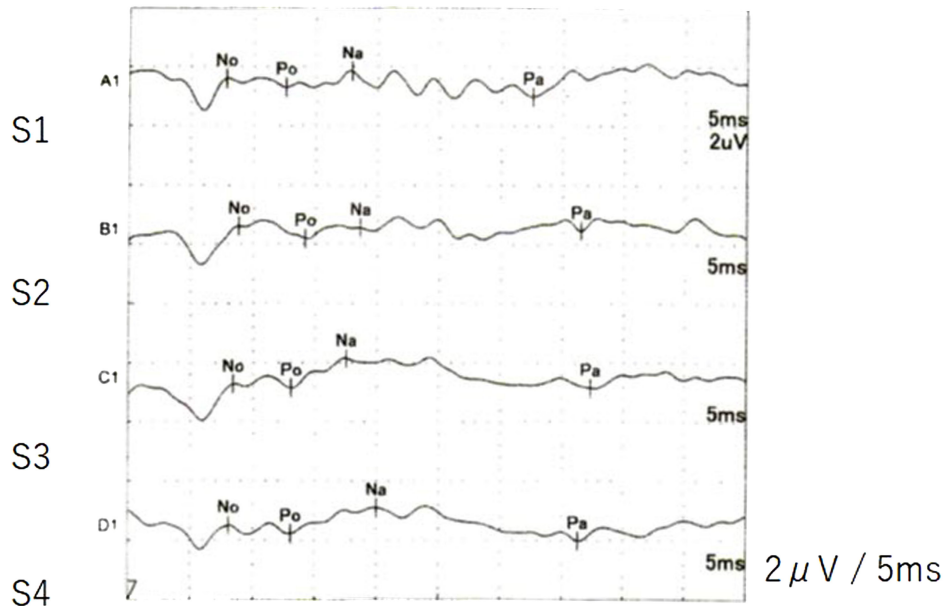


Figure 3. AMLR to repetitive stimuli in case 1. Raw amplitude of Na-Pa was 1.95 μ V in S1 and 2.40 μ V in S4; relative S4/S1 amplitude was 1.6, indicating lack of habituation (potentiation). AMLR, auditory mid-latency response.

headache that occurred at frequencies ranging from every day to once a week, depending on the weather, stress, and menstruation. Her headache was accompanied by blind spots and vision changes. Her family history was unclear. From her vertiginous episodes and headaches, diagnosis of VM/MD-OS was given, and lomerizine hydrochloride and diuretics were administered. Her cVEMP slope was indicative of left saccular EH at 1 year after the first visit, but this changed to bilateral EH after 2 years (Figure 2), and her AMLR showed potentiation (lack of habituation) (Figure 3), a feature of migraine patients. Following administration of lomerizine hydrochloride, her vertigo and headache resolved, but her headache still returned during bad weather and menstrual periods. Furthermore, she experienced transient convulsions in her right upper arm, and

her electroencephalogram (EEG) showed spike and wave forms with hyperventilation (Figure 4). From this point, sodium valproate was added by her neurologist. Since then she has been free from vertigo and severe headache for 2 years.

In our department, cVEMP recording was basically performed according to international guidelines.⁷ Using the normalized amplitude of p13-n23, the 500-1000-Hz cVEMP slope was calculated as a tuning property index (a measure of frequency preference). According to Murofushi et al.³ when the 500-1000-Hz cVEMP slope is ≤ -19.9 , the tuning property test is regarded as positive, suggestive of saccular EH. And during the recording, subjects were asked to lie in the supine position and raise their heads to contract the SCM (sternocleidomastoid muscle).

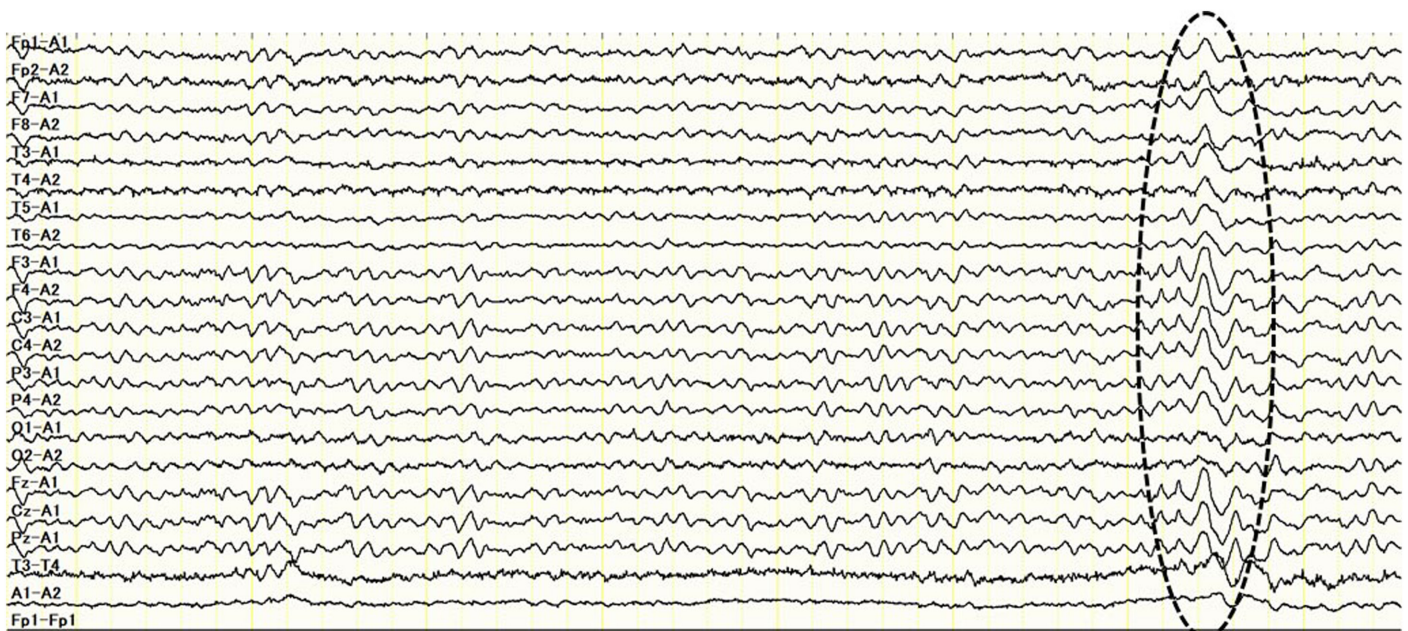


Figure 4. EEG in case 1. EEG through activation with 3 minutes of hyperventilation. Spike and wave forms are seen (dotted circle). EEG, electroencephalogram.

Auditory mid-latency responses were recorded by using the Neuropack system, following the same method as that described by Murofushi et al.⁴ No was defined as the largest negative deflection that followed wave 5 of the auditory brain response and was earlier than 15 ms. Po was defined as the largest positive deflection that followed No and was earlier than 20 ms. Na was defined as the largest negative deflection that followed Po and was earlier than 25 ms. When No was not found, the earliest negative deflection that followed wave 5 and was earlier than 25 ms was regarded as Na. Pa was defined as the largest positive deflection that followed Na and was earlier than 40 ms. When we could not decide Po or Na, the largest positive deflection earlier than 40 ms was defined as Pa. Peak-to-peak amplitudes of No-Po and Na-Pa and peak latencies of No, Po, Na, and Pa were measured.

According to Murofushi et al.⁴ the Na-Pa amplitude in S4 relative to that in S1 of >1.11 times can be regarded as indicating potentiation (lack of habituation).

Case 2: 25-Year-Old Man

This patient visited our clinic because of rotational vertiginous attacks and right severe headache lasting for 1 month. His headache was without aura, pulsatile, around the right ear, and occurring daily. His family history of migraine was not clear. His pure tone hearing was normal; however, cVEMP showed left EH and AMLR showed potentiation (S4/S1 ratio = 2.05), and we suspected EH and VM. Diuretics and lomerizine hydrochloride were administered after which his headache and vertiginous attacks resolved. However, 2 months later, he experienced convulsions and loss of consciousness and was referred to a neurological referral center. His EEG showed a slow wave in F4, and he was diagnosed with epilepsy. Lacosamide and lomerizine hydrochloride were administered, and he has been free from symptoms for 12 months.

Written informed consent was obtained from all subjects participating in the study.

DISCUSSION

Case 1 met the diagnostic criteria for MD,⁸ VM,⁹ and VM/MD-OS,³ and Case 2 met the criteria for VM.⁹ These patients were each evaluated by a neurologist, and EEG abnormalities were revealed. Because the diagnosis given in case 2 was also epilepsy, this patient was assumed to have seizures starting with an ictal epileptic headache.¹⁰ In case 1, sodium valproate was administered for the patient's migraine rather than for epileptic attacks, and she was not diagnosed as having definite epilepsy because her convulsions occurred only once; she is suspected to have migraine-triggered seizures.¹⁰

When we diagnose the vestibular disease as MD, of course, we use the diagnostic criteria,⁸ but cVEMP tuning property and gadolinium-enhanced magnetic resonance imaging (MRI) are useful tools for confirming the diagnosis^{3,11} and establishing causative EH. Furthermore, EH(+) or no response in the cVEMP tuning property test corresponds well to EH positivity in the MRI findings.¹² As for VM, these patients present with episodes of spontaneous or positional vertigo lasting from seconds to days that are accompanied by migraine symptoms. Because headache is often absent during acute attacks, other migraine features have to be identified by thorough history taking,

and vestibular testing serves mainly to exclude other diagnoses.¹³ On this point, Murofushi et al.⁴ showed that migraine patients lack habituation (are potentiated) to repetitive stimuli in AMLR. Potentiation to repetitive stimuli has been reported with various evoked potentials in migraine patients.^{14,15} Dysfunction of the raphe nuclei—part of the mesencephalic reticular formation—as well as dysfunction of the thalamocortical pathway and primary auditory cortex, might play a role in the lack of habituation (potentiation) observed in these studies.⁴ The use of AMLR could augment history taking to help confirm the diagnosis of VM in the clinical setting.

Regarding the pathophysiology of VM/MD-OS, neurogenic inflammation caused by migraine episodes might affect inner ear function because the trigeminal nerve innervates the blood vessels in the inner ear.¹⁶ As an alternative hypothesis, genetic ion channel disorders might play a role in VM/MD-OS, especially in patients with migraine with aura or in those with a genetic predisposition.³ The reason why case 2 showed EH(+) in the cVEMP tuning property is unclear. Although migraine attacks might lead to EH in the inner ear, the association between migraine attacks and EH is remaining to be investigated in the future.

Migraine and epilepsy have some overlapping aspects clinically and pathophysiologically.⁵ Migraine–epilepsy comorbidity might be explained by neuronal hyperexcitability, which increases the risk of both diseases. A higher concentration of extracellular glutamate—the main excitatory neurotransmitter—leads to cortical spreading depression (the pathophysiological mechanism underlying the migraine aura) and convulsions.⁵ Channelopathies—especially those involving sodium and potassium ions—might be the pathogenic mechanisms common to both migraine and epilepsy.⁵

We think that AMLR is useful not only when diagnosing patients with VM but also when diagnosing epileptic patients, as seen in case 2, whose potentiation (lack of habituation) is a manifestation of neuronal hyperexcitability.

CONCLUSION

Both cVEMP and AMLR are useful tools for diagnosing patients with vertigo, headache, and epileptic seizure and could help us to understand the underlying pathophysiology in those patients.

Ethics Committee Approval: Ethical committee approval was received from the Ethics Committee of Japanese Red Cross Medical Center (Approval no: 1194).

Informed Consent: Written informed consent was obtained from all subjects participating in the study.

Peer-review: Externally peer-reviewed.

Author Contributions: Concept – H.M., W.N., W.K.; Design – H.M., W.N., W.K.; Materials – H.M., Y.T.; Data Collection and/or Processing – H.M., Y.T.; Literature Search – H.M., W.N., W.K.; Writing – H.M.; Critical Reviews – W.N., W.K.

Declaration of Interests: The authors have no conflict of interest to declare.

Funding: The authors declared that this study has received no financial support.

REFERENCES

1. Lempert T, Neuhauser H. Vertigo as a symptom of migraine. *Med Klin (Munich)*. 2001;96(8):475-479. [\[CrossRef\]](#)
2. Furman JM, Marcus DA, Balaban CD. Vestibular migraine: clinical aspects and pathophysiology. *Lancet Neurol*. 2013;12(7):706-715. [\[CrossRef\]](#)
3. Murofushi T, Tsubota M, Kitao K, Yoshimura E. Simultaneous presentation of definite vestibular migraine and definite Meniere's disease: overlapping syndrome of two diseases. *Front Neurol*. 2018;9:749. [\[CrossRef\]](#)
4. Murofushi T, Goto F, Tsubota M. Vestibular migraine patients show lack of habituation in auditory middle latency responses to repetitive stimuli: comparison With Meniere's disease patients. *Front Neurol*. 2020;11:24. [\[CrossRef\]](#)
5. Zarcone D, Corbetta S. Shared mechanisms of epilepsy, migraine and affective disorders. *Neurol Sci*. 2017;38(Suppl 1):73-76. [\[CrossRef\]](#)
6. Rogawski MA. Common pathophysiologic mechanisms in migraine and epilepsy. *Arch Neurol*. 2008;65(6):709-714. [\[CrossRef\]](#)
7. Papathanasiou ES, Murofushi T, Akin FW, Colebatch JG. International guidelines for the clinical application of cervical vestibular evoked myogenic potentials: an expert consensus report. *Clin Neurophysiol*. 2014;125(4):658-666. [\[CrossRef\]](#)
8. Lopez-Escamez JA, Carey J, Chung WH, et al. Diagnostic criteria for Meniere's disease. *J Vestib Res*. 2015;25(1):1-7. [\[CrossRef\]](#)
9. Lempert T, Olesen J, Furman J, et al. Vestibular migraine: diagnostic criteria. *J Vestib Res*. 2012;22(4):167-172. [\[CrossRef\]](#)
10. Belcastro V, Striano P, Kasteleijn-Nolst Trenité DG, Villa MP, Parisi P. Migraine, hemicrania epileptica, post-ictal headache and "ictal epileptic headache": a proposal for terminology and classification revision. *J Headache Pain*. 2011;12(3):289-294. [\[CrossRef\]](#)
11. Nakada T, Yoshida T, Suga K, et al. Endolymphatic space size in patients with vestibular migraine and Meniere's disease. *J Neurol*. 2014;261(11):2079-2084. [\[CrossRef\]](#)
12. Murofushi T, Tsubota M, Kanai Y, Endo H, Ushio M. Association of cervical vestibular-evoked myogenic potential tuning property test results with MRI findings of endolymphatic hydrops in Meniere's disease. *Eur Arch Otorhinolaryngol*. 2021;278(9):3267-3273. [\[CrossRef\]](#)
13. Lempert T, von Brevern M. Vestibular migraine. *Neurol Clin*. 2019;37(4):695-706. [\[CrossRef\]](#)
14. Afra J, Cecchini AP, De Pasqua V, Albert A, Schoenen J. Visual evoked potentials during long periods of pattern-reversal stimulation in migraine. *Brain*. 1998;121(2):233-241. [\[CrossRef\]](#)
15. de Tommaso M, Ambrosini A, Brighina F, et al. Altered processing of sensory stimuli in patients with migraine. *Nat Rev Neurol*. 2014;10(3):144-155. [\[CrossRef\]](#)
16. Vass Z, Shore SE, Nuttall AL, Miller JM. Direct evidence of trigeminal innervation of the cochlear blood vessels. *Neuroscience*. 1998;84(2):559-567. [\[CrossRef\]](#)