

## Case Report

# Vestibular Schwannoma Presenting with Cough-Induced Vertigo

Jeffrey Walter<sup>ID</sup>, J. Scott Greene<sup>ID</sup>, Arun K. Gadre<sup>ID</sup>

Department of Otolaryngology-Head and Neck Surgery, Vestibular &amp; Balance Center, Geisinger Medical Center, Pennsylvania, USA

ORCID IDs of the authors: J.W. 0000-0001-5570-285X, J.S.G. 0000-0001-9161-9463, A.K.G. 0000-0002-7784-5533.

Cite this article as: Walter J, Greene JS, Gadre AK. Vestibular schwannoma presenting with cough-induced vertigo. *J Int Adv Otol*. 2023;19(1):66-69.

Vestibular schwannomas often present with unilateral hearing loss, tinnitus, or dizziness. Imaging is commonly pursued in individuals with unexplained unilateral sensorineural hearing loss, deterioration in word recognition scores, or persistent tinnitus. We present the case of a 76-year-old male with cough-induced vertigo as his primary presenting symptom. Vestibular testing suggested a right vestibular hypofunction, and a small right-sided vestibular schwannoma was discovered using magnetic resonance imaging. Cough-induced vertigo and associated nystagmus may be a presenting feature of vestibular schwannoma.

**KEYWORDS:** Vestibular schwannoma, vertigo, cough, vestibular

## INTRODUCTION

Vestibular schwannomas (VS) are benign tumors originating from Schwann cells within the vestibular division of the vestibulocochlear (eighth) cranial nerve. Its lifetime incidence is estimated at 1/1000<sup>1</sup> of the population, accounting for approximately 85% of cerebellopontine angle tumors.<sup>2</sup> Although typically benign, tumor growth can pose a risk to surrounding structures with the potential for involvement of other cranial nerves, the cerebellum, and brainstem as well as the development of hydrocephalus. The most common chief presenting complaints in individuals with VS have recently been reported as hearing loss (51.5%), dizziness (17%), and tinnitus (11.2%).<sup>3</sup> Due to slowly progressive compression of the vestibular nerve by the VS, postural instability is more commonly reported than positional or spontaneous attacks of vertigo. In geriatric populations, complaints of postural instability can be related to a wide variety of causes including somatosensory deficiency, visual impairment, vestibular disease, cerebellar ataxia, and muscle weakness. Therefore, the presence of postural instability alone is not considered specific for VS. Imaging to detect VS is commonly pursued based on unexplained unilateral sensorineural hearing loss or tinnitus, often with an inordinate deterioration in word recognition scores. Specific indications to pursue imaging based on complaints of “dizziness” alone are less clear.

There are multiple causes of cough-induced dizziness reported in the literature. Cough-induced vertigo can occur in individuals with “third window” disorders, the most common of which is superior canal dehiscence.<sup>4</sup> The likely mechanism is the transmission of elevated intracranial pressure through the dehiscence resulting in utriculopetal displacement of the cupula when coughing. Cough-induced syncope may also be related to increased intrathoracic pressure, resulting in diminished venous return and cardiac output.<sup>5</sup> Additionally, cough-induced syncope has been occasionally reported in association with Chiari malformation.<sup>6</sup>

This case study describes cough-induced nystagmus and vertigo in an individual with VS. The authors are not aware of this association being reported previously in the literature.

## CASE PRESENTATION

The patient was a 76-year-old male presenting to our multidisciplinary balance center with a 7-month history of vertigo. The patient was seen jointly by 2 of the authors (JW, AKG). Written informed consent for the information presented in this article was obtained from the patient. His primary complaint was episodes of vertigo, lasting 1 minute, induced by coughing. During the cough-induced attacks of vertigo, he reported severe horizontal oscillopsia. Additionally, he complained of mild imbalance with mobility attempts on his feet or with rapid head movement. He did not report any falls associated with his dizziness. There was no history of head

injury or barotrauma preceding the onset of symptoms. He denied positional or spontaneous episodes of dizziness. The patient did not complain of any associated changes in hearing, tinnitus, aural fullness, autophony, or sound-induced dizziness.

Previous care included a consultation with an outside vestibular physical therapist who did not feel that vestibular rehabilitation was indicated. However, the therapist recommended further medical work-up for possible superior semicircular canal dehiscence. Subsequent temporal bone computed tomography (CT) and magnetic resonance imaging (MRI) scans with and without contrast of the internal auditory canals were both reported as being negative for pathology. Consultation with a neurologist was non-yielding for central nervous system involvement, and the patient was referred for further evaluation at our balance center.

Physical examination demonstrated that the external auditory canals were clear and tympanic membranes were normal in appearance. Tuning fork examination revealed the Weber test to be midline and the Rinne test to be positive (air conduction > bone conduction). Gaze holding nystagmus was negative with fixation; however, subtle third-degree left beating nystagmus was observed when fixation was removed using infrared video goggles. Bedside head impulse, head shake, and hyperventilation testing were negative. Mastoid vibration at 100 cycles/s evoked left beating nystagmus on both sides. Nystagmus was not evoked with nasal or glottal Valsalva, tragal pressure, or tone bursts. Loaded Dix-Hallpike<sup>7</sup> and roll testing were negative. Romberg testing was negative with eyes open and closed. Sharpened Romberg testing was also negative with eyes open but positive with eyes closed. Tandem gait was unstable. A moderate degree of sway was observed on a cushioned surface with eyes closed.

The provocation of nystagmus with coughing was then assessed. This was video recorded with the use of infrared video goggles. Vigorous right-beating mixed horizontal and torsional nystagmus, lasting approximately 1 minute, was evoked following, not concurrent

with, forceful coughing. (Video 1) This was repeatable. There was no evidence of cough-induced syncope.

His audiogram revealed mild-to-moderate sensorineural hearing loss bilaterally (Figure 1). Word recognition scores were 92% at 70 decibels (dB) on the right and 96% at 70 dB on the left. Caloric testing elicited a 51% decreased right caloric response (Figure 2) consistent with asymmetric peripheral vestibular function (normal < 20%). Cervical-vestibular evoked myogenic potential responses were unattainable bilaterally. The patient provided copies of previously obtained CT and MRI scans. Despite the radiologic interpretation to the contrary, a lesion consistent with a small VS was noted in the fundus of the right internal auditory canal (Figure 3). The tumor measured 8.0 mm (longitudinal) × 4.0 mm (anteroposterior) × 4.8 mm (craniocaudal).

After discussing management options, the patient elected to have the tumor monitored for growth using serial MRI. Two months following the initial visit to our center, the severity of his symptoms increased, and he unfortunately sustained a non-life-threatening motor vehicle accident, which occurred after coughing. Due to the worsening of symptoms, stereotactic radiosurgery (SRS) was initiated after a consultation with a radiation oncologist. Shortly after completing SRS (25 Gy), the cough-induced dizziness completely resolved; however, he developed a profound right-sided hearing loss. Magnetic resonance imaging suggested an increase in tumor size to 9 mm in the longitudinal axis. Follow-up MRI 1 year later demonstrated a decrease in the size of the lesion. It measured 6.4 mm × 4.0 mm × 4.6 mm. The profound right-sided hearing loss has been permanent to date.

## DISCUSSION

This case demonstrated cough-induced vertigo with nystagmus as the primary presenting complaint in an individual with VS. To our knowledge, this has not been previously reported in the literature.

The mechanism responsible for this phenomenon is unclear. Upon coughing, the nystagmus was irritative with the fast phase


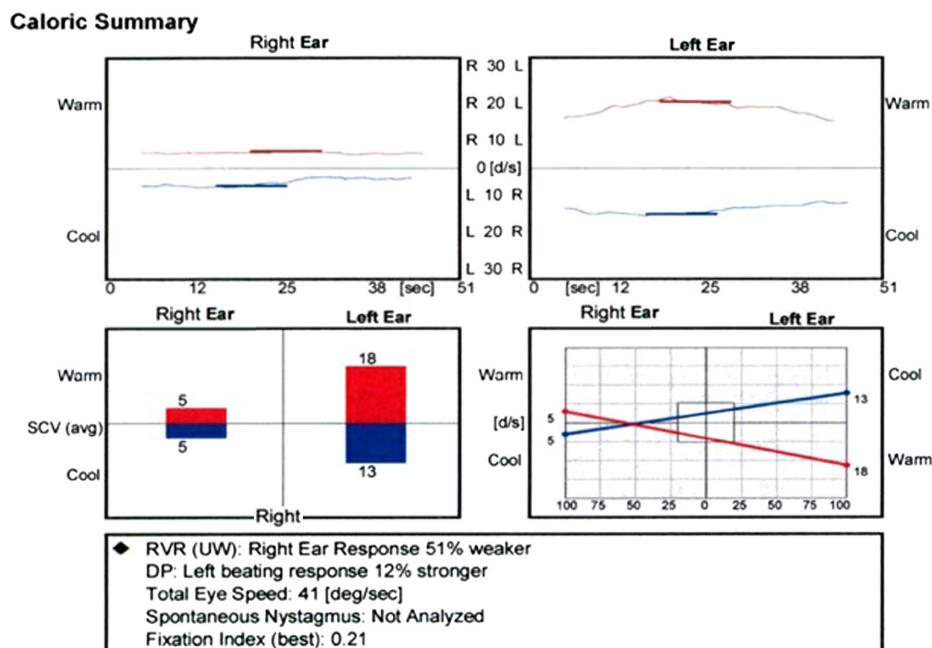
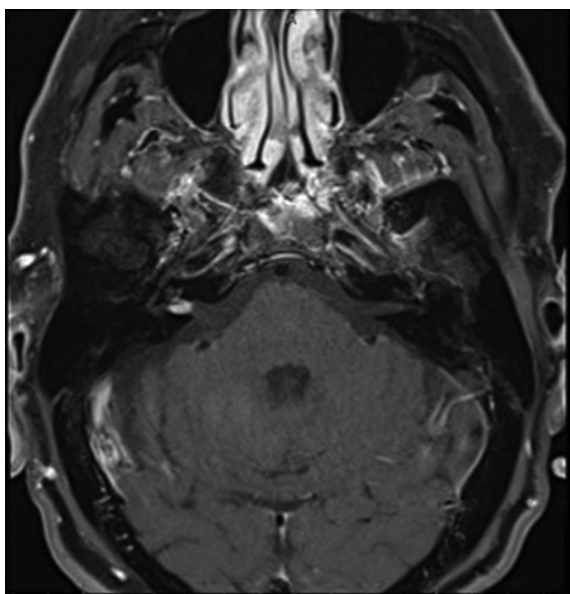


Figure 1. Audiogram demonstrating bilateral mild-to-moderate sensorineural hearing loss.



**Figure 2.** Caloric testing demonstrating a 51% rightward asymmetric response.

beating toward the side of the lesion. There is abundant literature regarding hyperventilation-induced irritative nystagmus in some individuals with VS<sup>8</sup>. Aggressive hyperventilation, completed twice by our patient, did not induce any nystagmus. A third-window disorder was an initial consideration; however, this seemed unlikely as the nystagmus was not time-locked to the coughing. The nystagmus began soon after volitional coughing ceased and lasted nearly 1 minute and was reproducible. Additionally, third window pathology was not observed on high-resolution CT scans. Cardiovascular dizziness is unlikely given the associated nystagmus with cough-induced vertigo. Additionally, the patient did not report any impending sense of loss of consciousness with the vertiginous episodes.



**Figure 3.** Magnetic resonance imaging demonstrating right vestibular schwannoma within the internal auditory canal.

Coughing transiently increases intracranial pressure. We propose that increased compressive forces within the internal auditory canal during coughing may have induced transient neural irritation on the right side resulting in right beating nystagmus. It is interesting that right beating nystagmus occurred even though there was a diminished response on the right side with caloric testing. Vestibular function testing is currently unable to differentiate diminished vestibular end organ function from compromised eighth nerve function. We hypothesize that the source of the cough-induced irritative nystagmus was likely momentary eighth nerve hyperexcitability. Cough-induced nystagmus as an epiphenomenon unrelated to VS seems very doubtful. There was clearly substantial evidence of vestibular hypofunction on the involved side with vestibular testing. Additionally, the cough-induced nystagmus resolved in tandem with the loss of hearing on the involved side.

Dizziness is frequently multifactorial and is a very common complaint within the general population. The presence of cough-induced vertigo or dizziness may be a presenting feature of VS and should signal the need for further targeted imaging tests. Although this is an interesting case, it is unclear how frequently this phenomenon may be associated with VS. Further investigation to discern the frequency of cough-induced nystagmus in individuals with VS would be a suggested focus of further research. Identification of specific clinic scenarios where VS may be more likely is critical to cost-effective care.

## CONCLUSION

Cough-induced vertigo may be an atypical presenting complaint in individuals with VS.

**Informed Consent:** Written informed consent was obtained from the patient for the information and video utilized in the article.

**Peer-review:** Externally peer-reviewed.

**Author Contributions:** Analysis and/or Interpretation – J.W., A.K.G.; Literature Review – J.W., A.K.G.; Writing Manuscript – J.W., A.K.G.; Critical Review – A.K.G., J.S.G.

**Declaration of Interests:** The authors declare that they have no competing interest.

**Funding:** The authors declared that this study has received no financial support.

**Video URL:** Intense mixed right horizontal, torsional nystagmus evoked following forceful coughing. <https://www.youtube.com/watch?v=f4vFgUuxgV4&t=43s>

## REFERENCES

1. Evans DG, Moran A, King A, Saeed S, Gurusinghe N, Ramsden R. Incidence of vestibular schwannoma and neurofibromatosis 2 in the North West of England over a 10-year period: higher incidence than previously thought. *Otol Neurotol*. 2005;26(1):93-97. [\[CrossRef\]](#)
2. Singh K, Singh MP, Thukral C, Rao K, Singh K, Singh A. Role of magnetic resonance imaging in evaluation of cerebellopontine angle schwannomas. *Indian J Otolaryngol Head Neck Surg*. 2015;67(1):21-27. [\[CrossRef\]](#)
3. Peris-Celda M, Graffeo CS, Perry A, et al. Main symptom that led to medical evaluation and diagnosis of vestibular schwannoma and patient-reported tumor size: cross-sectional study in 1,304 patients. *J Neurol Surg B Skull Base*. 2019;80(3):316-322. [\[CrossRef\]](#)
4. Minor LB, Solomon D, Zinreich JS, Zee DS. Sound- and/or pressure-induced vertigo due to bone dehiscence of the superior semicircular canal. *Arch Otolaryngol Head Neck Surg*. 1998;124(3):249-258. [\[CrossRef\]](#)
5. Dicipinigaitis PV, Lim L, Farmakidis C. Cough syncope. *Respir Med*. 2014;108(2):244-251. [\[CrossRef\]](#)
6. Oliveira IC, Carvalho J, Oliveira L. Cough syncope, a rare presenting symptom of Chiari I malformation and atlanto-occipital assimilation. *Eur J Case Rep Intern Med*. 2020;7(4):001466. [\[CrossRef\]](#)
7. Andera L, Azeredo WJ, Greene JS, Sun H, Walter J. Optimizing testing for BPPV - the loaded Dix-Hallpike. *J Int Adv Otol*. 2020;16(2):171-175. [\[CrossRef\]](#)
8. Califano L, Iorio G, Salafia F, Mazzone S, Califano M. Hyperventilation-induced nystagmus in patients with vestibular schwannoma. *Otol Neurotol*. 2015;36(2):303-306. [\[CrossRef\]](#)