

ORIGINAL ARTICLE

Transmastoid Decompression of Labyrinthine-Meatal Segment of the Facial Nerve: A Comparative Radio-Anatomic Study

Bahar Keles, Dilek Emlik, Yavuz Uyar, Aynur Emine Cicekcibasi, Kayhan Ozturk

Department of Otorhinolaryngology and Head&Neck Surgery, Meram Medical Faculty, Selcuk University, (BK, YU, KO) Konya, Turkey.

Department of Radiology, Meram Medical Faculty, Selcuk University, (DE) Konya, Turkey.

Anatomy, Meram Medical Faculty, Selcuk University, (AEC) Konya, Turkey.

Objective: To evaluate the routes for approaching to labyrinthine-meatal segment of the facial nerve (FN) via transmastoid approach by drilling the ampullar ends of the lateral semicircular canal (LSC).

Materials and Methods: Ten temporal bones of adult cadavers underwent high-resolution computed tomography (HRCT). Among them in 6 temporal bones the FN was decompressed under operating microscope via transmastoid approach by drilling the ampullar ends of the LSC. Within the remaining four of temporal bones the ampullary ends of the LSC were preserved. All temporal bones were re-evaluated by HRCT scans following the dissection. Distances between labyrinthine-meatal segment and surrounding anatomical landmarks were measured through the HRCT scans.

Results: The mean distances from labyrinthine-meatal segment to the midpoint of the basal turn of the cochlea, LSC and vestibule were 9.5 ± 0.6 mm (range 8.1-10.4), 10.1 ± 1.2 mm (range 8.5-11.9 mm), 2.6 ± 0.4 mm (range 1.9-3.2 mm), respectively. The mean distance of remaining bony part of fallopian canal near the meatus was determined as 0.57 ± 0.3 mm in the temporal bones drilled from the ampullary ends of the LSC and 2.07 ± 0.5 mm in the temporal bones preserved from ampullary ends of the LSC. This difference was significant ($p < 0.05$).

Conclusions: The results showed that the labyrinthine-meatal segment of the FN could be adequately accessed via transmastoid approach by skeletonizing the ampullary end of the LSC. This approach may be used as an alternative technique in the decompression of labyrinthine-meatal segment of the FN.

Submitted : 20 October 2008

Revised : 25 March 2009

Accepted : 25 March 2009

Knowing the facial nerve (FN) anatomy is important for ENT surgeons especially when the FN or fallopian canal is involved in several diseases. The labyrinthine segment of the facial nerve is its shortest segment and the nerve has the smallest diameter in this segment (0.68 mm).^[1] This part of the nerve is most vulnerable to stress as having also poor blood supply. Even the lesions may influence FN within any part of the fallopian canal, the labyrinthine segment is the segment mostly involved.^[2,3] The labyrinthine segment as surrounded by the cochlea and the superior semicircular canal creates difficulty to manage and middle fossa approach is preferred to keep the hearing intact. However, craniotomy through the middle fossa and its possible risks, such cerebrospinal fluid leak,

intracranial hemorrhage, epilepsy and meningitis can be a deterrent factor for the patient. Additionally the lack of consistent landmarks may limit the approach especially for the inexperienced surgeons^[4]. In this regard some new transmastoid approaches preserving hearing and without craniotomy were suggested^[5-10]. The extra-labyrinthine transmastoid approach was described by Salaverry and later by May and Zini. With this technique the labyrinthine-meatal segment of FN was exposed by drilling the medial attic wall anteriorly towards the superior semicircular canal and LSC^[5-7]. The FN could be exposed from the stylomastoid foramen until a few millimeters to meatal foramen keeping the labyrinth intact. Yanagihara et al. described extended transmastoid approach to

Corresponding address:

Bahar Keles

Selcuk Universitesi, Meram Tip Fakultesi Kulak Burun Bogaz Hastaliklari Servisi
42080 Meram, Konya, TURKEY

Tel: +90 332 2236646; Fax: +90 332 3236181; E-mail: baharkeles@hotmail.com

Copyright 2005 © The Mediterranean Society of Otolaryngology and Audiology

decompress the FN on more than two hundred patients.^[8] They reported that their technique allowed a wide exposure of entire horizontal segment, the geniculate ganglion, and lateral half of the labyrinthine segment by removing the incus and supralabyrinthine cells^[8-10]. In contrast, Fish and many others recommended the middle fossa approach for the labyrinthine-meatal segment of the FN, because of the limited access by transmastoid routes to the labyrinthine-meatal segment^[9,10]. The goal of the present study was to evaluate if the approach to the labyrinthine-meatal segment of the FN could be possible by drilling ampullar ends of the LSC via transmastoid approach using anatomic and radiologic data.

Materials and Methods

Ten adult temporal bones were used for transmastoid dissection. A complete mastoidectomy and posterior hypotympanotomy were performed followed by the identification of LSC, sigmoid sinus, the middle fossa dural plate and digastric ridge. The facial recess was reached. The incudal fossa was exposed. Incus was removed to obtain wider exposure to geniculate ganglion and tympanic segment (Figure 1). Following the decompression of tympanic segment,

supralabyrinthine cells were removed to reach to geniculate ganglion and labyrinthine segment. Ampullary ends of the LSC in 6 temporal bones were skeltonized until the the blue line was identified (Figure 1). In the remaining four temporal bones the ampullar ends were preserved. Skletonization of the LSC ampulla provided wider angle to the labyrinthine-meatal segment. Incus was reinserted between the malleus and stapes following the decompression (Figure 2).

Radiological Examination

All of the temporal bones were scanned by axial and coronal HRCT before and after dissection by using GE Hi-Speed CTI scanner (GE Medical Systems, Milwaukee, WI). The scanning parameters were: 120 kV, 200 mA (axial and coronal), 1-mm slice thickness, zero interslice gap, 512 x 512 matrix and bone algorithm. All parameters described below were measured and converted into millimetric scales. The distances between labyrinthine-meatal segment and surrounding landmarks were evaluated including remaining bone of the fallopian canal nearby the meatus. This distance was compared with temporal bones with skeltonized ampulla of the LSC and the remaining four bones.

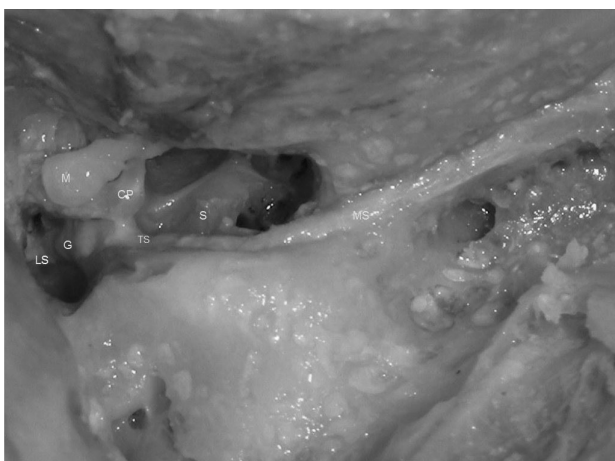


Figure 1. View of the FN from labyrinthine-meatal segment to mastoid segment, and the drilling of the ampullaceous end of the LSC after incus was removed. LS; Labyrinthine segment, G; Ganglion geniculate, TS; Tympanic segment, MS; Mastoid segment, M; Malleus, CP; Cochleiform process, S; Stapes.

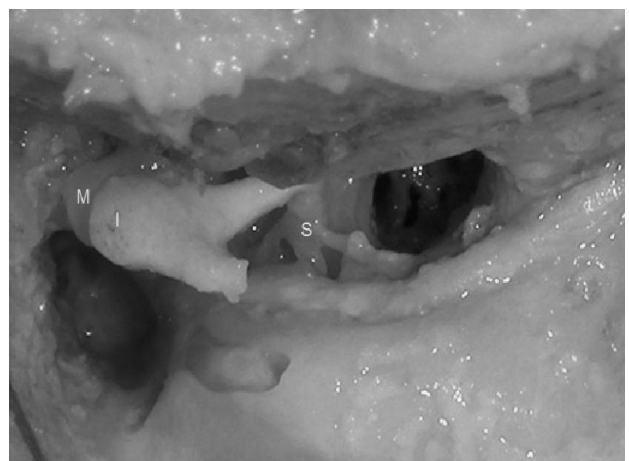

Figure 2. View of the incus (I) repositioned between the malleus (M) and stapes (S) after transmastoid decompression of the FN

Measurements:

1. LS: Length of labyrinthine segment.
2. LS-C: Labyrinth segment to midpoint of the basal turn of the cochlea.
3. LS-LSC: Labyrinth segment to lateral semicircular canal.
4. LS-V: Labyrinth segment to vestibule.
5. LS-TS: Angle between the LS and the tympanic segment (TS) in the geniculate fossa.
6. Remaining bony part near the meatus.

Statistical Analysis

Overall descriptive statistics were calculated. Data were analyzed with Mann-Whitney U test in the SPSS 13.0. Statistical significance was considered as $p < 0.05$. The study was approved by The Ethical Committee of Selcuk University, Konya, Turkey.

Results

The labyrinthine-meatal segment of the FN was demonstrated in all of the axial scans before transmastoid decompression (Figure 3). It was located just behind the anterior wall of the petrous part of the temporal bone and between cochlea and vestibule in all temporal bones. LSC was seen on the same axial plane (Figure 3). The mean length of labyrinthine-meatal segment was determined as 36.8 ± 3.9 mm (range 31.5-

42 mm) (Table 1, Figure 4). The mean distance between LS and the midpoint of the basal turn of the cochlea was found 9.5 ± 0.6 mm (range 8.1-10.4). The mean distance between LS and LSC was 10.1 ± 1.2 mm (range 8.5-11.9 mm). The mean distance between LS and vestibule was 2.6 ± 0.4 mm (range 1.9-3.2 mm) (Table 1, Figure 5). The mean angle between the LS and the tympanic segment was $75.9 \pm 3.5^\circ$ (range $67.8-81^\circ$) (Table 1, Figure 6). The mean distance of remaining bony part of fallopian canal near the meatus in the temporal bones drilled from the ampullary ends of the LSC and in the temporal bones preserved from the ampullary ends of the LSC was measured as 0.57 ± 0.3 mm (range 0.10-0.91 mm) and 2.07 ± 0.5 mm (range 1.4-2.6 mm), respectively (Table 2, Figure 7). This distance was significantly shorter in the temporal bones drilled from the ampullary end of the LSC than in the temporal bones preserved from the ampullary ends of the LSC ($p < 0.05$).

Discussion

Frayse et al. performed extralabyrinthine transmastoid approach in the 30 temporal bones. They reported that internal auditory meatus was reached in 50% of the temporal bones via extralabyrinthine mastoid approach. The presence of 0.2-1.2 mm of bone

Table 1. Measurements of labyrinthine segment from high resolution computed tomography (HRCT)

Measurements	Temporal Bones No.										Mean +SD
	1.	2.	3.	4.	5.	6.	7.	8.	9.	10.	
LS (mm)	33.2	31.7	35.9	31.5	37.9	35.8	40.9	37.3	41.7	42	36.8 ± 3.9
LS-C (mm)	9.7	10.4	9.8	9.4	9.6	8.1	10.3	9.3	9.9	9	9.5 ± 0.6
LS-LSC (mm)	9.5	11.5	9.8	10.4	9.9	8.5	8.6	9.8	11.9	11.4	10.1 ± 1.2
LS-V (mm)	3.2	2.1	1.9	3.0	2.8	2.9	2.7	2.8	2.3	2.2	2.6 ± 0.4
Angle between LS and TS ($^\circ$)	77	75	75.4	79	77.7	74.7	67.8	75.3	81	77	75.9 ± 3.5

LS: Labyrinthine segment, C: Cochlea, LSC: Lateral semicircular canal, V: Vestibule, TS: Tympanic segment.

Table 2. Distance of the remaining bony part of fallopian canal near the meatus

	Temporal Bones No.						Mean +SD	p
	1.	2.	3.	4.	5.	6.		
Drilled from ampullary ends of the LSC (mm)	0.68	0.10	0.59	0.91	0.52	0.62	0.57 ± 0.3	0.01
Preserved from ampullary ends of the LSC (mm)	2.6	2.4	1.4	1.9			2.07 ± 0.5	

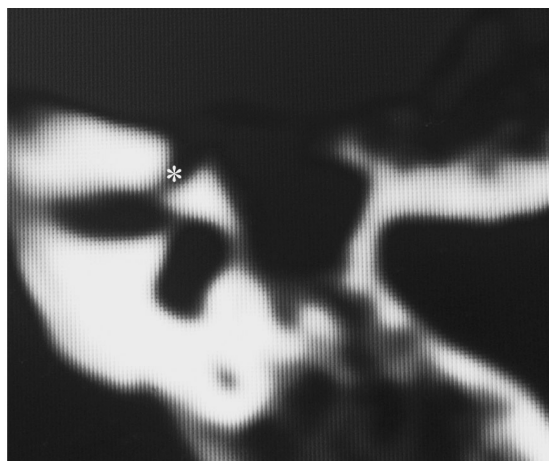


Figure 3. View of the LS of the FN (*) on the axial temporal bone HRCT scan before transmastoid decompression.

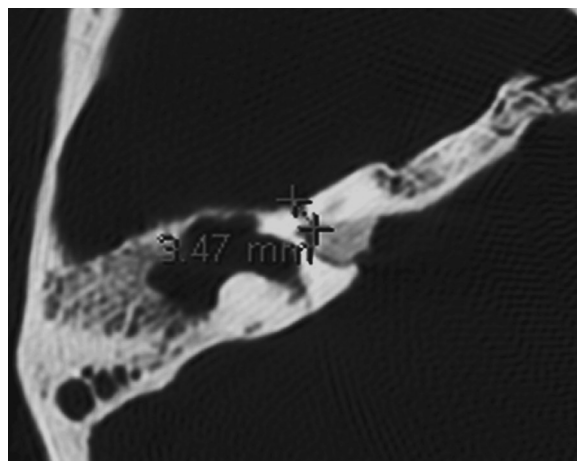


Figure 4. The length of the LS of the FN on the axial temporal bone HRCT scan.

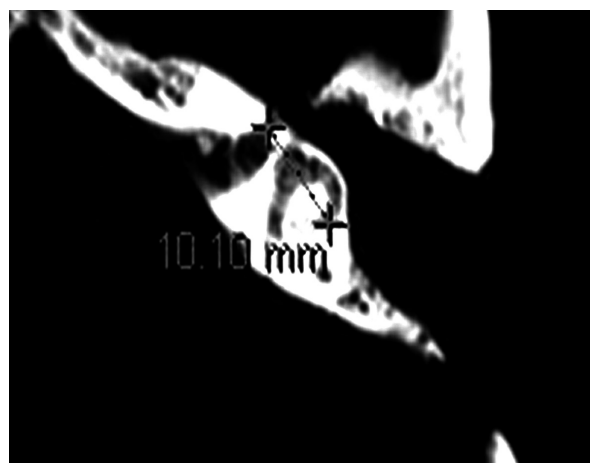
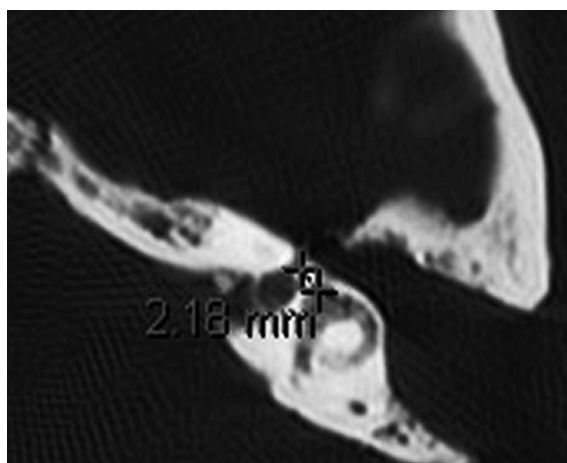


Figure 5. The distance of between the LS and the vestibule (a) and the LSC (b) on the axial temporal bone HRCT scan.

was mentioned ^[11]. Similarly, in the present study, the distance of remaining bony part of fallopian canal near the meatus was determined as 0.57 mm in the temporal bones drilled from the ampullary end of the LSC and 2.07 mm in the temporal bones preserved from the ampullary end of the LSC.

On the other hand, clinical studies supported that labyrinthine meatal segment of the FN was adequately exposed via transmastoid approach. May et al. suggested that the geniculate ganglion and labyrinthine segment of the FN could be explored via transmastoid, extralabyrinthine, and subtemporal approach in patients with Bell's palsy ^[6]. Additionally,

Yanagihara et al. performed decompression from the labyrinthine segment to the stylomastoid foramen via transmastoid approach in 58 patients. Significantly better recovery with facial decompression was reported in this study with no serious complications ^[12]. Quaranta et al. used transmastoid extralabyrinthine approach in patients with traumatic facial paralysis. Normal and subnormal FN function (HB 1 or HB 2) was achieved in 78% of patients within one year after surgery ^[13]. Additionally, Goin and Dubarry et al. confirmed suggested that the end of the internal auditory meatus can be reached via extralabyrinthine transmastoid approach ^[14,15].

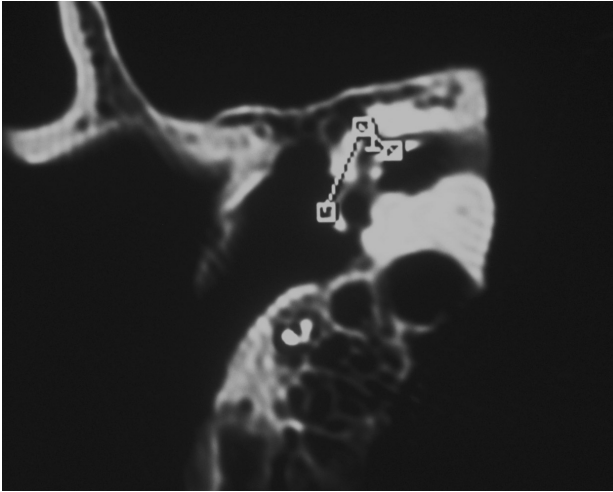


Figure 6. The angle of between LS and tympanic segment of the FN on the axial temporal bone HRCT scan.

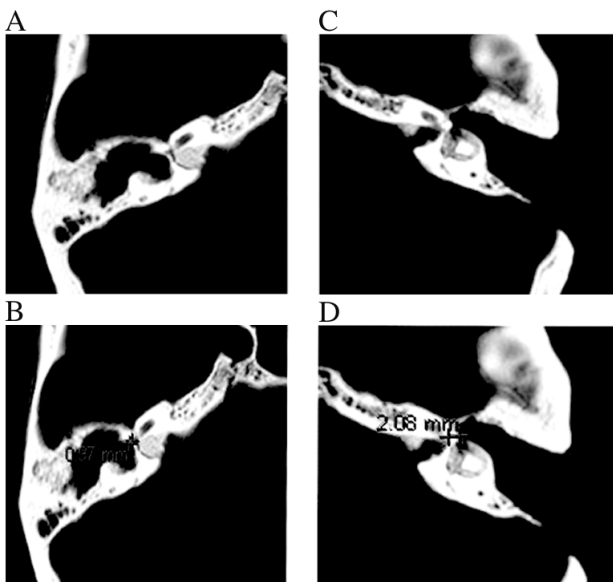


Figure 7. (a,b), The distance of remaining bony part of fallopian canal near the meatus in the temporal bones drilled from the ampullary end of the LSC. (c,d), The distance of remaining bony part of fallopian canal near the meatus in the temporal bones preserved from the ampullary end of the LSC.

The morbidities that come up with transmastoid approach to the labyrinthine segment of the facial nerve show themselves with hearing loss (either conductive or sensorineural) and vestibular dysfunction. The removal of incus to avoid trauma to stapes and gain space will cause conductive type of hearing loss even it is reinserted at the end of the surgery. Previous studies demonstrated that hearing returns to normal or preoperative levels within 6

months when the incus is repositioned exactly between the intact malleus and stapes^[8,11,12]. In such a case establishing the contacts between incudostapedial and incudomalleolar joints by using fibrine glue or calcium phosphate bone cement may help reducing the postoperative air bone gaps. Sensorineural hearing loss and vestibular dysfunction are serious complications of this approach as of the ampullae of LSC can be injured during skeletonization. There have been clinical and experimental studies concerning that the semicircular canals can be manipulated without hearing loss^[16,17]. Realtime ABR monitorization may help on preserving the labyrinthine functions. In case of an injury directed to labyrinthine membranes, occlusion of the semicircular canal may help on preserving the hearing.^[17-18]. The good hearing results that comes out with the occlusion of the posterior semicircular canal performed for treating the intractable benign paroxysmal positional vertigo (BPPV) can be a satisfactory explanation of occlusion.^[19,20]. Shai et al. reported mild hearing loss in one case out of 28 patients who received posterior semicircular occlusion.^[21]

Anatomic relation between labyrinthine-meatal segment of the FN and surrounding structures such as cochlea and vestibular system is important to deal with and being familiar to this anatomic relationship is necessary to avoid surgical damage. HRCT may help on constructing the three dimensional relationship in minds.

The results show that labyrinthine-meatal segment of the FN could be accessed via transmastoid approach by skeletonizing the ampullary ends of the LSC. This approach may be performed as an alternative technique to middle fossa approach. It is necessary to drill around the ampullary ends of the LSC carefully to avoid sensory neural hearing loss or vestibular dysfunction. Incus should be repositioned meticulously between the malleus and stapes to avoid conductive hearing loss.

References

1. May M. Anatomy for the clinician. In: May M. The Facial Nerve. New York: Thieme press 2000:19-56.

2. Phillips CD, Bubash LA. The facial nerve: Anatomy and common Pathology. *Semin Ultrasound CT MR* 2002; 23:202-17.
3. Jager L, Reiser M. CT and MR imaging of the normal and pathologic condition of the facial nerve. *Eur J Radiol* 2001; 40:133-46.
4. Gantz BJ, Redleaf MI. Management of Bell's palsy and Ramsay Hunt Syndrome. In: Brackmann DE., Shelton C, Arriaga MA. *Otologic Surgery*. Philadelphia. W.B. Saunders Press. 1994: 385-95.
5. Salaverry MA. Transattical approach. A technique variation for total decompression of the facial nerve. *Rev Brasil de Oto-Rhino-Laryngol* 1974; 49: 262-4.
6. May M. Total facial nerve exploration: transmastoid, extralabyrinthine, and subtemporal indications and results. *Laryngoscope* 1979; 89:906-17.
7. Zini C, Sanna M, Jemmi G, Gandolfi A. Transmastoid extralabyrinthine approach in traumatic facial palsy. *Am J Otol* 1985; 6:216-321.
8. Yanagihara N. Transmastoid decompression of the facial nerve using supralabyrinthine approach. In: Portmann M. *Facial Nerve*. New York. Masson Press 1985; 479-81.
9. Fish U. Surgery for Bell's palsy. *Arch Otolaryngol* 1981; 107:1-11.
10. Glasscock ME, House WF, Alford BR. Middle fossa facial nerve decompression. *Ann Otol Rhinol Laryngol* 1970; 79:234-40.
11. Fraysse B, Dubarry B, Lecomme Y. The extralabyrinthine mastoid approach route to the facial nerve. In: Portmann M. (ed), *Facial Nerve*. Masson Publishing; USA. 1985:487-90pp.
12. Yanagihara N, Hato N, Murakami S, et al. Transmastoid decompression as a treatment of Bell palsy. *Otolaryngol Head Neck Surg* 2001; 124:282-7.
13. Quaranta A, Campobasso G, Piazza F, Quaranta N, Salonna I. Facial nerve paralysis in temporal bone fractures: outcomes after late decompression surgery. *Acta Otolaryngol.* 2001; 121:652-5.
14. Goin DW. Proximal intratemporal facial nerve in Bell's palsy surgery. A study correlating anatomical and surgical findings. *Laryngoscope* 1982; 92,263-72.
15. Dubarry B., Fraysse B. Exploration of the labyrinthine portion of the facial nerve using the prelabrynth transmastoidal approach. Preliminary anatomic study. *Rev Laryngol Otol Rhinol* 1982; 103, 427-9.
16. Nam BH, Park CI, Jung TT. Early histopathologic changes after lateral semicircular canal transection and occlusion in guinea pigs. *Ann Otol Rhinol Laryngol* 2002; 111,402-6.
17. McElveen JT Jr, Wilkins RH, Molter DW, et al. Hearing preservation using the modified translabyrinthine approach. *Otolaryngol Head Neck Surg* 1993; 108:671-9.
18. Smouha EE, Namdar I, Michaelides EM. Partial labyrinthectomy with hearing preservation: an experimental study in guinea pigs. *Otolaryngol Head Neck Surg* 1996; 114:777-84.
19. Walsh RM, Bath AP, Cullen JR, et al. Long-term results of posterior semicircular canal occlusion for intractable benign paroxysmal positional vertigo. *Clin Otolaryngol Allied Sci* 1999; 24:316-23.
20. Zappia JJ. Posterior semicircular canal occlusion for benign paroxysmal positional vertigo. *Am J Otol* 1996; 17:749-54.
21. Shaia WT, Zappia JJ, Bojrab DI, et al. Success of posterior semicircular canal occlusion and application of the dizziness handicap inventory. *Otolaryngol Head Neck Surg* 2006; 134: 424-30.