

CASE REPORT

Congenital Cholesteatoma in the Mastoid Cavity

Kai-Chieh Chan, Jen-Liang Su, Che-Ming Wu

Department of Otolaryngology, Chang Gung Memorial Hospital, Chang Gung University, Taipei, Taiwan

Congenital cholesteatoma may arise from various sites within the temporal bone including the petrous apex, the cerebellopontine angle, the mastoid, the middle ear and the external auditory canal. Of these, the mastoid cavity is the least frequent site of origin. Herein, we report an extremely rare case of congenital cholesteatoma of mastoid origin with extension into the epitympanum and presentation of conductive hearing loss. Computed tomography (CT) displayed anatomic anomalies including ossicular erosion, exposure of the dura, and dehiscence and exposure of the facial nerve. This patient was successfully treated with canal wall up mastoidectomy with ossicular reconstruction. The hearing threshold showed significant improvement, and there has been no recurrence during 18 month-follow-up.

Submitted : 14 July 2008

Revised : 09 April 2009

Accepted : 09 April 2009

Congenital cholesteatoma (CC) was first introduced by Luchae in 1885. CC is much less common than acquired cholesteatoma, and it accounts for 2% to 5% of all cholesteatomas.^[1] Although the incidence of CC seems to be increasing, this may be the result of improved imaging techniques and increased awareness among clinicians.

CC has been reported to originate from various locations in the temporal bone. The most frequent site is the middle ear, whereas the rarest is the mastoid cavity.^[2] To the best of our knowledge, only one series study (nine cases) and nine separate cases of CC of mastoid origin have been reported in the English literature.^[3-11] The clinical presentations of the mastoid CC vary depending on the extent of the disease and include conductive hearing loss, disequilibrium, neck pain and neural manifestations. Radiologic findings by computed tomography (CT) and/or magnetic resonance imaging (MRI) are invaluable in the diagnosis of this rarely occult lesion and also in identification of its extension with associated anatomic anomalies such as exposure of the dura or facial nerve,

ossicular erosion, dehiscence of the sigmoid sinus plate or compression of the cerebellum. Thus, careful preoperative evaluation by imaging is crucial to determine the appropriate surgical approach and prevent significant complications intraoperatively.

Case Report

A 17-year-old female patient presented with a 6-month history of progressive hearing impairment in the right ear. There was no history of ear infection, otorrhea, ear surgery, dizziness, tinnitus, facial weakness or other otologic complaints. Otoscopic examination revealed apparently normal tympanic membranes in both sides. The pure tone audiometry showed 70 dB-conductive hearing loss with an air-bone gap of 65dB in the right ear and 15 dB threshold in the left ear. Acoustic impedance measurement yielded a "type As" tympanogram in both ears. The computed tomography (CT) scan of the temporal bone revealed a large, dense soft-tissue density lesion occupying the whole mastoid cavity and extension to the epitympanum with ossicular erosion (Figure 1). Bony dehiscence of the tegmen mastoideum and the mastoid segment of the

Corresponding address:

Che-Ming Wu
Department of Otolaryngology
Chang Gung Memorial Hospital 5, Fu-Shin Street, KweishanTaoyuan 333, Taiwan
Phone: 886-3-3281200 ext.3967; Fax: 886-3-3979361; E-mail: bobwu506@seed.net.tw

Copyright 2005 © The Mediterranean Society of Otolaryngology and Audiology

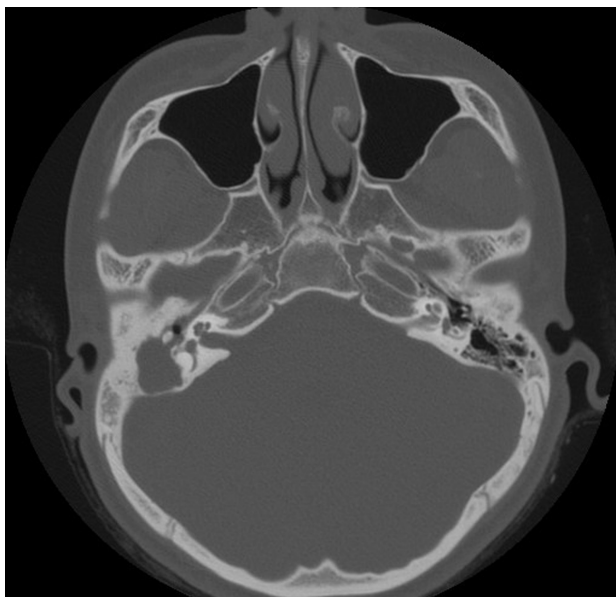
facial nerve canal was also identified (Figure 2). Under the impression of mastoid tumor with epitympanic extension, a canal wall up mastoidectomy (via postauricular approach) was performed. During the surgery, the mastoid pneumatization appeared poorly to moderately developed. The mastoid cavity was filled with a huge cholesteatoma containing a considerable amount of keratinous matrix. The tegmen mastoideum appeared to be partially dehiscence, and most part of the mastoid segment of the facial nerve was found exposed. However, the labyrinthine fistula was not observed. Besides, the malleus head and incus short process were also encased tightly by the cholesteatoma matrix. Nevertheless, the mesotympanum was free of cholesteatoma extension. Thus, the huge cholesteatoma lesion was completely removed along with the malleus head and incus. Ossicular reconstruction with partial ossicular replacement prosthesis (PORP) between the stapes head and malleus handle was performed subsequently. The postoperative course was uneventful, and the definitive diagnosis of cholesteatoma was made. The patient's hearing threshold improved to 40 dB with an air-bone gap of 35 dB, and there was no evidence of recurrence over 18 months of follow-up.

Discussion

Many studies have been put forward to explain the origin of CC; however, none of them so far have convincingly shown the exact pathogenesis of CC in the temporal bone. The epithelial rest theory is the most widely accepted for the middle ear; nevertheless, it has not been quoted for the mastoid cavity. Another explanation involves the implantation of epithelium in the sutures surrounding the mastoid.^[12] It was proposed that ectoderm gets caught in the suture during the closure of the mastoid fontanelle, because the skin, periosteum and dura contact one another at this point, and thus, trapping of epithelium can occur.

Mastoid CC tends to occur in adult patients, whereas CC in the middle ear usually presents at an earlier age. This is thought to be due to the fact that CC in the middle ear is easier to detect and more commonly presents with hearing loss, ossicular erosion, and abnormal otoscopic findings of a retrotympanic whitish mass. However, mastoid CC is difficult to detect early unless it extends to the surrounding structures because of its quiescent characteristics and variable presentations.^[3] Mastoid CC that has extended into the epitympanum with involvement of the middle

A



B

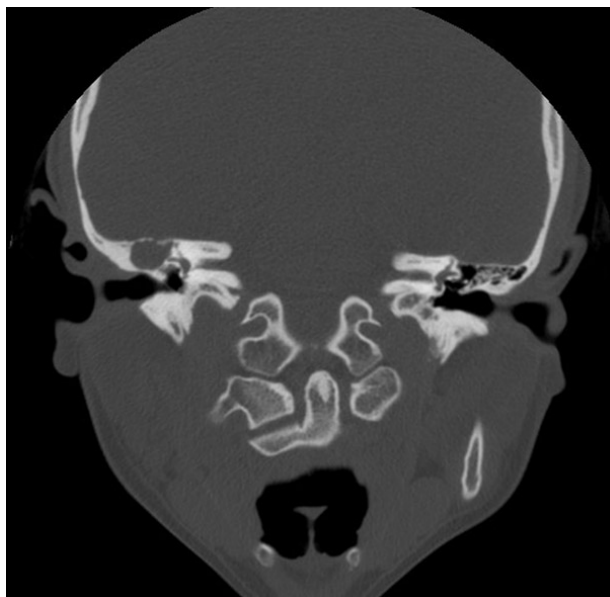


Figure 1. Axial view (a.) and coronal view (b.) of computed tomography scan of the temporal bone showing a mastoid soft tissue density mass with epitympanic extension and ossicular involvement.

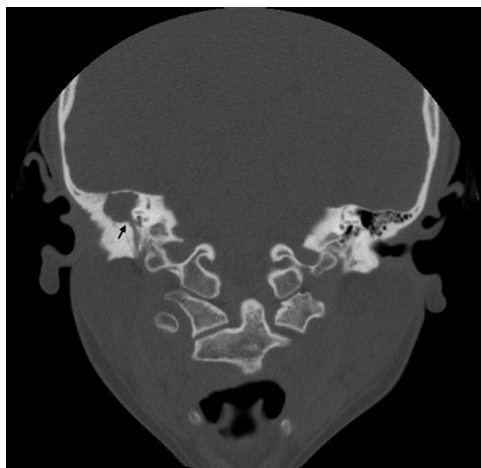


Figure 2. Computed tomography scan of the temporal bone (coronal view) showing bony dehiscence of tegmen mastoideum and the mastoid segment of facial nerve (arrow)

ear will present with hearing loss or otalgia, such as in our present case. Erosion of the mastoid cortex when the disease involves the periosteum may present retroauricular pain or neck pain.^[5,8,10] As the disease extends beyond the mastoid, it will present as a retromastoid swelling.^[6,10] Expansion into the posterior cranial fossa with compression of the cerebellum will manifest as disturbed balance.^[8,9] Bony fistulae arising from erosion of the external auditory canal will lead to discharge from the ear.^[5] In reviewing the literature,^[3-11] we found that mastoid CC presented most often with pain (neck pain or otalgia), or it was discovered as an incidental finding. Conductive hearing loss was the second most common sign.

The diagnosis of the mastoid CC with extension into the epitympanum is sometimes difficult to make. If the mastoid CC has extensive involvement of the middle ear, it becomes impossible to discriminate whether it originates from the mastoid or middle ear. Therefore, the accurate diagnosis of the mastoid CC with epitympanic involvement should be made with a combination of radiologic imaging and intraoperative findings. In our case, the tympanic membrane appeared normal without retrotympanic mass, and the cholesteatoma matrix was found to locate mainly in the mastoid cavity with limited epitympanic involvement. Therefore, we believe that its origin was the mastoid cavity rather than the middle ear. As for the spreading route of epitympanic extension, we suggest that it

should be from the mastoid antrum through aditus ad antrum and/or superior incudal space to the epitympanum.

CT imaging studies of the mastoid CC are essential and diagnostic, whereas MRI is an additional tool to confirm the definite diagnosis preoperatively. In our case, CT revealed an expansive mastoid soft-tissue density with bony erosion of the ossicular chain, tegmen mastoideum and facial nerve canal. Differential diagnosis of this radiologic finding should include cholesterol granuloma, anomalous sigmoid sinus and neoplasm.^[13] On MRI, cholesterol granuloma can be distinguished by the bright signal intensity in both T1- and T2-weighted images. CC, which is low on T1 and high on T2, does not produce increased signal with gadolinium during MRI unlike meningioma, schwannoma, or other metastatic lesions. An MRI venogram can facilitate the differentiation of an anomalous sigmoid sinus.^[17]

Intraoperative findings in our case revealed partial erosion of the dural plate, ossicular erosion and exposure of the mastoid segment of the facial nerve. These aforementioned anatomic anomalies were also observed by Warren et al.^[3], who stated that there was a notable discrepancy between the mastoid-only group (5 cases) and mastoid with the epitympanic extension group (4 cases) in intraoperative findings, however, the mastoid-only group had a higher incidence of dural exposure, facial nerve exposure and external canal erosion. Most often, these anatomic anomalies could be detected preoperatively by CT image, especially through the bony destruction of vital structures. In addition, MRI is indicated if the lesion has intracranial involvement. Thus, meticulous preoperative evaluation of the mastoid CC by imaging for these pitfalls is imperative and helpful for an otologist to choose the proper surgical approach and minimizes major intraoperative complications. If the disease is limited to the mastoid and middle ear, a tympanoplasty with mastoidectomy approach can be taken, such as in our case. If the disease is more extensive with exposure of dura, sigmoid sinus or the facial nerve, a transtemporal approach, can be planned with preparation for autologous fat grafting^[13].

Conclusion

Although the mastoid CC is unusual and its presentations are variable, one should bear in mind the differential diagnosis of this rare entity with the epitympanic extension when encountering a patient who has a normal tympanic membrane with conductive hearing loss. Preoperative image studies with CT and/or MRI will help surgeons to make differential diagnoses, define the extent and associated anatomic anomalies of the lesion, and determine the appropriate surgical management.

References

1. Paparella M, Ryback L. Congenital cholesteatoma. *Otolaryngol Clin North Am* 1978; 11:113-20
2. Nager GT. Pathology of the ear and temporal bone. Baltimore: Williams & Wilkins; 1993. p.710-42
3. Warren FM, Bennett ML, Wiggins RH 3rd, Saltzman KL, Blevins KS, Shelton C, et al. Congenital cholesteatoma of the mastoid temporal bone. *Laryngoscope* 2007; 117:1389-94
4. Lee JH, Hong SJ, Park CH, Jung SH. Congenital cholesteatoma of mastoid origin. *J Laryngol Otol* 2007; 121: e20. Epub 2007 Oct 12.
5. Rashad U, Hawthorne M, Kumar U, Welsh A. Unusual cases of congenital cholesteatoma of the ear. *J Laryngol Otol* 1999; 113:52-4.
6. Cüreoglu A, Osma U, Oktay MF, Nazaroglu H, Meric F, Topçu I. Congenital cholesteatoma of the mastoid region. *J Laryngol Otol* 2000; 114:779-80.
7. Thakkar KH, Djalilian HR, Mafee MF. Congenital cholesteatoma isolated to the mastoid. *Otol Neurotol* 2006; 27:282-3
8. Luntz M, Telischi F, Bowen B, Ress B, Balkany T. Congenital cholesteatoma isolated to the mastoid. *Ann Otol Rhinol Laryngol* 1997; 106:608-10.
9. Mevio E, Gorini E, Sbrocca M, Artesi L, Lenzi A, Lecce S, et al. Congenital cholesteatoma of the mastoid region. *Otolaryngol Head Neck Surg* 2002; 127:346-8.
10. Derlacki EL, Clemis JD. Congenital cholesteatoma of the middle ear and mastoid. *Ann Otol Rhinol Laryngol* 1965; 74:706-27
11. Coskun U, Hidir Y, Karslioglu Y, Satar B. Coexistence of congenital cholesteatoma and non-neoplastic neuroectodermal remnants in the temporal bone: Case report. *Mediterr J Otol* 2007; 3:99-103.
12. Canalis RF, Shapiro N, Lufkin R, Becker DP. Congenital implantation cholesteatomas of the occipitoparietotemporal junction. *Ann Otol Rhinol Laryngol* 2002; 111:778-82.
13. Jackler RK, Parker DA. Radiologic differential diagnosis of petrous apex lesions. *Am J Otol* 1992; 13:561-74