

## CASE REPORT

### Intradermal Nevus of the External Auditory Canal: A Case Report

Sedat Ozturkcan, Ali Ekber, Riza Dunder, Filiz Gulustan, Demet Etit, Huseyin Katilmis

Department of Otorhinolaryngology and Head and Neck Surgery

Izmir Atatürk Research and Training Hospital, Ministry of Health, IZMIR-TURKEY (SO, AE, FG, DE, HK)

Department of Otorhinolaryngology and Head and Neck Surgery

Etmesgut Military Hospital, ANKARA-TURKEY (RD)

Intradermal nevus is the most common skin tumor in humans; however, its occurrence in the external auditory canal (EAC) is uncommon. The clinical manifestations of pigmented nevus of the EAC have been reported to include ear fullness, foreign body sensation, hearing impairment, and otalgia, but some cases were asymptomatic and were found incidentally. The treatment of choice for a symptomatic intradermal nevus in the EAC is complete excision. There has been no recurrence reported in the literature. A pedunculated, papillomatous hair-bearing lesion was detected in the external auditory canal of the patient who was on follow-up for pruritus. Clinical and pathologic features of an intradermal nevus of the external auditory canal are presented, and the literature reviewed.

Submitted : 14 October 2008

Revised : 01 July 2009

Accepted : 09 July 2009

Intradermal nevus is the most common skin tumor in humans; however, its occurrence in the external auditory canal (EAC) is uncommon <sup>[1-4]</sup>. Intradermal nevus is considered to be a form of benign cutaneous tumors and referred to the group of common acquired nevocytic nevi <sup>[5]</sup>. Common acquired nevi may be papillomatous, dome-shaped, pedunculated or flat-topped and are usually flesh-colored, pink or pigmented <sup>[6]</sup>. Intradermal nevus in the external ear canal can present with aural obstruction and conductive deafness or cause the trapping of water within the external meatus and a predisposition to recurrent attacks of acute otitis externa <sup>[1]</sup>. The treatment of intradermal nevus is surgical removal. We report a case of intradermal nevus originating from the external auditory canal in a 38-year-old woman

#### Case Report

The patient, a 38-year-old woman, visited our outpatient clinic for evaluation of pruritus in the left ear. Findings on physical examination of the head and neck were unremarkable except for the condition of the

left external auditory canal. Otomicroscopic examination revealed a pedunculated, papillomatous hair-bearing lesion in the postero-inferior cartilaginous portion of the external auditory canal (Figure 1). Tympanic membrane was intact and absolutely normal. The patient denied any otorrhea, weakness of the facial nerve or tenderness to palpation. We decided excisional biopsy to rule out melanoma. Local anesthesia and vasoconstriction were achieved with lidocaine HCl 20 mg/ml and epinephrine 0.125 mg/ml. The lesion was completely removed. On histopathologic examination, the nests and cords of nevus cells were seen in the upper dermis. The cells were fairly uniform in size with bland nuclei and no nucleoli. Melanocytic cells were pale (Figures 2-3). The wound was left to heal spontaneously. The wound site healed well and there was no stenosis of the ear canal.

#### Discussion

Melanocytic nevi are benign neoplastic proliferations of nevus cells, and reclassified as congenital and acquired <sup>[5]</sup>. Melanocytic nevi are categorized in three

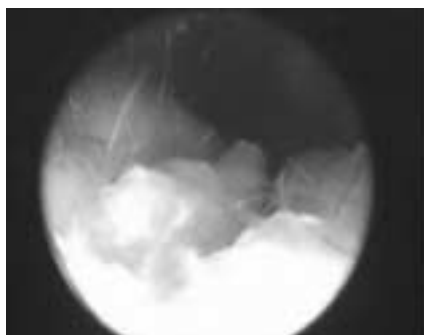
#### Corresponding address:

Riza Dunder

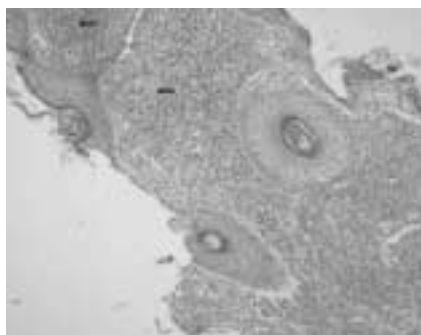
Department of Otorhinolaryngology and Head and Neck Surgery Etmesgut Military Hospital, ANKARA-TURKEY

Fax: + 90 312 244 49 77; E-mail: dundarkbb2@myinet.com

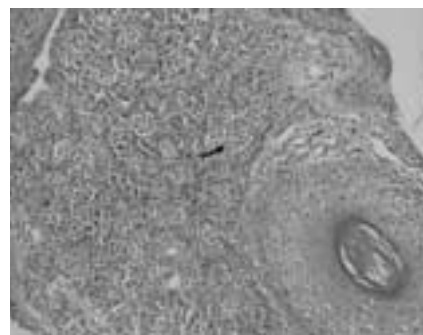Copyright 2005 © The Mediterranean Society of Otolaryngology and Audiology



**Figure 1.** Otomicroscopic image shows that a pedunculated, papillomatous hair-bearing lesion in the postero-inferior cartilaginous portion of the external auditory canal



**Figure 2.** Just beneath the epidermis are the nests of nevic cells within the dermis (Arrows) (H&E X10)



**Figure 3.** The cells with scant cytoplasm and uniform nuclei in nevic nests (Arrow). (H&E X20)

subgroups according to histological location, namely, junctional, compound, and intradermal <sup>[7]</sup>. Junctional nevus cells are situated at the epidermo-dermal junction and extend into the dermis, but they always remain in contact with the epidermis. Characteristically, intradermal nevus cells are restricted to within the dermis and do not contact the epidermis. The compound nevus represents the transitional stage between the junctional and intradermal nevus, and exhibits features of both these forms <sup>[7]</sup>. Clinically, five types of melanocytic nevi can be recognized: flat lesions, slightly elevated lesions often with raised centers and flat peripheries, papillomatous lesions, dome-shaped lesions and pedunculated lesions <sup>[5]</sup>. Most papillomatous lesions, as in the present case, and nearly all dome-shaped and pedunculated lesions represent intradermal nevi <sup>[8]</sup>.

Histologically, melanocytic nevi are defined and recognized by the presence of nevus cells, which, even though they are melanocytes, differ from ordinary melanocytes by being arranged at least partially in clusters or nests. While melanocytic nevi have traditionally been classified into junctional nevi (in which the nevus cells are confined to or still in contact with the lower epidermis), intradermal nevi (in which the nevus cells are located within the dermis and no longer contact with the epidermis) and compound nevi (which possess the features of both junctional and intradermal nevi); in fact, current theory suggests that this classification simply describes the normal

development pattern of melanocytic nevi in which the nevus cells first appear in the lower epidermis (junctional) and over time begin to descend into the dermis (compound) and ultimately end up solely within the dermis (intradermal) <sup>[6]</sup>. Intradermal nevi that have few or no junctional nests frequently have a border zone relatively free of nevomelanocytes just below the epidermis. Multinucleated nevomelanocytes occasionally occur and may be interpreted as a sign of benign lesion. Nevomelanocytes in the deep dermis may be disposed within a collagenous framework that is loose, pale and wavy in formations called neuroid tubes, similar to a neurofibroma <sup>[5]</sup>.

Most nevi at all locations are usually asymptomatic and require no treatment; however, these lesions may be excised for cosmetic reasons or if melanoma is suspected <sup>[7]</sup>. Intradermal nevi are usually papillomatous or pedunculated dome shaped and pink colored lesion <sup>[5]</sup>. The differential diagnosis should include osteoma, malignant melanoma, inflammatory polyp, encephaloceles, foreign body granuloma, and a variety of benign and malignant neoplasms of external acoustic canal <sup>[2,5]</sup>. Osteoma and exostosis of external auditory canal occur on the bony portion of external auditory canal. The thin and pale skin covers both of them. Although osteoma appears pedunculated, exostosis usually has broad base. The inflammatory polyp, foreign body granulomas, adenoid cystic carcinoma of the ceruminous glands and squamous

carcinoma are painful lesions. The inflammatory polyps are commonly associated with chronic otorrhea and hearing loss. The carcinomas of external canal auditory are usually ulcerated with surrounding induration or granulation tissue and can be associated with chronic otitis media or external otitis media. If the pain persists after medical treatment of otitis media, malignancy must be suspected. Malignant melanoma should be suspected in cases of dark colored, ulcerated and irregular bordered nevi. Ultimately the definitive diagnosis should be made microscopically <sup>[7]</sup>.

The occurrence of melanocytic nevus in the skin of the external auditory meatus is mentioned by Friedmann <sup>[9]</sup>, but Youngs et al. published the first clinical and pathological features of an intradermal nevus arising within the external auditory canal in the English literature <sup>[1]</sup>. Other clinical reports in the literature are Japanese <sup>[10,11]</sup>. The definitive diagnosis of the intradermal nevi is made by clinical appearance and histopathological examination

The treatment of intradermal nevus is surgical removal. Surgical methods are shaving technique and complete excision. Hairless intradermal nevi may be removed using the shaving technique. Complete excision was performed when the pedunculated, papillomatous hair-bearing lesions. Our patient's excision site healed well, and there was no stenosis

In conclusion, all melanocytic nevi of the external auditory canal should be excised to rule out melanoma.

## References

1. Youngs R, Hawke M, Kwok P. Intradermal nevus of the ear canal. *J Otolaryngol.* 1988; 17:241-3.
2. Deguine C, Pulec JL. Benign nevus of the external auditory canal. *Ear Nose Throat J.* 1998; 77:448.
3. Bothwell NE, Willard CC, Sorensen DM, Downey TJ. A rare case of a sebaceous nevus in the external auditory canal. *Ear Nose Throat J.* 2003; 82:38-41.
4. Cagici CA, Yilmaz I, Ozlüoğlu L, Kayaselçuk F. Intradermal nevus of the external auditory canal: a case report. *Kulak Burun Bogaz Ihtis Derg.* 2004; 12(3-4):91-4.
5. Elder D, Elenitsas R, Jaworsky C, Johnson B. *Levers histopathology of the skin.* 8th Ed. Lippincott-Raven, Philadelphia. 1997; pp:633-638.
6. Fitzpatrick TB. *Dermatology in general medicine.* 4th Ed.. McGraw-Hill, New York. 1993; pp:996-1005.
7. Cochran AJ, Bailly C, Paul E, Dolbeau D. Nevi, other than dysplastic and Spitz nevi. *Semin Diagn Pathol.* 1993; 10:3-17.
8. Shaffer B. Pigmented nevi; a clinical appraisal in the light of present-day histopathologic concepts. *AMA Arch Derm.* 1955 Aug; 72(2):120-32.
9. Friedmann J. *Pathology of the ear* 1st ed. Blackwell Scientific Publications; Oxford. 1974; pp:156.
10. Nishijima W, Takoda S, Tsuchiya SI, Naka H, Edamatsu H, Noguchi A. Clinico-pathological study of nevocellular nevi in the external auditory canal *Nippon Jibiinkoka Gakkai Kaiho.* 1982; 85:1039-46.
11. Miyake H, Matsumura K. Nevus pigmentosus of the external auditory canal. *Jibiinkoka.* 1966; 38:493-6.