
ORIGINAL ARTICLE

The value of endoscopy in the surgical management of vertigo

Jacques Magnan MD, Hani El Garem MD, Arnaud Deveze MD, Jean-Pierre Lavieille MD, PhD

From the ORL Unit,
Hôpital Nord, 13915,
Marseille, France

Correspondence

Pr. Jacques. Magnan
Head of the ORL Department
Université de la Méditerranée
Hôpital Nord
13915 Marseille Cedex 20 France

Tel : + 33 4 91 96 86 75
Fax : + 33 4 91 96 81 98
Email : jmagnan@ap-hm.fr

Submitted: 20 October, 2005

Revised: 09 January, 2006

Accepted: 20 January, 2006

OBJECTIVE: The authors present their experience in using an endoscope-assisted procedure to manage functional surgery of the auditory nerve in selected patients suffering from disabling vertigo.

MATERIAL AND METHODS: The value of endoscopy was retrospectively evaluated in 2 groups of patients. Over a period of 10 years, 25 patients suffered from disabling positional vertigo with vascular compression of the eighth cranial nerve; during a shorter period of 3 years, 45 patients with Meniere's disease required vestibular neurectomy. Both series were performed via a minimally invasive retrosigmoid approach.

RESULTS: Endoscope-assisted surgery is very useful for a sure and safe vascular decompression of the auditory nerve, with no induced side effects. Of 25 patients who had endoscopic-assisted surgery for disabling positional vertigo syndrome, 14 were actually cured. In contrast, the usefulness of the endoscopic procedure has not yet been demonstrated in vestibular neurectomy.

Mediterr J Otol 2006; 2: 1-8

Copyright 2005 © The Mediterranean
Society of Otolaryngology and Audiology

Despite its illumination and magnification, the operating microscope has distinct limitations. The operator can visualize the structures directly ahead but is unable to see around them. These limitations can be overcome with the complementary help of an endoscope, which allows the operator to "look around the corner." The use of the endoscope as a complementary tool in otology and neuro-otology enhances the concept of minimally invasive approaches.

HISTORICAL BACKGROUND

The first comprehensive description of endoscopy of the cerebellopontine angle (CPA) was provided by French surgeon Doyen, who in 1917 described an endoscopic technique for selective fifth-nerve section in trigeminal neuralgia.¹ A further description of this technique was outlined by Prott in 1974, who advocated a transmastoid retrolabyrinthine approach to the CPA.² Jähme and Oeken in 1977 suggested the use of a retrosinusal-suboccipital approach for diagnostic purposes.³ Oppel and colleagues described a transpyramidal-retrolabyrinthine approach for endoscopic section of the sensory trigeminal root,⁴ then for the vestibular nerve.⁵ However, the instrumentation available until relatively recently was a major deterrent to progress, and the procedure found few disciples until Magnan stimulated renewed interest in endoscopic surgery of the CPA via a keyhole retrosigmoid approach.⁶

The basic benefit of the endoscopic procedure is a more comprehensive "mapping" of the neurovascular components without the necessity of cerebellar retraction, keeping the anatomic relations between vascular and neural elements undisturbed. The endoscope has the advantage of providing magnified high-resolution images and an unobstructed panoramic view of all nervous and vascular structures crossing the area, unlike the monoaxial one offered by the operating microscope. Also, its use does not necessitate excessive cerebrospinal fluid drainage, as the view is as clear inside as it is outside. These advantages allow the precise identification of the vasculoneural conflicts in 100%

of patients in an atraumatic and less invasive way. Thus, the combination of the endoscope and the operating microscope in CPA surgery is an intraoperative refinement that should be applied in the surgical treatment of neurovascular compression syndromes of the cochleovestibular nerve and in the sectioning of vestibular nerves.⁷

ENDOSCOPIC ANATOMY

From an endoscopic viewpoint, the acousticofacial bundle divides the CPA into 2 parts with a superior level and an inferior level (Figure 1)⁸. The acousticofacial nerve bundle crosses the middle of the CPA. The flocculus overlies the root entry zone (REZ) of the cochleovestibular and facial nerves. The relationships with the loops of the anterior inferior cerebellar artery (AICA) are clearly seen without the need to retract the cerebellum, preventing any distortion of the vasculoneural structures. A 30° angled-view endoscope provides accurate visualization of the REZ of the nerves. The loops of the AICA may be found to be situated above, below, or between the facial and cochleovestibular nerves. At this point, the AICA leads to the labyrinthine and subarcuate arteries.

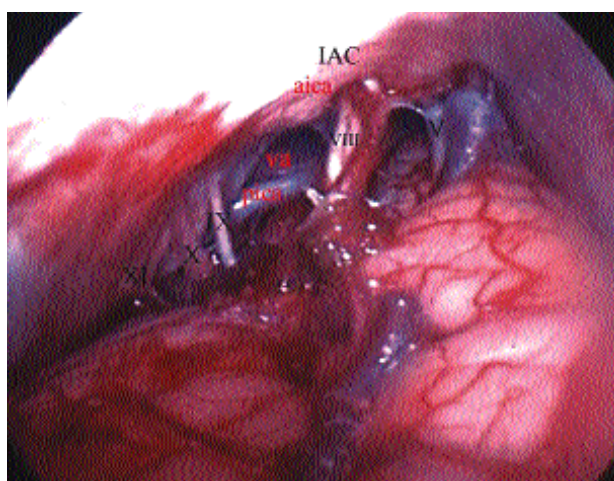

Figure 1: Endoscopic view of the right cerebellopontine angle with the acousticofacial nerve VIII dividing it into 2 parts: superior area with Dandy's vein and trigeminal nerve (V), inferior area with lower cranial nerves (XI, X, XI). (IAC, internal auditory canal.)

Superior level or trigeminal area. In this level, we find the pons, the fifth and sixth nerves, the vein of Dandy (more superficial above and lateral to the fifth nerve) which joins the superior petrosal sinus and the tentorium cerebelli above. We also see the superior cerebellar artery and, sometimes, the ascending part of the AICA.

Inferior level or lower cranial nerves area. Here we see the roots of the lower cranial nerves, the course of the posterior inferior cerebellar artery (PICA), and the vertebral artery.

Site of the neurovascular conflict of the eighth cranial nerve. The vascular compression is at the Schwann cell–glial junction transitional zone (TZ).⁹ The TZ of the eighth nerve varies in its location along the course of nerve. Consequently, the sites of the vascular conflicts can occur anywhere along the nerve from the brain stem to the internal auditory canal.¹⁰

There are different types of contact between the vessel and the cochleovestibular nerve (Figure 2):

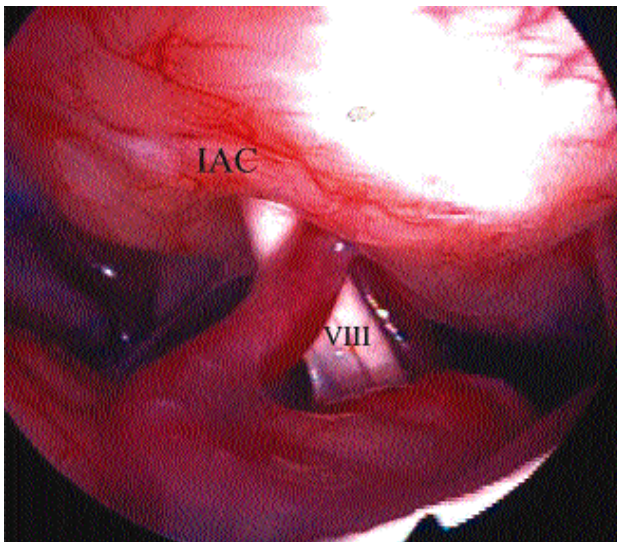


Figure 2: Neurovascular conflicts of the eighth cranial nerve with a loop of the anterior inferior cerebellar artery below the eighth nerve (VIII) at the level of the internal auditory canal (IAC).

1. Simple contact: The conflict is caused by a loop of the AICA and a single point of contact above the nerve. A special finding is a long subarcuate artery

stretching posteriorly along the nerve at its entrance into the internal auditory canal.

2. Multiple contacts: The conflict includes different points of contact by several loops of the AICA around the REZ of the nerve along its cisternal and/or intracanalicular course.

3. Nutcracker type of contact: The conflict includes 1 or more offending vessels (AICA and PICA) above and below the nerve entangled between them.

4. Vein contact: The venous structure is an inconsistent and aberrant inferior cerebellar vein, part of a developmental venous anomaly, and the contact is along the REZ of the nerve and at the Luschka foramen.

Vascular compressive neuropathy should induce vestibular nerve irritation that results to hyperactivity and hyperexcitability of the nuclei and central nuclear dysfunction.¹¹

MATERIALS AND METHODS

Endoscopes. We recommend a rigid instrument for precise surgical maneuvers. The safest endoscopes are 6 cm in length and 4 mm in diameter with a 0° angle. This provides a panoramic view. The limited length prevents inadvertent contact with deeply lying structures. The most useful endoscopes are 11 cm in length and 4 mm in diameter with a 30° angle.

The 60°- and 70°-angled endoscopes are not optimal because the surgeon cannot appreciate the exact position of the tip of the endoscope.

Aseptic techniques. Telescopes marked as autoclavable can be steam-autoclaved at a maximum temperature of 134° C (272° F) for 5 to 8 minutes at 2-2 atmospheric pressures.

A sterile cover protects the camera and light cable. A warm (37° C) saline solution is used as an antifog agent. The tip of the endoscope must be cleaned after each withdrawal. To assure aseptic conditions, the surgeon must check the progression of the endoscope using a video camera and monitor (and not by direct inspection through the eyepiece).

Lastly, we recommend avoiding prolonged direct contact between the tip of the endoscope and the nerves to prevent thermal effect and neural injury. All staff should be fully trained in the use of the endoscope.

Approaches. Our standard practice in combining surgical and endoscopic procedures was to use the retrosigmoid approach, which is a posterior and direct approach to the CPA. Now, through middle fossa, retrolabyrinthine, translabyrinthine, and transcochlear approaches, the endoscope is used with the same technique and for the same purposes as in the retrosigmoid approach.

Indications

Vascular compression of the eighth cranial nerve

Disabling positional vertigo (DPV) was first described by Jannetta in 1975.¹⁰ The symptoms include severe motion-induced dizziness, continuous disequilibrium and unsteadiness while in motion, visually induced nausea, and instability.¹²⁻¹⁵ Standing still, sitting, or lying down relieves DPV. Symptoms are not acute, are not fatigable, and are not relieved by vestibular rehabilitation or medical treatment.¹⁶ DPV is usually not accompanied by other aural symptoms, although tinnitus; hearing loss, fullness, and ear pain can be present in varying degrees.

On audiometric examination, a unilateral high- or middle-frequency hearing loss is found in more than 70% of patients, and 22% have middle-frequency hearing loss.¹⁵

The validity of the diagnosis of DPV was questioned by Bergsneider and Becker.¹⁷ "It would appear that the syndrome of DPV might encompass a broad spectrum of other vertigo syndromes, predominantly what would be considered variants or atypical symptoms of classic syndromes."

Abnormal auditory brainstem response (ABR) is found in up to 40% of patients.¹⁸ The pressure on the eighth cranial nerve by an offending vessel would result in a delay of wave II or an increase in the latency between peaks I and II, which corresponds to the dis-

tal auditory nerve. The most relevant Moller's criteria for ABR abnormalities are wave I-III interval difference >0.2 ms, wave I-III interval difference >0.16 ms if low or absent wave II, wave II amplitude 33% to the contralateral side, and ipsilateral wave I-III absolute interval >2.3 ms.

Magnetic resonance imaging (MRI) is the key assessment tool for neurovascular conflicts. It must include all CPA components. For all patients, 3-dimensional Fourier transform MRI with special T2 sequences, constructive interference in study state (CISS), and postcontrast special T1 sequences (TurboFlash) are performed to show the presence of a neurovascular conflict and its location (Figures 3 and 4). Magnetic resonance angiography (MRA) can be performed in some patients. MRI also excludes the presence of other pathologies. The variability of the vascular anatomy of the CPA and the frequency of the presence of a vascular loop in contact with the eighth cranial nerve in asymptomatic patients results in skepticism regarding the likelihood of pathology arising from cross compression.^{19,20} Reliable radiologic diagnostic criteria of neurovascular conflict are required before claiming a cross compression of the cochleovestibular nerve secondary to a vascular loop.²¹

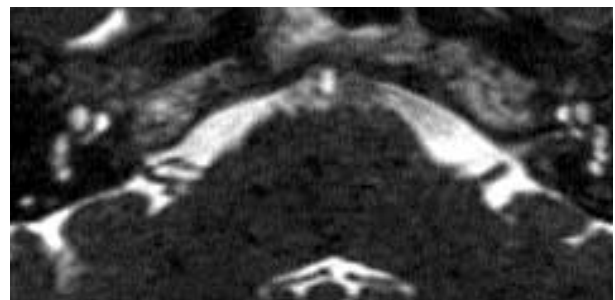

Figure 3: MRI assessment with T2 CISS sequence of the right acousticofacial nerve bundle a perpendicular contact and posterior distortion of the cochleovestibular nerve. (MRI, magnetic resonance imaging; CISS, constructive interference in study state.)

There are two diagnostic criteria for DPV, the presence of orthogonal contact between the nerve and the vessel, and the presence of neural structure distortion by the offending vessel. In patients with DPV, an abnormal ABR associated with an MRI showing a vascu-

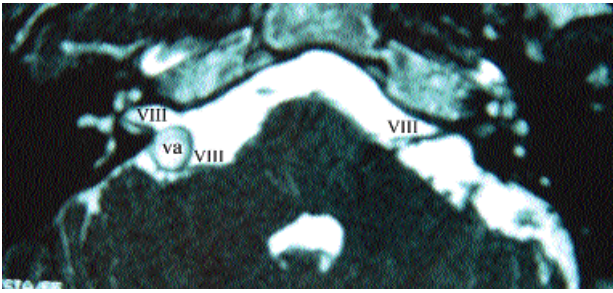


Figure 4: MRI assessment with gadolinium T2 CISS sequence show the presence of the right vertebral artery (va) distorting the acousticofacial nerve bundle (VIII) at its cisternal course. (MRI, magnetic resonance imaging; CISS, constructive interference in study state.)

lar conflict with the eighth nerve are sufficient indications for surgical decompression of the nerve.¹⁸

Endoscope-assisted microvascular decompression procedure

Vascular decompression is performed via a minimal retrosigmoid approach, followed by a limited craniotomy, behind and close to the sigmoid sinus. The CPA is explored by a 30°-angled endoscope, which gives a panoramic view of this space and allows clear visualization of the REZ of the acousticofacial nerves as well as the porus acousticus. Before starting surgery, the endoscope gives the surgeon a precise mapping of the site and the course of the offending vessel, minimizing retraction and dissection (Figure 5). Whatever the location of artery-nerve conflict, the purpose of the microvascular decompression procedure is to change the axis of the offending vascular loop and keep it away from the offended nerve (Figure 6).

This surgical maneuver is easier and more safely accomplished under the operating microscope which allows the use of 2 free hands. The offending vessel is carefully mobilized using microelevators and microhooks. Meticulous and careful dissection allows changing the vessel's axis of direction. Then, the microvascular decompression is realized with a small Teflon® pad, adjusted with a microhook to hold the artery away from the nerve. An inert material, Teflon® is very well tolerated in the CPA as well as in other parts of the body.

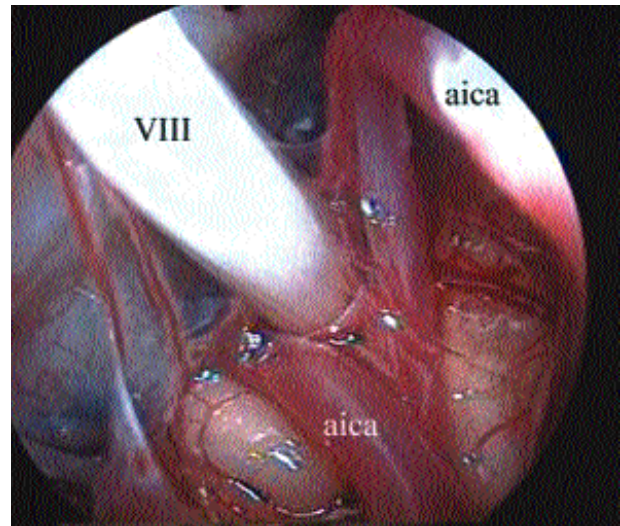


Figure 5: Endoscopic assessment of a nutcracker-type conflict: several loops of the anterior inferior cerebellar artery (aica) are surrounding the root entry zone of the nerve (VIII).

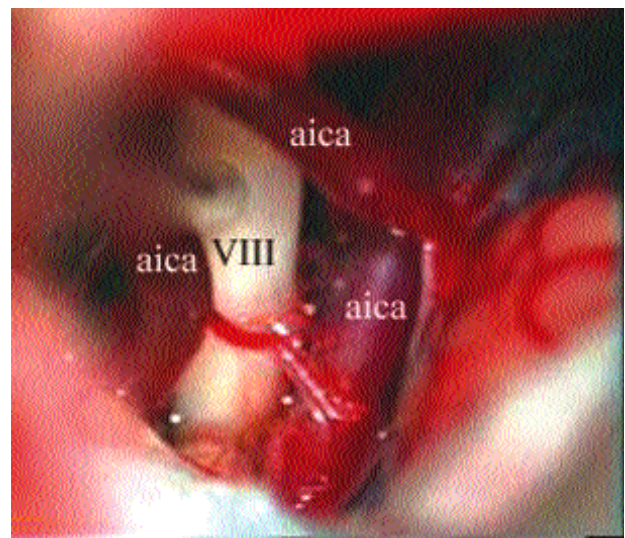


Figure 6: View of the same patient with the operation microscope to mobilize the offending vessels.

When a nonpredominant vein is involved in the conflict, it is coagulated using bipolar coagulation. If the vein is predominant, as shown by preoperative MRI or intraoperative examination, it should be treated as an artery .

The microvascular decompression of the eighth cranial nerve is particularly delicate. The most common offending vessel, the AICA, has a course between the seventh and eighth nerve in 50% of patients,

which prevents an efficient microvascular decompression performance. Furthermore, an intracanalicular AICA loop requires a complementary drilling of the internal auditory canal with the risk of postoperative hearing loss.

The operation ends with a new endoscopic review of the quality of the surgical act, the good positioning of the Teflon® pad, and the absence of contact between the decompressed nerve and all adjacent vascular structures (Figure 7). The endoscope allows the performance of this control without disturbance to the microvascular decompression.

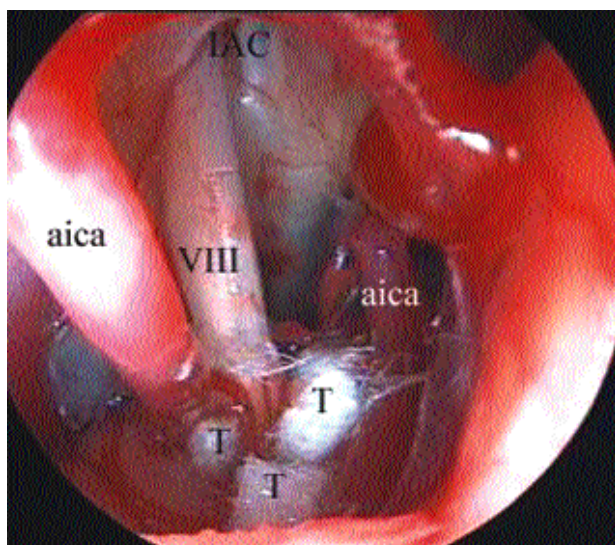


Figure 7: Endoscopic control of the positioning of the Teflon® (T) and the completion of the vascular decompression. (IAC, internal auditory canal; aica, anterior inferior cerebellar artery; VIII, eighth nerve).

Intraoperative ABR monitoring of the cochlear nerve is performed during microvascular decompression for DPV or tinnitus. It can help in avoiding cochlear nerve injury. The return of the ABR to normal after the decompression is a sign of good prognosis, but, unfortunately, this does not mean constant relief from symptoms.

RESULTS

Of the 25 patients who underwent microvascular decompression assisted by endoscopy for vertigo, the

procedure was successful in 14 (56%) with complete disappearance of the complaint. One patient showed a sudden sensorineural hearing loss (20dB), 1 month postoperatory. ABR returned to normal in 5 patients. In the remaining 11 patients (44%), the decompression procedure was ineffective.

DISCUSSION

The value of endoscope-assisted surgery in vascular compression syndrome has already been emphasized for trigeminal nerve in 141 cases and facial nerve in 265 cases.²² Vertigo disorder, the consequence of an offending vascular loop on the auditory nerve, is more controversial and less common. Between 1994 and 2004, only 25 patients were identified as having DPV requiring surgery out of 561 endoscope-assisted microvascular decompression procedures. During the same period, 363 patients with untreatable incapacitating Meniere's disease underwent vestibular neurectomy.

Jannetta and Moller reported the results of 3 series of DPV patients who underwent microvascular decompression.^{10,12,13,17} Simply, of 71 patients, 76% were considered "excellent" or "significantly improved" in terms of vertigo symptoms or quality of life. McCabe and Gantz reported that 23 of 29 patients experienced relief from vertigo and motion intolerance.¹⁴ In Sakaki and colleagues, of 18 patients, vertigo disappeared in 11 and improved markedly in 2.²³ In the House Ear Clinic experience, Brackmann and colleagues reported 85% improvement of the overall disabling rating in a group of 20 patients.¹⁶

So far, Schwaber's conclusions still summarize the efficiency of "this controversial treatment for a controversial illness."^{17,18} Microvascular decompression of the cochleovestibular nerve eliminates the disequilibrium in approximately half of patients, improves the symptoms in one fourth of patients, and fails to control the symptoms in another one fourth of patients.

Vestibular neurectomy, a minimally invasive retrosigmoid approach is particularly suited to vestibular neurectomy in treating incapacitating vertigo in Meniere's disease when residual hearing still exists. The retrosigmoid approach is not technically difficult, pro-

vides excellent access, and allows a sure selective section of the vestibular nerve.

Endoscopic vestibular neurectomy can be performed using a similar approach^{24,25}. We have been able to carry out vestibular neurectomy with the endoscope alone in 16 of 45 patients undergoing the procedure to control disabling vertigo in Meniere's disease.

Difficulties and obstacles encountered during endoscopic vestibular neurectomy included insufficient spontaneous retraction of the cerebellum prior to opening the basal cisterns, the presence of thick arachnoid wrapping requiring dissection, and difficulties in determining the cochleovestibular cleavage.

As yet, there are no advantages to the use of the endoscopic vestibular neurectomy in comparison with the operating microscope with regard to the safety and the efficiency of the operation.

CONCLUSION

There is trend toward the development of less-invasive procedure in all surgical fields, including otoneurologic surgery. Videoendoscopy technology is a part of this improvement. The use of endoscopes in complement to the operating microscope for functional surgery of vertigo is helpful in achieving a sure and safe vascular decompression of the auditory nerve, but it still presents significant limitations for vestibular neurectomy. Endoscope-assisted microvascular decompression of the auditory nerve should be considered as a surgical option, in selected cases, as it is already established for trigeminal and facial nerves.

REFERENCES

1. Doyen F. Historical perspectives. In Rovit R, Murali R, Jannetta P, eds. Trigeminal neuralgia. Baltimore: Williams and Wilkins. 1990; p17.
2. Prott W. Cisternoscopy of the cerebellopontine angle (author's transl) [in German]. HNO 1974;22:337-41. German.
3. Jähme W, Oeken FW. Endoscopy of the cerebellopontine angle using the retrosinusal-suboccipital route [in German]. Zentralbl Neurochir 1977;38:275-80.
4. Oppel F, Mulch G. Selective trigeminal root section via an endoscopic transpyramidal retrolabyrinthine approach. Acta Neurochir Suppl (Wien) 1979;28:565-71.
5. Oppel F, Handrock M. Endoscopic section of the vestibular nerve by transpyramidal retrolabyrinthine approach in Meniere's disease. Adv Oto Rhino Laryng 1984;34:234-41.
6. Magnan J, Chays A, Lepetre C, Pencroff E, Locatelli P. Surgical perspectives of endoscopy of the cerebellopontine angle. Am J Otol 1994;15:366-70.
7. Magnan J, Sanna M, et al. Endoscopic and microscopic neuro-otological surgery. Endoscopy in neuro-otology. Stuttgart/New York: Thieme Verlag. 1999;24-98.
8. O'Donoghue G, Greengrass S, Magnan J. Endoscopy in otology and neurosurgery. Adv In Otolaryngology 1994;8:43-67
9. Jannetta P. Microsurgery of cranial nerve cross-compression. Clin Neurosurg 1979;26:607-15.
10. Jannetta P. Neurovascular cross-compression in patients with hyperactive dysfunction symptoms of the eighth cranial nerve. Surg Forum 1975;26:467-69.
11. Moller A. Vascular compression of cranial nerves: II: pathophysiology. Neurol Res 1999;21:439-43.
12. Jannetta PJ, Moller MB, Moller AR. Disabling positional vertigo (DPV). N Engl J Med 1984;310:1700-5.
13. Moller MB. Results of microvascular decompression of the eighth nerve as treatment of disabling positional vertigo. Ann Otol Rhinol Laryngol 1990;99 (pt 1):724-9.
14. McCabe BF, Gantz BJ. Vascular loop as a cause of incapacitating dizziness. Am J Otol 1989;10:117-20.
15. Schwaber MK, Hall JW. Cochleovestibular compression syndrome. I: Clinical features and audiovestibular findings. Laryngoscope 1992;102:1021-9.
16. Brackmann DE, Kesser BW, Day JD. Microvascular decompression of the vestibulocochlear nerve for disabling positional vertigo: the House Ear Clinic experience. Otol Neurotol 2001;22:882-7.

17. Bergsneider M, Becker D. Vascular compression syndrome of the vestibular nerve: a critical analysis. *Otolaryngol Head Neck Surg* 1995;112:118-24.
18. Schwaber M. Vascular compression syndromes In: Jackler R, Brackmann D, editors. *Neurotology*. St Louis, Mo: Mosby. 1993:881-903.
19. Herzog JA, Bailey S, Meyer J. Vascular loop of the internal auditory canal: a diagnostic dilemma. *Am J Otol* 1997;18:26-31.
20. Makins AE, Nikolopoulos TP, Ludman C, O'Donoghue GM. Is there a correlation between vascular loops and unilateral auditory symptoms? *Laryngoscope* 1998;108:1739-42.
21. Girard N, Poncet M, Chays A, Tallon Y, Raybaud C, Magnan J. Neurovascular compression in the CP angle. *Rev Neuroradiol* 1995;8:981-89.
22. Magnan J. The value of endoscopy in otology and neuro-otology. *Otol Jpn* 2003;13:163-73.
23. Sakaki T, Morimoto T, Miyamoto S, Kyoi K, Utsumi S, Hyo Y. Microsurgical treatment of patients with vestibular and cochlear symptoms. *Surg Neurol* 1987;27:141-6.
24. Ozluoglu L, Akbasak A. Video endoscopy-assisted vestibular neurectomy. *Skull Base Surg* 1996;7:215-25.
25. Wackym PA, King W, Barker F, Poe D. Endoscope-assisted vestibular neurectomy *Laryngoscope* 1998;108:1787-93.

Letter to the Editor

1-The value of angled endoscopes in posterior fossa approaches is unquestionable since this tool discloses the hidden areas not visible or reachable with surgical microscope, especially in acoustic neuroma dissection and decompression of trigeminal and facial nerves. However, to my opinion, for microvascular decompression and/or neurectomy of the 8th nerve the surgical microscope itself is a sufficient tool to perform these surgeries, since the microscope is capable of viewing the cisternal part of the 8th nerve. Only in some cases, in which the AICA loops into the internal auditory canal (IAC), 30 and even 45 degree angled endoscopes may be useful. Even in these cases, a limited drilling (not more than 4 mm) of the posterior lip of IAC discloses the loop sufficiently and allows successful decompression without the need of endoscopes. We have been using angled endoscopes (30 and 45 degree) in our all acoustic and trigeminal and facial decompression surgeries since 1994, but we have never felt a necessity of this tool in 8th nerve section nor decompression.

2- The dimension of craniotomy for any kind of posterior fossa approaches should not be less than 25-30 mm in diameter. Introducing the rigid endoscope through a mini craniotomy and dural incision might cause insufficient orientation to the

posterior fossa, and cause troublesome venous bleeding from some cerebellary - petrous dura overhanging veins, especially near the cerebellary tentorium. This condition leads to re-enlarge the surgical field to control such a bleeding which is time consuming.

Prof. Nebil GÖKSU M.D.

Gazi University Otolaryngology Dept.

Beşevler-Ankara-Turkey

The author's response:

The above comments are very interesting because they come without any doubt from an excellent surgeon still using the principles of the conventional sub-occipital approach.

In the manuscript we promote the concept of minimally invasive retro-sigmoid approach with keyhole approach requiring different technologies to be achieved safely. Consequently the conclusive remarks should be adapted to the performed surgery.

Prof. Jacques MAGNAN M.D.

ORL Unit, Hôpital Nord, 13915,
Marseille, France