

CASE REPORT

Invasive Aspergillosis of Temporal Bone: A Surgeon's Dilemma?

Roshan K Verma, Amit Shankar, Amanjeet Bal, Naresh K Panda

Department of Otolaryngology, Head and Neck surgery, Post Graduate Institute of Medical Education and Research, Chandigarh, India, (RV, AS)
Department of Pathology, Post Graduate Institute of Medical Education and Research, Chandigarh, India, (AS)

Although invasive fungal infections of the paranasal sinuses have been well described in literature, those affecting the ear and temporal bone are very rare. Described is a case of invasive aspergillosis of the temporal bone in a 66-year old diabetic male. The diagnosis and treatment of such infections are discussed. The dilemma of the surgeon in managing such lesions (medical vs surgical options) are also discussed.

Submitted : 07 March 2009

Revised : 26 June 2009

Accepted : 20 November 2009

Introduction

The external auditory canal is a bony- cartilaginous channel lined by thin layers of epidermal and connective tissue. External auditory canal infections can be credited to viral, bacterial or fungal pathogens. Of these, the most dangerous is necrotizing or malignant otitis externa, commonly seen in the immune-compromised patients and patients with poorly controlled diabetes mellitus.

The most commonly involved microorganism is *Pseudomonas aeruginosa*, but invasive fungal osteomyelitis of the temporal bone should not be forgotten. This disease is often aggressive and can extend through soft tissues and vascular planes into the adjacent structures. If uncontrolled, multiple cranial neuropathies and septic thrombo-embolism can occur resulting in death. The cardinal rules to management of invasive temporal infections are timely identification followed by prolonged antimicrobial, antifungal therapy and early surgical debridement.

Case Report

An 66 year old diabetic male presented with three months history of right ear discharge, hearing impairment, and ear ache. He developed right temporal swelling for one month and facial asymmetry for five

days. Ear discharge was scanty, mucopurulent, occasionally bloodstained and non foul smelling.

There was no history of fever, headache, vomiting, seizures or any neurological deficits. He had history of diabetes for last five years and blood sugar was uncontrolled at the time of presentation.

He also had history of hypertension and was on regular treatment.

On examination, there was pinkish, fleshy, polypoidal mass filling whole of right external auditory canal along with mucopurulent discharge. Tympanic membrane on right side could not be seen due to mass whereas on the left tympanic membrane was normal. There was diffuse indurated, nontender, nonfluctuant, 5x4 cm swelling over right temporal region. The swelling was extending from just in front of the zygoma anteriorly to front of tragus posteriorly. The skin over the swelling was congested and indurated. There was loss of sensation over the swelling. There was mild facial paresis on the right side (Figure 1). On indirect laryngoscopic examination, there was right vocal cord palsy but the patient did not have any change in voice. Weber test demonstrated lateralization to right ear. Bone conduction was better than air on the right ear on Rinne testing. Audiometry

Corresponding address:

Dr. Roshan K Verma

Department of Otolaryngology, Head and Neck surgery Post Graduate Institute of Medical Education and Research, Chandigarh, India- 160012.

Phone: +91-991420976; Fax: +91-172-2744401; E-mail : roshanverma@hotmail.com

Copyright 2005 © The Mediterranean Society of Otolaryngology and Audiology

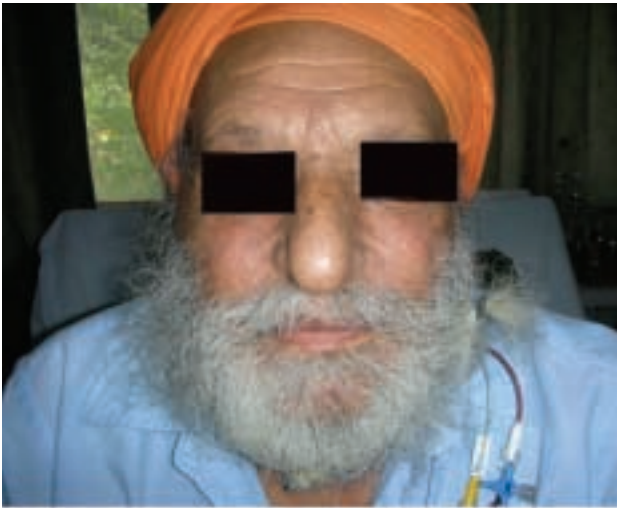

Figure 1. Pre treatment clinical photography of the patient showing diffuse swelling in right temporal area with facial paresis

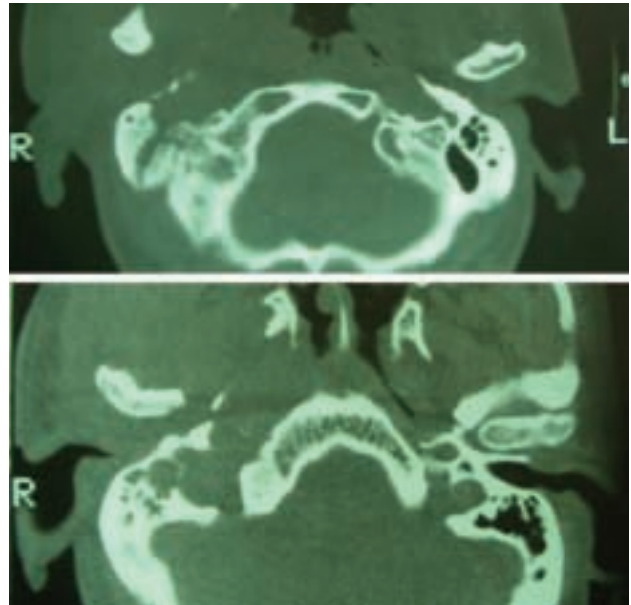


Figure 2(a, b). HRCT- Temporal bone: Pretreatment extension of the disease (a,b)

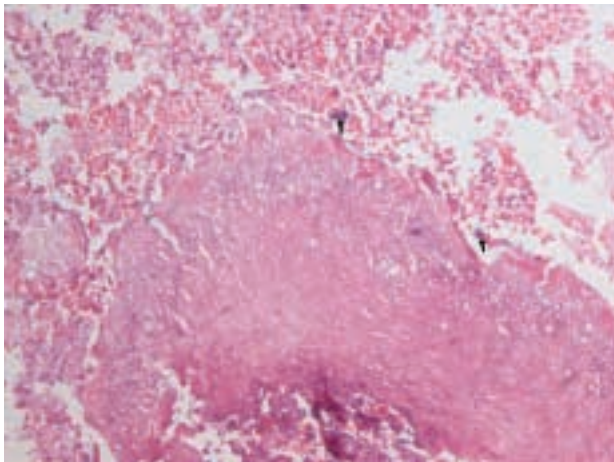


Figure 3. Photomicrograph showing necrosis and septate fungal hyphae conforming to morphology of aspergillus (Haematoxylin & eosin, x100).

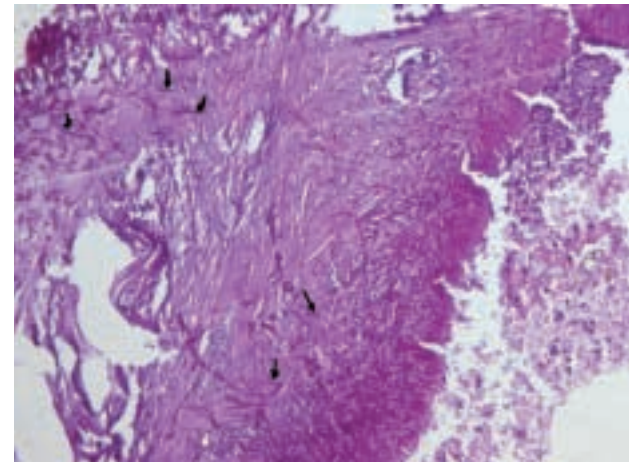


Figure 4. Photomicrograph showing PAS positive septate fungal hyphae conforming to morphology of aspergillus (PAS stain, x100).

revealed a 50dB conductive hearing loss on the right ear while mild sensorineural hearing loss on the left.

High resolution computer tomographic scan (HRCT) of the temporal bone without contrast showed heterogeneous soft tissue density filling the entire external auditory canal, mesotympanum, hypotympanum and mastoid antrum with extension into infratemporal fossa, nasopharynx and parapharyngeal space on the right side. There was

evidence of erosion of the adjacent squamous temporal bone and temporomandibular joint (Figure 2).

Biopsy of the polypoid mass was obtained from the right external auditory canal mass showed evidence of invasive aspergillosis. Histologic evaluation revealed 0.6x0.4x0.2 cm aggregate of tan-yellow friable tissue fragments, which when sectioned using hematoxylin-eosin stain showed hyphae with multiple septae branching at acute angles. The hyphae were embedded

and surrounded by fibrin and squamous debris. The hyphae also appeared to infiltrate the fibrous tissue. A culture of the material acquired through biopsy grew *Aspergillus fumigatus* (Figure 3, 4).

He was started on intravenous conventional Amphotericin (50mg / day) with continuous monitoring of all biochemical parameters including renal profile. After completion of 2gm of Amphotericin, repeat HRCT temporal bone was done which showed significant resolution of disease (Figure 5a, b). No debridement of the disease was required. Patient was discharged on oral voriconazole for two months. Patient is under regular followup for the last six months and he is asymptomatic with no evidence of recurrence.

Discussion

Malignant external otitis was first described in 1959 by Meltzer and Kelemen^[1]. Chandler is credited with naming the disorder in 1968^[2]. The disease can be aggressive and spreads through vascular and soft tissue planes into the neighboring skull base^[3]. In the final stages of the disease, multiple cranial neuropathies and septic thromboembolism may occur^[4]. This case represents an unusual presentation of fungal temporal bone (lateral skull base) osteomyelitis in an immunocompromised host. In contrast to bacterial skull base osteomyelitis, fungal skull base osteomyelitis has not been definitively associated with diabetes mellitus. Invasive fungal disease is usually caused by *Aspergillus fumigatus* and less commonly *Aspergillus flavus*.

Review of the literature revealed 9 reported cases of invasive fungal skull base osteomyelitis of the temporal bone. Given the rarity of fungal osteomyelitis, it is not surprising that almost all prior cases involved a several week delay in diagnosis secondary to misdiagnosis of necrotizing external otitis. Relatively prompt diagnosis occurred in this case because of the lack of response to conventional antibacterial therapy, and the finding fungal elements on serial examination. Definitive diagnosis of fungal skull base osteomyelitis usually requires pathologic demonstration of tissue invasion. However, technetium bone scan is very sensitive for osteomyelitis, and this was strongly positive. In addition, computed tomography revealed definite evidence of bone destruction. Pathogenic mechanisms proposed for fungal invasion include immune deficiency states (ie, neutropenia), point of entry for fungus (eg, skin breakdown), and disruption of normal bacterial flora by antibiotic use. An important distinguishing characteristic is that granulation typically is not a common finding on physical examination. This is thought to be to the diminished immune response of these patients. The infectious process often starts in the mastoid air cell or middle ear space and spreads along the skull base slowly.

Surgical debridement and an Amphotericin B are the current mainstays of treatment and the resolution of an infection greatly depends on the patient's overall health and the severity of the underlying disease. Most cases of skull base osteomyelitis do not require

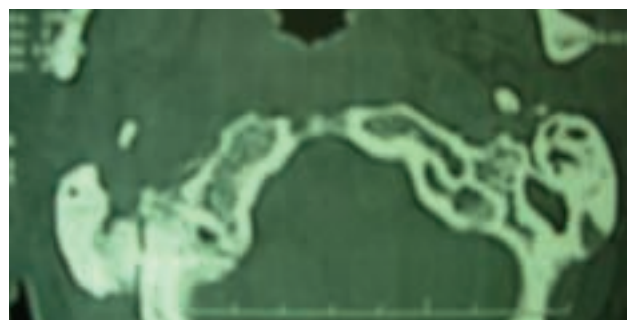


Figure 5. HRCT Temporal Bone: post treatment image. (a, b)

surgery, other than an initial biopsy if necessary and, possibly, debridement of bony or cartilaginous sequestra is sometimes sufficient in cases unresponsive to medical treatment.

Conclusions

The diagnosis of invasive fungal temporal bone osteomyelitis requires a high index of suspicion as it is often misdiagnosed as bacterial otitis externa. It is overwhelmingly associated with an immunocompromised state involving neutropenia. Surgical debridement and an Amphotericin B is the current mainstays of treatment.

References

1. Meltzer P, Kelemen G. Pyocyanous osteomyelitis of the temporal bone, mandible, and zygoma. *Laryngoscope* 1959-69; 1300-1316.
2. Chandler JR. Malignant external otitis. *Laryngoscope* 1968; 78: 1257-1294.
3. Lucente FE, Parisier SC, Som PM. Complication of the treatment of malignant external otitis. *Laryngoscope* 1983; 93:279-281.
4. Barrow HN, Levenson MJ. Necrotizing malignant external otitis caused by staphylococcus epidermidis. *Arch Otolaryngol Head Neck Surg* 1992; 118: 94-96.