

ORIGINAL ARTICLE

Transposed Canal Wall Tympanomastoidectomy*

Tuncay Ulug

Istanbul University, Istanbul Medical Faculty, Department of Otorhinolaryngology and Head and Neck Surgery, Istanbul, Turkey

Objective: The study was designed to describe and evaluate the technique of transposed canal wall (TCW) tympanomastoidectomy in the treatment of chronic otitis media with cholesteatoma.

Materials and Methods: Study design is prospective clinical study of randomly chosen 11 procedures performed from 2005 to 2008. Setting is tertiary referral center and academic practice in otology. The study population comprised of 7 males and 4 females, with an age range of 12-66 years. The interventions were based on enlarging the external auditory canal extensively and exenteration of the anterior part of the tympanomastoid with an outside-in technique, so that a new canal was created with a superior wall at the middle cranial fossa dural plate and the other walls transposed 2-3 mm posteriorly, inferiorly and anteriorly. Depending on the extension of the cholesteatoma, a separated posterior mastoidectomy was added, protecting the transposed posterior canal wall. Main outcome measures were clinical follow-up and audiological assessment.

Results: Eight patients received a TCW anterior tympanomastoidectomy and 3 patients received a TCW anterior tympanomastoidectomy combined with posterior mastoidectomy. All of the 11 ears maintained a small anterior tympanomastoidectomy cavity. There was no residual or recurrent cholesteatoma, tympanic membrane perforation, permanent otorrhea or meatal stenosis. The mean air-bone gap was found 30.18 dB HL preoperatively and 20.09 dB HL postoperatively.

Conclusion: TCW technique provides improved intraoperative exposure of the key areas without creating a mastoid bowl, reduces the incidence of recidivism, and allows for hearing restoration by only transposing the canal walls circumferentially.

Submitted : 19 February 2010

Revised : 26 February 2010

Accepted : 28 February 2010

Introduction

The main goals in the surgical management of chronic otitis media with cholesteatoma are eradication of the disease, prevention of a mastoidal bowl and restoration of the hearing mechanism. A variety of surgical approaches are currently used to remove cholesteatomas and to achieve these goals. They mainly include intact canal wall (ICW) and canal wall down (CWD) tympanomastoidectomy techniques, and their modifications (Figures 1-3). ICW techniques preserve the anatomy of the posterior canal wall and eliminate the bowl problems. However the recidivism rate is higher than with CWD techniques. CWD techniques reduce the recidivism rate. In contrast they create a mastoidal bowl needing periodic cleaning^[1,2]. To eliminate the disadvantages of both categories different techniques have been proposed; obliteration techniques, posterior canal wall temporary removal techniques, and immediate or delayed posterior canal wall reconstruction techniques using various materials^[1-5]. The proposed technique, TCW tympanomastoidectomy has been designed to increase

the exposure in the critical anterior part of the temporal bone and remove cholesteatoma safely, while preventing a large mastoidal bowl (Figure 4). In this prospective study the technique of TCW is described and the outcomes of 11 cases are evaluated.

Materials and Methods

A prospective study of patients, who underwent TCW tympanomastoidectomy techniques between 2005 and 2008, was performed. The setting was tertiary referral center and academic practice in otology. The study comprised of 11 procedures chosen randomly to be operated with the TCW technique. All the operations were performed by the author. The study population consisted of 7 males and 4 females, with an age range of 12-66 years.

A detailed database, including 26 characteristics, was prepared for prospective recordings. It was designed to record general-, operative findings-, operative technique- and follow-up data. General data included age, sex, side of surgery, date of surgery, status of the other ear and finding of preoperative HRCT; operative findings data included tympanic membrane-, ossicular

Corresponding address:

Prof. Dr. Tuncay Ulug

Istanbul University Istanbul Medical Faculty Department of Otorhinolaryngology and Head and Neck Surgery, Capa, Istanbul, Turkey

E-mail: ulugt@tmail.com

* Presented in part at the 8th International Conference on Cholesteatoma / Ear Surgery,

June 15-20, 2008, Antalya, Turkey; at the 6th Extraordinary Otitis Media Symposium, May 6-10, 2009, Seoul, Korea; and at the 27th Politzer Society Meeting, September 3-5, 2009, London, UK.

Copyright 2005 © The Mediterranean Society of Otolaryngology and Audiology

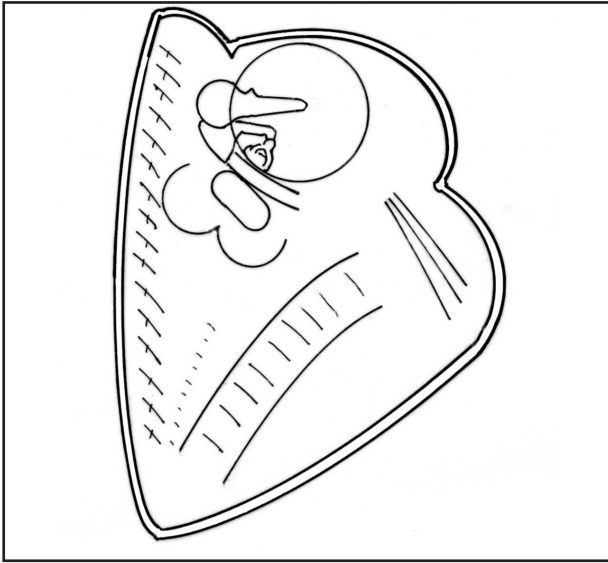


Figure 1. CWD: Canal wall down tympanomastoidectomy technique (View from anterior).

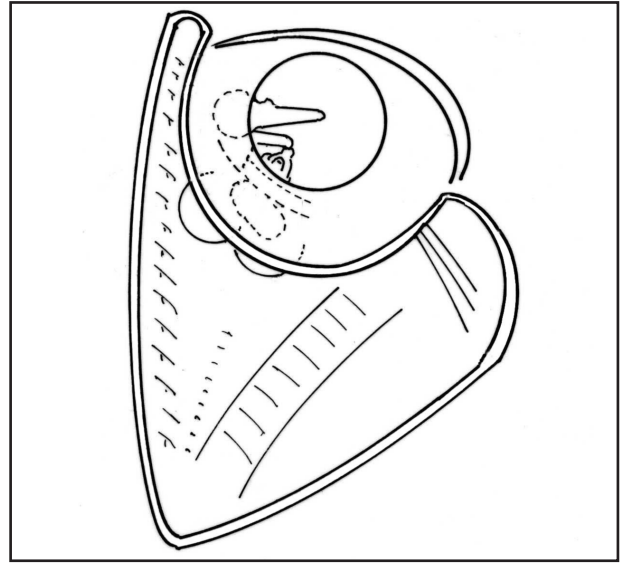


Figure 2. ICW: Intact canal wall tympanomastoidectomy technique (View from anterior).

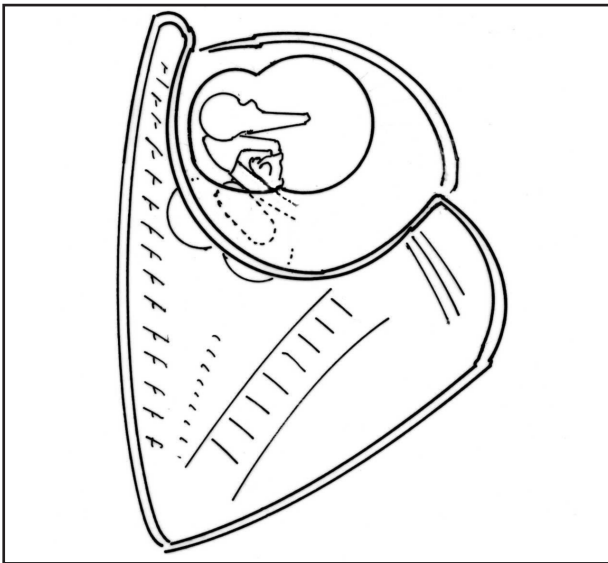


Figure 3. M-ICW: Conservatively-Modified intact canal wall tympanomastoidectomy technique (View from anterior).

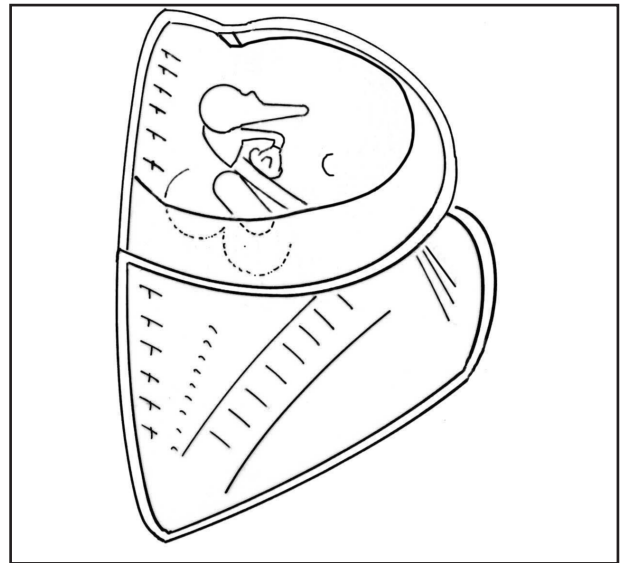


Figure 4. TCW: Transposed canal wall tympanomastoidectomy technique; isolated anterior or combined (View from anterior).

chain, cholesteatoma findings and classifications; operative technique data included type of approach, type of bony access, type of reconstruction; and follow-up data included postoperative audiological course compared to preoperative status, postoperative course of the cavity and tympanic membrane finding. The tympanic membrane status and cholesteatoma finding was described in detail. In accordance with Tos, patients were grouped according to 3 types of

cholesteatoma: attic, sinus and tensa retraction cholesteatoma^[5]. The most distant extension of the cholesteatoma from the middle ear was also defined. The ossicular chain finding was described in detail. In addition, the ossicular status was reported according to the presence (+) or absence (-) of the malleus handle (MM) and stapes suprastructure (SS)^[6].

Auditory status was evaluated according to the recommendations of the Committee on Hearing and

Equilibrium^[7]. The four pure-tone averages were used; the air- and bone pure-tone averages were calculated using air- and bone thresholds at frequencies of 0.5, 1, 2, 3 kHz. The threshold at 3 kHz was estimated as the mean of the thresholds at 2 and 4 kHz. The air-bone gap was the four pure-tone average for air conduction minus the four pure-tone average for bone conduction, preoperative and postoperative respectively. The improvement was defined by subtracting the postoperative air-bone gap value from those of the preoperative air bone gap.

Demographic characteristics, operative findings and the details of the operation were recorded on the database form after the operation. The patients were seen postoperatively in the first week and afterwards every two week on 3-4 occasions. Further follow-up included visits in the 3rd month, 6th month and at half-yearly intervals thereafter. Oto-microscopy and pure-tone audiometry were performed during these visits. All the microscopic findings and audiological evaluations were recorded on the database form during these visits.

Surgical Technique

The procedures are performed under general anesthetic and local infiltration of lidocain hydrochloride with epinephrine. Patients are given perioperative intravenous antibiotics, ampicillin-sulbactam. The procedures are carried out either through an endaural approach or a retroauricular approach. In all the approaches the rest of the operation includes the same steps; neither the design of the meatal and tympanometal flaps nor the bony work are changed according to the approach (Figure 5).

At the beginning of the operation a temporoparietal fascia-, a temporal fascia- and a tragal- or conchal cartilage graft are obtained. A classical tympanomeatal flap is elevated, followed by elevation of the laterally based posterior and anterior meatal flaps, which are preserved carefully during the drilling. In exceptional cases of sufficient anterior exposure, the anterior meatal skin may be left in place.

The initial steps in drilling are superior and posterior canal widening followed by inferior and anterior widening. This is a planned outside-in extensive drilling, which comprises of not only enlargement of the external auditory canal but also partially exenteration of the anterior part of the tympanic and mastoid bones. In this way the new canal wall is recreated regularly at the middle cranial fossa dural

plate superiorly and the other walls are transposed a couple of millimeters posteriorly, inferiorly and anteriorly (Figures 4 and 5). If more exposure is required, a mastoid facial nerve skeletonization posteriorly, jugular bulb skeletonization inferiorly, and temporomandibular joint periosteum skeletonization anteriorly may be performed through this anterior main route.

When the cholesteatoma is limited posteriorly to the aditus, all the cholesteatoma is removed through this anterior isolated tympanomastoidectomy procedure (TCW anterior tympanomastoidectomy) and when the cholesteatoma is beyond the limits of the aditus, e.g. reaching antrum, a posterior mastoidectomy is added to the procedure (TCW combined tympanomastoidectomy), protecting the transposed canal wall (Figure 4). In this case the cholesteatoma is delivered from antrum through the aditus anteriorly into the attic. The rest of the cholesteatoma is dissected through the anterior access. In either case all the delicate structures and key areas, meaning the attic, aditus, horizontal semicircular canal, tympanic facial nerve, facial recess, sinus tympani, the ossicles, oval- and round window are explored and cleared of cholesteatoma through the anterior access.

According to the finding of the ossicles, they are denuded and left intact or various ossiculoplasty techniques are performed. After total cholesteatoma removal and ossicular reconstruction, a piece of cartilage with perichondrium is used to partially fill the anterior mastoidal tegmen close to the middle cranial fossa dural plate. The attic is also reconstructed using the same or another piece of cartilage and temporal fascia. In sinus cholesteatoma cases, the posterior tympanic membrane area and in tensa cholesteatoma cases, the whole tympanic membrane are also reconstructed using cartilage and temporal fascia. The rest of the temporal fascia and the temporoparietal fascia are used to cover any bare bony areas. The laterally based posterior and anterior meatal flaps are placed over the graft lining the cavity. If required, the incisions of the posterior meatal flap are slightly extended laterally to fit the flap better to the posterior wall of the cavity. The small cavity is packed with several pieces of gelfoam. In case of combined TCW, any additional procedure is applied to the posterior mastoidectomy cavity. The wound incision is closed in layers and dressed with a bandage.

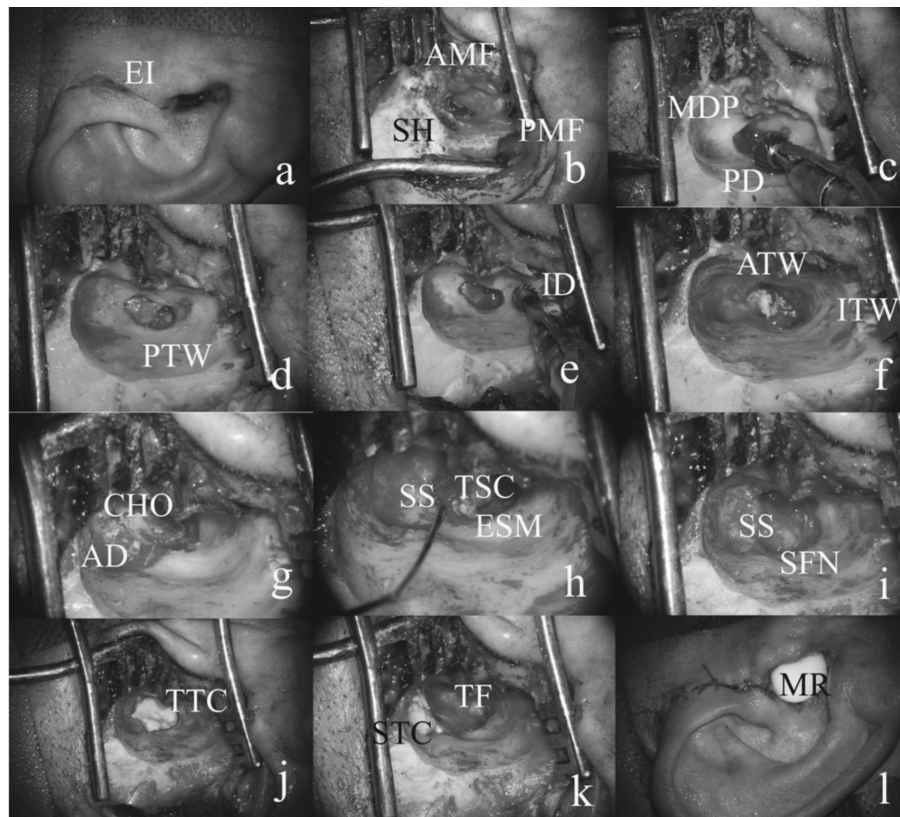


Figure 5. Operation steps; TCW anterior tympanomastoidectomy (endaural; tensa cholesteatoma; type 3 reconstruction).

Abbreviations: EI, endaural incision; SH, spine of Henle; AMF, anterior meatal flap; PMF, posterior meatal flap; MDP, middle cranial fossa dural plate; PD, posterior drilling; PTW, posteriorly transposed wall; ID, inferior drilling; ITW, inferiorly transposed wall; ATW, anteriorly transposed wall; CHO, cholesteatoma; AD, aditus; SS, stapes superstructure; TSC, tympanic sinus cholesteatoma; ESM, exposed stapedial muscle; SFN, skeletonized mastoidal facial nerve; TTC, tympanic membrane reconstruction with tragal cartilage; STC, superior wall reconstruction with tragal cartilage; TF, temporal fascia; MR, merocele.

Results

The study comprised of 11 ears in 8 adults and 3 children who underwent the procedure.

Table 1 summarizes the patient population by sex, age, date of operation, follow up time, side and the status of other side. The population included 7 males and 4 females, with an age range of 12-66 years (mean 35). Preoperative CT scans revealed findings consistent with the peroperative findings. The operation was performed on the left side in 7 cases and in 4 cases on the right. Mean follow up time was 20 months.

Table 2 describes the operative findings of the population including classification of cholesteatoma, the finding of tympanic membrane and cholesteatoma the extension of cholesteatoma, the finding of the ossicular chain and classification of ossicular status. In accordance with Tos cholesteatoma classification, 5 patients had attic cholesteatoma, 3 sinus cholesteatoma and 3 tensa cholesteatoma. The mucosa of the tympanic cavity was near normal in all cases except the 3 ears with tensa

cholesteatoma. Cholesteatoma was limited to the tympanic cavity in 2 cases, localized or extended into the attic in 2 cases, extended into aditus in 4 cases, and into antrum in 3 cases. The ossicular status evaluation, according to the presence or absence of malleus handle and stapes suprastructure, revealed in 8 cases MM+SS+, in 2 cases MM+SS- and in 1 case MM-SS-.

Table 3 summarizes the operation details including type of approach, type of bony access, type of reconstruction of anterior mastoidal tegmen, of tympanic membrane and of ossicular chain. The soft tissue approach was endaural in 8 cases, retroauricular in 2 cases and retroauricular with endaural relaxation incision in 1 case. In 8 patients the bony access was limited to the anterior part, i.e. only TCW anterior tympanomastoidectomy was performed. In 3 patients the anterior as well as the posterior bony access was used, i.e. TCW combined tympanomastoidectomy was performed. For reconstruction of anterior tegmen mastoidea tragal cartilage with perichondrium,

Table 1: General Data

Patient No.	Sex	Age	Date of Operation	Follow-up Time	Side	Status of the Other Ear
1	F	66	April, 2, 2005	34 Months	L	38 dB NSHL
2	M	12	June, 5, 2005	31 Months	L	N
3	M	12	September, 6, 2005	29 Months	L	Adhesive OM
4	F	26	September, 19, 2005	29 Months	L	COM
5	F	42	April, 3, 2006	22 Months	R	N
6	M	37	September, 4, 2006	17 Months	R	Operated COM
7	M	26	September, 15, 2006	17 Months	R	N
8	F	52	November, 9, 2006	15 Months	L	COM
9	M	40	January, 12, 2007	14 Months	L	N
10	M	14	April, 12, 2007	10 Months	L	N
11	M	59	January, 2, 2008	2 Months	R	Rad. mastoidectomy with total hearing loss.
Total,	7 M	Mean	April, 2, 2005 -	Range:	7 L	5 N
Distri.,	4 F	35	January, 2, 2008	2-34 Months	4 R	3 COM
Mean,				Mean:		2 Operat. COM
Range				20 Months		1 NSHL

M, male; F, female; R, right; L, left; N, normal; COM, chronic otitis media; OM, otitis media; dB HL, decibel hearing level; NSHL, neurosensorial hearing loss. All audiological results are in dB HL as PTA, pure-tone average threshold for 0.5, 1, 2, 3 kHz.

temporal fascia and temporoparietal fascia were used in 9 cases and, conchal cartilage with perichondrium, temporal fascia and temporoparietal fascia were used in 2 cases. The attic was reconstructed in all 11 cases with cartilage and covered with temporal fascia. In sinus cholesteatoma- and tensa cholesteatoma cases, with some exceptions, the posterior tympanic membrane area was also supported with cartilage. Posterosuperior reconstruction with cartilage was performed in 2 cases (Cases 4 and 11) to prevent retraction, in 1 case (Case 5) to use as an interposition graft between malleus and stapes suprastructure, in 1 case (Case 7) for both purposes, in 1 case (Case 2) to cover TORP. In 1 case with tensa cholesteatoma (Case 3), because of total adhesion, a large cartilage tympanoplasty was preferred. In cases of attic cholesteatoma without pathology in the pars tensa, posterosuperior cartilage reconstruction was not used. All the tympanic membrane reconstructions were performed using the underlay technique, except in case 11, where because of subtotal perforation an overlay technique was preferred. Different types of ossiculoplasty were used to reconstruct the hearing mechanism. In 2 cases with intact but partially eroded ossicles (Cases 3 and 4) the chain was left intact. In 3 cases (Cases 5, 7 and 10) some type of interposition graft was used. In 1 case (Case 2) TORP; in 1 case (Case 1) incus columella between malleus handle and stapes footplate was preferred. Three cases (Cases 6, 8 and 9) were reconstructed as Type III tympanoplasty and 1 case with total destruction of all three ossicles (Case 11) was planned for a second stage ossiculoplasty.

The follow up data on the audiological evaluation and postoperative course are summarized in Table 4. These included postoperative audiological data compared to preoperative status, postoperative complication records and course of the cavity- and tympanic membrane finding. The mean air-bone gap according to the four pure-tone air- and bone conduction threshold averages was found to be 30.18 dB HL preoperatively and 20.09dB HL postoperatively. The mean gain in the air-bone gap was 10.09 dB HL. The postoperative hearing status at the final evaluation was better than at the preoperative in 8 cases, did not change in 3 cases. In 2 of these cases (Cases 3 and 10) the hearing was good preoperatively as well as postoperatively and in the last case, because of extensive destruction, the hearing restoration was left for a second stage without any primary reconstruction. Temporary postoperative complications were encountered in two cases. One patient (Case 5) had postoperative cavity infection in the early postoperative period, which resolved after a short period local therapy. The other patient (Case 7) had granulation problems, also in the early postoperative period, in the medial part of the cavity close to the new tympanic membrane, which resolved after office excisions of the granulations. As permanent complication, only one case with a classical type 3 reconstruction, i.e. without posterosuperior cartilage support (Case 6) showed slight retraction in the posterior mesotympanum without the need for further surgery. All of the 11 ears maintained a small and dry

Table 2. Operative Findings Data

Patient No.	Classification of Cholesteatoma	Finding of Tympanic Membrane/ Cholesteatoma	Cholesteatoma Extension	Classification of Ossicular Status	Finding of Ossicular Chain
1	Attic	Attic perforation, chol. invading attic along the lateral side of I and M	Attic	MM+ SS-	Destruction of all the LPI and SS
2	Attic	Attic perf., chol. invading attic, aditus, FR, ST and OW	Aditus	MM+SS-	Destruction of all the LPI and SS
3	Tensa	Adhesion in the pars tensa of TM with retraction into the retrotymp. and ST	Tympanic cavity	MM+SS+	Ossicular chain is intact, only LPI is thinned
4	Sinus	Posterosup. perf., chol. invading along lateral side of S-I-M attic aditus medial portion of antrum	Medial portion of antrum	MM+SS+	Ossicular chain is intact, only partial erosion of MH and SPI
5	Attic	Attic perf. (combined with 3 mm. central perf.), chol. invading attic aditus and medial portion of antrum	Medial portion of antrum	MM+SS+	Total destruction of MH and I
6	Attic	Attic perf. (combined with limited postero-superior retraction), chol. invading attic and aditus	Aditus	MM+SS+	Destruction of all the LPI
7	Sinus	Posterior retraction, chol. invading along medial side of M-I attic, aditus and antrum	Antrum	MM+SS+	Extreme destruction of I, ancylosis of MH
8	Sinus	Posterosuperior perf., chol. invading attic supratubal recess and aditus	Aditus	MM+SS+	Destruction of all the LPI
9	Tensa	Perf. anterior to malleus, chol. invading superior mesotympanum and attic with supratubal recess	Attic	MM+SS+	Destruction of the LPI
10	Attic	Attic perf., chol. invading attic and aditus	Aditus	MM+SS+	Partial destruction of MH and BI
11	Tensa	Subtotal perf., chol. invading OW, FR, ST and posterior mesotymp.	Tympanic cavity	MM-SS-	Extreme destruction of MM, LPI and SS
Total, Distr.	5 Attic 3 Sinus 3 Tensa	—	2 Tymp. cavity 2 Attic 4 Aditus 3 Antrum	8 MM+SS+ 2 MM+SS- 1 MM-SS-	—

Chol, cholesteatoma; TM, tympanic membrane; M, malleus; MM, manubrium mallei; MH, malleus head; I, incus; LPI, long process of incus; SPI, short process of incus; BI, body of incus; S, stapes; SS, stapes suprastructure; OW, oval window; FR, facial recess; ST, sinus tympani.

anterior tympanomastoidectomy cavity which was two times larger than a normal external auditory canal. There was no residual or recurrent cholesteatoma, tympanic membrane perforation, permanent otorrhea or meatal stenosis.

Discussion

TCW tympanomastoidectomy provides improved exposure of the delicate anatomical structures and key areas without creating a mastoidal bowl. It is a one stage, planned, outside-in technique resulting in a small anterior tympanomastoidectomy cavity, which is two times larger than a normal external auditory canal.

It affords safe cholesteatoma removal, prevention of cholesteatoma recidivism and restoration of the hearing mechanism.

Before the 1950's, the only surgery that was popularly used for chronic suppurative otitis media was modified radical mastoidectomy, i.e.. CWD tympano mastoidectomy^[8,9]. In the late 1950's combined approach tympanoplasty, i.e. ICW was described and gained popularity among otologists^[10,11]. In CWD techniques removal of the canal wall improves exposure and affords complete removal of cholesteatoma. However the postoperative healing

Table 3. Operative Technique Data

Patient No.	Soft Tissue Approach	Bony Access	Reconstr.of Anterior Tegmen Mastoidea	Reconstr. of Tymp. Membrane	Classification of Tymp. Membrane Reconstr.	Reconst. of Ossicular Chain	Classsif. of Ossicular Chain Reconstr.
1	Endaural	Anterior TCW	TC with PC+ TF+TPF	TF with TC support at attic + grommet	Underlay/ Pars tensa of TM left intact	I sculptured between MM and SF	Columella / MM remov, I remnant used
2	Endaural	Anterior TCW	TC with PC+ TF+TPF	TF with large TC as attic-TORP coverage	Underlay/Ant. remnant of TM left intact	TORP between MM and SF	TORP/ MTTT left intact MM- I removed
3	Endaural	Anterior TCW	TC with PC+ TF+TPF	TF with TC as reinforcem.	Underlay/Ant. remnant of TM left intact	Ossicular chain left intact	Intact chain /Partially eroded
4	Endaural-extended	Combined TCW	TC with PC+ TF+TPF	TF with TC support at attic-postsup.	Underlay/Ant. remnant of TM left intact	Ossicular chain left intact	Intact Chain / Partially eroded
5	Retroauric -with osteoplast Palva flap	Combined TCW	CC with PC+ TF+TPF	TF with CC covering cent. perf. attic-posts.	Underlay/ Pars tensa of TM left intact perf. reconst.	CC-Interpos between MM and S	Interposition /MH-I totally destructed
6	Endaural	Anterior TCW	TC with PC+ TF+TPF	TF with TC support at attic	Underlay/ Pars tensa of TM left intact	Classical Type III	Type III / MH-I remn. removed
7	Retroauric -with osteoplast Palva flap	Combined TCW	CC with PC+ TF+TPF	TF with CC support at attic and post reinfor	Underlay/ Retracted TM left intact	CC-interpos between MM and S	Interposition /MH-I remn. removed
8	Endaural	Anterior TCW	TC with PC+ TF+TPF	TF with TC support at attic	Underlay/ Pars tensa of TM left intact	Classical Type III	Type III / MH-I remn. removed
9	Endaural	Anterior TCW	TC with PC+ TF+TPF	TF with TC support at attic	Underlay / Circumferent remnant of TM left intact	Type III with an addition of small TC	Type III / MH-I remn. removed
10	Endaural	Anterior TCW	TC with PC+ TF+TPF	TF with TC support at attic	Underlay/ Pars tensa of TM left intact	I-interpos. between MM and S	Interposition /MH-I remn. removed
11	Retroauric with endaural relax incis	Anterior TCW	TC with PC+ TF+TPF	TF with TC support at attic-postsup.	Overlay/ Remnant of TM removed	2. stage ossi-plasty planned	None / MH-I remn. removed
Total, Distr.	8 Endau. 2 Retroa. 1 Retroa. with relax	8 Anteri. 3 Combi.	9 TC+fascia 2 CC+fascia	—	10 Underlay 1 Overlay	—	2 Intact ch 3 Interpos. 3 Type III 1 TORP 1 Columella 1 None

TM, tympanic membrane; MM, manubrium mallei; MH, malleus head; I, incus; S, stapes; SF, stapes footplate; MTTT, tendon of tensor tympani muscle; TC, tragal cartilage; CC, conchal cartilage; TF, temporal fascia; TPF, temporoparietal fascia; PC, perichondrium; TORP, total ossicular replacement prosthesis.

time is long, the resulting large cavity is prone to bowl infections and retention cholesteatoma, and do require periodic cleaning^[3,4]. The retrograde modification of this technique, e.g. beginning with an atticotomy and enlarging the cavity with an inside-out procedure, results also in most instances in a large atticotomy cavity. Preservation of the canal wall in ICW techniques maintains the normal anatomy of the external auditory canal, shortens the postoperative healing time and

avoids cavity problems. However, surgical exposure of the key areas in the attic and mesotympanum is limited, leading to higher residual cholesteotoma rates; and the preservation of the posterior canal wall in its natural position is prone to retraction, leading to higher recurrence rates^[2,5].

To resolve the disadvantages and combine the advantages of ICW and CWD tympanomastoidectomy, many techniques have been proposed. Mastoid

Table 4. Audiological and postoperative course data

Patient No.	Preop. Air- and Bone- PTA	Preop. Air-Bone Gap	Postop. Air- and Bone- PTA	Postop. Air-Bone Gap	Gain in Air-Bone Gap	Complication: Temporary / Permanent	Current Status of Cavity
1	80 / 47	33	62 / 47	15	-18	None	Small cavity,dry/ Intact membrane
2	41 / 8	33	30 / 8	22	-11	None	Small cavity,dry/ Intact membrane
3	18 / 1	17	18 / 1	17	0	None	Small cavity,dry/ Intact membrane
4	35 / 10	25	20 / 10	10	-15	None	Small cavity,dry/ Intact membrane
5	57 / 10	47	25 / 10	15	- 32	Postoperative infection	Small cavity,dry/ Intact membrane
6	40 / 8	32	35 / 8	27	- 5	Limit. retraction at posterior TM	Small cavity,dry/ Intact membrane
7	33 / 7	26	25 / 7	18	- 8	Postoperative granulations	Small cavity,dry/ Intact membrane
8	35 / 10	25	33 / 10	23	- 2	None	Small cavity,dry/ Intact membrane
9	52 / 5	47	32 / 5	27	- 20	None	Small cavity,dry/ Intact membrane
10	13 / 1	12	13 / 1	12	0	None	Small cavity,dry/ Intact membrane
11	50 / 15	35	50 / 15	35	0	None	Small cavity,dry/ Intact membrane
Total, Distr.	—	Range: 12-47 Mean: 30.18	—	Range: 12-35 Mean: 20.09	Range: 0-32 Mean: 10.09	1 Retraction 2 Postop. Infect. -Granul.	11 Cavities without problem

PTA, four pure-tone average threshold; dB HL, decibel hearing level; TM, tympanic membrane. All audiological results are in dB HL; PTA, average threshold for 0.5, 1, 2, 3 kHz.

obliteration techniques including Palva flap and inferior based musculoperiosteal flap have long been used to decrease the size of the cavity after CWD procedures^[2]. The long-term follow up of these techniques revealed that following shrinkage of soft tissue, the cavity problems partially reappeared. Ceramics, hydroxyapatite granules, demineralized bone matrix, bone paste and titanium have been used to obliterate the cavity or to reconstruct the posterior canal wall. The main drawback of these techniques is a higher infection rate^[2,12]. In the current study, although only a short period perioperative antibiotic coverage was used; in only one case did postoperative infection occur, and short local therapy was enough to overcome the infection. Postoperative infection is not a concern in TCW tympanomastoidectomy. Temporary removal of the posterior canal wall and replacement at the end of the operation has also been used by different authors. This technique affords complete removal of cholesteatoma and

reconstruction near normal anatomy^[1,2,5]. The major drawback of this technique is also that the postoperative infection rate is higher than in classical techniques and postoperative infections may result in partial destruction of the reconstructed posterior canal wall. The other minor drawback is the possibility of formation of recurrent retraction pockets^[2]. To reduce infection rates and infection related problems 48 hours intravenous antibiotics usage and 48 hours drainage followed by long period oral antibiotics take, and to overcome formation of retraction pockets blockage of the attic with bone chips have been advocated^[2]. Furthermore, for CWD procedures, delayed reconstruction techniques of the posterior canal wall with cortical bone or ceravital have been described^[3,4]. Additionally, to overcome the disadvantages of ICW and CWD, modified combined approach tympanoplasty and combined approach tympanoplasty with anterior atticotomy have been described^[13,14]. The main contribution of these

techniques to classical ICW have been better exposure of the attic through transmeatal atticotomy following the recommendations of Lempert many decades ago^[9,15]. The common feature of these approaches, which are used in selective indications, are that the external auditory canal is only enlarged superiorly towards middle cranial fossa like in atticotomy or in atticoaditotomy and left untouched posteriorly, inferiorly and anteriorly, meaning the posterior wall is in the same position like in ICW. In these approaches the exposure in the retrotympanum, facial recess and hypotympanum is afforded with exenteration of bone only around posterior tympanic annulus and therefore the exposure in these areas is limited.

The proposed technique, TCW tympanomastoidectomy, has been designed to form a new relatively large external auditory canal wall with a superior wall at the middle cranial fossa plate and the other walls transposed 2-3 mm posteriorly, inferiorly and anteriorly. The procedure has the primary intention of creating the new canal at an exact location and exposure of the cholesteatoma is the separate, second step of the procedure. Following this planned, outside-in extensive drilling and creating an anterior tympanomastoid cavity, the cholestatoma exposure and removal begins. The goal of the technique is to remove all the cholesteatoma through the anterior approach. A posterior mastoidectomy is added, only if the cholesteatoma extends beyond the posterior entrance of the aditus or if extensive hypertrophic mucosal disease with granulations and polyps exists. Because the posteriorly transposed canal wall is in the ideal position, there is no need to change the operation to a CWD procedure, which is often performed by inexperienced surgeons in difficult cases during ICW operations. The only restriction of TCW tympanomastoidectomy is an extensively destroyed or thinned posterosuperior wall with cholesteatoma which prevents skeletonization of the anterior antrum wall.

In TCW tympanomastoidectomy, cholesteatoma resection is safe as with a CWD procedure and because of partially exteriorisation, the recurrence rate is also low. To prevent retraction pockets, the attic was reconstructed in all cases with cartilage and the posterosuperior quadrant was also supported with cartilage according to the needs of the case. In only one case, because a classical type 3 tympanoplasty was performed without any use of cartilage support in the

posterosuperior area, limited retraction of the tympanic membrane in the posterosuperior area occurred. In this technique, the retraction and cholesteatoma recurrence risk is reduced because of the exteriorized shape of the cavity and usage of the cartilage for tympanic and attic reconstructions. Recurrences would also be detected early in TCW tympanomastoidectomy, because they would be expected to occur in the anterior cavity; through office inspection it is possible to notice recidivism early on and possibly treat it with an office procedure. In this series no recidivism was noticed.

The reconstruction in TCW is nearly as good as in the ICW technique. The resulting cavity which has the shape of a cut cone is only two times larger than a normal external auditory canal. The intact bony walls prevent bowl problems and provides the best protection against invasion and extension of cholesteatoma in cases of recidivism. There is no need for a classical meatoplasty. The healing time of the new canal is comparable to that of a canalplasty, because nearly all the bony areas are covered with some connective tissue, i.e. meatal flaps, cartilage or fascia. Cavity problems do not exist because of the limited volume of the cavity. In this series there was granulation-tissue reaction in only one case, and which resolved after a short period of local therapy. All of the 11 ears maintained a small and dry anterior tympanomastoidectomy cavity. There was no residual or recurrent cholesteatoma, tympanic membrane perforation, permanent otorrhea or meatal stenosis. The position of the pinna did not change in any case, which may be a problem in conventional- and in muscle obliterated CWD procedures.

The exposure in TCW technique not only facilitates cholesteatoma removal, but also affords the surgeon the potential to preserve the normal middle ear hearing mechanism. Complete exposure of all the ossicles through the same route, enables in some cases the integrity of the ossicular chain to be protected, which results in the best hearing condition. In two cases with partially eroded but intact ossicular chain, cholesteatoma was removed from the ossicular chain without disrupting the middle ear transformer mechanism, which is very difficult in ICW techniques. The hearing results are comparable to ICW tympanomastoidectomy; the support points around the ossicles and new tympanic membrane are sufficient for good hearing restoration. In this series, different types of ossiculoplasty including interposition, columella,

type 3, TORP and chain protection, were used to reconstruct the hearing mechanism. The mean air-bone gap according the four pure-tone air- and bone conduction threshold averages was found 30.18 dB HL preoperatively and 20.09dB HL postoperatively. The mean gain in the air-bone gap was 10.09 dB HL.

Chronic otitis media with a cholesteatoma continues to be a medical problem having the risk to result in serious complications. A variety of surgical approaches are currently used to remove cholesteatomas and to achieve the goals of eradication of the disease, prevention of a mastoidal bowl and restoration of the hearing mechanism. The findings of this study show that the TCW tympanomastoidectomy procedure may be used as an alternative technique in cholesteatoma surgery. Firm conclusions on differences in the rates of advantages, disadvantages including the effect of the mastoid, hearing gains, recidives, recurrences and complications between different techniques require larger prospective trials.

Conclusion

In conclusion, the TCW technique provides improved intraoperative exposure of the key areas and delicate structures attic, aditus, horizontal semicircular canal, tympanic facial nerve, facial recess, sinus tympani, oval, round window and all the ossicles without creating a mastoid bowl. When the cholesteatoma is limited posteriorly to the aditus, it is removed through TCW anterior tympanomastoidectomy and when the cholesteatoma is beyond the limits of aditus, it is removed through TCW combined tympanomastoidectomy, protecting the TCW. This one stage procedure reduces the incidence of recidivism and allows for hearing restoration by only transposing the canal walls circumferentially.

References

1. McElveen JT Jr, Chung AT. Reversible canal wall down mastoidectomy for acquired cholesteatomas: preliminary results. *Laryngoscope* 2003; 113:1027-33.
2. Gantz BJ, Wilkinson EP, Hansen MR. Canal wall reconstruction tympanomastoidectomy with mastoid obliteration. *Laryngoscope* 2005; 115:1734-40.

3. Sasaki Y, Iino Y, Suzuki J. Posterior canal wall reconstruction tympanoplasty for operated ears with open mastoid. *Acta Otolaryngol* 2002; 122:249-54.
4. Della Santina CC, Lee SC. Ceravital reconstruction of canal wall down mastoidectomy: long-term results. *Arch Otolaryngol Head Neck Surg* 2006; 132:617-23.
5. Babighian G. Posterior and attic wall osteoplasty: hearing results and recurrence rates in cholesteatoma. *Otol Neurotol* 2002; 23:14-7.
6. Austin DF. Ossicular reconstruction. *Otolaryngol Clin North Am* 1972; 5:145-60.
7. Committee on Hearing and Equilibrium guidelines for the evaluation of results of treatment of conductive hearing loss. American Academy of Otolaryngology-Head and Neck Surgery Foundation, Inc. *Otolaryngol Head Neck Surg* 1995; 113:186-7.
8. Bondy G. Totalaufmeisselung mit Erhaltung von Trommelfell und Gehörknöchelchen. *Monatschrift für Ohrenheilkunde und Laryngo-Rhinologie* 1910;44:15-23.
9. Lempert J. Lempert endaural subcortical mastoidotomy for the cure of chronic persistent suppurative otitis media. *Arch Otolaryngol* 1949; 49:20-35.
10. Jansen C. The combined approach for tympanoplasty. *J Laryngol Otol* 1968; 82:779-93.
11. Sheehy JL, Patterson ME. Intact canal wall tympanoplasty with mastoidectomy. A review of eight years' experience. *Laryngoscope* 1967; 77:1502-42.
12. Black B. Mastoidectomy elimination: obliterate, reconstruct, or ablate? *Am J Otol* 1998; 19:551-7.
13. Tos M. Modification of combined-approach tympanoplasty in attic cholesteatoma. *Arch Otolaryngol* 1982; 108:772-8.
14. Farrior JB. The canal wall in tympanoplasty and mastoidectomy. *Arch Otolaryngol* 1969; 90:706-14.
15. Lillie HI, Simonton KM. The mastoid incision; endaural or postauricular? *Surg Clin North Am* 1949; 29:1093-6.