

## ORIGINAL ARTICLE

### Stapedectomy Gusher: A Clinical Experience

Hassan Wahba, Tamer Youssef

Ain Shams University, Otolaryngology Dept. Cairo, Egypt

**Objective:** Purpose of this study is to review the experience of other authors and to present our experience with the stapes 'gusher' regarding the clinical and radiological findings, intraoperative and postoperative management.

**Materials and Methods:** In the period from 1998 to 2008, 83 patients (107 ears) diagnosed with otosclerosis were operated at the Department of Otorhinolaryngology of Ain Shams University Hospitals. From the 107 ears, we encountered six cases (5.6%) of perilymph gusher during stapedectomy. Five patients had familial history of decreased hearing in male brothers and audiological examination of the brothers showed mixed hearing loss and the last patient was a female patient who showed history of decreased hearing in 2 sisters. CT-scan temporal bone was done in the six patients, postoperatively in 2 cases and preoperatively in 4 cases. Only one of them showed wide cochlear aqueduct. In the six cases piston with fat seal around was placed.

**Results:** The perilymphatic leak was stopped effectively in three patients intraoperatively. In the other three patients the leak continued from 4 to 13 days postoperatively, in these patients there was marked postoperative vertigo. Three patients showed marked improvement in hearing, one patient showed mild improvement in hearing and two patients encountered sensorineural hearing loss and needed hearing aids.

**Conclusion:** We can conclude from our work and other authors' experience that anticipation of a stapes gusher preoperatively should be suspected if there is an X-linked family history of hearing loss in individuals who show a mixed type of hearing loss. In all of these cases, a high resolution, thin section CT should be performed, looking for abnormalities of the internal auditory canal, cochlear aqueduct and the labyrinthine structures.

Submitted : 22 June 2009

Revised : 02 December 2009

Accepted : 07 March 2010

## Introduction

The otologic surgeons who have encountered the rare "stapes gusher" during routine stapedectomy will attest to the fact that this is dramatic, often catastrophic, and the management, usually problematic.<sup>[1]</sup> "Gusher" is a sudden and profuse perilymphatic flow that occurs immediately after stapedotomy and often fills up the middle ear and external canal.<sup>[2]</sup>

X-linked deafness with stapes gusher is associated with a communication between the subarachnoid and perilymphatic spaces, probably caused by a deficiency or absence of the bony plate—the so-called lamina cribrosa—separating the lateral end of the IAC from the basal turn of the cochlea.<sup>[3-8]</sup> This communication provokes elevation of the perilymphatic pressure and stapes' foot plate fixation with impairment in the conductive component of hearing. Even the milder manipulation of the stapes during surgery can induce a stapes gusher in these patients. Also, the perilymphatic hydrops also causes progressive cochlear nerve dysfunction, affecting the sensorineural component of hearing. The overall

consequence is mixed progressive severe hearing loss with perilymphatic gusher during stapes surgery.<sup>[3-5 7-9]</sup>

Nance et al. established that the X-linked transmission of congenital mixed hearing loss is associated with a fixed stapes footplate and perilymph gusher during attempted stapedectomy.<sup>[9]</sup> The first and the largest case series describing the CT features of congenital X-linked mixed hearing loss was published by Phelps et al.<sup>[6]</sup> In that study, imaging features of X-linked deafness across seven pedigrees were reported. Sixteen of 24 affected male patients were found to have bulbous internal auditory canals and incomplete separation of basal turn of cochlea from the fundus of the internal auditory canals. Widened first and second parts of the intratemporal facial nerve canals were also seen. These findings were bilaterally observed.

The rarity of this condition and the small number of patients studied in the previous studies do not give us any criteria for diagnosing or managing it. In this study, a review of our experience and other authors' experiences regarding stapedectomy gusher will be discussed.

#### Corresponding address:

Dr Tamer Ali Youssef

3 Ahamed Sanan street, Saint Fatima square, Heliopolis, Cairo, Egypt (11361)

Phone: 002020101587000; Fax : +20235179272; Email: tayoussef@yahoo.com

Copyright 2005 © The Mediterranean Society of Otolaryngology and Audiology

## Materials and Methods

In the period from 1998 to 2008, 83 patients (107 ears) aged 17- 51 years diagnosed as having otosclerosis were operated at the Department of Otorhinolaryngology of Ain Shams University Hospitals by both authors. The medical history and audiological findings of all the patients met the criteria of otosclerosis. None of the patients was afflicted with chronic inflammatory conditions of the ears nor suffered from head injury in the past. All patients underwent full ENT examination and audiological evaluation. Preoperative CT scan was not done routinely but ordered when the patient had mixed hearing loss or had a family history of hearing loss in male brothers. Postoperative CT scan was done in the patients who developed gusher and did not have a preoperative CT scan.

From the 107 ears operated on, six cases (5.6%) of perilymph gusher during stapedotomy (Table 1) were met. Five males and one female, all of them showed mixed hearing loss on audiological evaluation. The five male patients had familial history of decreased hearing in male brothers, and audiological examination of the brothers showed mixed hearing loss. The female patient had familial history of mixed hearing loss in two sisters and audiological examination of the sisters showed mixed hearing loss.

CT-scan of temporal bone was done preoperatively in ten cases from the 83 patients and postoperatively in two cases. Of the suspected ten cases only four cases developed gusher and their preoperative CT-scan was normal. Postoperative CT-scan was done in two cases, one of them was a female patient for whom we did not think that she would develop gusher and her CT-scan was normal; and the other patient was a male patient who refused to have a preoperative CT-scan and his postoperative CT-scan showed a wide cochlear aqueduct (Figure 1).

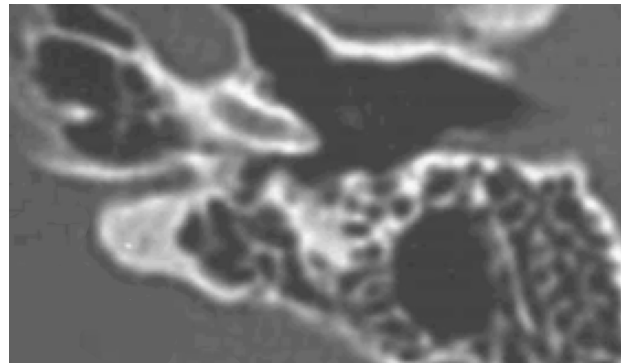
In the 6 cases piston with fat seal the around was placed.

Operative management of gusher in the six cases:

- Fine suction inferior to the oval window.
- Diuretics and mannitol 10%.
- Raising head to 45 degrees after initially lowering the head for a few minutes.
- Lumbar drain was not required in all cases.
- Proceeding and placing the prosthesis with fat seal from the ear lobule (one- stage procedure).

Postoperative management of gusher:

- Continue hospitalization until vertigo improves.
- Semisitting position.
- No straining (laxatives).
- Diuretics (one tablet furosemide daily).
- Mannitol 10% (100 cc daily).
- IV Antibiotics for prophylaxis from meningitis.
- Ear dressing with assessment of perilymph leak.
- Tight packing of external canal with sterile gelfoam.
- Analgesics for headache.
- Observation for symptoms and signs of meningitis (fever, neck rigidity, fundus examination).



**Figure 1.** Wide cochlear aqueduct.

## Results

In three patients the perilymphatic leakage stopped effectively during surgery. In the other three patients the leak continued from 4 to 13 days postoperatively. In these patients there was marked postoperative vertigo. Three patients showed marked improvement in hearing, and one patient showed mild improvement in hearing while two patient suffered from sensorineural hearing loss and needed hearing aid. These two patients had postoperative leaks lasting 8 and 13 days with marked vertigo.

## Discussion

Stapes gusher is a dreadful complication because it can cause long-term vertigo and additional sensorineural hearing loss. <sup>[4]</sup> There have been only few referrals to this entity mostly in the form of case reports and its findings on polytomography <sup>[4, 5]</sup> and computerized tomography <sup>[10, 11]</sup>. All the authors agreed that this disease shows an X-recessive type of inheritance, since the male patients had severe mixed hearing loss

**Table 1:** Summary of results

Patients	Age	Sex	CT-scan	Preoperative Hearing loss	Surgical Outcome	Prognosis after 6 months	Cessation of Postoperative Leakage
1	33	male	Preop. Normal	Mixed HL ABG=35dB B.C. 35dB	Piston with seal	ABG=30dB	4 days
2	42	male	Postop. wide cochlear aqueduct	Mixed HL ABG=25dB B.C. 35dB	Piston with seal	SNHL (hearing aid)	13 days
3	38	male	Preop. Normal	Mixed HL ABG=35dB B.C. 30dB	Piston with seal	ABG=15dB	During surgical procedure
4	41	male	Preop. Normal	Mixed HL ABG=35dB B.C. 35dB	Piston with seal	ABG=15dB	During surgical procedure
5	34	male	Preop. Normal	Mixed HL ABG=5dB B.C. 35dB	Piston with seal	SNHL (hearing aid)	8 days
6	27	female	Postop. Normal	Mixed HL ABG=35dB B.C. 35dB	Piston with seal	Excellent no CHL	During surgical procedure

(Preop.: Preoperative, Postop.: Postoperative, HL: hearing loss, SNHL: sensorineural hearing loss, B.C.: Bone conduction, ABG: Air Bone Gap).

**Table 2.** Imaging features of X-linked congenital mixed deafness (findings bilateral in all patients) <sup>[12]</sup>

Authors	Total Number of Patients/Gender	Enlarged IAC	Absent/Hypoplastic Bony Plate at Fundus of IAC	Absent Modiolus	Abnormal Vestibular Aqueduct	Wide Facial Nerve Canal
Phelps et al. (6)	24/male	16	16	Not described	Not described	16
Talbot and Wilson (10)	4/male	3	4	4	4	4
Tang and Parnes (7)	2/male	2	2	2	Not described	1
Papadaki et al (16)	2/female	2	2	Not described	Not described	2

at all frequencies, while the obligate female carriers were normal or had mild hearing impairment.<sup>[1]</sup> Preoperative recognition of this entity plays an important role in the identification of patients at risk for perilymphatic stapes gusher and avoids worsening of sensorineural hearing loss. In all of these cases, a high resolution, thin section CT should be performed, looking for abnormalities of the internal auditory canal (IAC), cochlear aqueduct and the labyrinthine structures.<sup>[12]</sup>

Different gene loci for nonsyndromic deafness are designated DFN (DeafNess). Genes inherited in an autosomal dominant manner are designated (DFNA), while genes inherited in an autosomal recessive manner are designated (DFNB). Genes inherited in X-linked manner are designated DFN (number following these designations reflects the order of gene mapping

and/or discovery). X-linked deafness type 3 (DFN3) is the X-recessive mixed deafness syndrome with congenital fixation of the stapedial footplate and perilymphatic gusher.<sup>[13]</sup> In 1998 two papers discussed the gene responsible for this DFN3. Hagiwara et al. (1998) described the molecular defect in patients with X-linked mixed deafness (DFN3) showing a perilymphatic gusher at stapedectomy to be Frame shift deletions and missense mutations in POU3F4 gene<sup>[13]</sup>, While Wallis et al. (1998) localized X-linked mixed deafness to Xq 13-q21.1 region with no further work done on genetic basis for this syndrome, this may be due to the small number of cases.<sup>[14]</sup>

Some authors reported that the CT scan findings (Table 2) <sup>[12]</sup> and clinical findings are considered typical, and a family history does not need to be present to suggest the diagnosis of X-linked congenital

hearing loss. [6, 10] Glasscock (1973) presented his clinical investigation based on two families with manifest and X-linked mixed deafness, with congenital fixation of the stapes footplate and perilymphatic gusher. [15] In his report, Glasscock described three case reports in detail in which the excessive flow of CSF that started at stapedectomy could be stopped by packing temporalis muscle into the IAC. When the muscle was removed, the excessive flow of CSF resumed. Glasscock was the first to describe abnormality of the ears in this condition shown by polytome X-ray. He described an abnormally dilated IAC at its most lateral extent and abnormally large vestibule. [15] Cremers and coworkers (1985) studied 8 affected males in a large Dutch family. [4] They described dilatation of lateral part of the IAC and widening of the first part of the facial canal. In a study of X-linked mixed deafness, Phelps and coworkers (1991) found a distinctive inner ear deformity in some of the deaf males, characterized not only by a wide bulbous IAC but also, most importantly, by a deficient or absent bony lamina between the lateral end of the IAC and the basal turn of the cochlea. [6] It was their belief that this resulted in a communication between the subarachnoid space in the IAC and the perilymph in the cochlea, leading to perilymphatic hydrops and a "gusher" if the stapes was disturbed. In a report of computerized tomography (CT) diagnosis of X-linked congenital mixed deafness associated with fixation of the footplate and perilymph gushers, Talbot and Wilson (1994) underscore the fact that most cases of perilymph gushers are not associated with an abnormally patent cochlear aqueduct. [10] They reported CT findings of an enlarged IAC, hypoplasia of the cochlear base, absent bony modiolus, abnormal vestibular aqueduct, and enlarged labyrinthine facial nerve canal. Three patients were scanned following stapes surgery that resulted in a gusher. A fourth stapedectomy was avoided by preoperative CT recognition of the dysplasia. In our study, five patients had normal CT scan and one had a wide cochlear aqueduct, and this coincides with Jackler and Hwang (1993) results who stated that it is extremely improbable that a stapes gusher, transotic CSF leak, and a vigorous perilymphatic fistula are generated by the cochlear aqueduct when CT shows

any portion of it to be very narrow. [11] We concluded that the CT scan features are not mandatory found in all patients. Rarity of the condition and the small number of patients studied in previous studies do not give us a solid base to adhere to specific CT scan features to diagnose this syndrome.

In four patients reported by Talbot and Wilson (1994), a family history was not present. [10] Of 24 cases described by Phelps et al. (1991), 16 had a family history. [6] In our study, five patients had a familial history of mixed hearing loss affecting male brothers and the last patient in our study was a female patient with a familial history of mixed hearing loss in two sisters. So, the presence of mixed hearing loss and familial history were the main features of diagnosing X-linked hearing loss in our study. So, we can conclude from our work and other authors' experience that stapes gusher should be suspected preoperatively if there is an X-linked family history of hearing loss in individuals who show a mixed type of hearing loss.

All the authors agreed that this disease shows an X-recessive type of inheritance, since the male patients had severe mixed hearing loss at all frequencies, while the obligate female carriers were normal or had mild hearing impairment. [16] In their study Phelps et al. (1991) showed that some of the obligate female carriers seem to have a milder form of the same anomaly associated with slight hearing loss. They found no CT abnormalities in eight and bulbous IACs in three obligate female carriers. [6] Papadaki et al. (1998) presented a case report of two females presented with severe mixed hearing loss and stapes gusher during stapedectomy. [16] High resolution CT of the temporal bones showed characteristic abnormalities of the inner ear described in X-linked progressive mixed deafness with stapes gusher (bulbous dilatation of the lateral portion of the IAC with incomplete separation from the cochlea, and widening of the first part of the facial nerve canal). Evaluation of the patient's family revealed a sister with the same clinical history and identical high resolution CT scan findings, and 11 normal male relatives. This is the first report with typical findings of this entity that affects only female members of a family, suggesting another type of inheritance. They were not able to fully illuminate genetic basis of the

disease in their cases. <sup>[16]</sup> One female developed stapes gusher during stapedectomy in our study and she has two sisters who showed mixed hearing loss which is in line with the work of Phelps et al. <sup>[6]</sup> and Papadaki et al. <sup>[16]</sup>. Possible explanations include an autosomal recessive version of that entity and a low goniodial penetration or a non-random inactivation of the normal gene favoring the mutated X gene in these patients. The clinical and radiological appearance of X-linked progressive mixed hearing loss with perilymphatic gusher during stapes surgery can occur not only in males but in females as well. One should be aware of it prior to surgery, and a CT scan evaluation should be performed even in females presenting the clinical features of the disease and a suspicious family history. <sup>[16]</sup>

If perilymph gusher occurred during stapedectomy, regardless of the procedure; functional results are often variable. The surgeon either continues the procedure (places the prosthesis and seals the around with fat) or controls the catastrophic flow of perilymph and terminates the operative procedure. <sup>[1]</sup> The surgeon should make a tiny control hole by either a pick or laser and if a perilymph gusher is encountered, the leak should be plugged with a tissue seal, such as vein, and held in place by packing the middle ear space. <sup>[1]</sup> In some cases, packing of the vestibule with muscle or other tissue may be required. If the flow of CSF persists, an epidural cannula can be placed into the lumbar subarachnoid space, draining away excessive spinal fluid, as first described by Shea. <sup>[17]</sup> The patient should be maintained in a recumbent position. In rare cases, packing of the IAC may be necessary. <sup>[15]</sup> In this study, we were able to continue the procedure and place the prosthesis and sealed the around with fat. In spite of the difficult procedure, it gave good results as three patients showed marked improvement and one patient showed mild improvement and only two patients ended up with sensorineural hearing loss and needed hearing aids.

## **Conclusion**

We can conclude from our work and other authors' experience that stapes gusher should be suspected preoperatively if there is an X-linked family history of hearing loss in individuals who show a mixed type of hearing loss. In all of these cases, a high resolution, thin section CT should be performed, looking for

abnormalities of the internal auditory canal (IAC), cochlear aqueduct and the labyrinthine structures.

## **References**

1. John R. Emmett. Cerebrospinal fluid gusher during stapedectomy. *Operative Techniques in Otolaryngology - Head and Neck Surgery*, 2003; 14 (4): 300-302.
2. Shea JJ. Complications of the stapedectomy operation. *Ann Otol Rhinol Laryngol* 1963; 72:1109-1123.
3. Raphael R, Ciuman, MD. Communication routes between intracranial spaces and inner ear: function, pathophysiologic importance and relations with inner ear diseases. *American Journal of Otolaryngology-Head and Neck Medicine and Surgery* 2008; article in press.
4. Cremers CW, Hombergen GC, Scaf JJ, et al. X-linked progressive mixed deafness with perilymphatic gusher during stapes surgery. *Arch Otolaryngol Head Neck Surg* 1985; 111:249-254.
5. Cremers CWRI, Hombergen GCJH and Wentges RTR. Perilymphatic gusher and stapes surgery. A predictable complication? *Clin Otolaryngol* 1983; 8:235-40.
6. Phelps RD, Reardon W, Bellman S, et al. X-linked deafness, stapes gushers and a distinctive defect of the inner ear. *Neuroradiology* 1991; 33:326-330.
7. Tang A, Parnes LS. X-linked progressive mixed hearing loss. Computed Tomography findings. *Ann Otol Rhinol Laryngol* 1994; 103:655-7.
8. Ernst A, Snik FM, Mylanus IA, Cremers WR. Noninvasive assessment of the intralabyrinthine pressure. A new technique applied to patients with X-linked progressive mixed deafness syndrome with perilymphatic gusher during stapes surgery. *Arch Otolaryngol Head Neck Surg* 1995; 121:926-9.
9. Nance WE, Settleff R, McLead A, Sweeney D, Cooper C and McConnell F. X-linked mixed deafness with congenital fixation of the stapedial footplate and perilymphatic gusher. *Birth Defects* 1971; 7:64-9.
10. Talbot JM, Wilson DF. Computed tomographic diagnosis of X-linked congenital mixed deafness, fixation of the stapedial footplate, and perilymphatic gusher. *Am J Otol* 1994; 15(2):177-182.

11. Jackler RK, Hwang PH. Enlargement of the cochlear aqueduct: Fact or fiction. *Otolaryngol Head Neck Surg* 1993; 109:14-25.
12. Kumar G., Castillo M. and Buchman CA. X-Linked Stapes Gusher: CT Findings in One Patient *American Journal of Neuroradiology* 2003; 24:1130-1132.
13. Hagiwara H, Tamagawa Y, Kitamura K, Kodera K. A new mutation in the POU3F4 Gene in a Japanese family with X-linked mixed deafness (DFN3). *Laryngoscope* 1998; 108:1544-1547.

14. Wallis C, Ballo R, Wallis G. X-linked mixed deafness with stapes fixation in a Mauritian kindred: linkage to Xq probe pDP34. *Genomics* 1998; 3:299-301.
15. Glasscock ME. The stapes gusher. *Arch Otolaryngol Head Neck Surg*. 1973; 98:82-91.
16. Papadaki E, Prassopoulos P, Bizakis J, et al. X-linked deafness with stapes gusher in females. *Eur J Radiol* 1998; 29 :71-75.
17. Shea JJ. Symposium: Congenital anomalies of the middle ear: IV. Management of profuse perilymph leak. *Laryngoscope* 1976; 86:255-256.

**Causse Ear Clinic**  
Béziers (France)

**12<sup>th</sup> International Otology Course**  
July 1 - 3

Otosclerosis  
Cholesteatoma  
Ossicular reconstruction  
Implantable hearing aids  
Neurotology

Live Surgery  
Lectures  
Panel Discussion

**Special Guest Speakers:**  
Emilio Garcia-Ibanez (Spain)  
Thomas Lenarz (Germany)  
Jacques Magnan (France)  
John Niparko (USA)  
Jacob Sadé (Israel)

Official language: English  
Simultaneous translation: English to French

EA NO  
A O  
E O  
L O  
UNIVERSITÄT MEDISCH ZENTRUM  
SURF NET