

## ORIGINAL ARTICLE

# Alpha-Tricalcium Phosphate Bone Cement in the Surgical Treatment of Open Mastoid Cavity

Robinson Koji Tsuji, Vanda Jorgetti, Ricardo Ferreira Bento, Rubens de Brito Neto

Clinical Hospital of the Medical University of São Paulo, São Paulo – SP, Brazil, (RT, VJ, RBN)  
Otorhinolaryngology Department Medicine School University of São Paulo, (RB)

**Hypothesis:** This study aimed to evaluate the biocompatibility of alpha-tricalcium phosphate bone cement in the obliteration of the mastoid cavity in guinea pigs.

**Background:** Treatment with open cavity mastoidectomy can present poor functional results in chronic otitis media with cholesteatoma, especially if the cavity is large. Partial or total obliteration of the cavity can overcome these problems. Alpha-tricalcium phosphate bone cement has physicochemical characteristics that suggest its potential in mastoid cavity obliteration.

**Materials and Methods:** Twenty guinea pigs were studied. All animals underwent surgery involving the dorsal tympanic bulla. In the study group animals (n = 10), mastoid cavity obliteration was performed with alpha-tricalcium phosphate bone cement. In the control group animals (n = 10), the cavity was left unfilled.

On postoperative day 60, the animals were sacrificed and studied for signs of rejection of the material and other complications. Temporal bones were removed for histopathological study, in which the type and degree of inflammatory response, as well as the degree of ossification, were analyzed.

**Results:** The mortality rate was the same in both groups. Deaths were attributed to anesthetic complications in the initial postoperative period. In the animals that survived, there were no complications, and there was good healing of the incision in both groups. There were no clinical signs of rejection of the material, and the histopathological analysis of the cement group revealed no signs of foreign body reaction (inflammatory response).

**Conclusion:** Alpha-tricalcium phosphate bone cement is biocompatible in the mastoid cavity of guinea pigs.

Submitted : 28 May 2010

Accepted : 15 September 2010

## Introduction

Many authors consider open cavity mastoidectomy the surgical procedure of choice for the treatment of otitis media with cholesteatoma, due to the high incidence of recurrence of the disease<sup>[1-3]</sup>. This technique allows full removal of the cholesteatoma, as well as better postoperative control, since it allows the removal of recurrent disease<sup>[4]</sup>. However, the formation of this single cavity can generate problems such as deafness, persistent otorrhea, dizziness, poor aesthetics and the need for periodic cleaning of the cavity by an otorhinolaryngologist. Therefore, in selected cases, the elimination of the open cavity is indicated in order to improve the quality of life of the patient. The techniques for the elimination of the open cavity consist of the reconstruction of the posterior wall of the external auditory meatus (EAM), cavity obliteration or complete ablation of the middle ear<sup>[5]</sup>.

Since 1962 with the experiments conducted in 1962 by Mahoney et al.<sup>[6]</sup>, who used methyl methacrylate, various synthetic materials have been tested. Synthetic materials have the advantage of being easily obtained, as well as not submitting the patient to the risk of infectious diseases. However, such materials can present problems of biocompatibility and, consequently, rejection.

A new material similar to hydroxyapatite has been extensively studied for use in the reconstruction of bone defects in orthopedic surgery, neurosurgery, oral surgery and maxillofacial surgery<sup>[7-9]</sup>. This new material is alpha-tricalcium phosphate cement, which is an apatite carbonate formed by mixing alpha-tricalcium phosphate with calcium carbonate and monocalcium phosphate powder. Mixing these components with a sodium phosphate solution forms a crystalline structure known as dahllite, which is similar to the bone mineral phase.

### Corresponding address:

Robinson Koji Tsuji, MD  
Alameda Ibérica, 285 house 312  
Zipcode: 06543-502  
E-mail: rkttsuji@uol.com.br

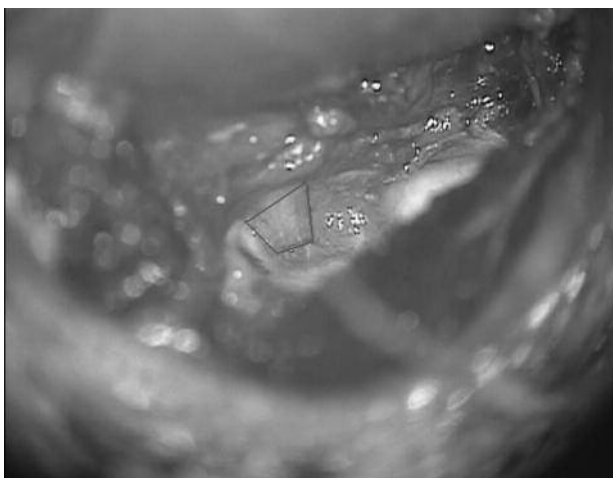Copyright 2005 © The Mediterranean Society of Otolaryngology and Audiology

Although it has been used for more than 10 years, there are no studies in the literature on its application in mastoid cavity obliteration. The objective of this study was to evaluate the biocompatibility of alpha-tricalcium phosphate bone cement in an animal model of mastoid cavity obliteration.

### **Materials and Methods**

The study design was approved by the Ethics Committee for the Analysis of Research Projects of the Clinical Board of the University of São Paulo School of Medicine Hospital das Clínicas. The experimental study was conducted in accordance with the manual for the care and handling of laboratory animals. A total of 20 young, healthy adult female guinea pigs (*Cavia porcellus*), aged 10-12 months and weighing between 350-450 g, were studied. Animals with signs of external or middle ear infection were excluded, as were pregnant animals and those with congenital malformations.

*C. porcellus* has a cellular aeration of the temporal bone composed of the ventral and dorsal tympanic bullae and retrotympanic cells. Making an analogy with the human temporal bone, the dorsal tympanic bulla would be the equivalent of the epitympanic recess, also known as the attic. The dorsal tympanic bulla is located in the superior posterior portion of the tympanic cavity, superior to the intracranial cavity, medial to the petrous portion of the temporal bone, inferior to the tympanic cavity and inferior to the EAM. The communication between the dorsal tympanic bulla and the tympanic cavity is through a hiatus located in the inferior portion, into which the incudomalleolar joint projects<sup>[10,11]</sup>. When the upper wall of the EAM is removed, the tympanic bulla communicates with the EAM, forming a single cavity similar to the open mastoid cavity.



**Figure 1.** Open tympanic bulla and removal of the wall of the external auditory meatus (Green trapezium).

The 20 animals were divided into 2 groups of 10 animals each. Animals in both groups were submitted to the same sterile surgical procedure and remained under observation for a period of 60 days. The animals were sacrificed after 60 days, and the temporal bones were removed for histopathological study.

### *Surgical Technique*

The guinea pigs were anesthetized with a mixture of ketamine (40 mg/kg) and xylazine (8 mg/kg). This anesthetic regimen allows a good level of anesthesia for a period of 60 to 90 min without respiratory depression. During the induction of anesthesia, all animals received 50 mg/kg of the antibiotic cefazolin.

Following local infiltration with lidocaine, at 2% with adrenaline 1:200,000, we made an incision over the auricular pavilion, exposing the temporal muscle. By making a posteriorly based pedicle musculoperiosteal flap, we exposed the membranous part of the squama of the temporal bone. With the use of cutting and diamond drill bits, under constant irrigation, the cortex of the dorsal tympanic bulla was removed, allowing complete exposure of the interior of the cavity. Subsequently, we removed the posterior bone wall of the EAM, which delineates the lower limit of the dorsal tympanic bulla (Figure 1). The cavity was then cautiously cleaned, and the cavity walls were scarified using a diamond drill bit.

The musculoperiosteal flap was rotated to the interior of the tympanic bulla, covering the bone defect of the posterior wall of the EAM. The cavities of the 10 control group animals remained unfilled, whereas those of the 10 study group animals were obliterated with alpha-tricalcium phosphate bone cement (Figure 2).



**Figure 2.** Mastoid cavity filled with bone cement.

The cement used comes in two containers: a jar containing sterile calcium phosphate powder and a flask containing sterile diluted sodium phosphate. The proportion between powder and the solvent need not be calculated: it is only necessary to mix the total contents of both vials. The mixture should be applied and molded within 3 min, at which point the hardening process begins, and the product becomes completely hardened within 10 min.

The incision was closed using subcutaneous polyglactin 910 sutures and cutaneous nylon sutures.

#### *Preparation of the histopathological material*

On postoperative day 60, the animals were sacrificed. The animals were initially anesthetized with ketamine (160 mg/kg) and xylazine (16 mg/kg), after which a lethal dose of 19.1% KCl was given via intracardiac injection.

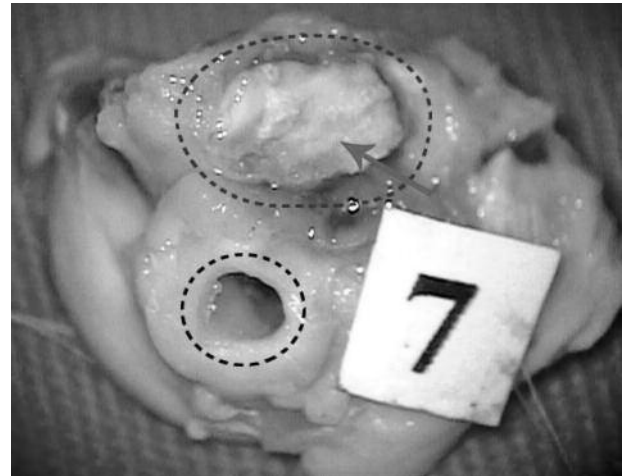Temporal bones were removed using a scope, a hammer and scissors. Each piece was carefully removed, preserving the tympanic bulla and maintaining the cement intact (Figure 3).

The material was then fixed with 70% alcohol and embedded in methyl methacrylate blocks. The blocks were then cut into 1-mm thick sections using a diamond-blade low rotation disc saw (Isomet-Buehler, Lake Bluff, IL, USA). Subsequently, the sections were polished down to a thickness of 10 µm using a metallographic polishing machine. The cuts were then stained with 0.1% toluidine blue and sent for histopathological analysis.

#### *Data analysis*

Histopathological analysis was carried out under optical microscopy by an experienced pathologist in the Department of Pathology of the University of São Paulo School of Medicine Hospital das Clínicas. The slides were initially examined in panoramic view for the identification of all fields and then at magnifications of  $\times 12.5$ ,  $\times 40$ ,  $\times 50$ ,  $\times 200$  and  $\times 400$ .

Clinical analysis was carried out prior to the removal of the temporal bone. The skin and muscle flap were



**Figure 3.** Guinea pig temporal bone removed. Note the mastoid cavity (blue circle) filled with bone cement (red arrow), and the external auditory meatus (black circle).

evaluated macroscopically, and the otoscopy was carried out using a surgical microscope.

The guinea pigs were studied for signs of rejection of the material, as well as to determine the degree of ossification and the incidence of complications.

#### *Biocompatibility analysis*

For the biocompatibility analysis of the alpha-tricalcium phosphate bone cement, the following parameters were evaluated:

- Inflammatory response.
- Incidence of complications of the procedure.
- Osteoneogenesis.

#### *Analysis of the inflammatory response*

As a histopathological parameter for the evaluation of the biocompatibility of the material, the granulomatous inflammatory response and giant cell formation was studied. For the analysis of the inflammatory response and foreign body reaction, a classification system consisting of five categories was created (Table 1).

According to the inflammatory response score given by the pathologist in the histological analysis, we divided the animals into three groups by type (Table 2).

**Table 1.** Classification of inflammatory responses

|     |   |
|-----|---|
| I   | Absence of signs of inflammatory response   |
| II  | Presence of minimum edema without granuloma formation   |
| III | Presence of granulomatous reaction with giant cells   |
| IV  | Presence of granulomatous reaction with giant cells and lymphocytic infiltrate in adjacent soft tissues                     |
| V   | Presence of inflammatory response with lymphohistiocytic inflammatory infiltrate with neutrophils and cicatricial fibrosis. |

### Analysis of the degree of ossification

For the analysis of the degree of ossification of the mastoid cavity, a previously five-point scale was used (Table 3)<sup>[13]</sup>. Using this classification system, the pathologist classified the degree of ossification in the control group and cement group samples. The presence of cartilage or chondrocytes, active osteoblasts, osteoid tissue, newly formed bone trabeculae and marrow, were the criteria listed for evidence of process of bone formation.

### Analysis of the incidence of complications of the procedure

For the analysis of the incidence of complications, the guinea pigs were evaluated in terms of the following parameters:

- Death of the animal
- Middle-ear effusion
- Signs of skin or muscle infection
- Signs of skin or muscle necrosis
- Signs of extrusion of the material
- Stenosis of the EAM
- Cutaneous fistula

## Results

The mean initial weight of the control group animals was 396.8 g, and the mean final weight was 570 g. Therefore, the mean weight gain in the control group during the study period was 173.2 g, an increase of 43.6% over the initial weight.

In the cement group, the mean initial weight of the animals was 398.8 g, and the mean final weight was

574.3 g. Therefore, the mean weight gain in the cement group during the study period was 175.5 g, a 44% increase in relation to the initial weight.

In each group, there were 2 deaths (a 20% incidence), all occurring on postoperative day 1 ( $p = 1.0$ ). The deaths were attributed to anesthetic complications, since they occurred in the immediate postoperative period, and since the same number of deaths occurred in both groups. The clinical analysis of the remaining animals revealed no signs of other complications: skin or muscle infection; middle ear effusion; EAM stenosis; cutaneous fistula; or secondary cholesteatoma formation. The clinical analysis of the guinea pigs showed no signs of granulomatous inflammatory response in any of the cement group animals. Nor were there any cases of extrusion of the material.

After the removal of the temporal bones, we observed that the material was firmly adhered to the mastoid cavity in all cement group samples.

The histological analysis of the degree and type of inflammatory response is shown in Table 4. There were no signs of foreign body reaction in the cement group, 8 (100%) of the samples presenting category I or II inflammatory responses. Only 3 (37.5%) of the control group animals presented a category III inflammatory response, whereas the remaining guinea pigs (100% of the cement group and 62% of the control group) presented a category II inflammatory response. Despite the difference among the prevalence of the types of inflammatory responses between the groups, this difference was not statistically significant ( $p = 0.2$ ).

**Table 2.** Subdivision of inflammatory responses into three types

| Type | Categories | Criteria   |
|------|------------|--|
| 1    | I and II   | Cicatricial alterations expected after surgery                             |
| 2    | III and IV | Inflammation alterations to the extrinsic material (foreign body reaction) |
| 3    | V          | Acute inflammation (possible infection)                                    |

**Table 3.** Histologic degree of ossification

| Degree | New bone formation                                | Score |
|--------|---|-------|
| 0      | No new bone                                       | 0     |
| I      | 1%-25% of cavity involved in new bone formation   | 1     |
| II     | 26%-50% of cavity involved in new bone formation  | 2     |
| III    | 51%-75% of cavity involved in new bone formation  | 3     |
| IV     | 75%-100% of cavity involved in new bone formation | 4     |



As for the study of the degree of ossification, 4 (50%) of the control group samples presented category III ossification of the samples and the remaining 4 control group samples (50%) presented category IV ossification. In the cement group, we observed category II in 8 (100%) samples (Table 5).

When attributing the scores of each animal according to the degree of ossification, we observed that the mean ossification in the control group (3.5) was greater than that shown by the cement group (1.0). The control group showed statistically significant ( $p < 0.001$ ) higher degrees of ossification (mean  $3.5 \pm 0.5$ ) when compared to the cement group ( $1.0 \pm 0.0$ ).

### Discussion

Several types of material have been used for open mastoid cavity obliteration. The materials most often employed are autologous tissues, such as cartilage, bone, fat, muscle and bone pate, which have the advantage of not being rejected and can be obtained during surgery<sup>[5,12,13]</sup>. The disadvantage is the difficulty in obtaining a quantity of material sufficient to perform the procedure.

Therefore, since the experiments conducted in 1962 by Mahoney et al.<sup>[6]</sup>, who used methyl methacrylate,

several synthetic materials have been tested. Synthetic materials have the advantage of being easily obtained, as well as not submitting the patient to the risk of transmission of infectious diseases. However, they present problems regarding biocompatibility, presenting high rates of rejection.

Silicone, proplast, ionomer cement and bioactive glass cement are among the synthetic materials studied for this objective<sup>[14-17]</sup>.

Silicone, proplast and ionomer cement are no longer used due to the incidence of complications. Silicone and proplast presented high degree of granulomatous inflammatory reaction in temporal bone and ionomeric cement was related cases of aluminium encephalopathy. In addition, bioactive glass cement is still in the experimental study phase<sup>[18]</sup>.

More recently, synthetic materials made of calcium and phosphate have been used. These present a biochemical structure similar to the mineral phase of human bone. Alloplastic calcium and phosphate implants are composed of calcium and phosphate in apatite form. Apatite is a compound in the form of crystals that has a chemical structure represented by the formula  $\text{Ca}_5(\text{X})(\text{PO}_4)_3$ . In this structure, the

**Table 4.** Results of the histological analysis of the control group and cement group.

|                                | Group             |                    |      |                   |
|--------------------------------|-------------------|--------------------|------|-------------------|
|                                | Cement<br>(n = 8) | Control<br>(n = 8) | p    | Total<br>(n = 16) |
| Inflammatory response category |                   |                    |      |                   |
| I                              | 7 (87.5%)         | 3 (37.5%)          | 0.09 | 10 (62.5%)        |
| II                             | 1 (12.5%)         | 2 (25.0%)          |      | 3 (18.8%)         |
| III                            | 0 (0.0%)          | 0 (0.0%)           |      | 0 (0.0%)          |
| IV                             | 0 (0.0%)          | 0 (0.0%)           |      | 0 (0.0%)          |
| V                              | 0 (0.0%)          | 3 (37.5%)          |      | 3 (18.8%)         |
| Inflammatory response type     |                   |                    |      |                   |
| 1                              | 8 (100.0%)        | 5 (62.5%)          | 0.2  | 13 (81.3%)        |
| 2                              | 0 (0.0%)          | 0 (0.0%)           |      | 0 (0.0%)          |
| 3                              | 0 (0.0%)          | 3 (37.5%)          |      | 3 (18.8%)         |

**Table 5.** Degree of ossification in the control group and cement group

|                        | Group             |                    |       |                   |
|------------------------|-------------------|--------------------|-------|-------------------|
|                        | Cement<br>(n = 8) | Control<br>(n = 8) | p     | Total<br>(n = 16) |
| Degree of ossification |                   |                    |       |                   |
| 0                      | 0 (0.0%)          | 0 (0.0%)           | 0.001 | 0 (0.0%)          |
| I                      | 8 (100.0%)        | 0 (0.0%)           |       | 8 (50.0%)         |
| II                     | 0 (0.0%)          | 0 (0.0%)           |       | 0 (0.0%)          |
| III                    | 0 (0.0%)          | 4 (50.0%)          |       | 4 (25.0%)         |
| IV                     | 0 (0.0%)          | 4 (50.0%)          |       | 4 (25.0%)         |

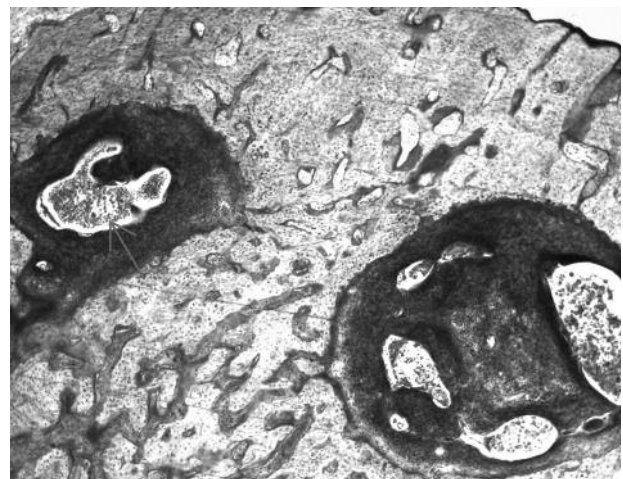
position X can be occupied by ions of fluorine, chlorine, hydroxide or carbonate<sup>[19]</sup>. Among these, the first material studied was hydroxyapatite, which has presented good results when used in EAM reconstruction or mastoid cavity obliteration<sup>[20-22]</sup>. From the study of hydroxyapatite, new types of material were developed.

Alpha-tricalcium phosphate cement is a product made of three solutes: alpha-tricalcium phosphate, calcium carbonate and monocalcium phosphate<sup>[23]</sup>. When these components are mixed with a sodium phosphate solution, they form a crystalline structure of apatite carbonate known as dahllite, which is similar to the mineral phase of the bone<sup>[24,25]</sup>.

The time involved in preparing the material, which consists of mixing the solid phase with the sodium phosphate solution, is approximately 2 min. The material manipulation time is 5 min. After the placement of the material, the dahllite is formed, and hardening occurs. Hardening time is 10 min at normal body temperature<sup>[24,26,27]</sup>. After 12 h, between 85 to 90% of the material has turned to dahllite, and its maximum compression force is 55 megapascals<sup>[24]</sup>. Constantz et al. studied the biochemical composition and the crystalline structure of the dahllite formed in this reaction and found that they were similar to those of the dahllite naturally present in the bone. This material has been widely used in the filling of bone defects in orthopedic surgery, neurosurgery, oral surgery and maxillofacial surgery. Studies involving surgical reconstruction of the ossicular chain in guinea pigs with alpha-tricalcium phosphate cement showed good results, with low levels of inflammation and minimal foreign body reaction<sup>[28,29]</sup>.

For the biocompatibility study, samples were studied using clinical and histopathological parameters. The system of classifying inflammatory response into five categories was adapted from that described by Hoffman et al., who studied the degree of inflammatory response in guinea pigs submitted to surgical reconstruction of the ossicular chain with the use of the alpha-tricalcium phosphate cement<sup>[28]</sup>. The classification system used by Hoffmann et al. was divided into 4 categories. Since this classification was inappropriate for use with animals presenting an acute inflammatory response, we added a fifth category (category V). We used these five categories to subdivide the animals into three groups by type, designated types 1, 2 and 3. Type 1 corresponds

histopathologically to an inflammatory response that normally occurs in tissues submitted to surgical trauma and encompasses categories I and II. Type 2 corresponds histopathologically to a foreign body reaction and encompasses categories III and IV. Type 3 corresponds histopathologically to an acute inflammatory response (Figure 4) with a possible infection and encompasses category V.



**Figure 4.** Temporal bone of a guinea pig in the control group. Inflammatory lymphohistiocytic infiltrate with fibrosis and polymorphonuclear cells (red arrow). Example of type 3 inflammatory response. Material stained with toluidine blue (magnification, 40).

In our study, we observed no clinical signs of rejection of the material, such as a granulomatous inflammatory response or implant extrusion. In the histopathological analysis, no samples treated with alpha-tricalcium phosphate cement showed signs of foreign body reaction, which normally occurs during the process of rejection of the material.

The present study also demonstrated that the use of alpha-tricalcium phosphate cement provoked no complications when used for obliteration of the guinea pig mastoid cavity. The absence of effusion in the middle ear is a sign that there was preservation of the middle ear physiology.

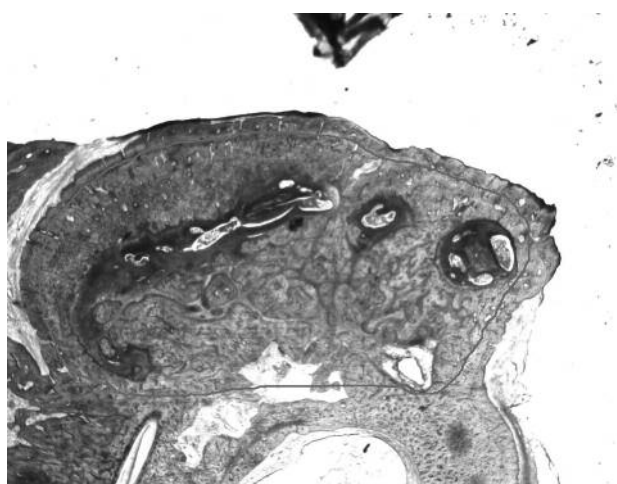
As for the degree of ossification, we found significantly less ossification in the cement group than in the control group (Figure 5). This fact confirms the findings of studies demonstrating that this material is not osteoconductive. Alpha-tricalcium phosphate

cement is microporous, which allows no internal bone growth<sup>[24]</sup>. However, there were signs of reabsorption and bone growth in the periphery of the implant (Figure 6), showing that, over longer periods of time, the material can be reabsorbed and replaced by new bone. Studies in animals have shown that alpha-tricalcium phosphate bone cement undergoes remodeling similar to that occurring in normal bone. This material suffers osteoclastic reabsorption followed by osteoblastic migration and formation of a new bone<sup>[24]</sup>. The drying properties, even in humid environments, and adherence to the bone may be advantages in relation to hydroxyapatite. The mastoid cavity is humid and often contains blood. Furthermore, the fact that the material adheres to the adjacent bone is a factor that might result in greater stability in the surgical bed. In all other samples studied, the cement was firmly adhered to the interior of the tympanic bulla.

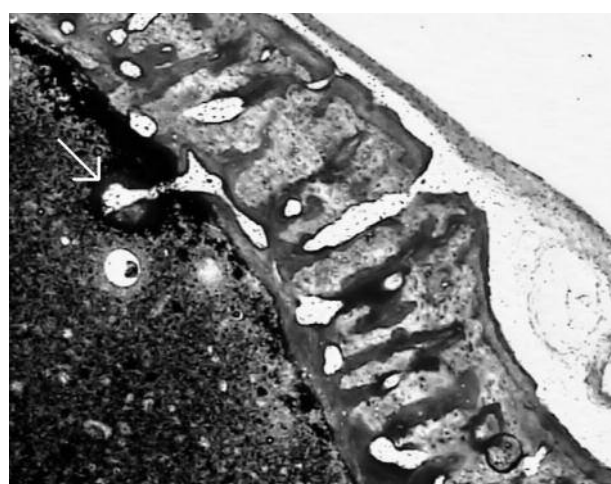
Based on our findings, we can state that alpha-tricalcium phosphate bone cement is biocompatible in the mastoid cavity of guinea pigs.

#### References

1. Bento RF, Miniti A, Marone SAM. *Tratado de Otolgia*. 1ª ed., São Paulo: EDUS; 1998.
2. Karmarkar S, Bhatia S, Saleh E, et al. Cholesteatoma surgery: the individualized technique. *Ann Otol Rhinol Laryngol*. 1995; 104: 591-5.
3. Chang C, Chen M. Canal-wall-down tympanoplasty with mastoidectomy for advances cholesteatoma. *J Otolaryngol*. 2000; 29: 270-3.
4. Roden D, Honrubia V, Wiet R. Outcome of residual cholesteatoma and hearing in mastoid surgery. *J Otolaryngol*. 1996; 25: 178-81
5. Black B. Mastoidectomy elimination. *Laryngoscope*. 1995; 105(12 Pt 2):1-30.
6. Mahoney JL. Tympanoacryloplasty. *Arch Otolaryngol Head Neck Surg*. 1962; 75:519-22.
7. Mahr MA, Bartley GB, Bite U, Clay RP, Kasperbauer JL, Holmes JM. Norian Craniofacial Repair System Bone Cement for the Repair of Craniofacial Skeletal Defects. *Ophthalmic Plastic & Reconstructive Surgery*. 2000 september; 16(5):393-8.
8. Baker S, Weinzeig, J, Kirschner RE, Bartlett SP. Applications of a New Carbonated Calcium Phosphate Bone Cement: Early Experience in Pediatric and Adult Craniofacial Reconstruction. *Plastic & Reconstructive Surgery*. 2002 may; 109:1789-96.
9. Kirschner RE, Karmacharya J, Ong GBS, Gordon AD, Hunenko OBA, Losee J, Gannon FH, Bartlett SP. Repair of the Immature Craniofacial Skeleton With a Calcium Phosphate Cement: Quantitative Assessment of Craniofacial Growth. *Annals of Plastic Surgery*. 2002; 49:33-8.



**Figure 5.** Temporal bone of guinea pig in the control group. Intense mastoid cavity ossification. The red circle represents the original size of the cavity. Material stained with toluidine blue (magnification, 12.5)



**Figure 6.** Temporal bone of guinea pig in the cement group. The dahlite bone cement (amorphous black material) is being invaded by ossification lamellae (white arrow) in its periphery. Material stained with toluidine blue (magnification, 40).

10. Goksu N, Hazirolu R, Kemalolu Y, Karademir N, Bayramolu I, Akyildiz N. Anatomy of the guinea pig temporal bone. *Ann Otol Rhinol Laryngol.* 1992 Aug;101:699-704.
11. Wysocki J. Topographical anatomy of the guinea pig temporal bone. *Hear Res.* 2005;199:103-10.
12. Linthicum FH Jr. The fate of mastoid obliteration tissue: a histopathological study. *Laryngoscope.* 2002; 112:1777-81.
13. Leatherman BD, Dornhoffer JL, Fan CY, Mukunyadzi P. Demineralized bone matrix as an alternative for mastoid obliteration and posterior canal wall reconstruction: results in an animal model. *Otol Neurotol.* 2001; 22(6):731-6.
14. Rosenblut B, Ahlvin RC, Carr CD, et al. Silicone implants in the mastoid portion of the temporal bone. *Ann Rhinol Laryngol.* 1966; 75: 889-9.
15. Shea JJ, Malenbaun BT, Moretz WH. Reconstruction of the posterior wall with proplast. *Otolaryngol Head Neck Surg.* 1984; 92:329-33.
16. Helms J, Geyer G. Closure of the petrous apex of the temporal bone with ionomeric cement following translabyrinthine removal of an acoustic neuroma. *J Laryngol Otol.* 1994; 108: 202-5.
17. Bryan DL, Dornhoffer JL. Bioactive Glass Ceramic Particles as an alternative for mastoid obliteration: results in an animal model. *Otol & Neurotol.* 2002; 23:657-60.
18. Jang CH, Cho YB, Bae CS. Evaluation of bioactive glass for mastoid obliteration: a guinea pig model. *In Vivo.* 2007; 21:651-5.
19. Costantino PD, Hiltzik D, Govindaraj S, Moche J. Bone healing and bone substitutes. *Facial Plast Surg.* 2002; 18:13-26.
20. Yung MW. The use of hydroxyapatite granules in mastoid obliteration. *Clin Otolaryngol.* 1996; 21: 408-84.
21. Jahn AF. Experimental applications of porous (coralline) hydroxyapatite in middle and mastoid obliteration. *Laryngoscope.* 1992; 102: 289-99.
22. Hussain A, Ram B, Hilmi OJ. Reconstruction of Mastoid Cavity With Hydroxyapatite Cement and Postauricular Flap. *Laryngoscope.* 2002; 112:583-5.
23. Frankenburg EP, Goldstein SA, Bauer TW, et al. Biomechanical and histological evaluation of a calcium phosphate cement. *J Bone Joint Surg Am.* 1998; 80:1112-4.
24. Constantz BR, Ison IC, Fulmer MT, et al. Skeletal repair by in situ formation of the mineral phase of bone. *Science* 1995; 267:1796-9.
25. Ison I, Fulmer B, Barr B, et al. Synthesis of Dahllite. The Mineral Phase of Bone. Boca Raton, FL: CRC Press Lewis Publishers, 1994.
26. Kopylov P, Jonsson K, Thorngren KG, et al. Injectable calcium phosphate in the treatment of distal radius fractures. *J Hand Surg. [Br]* 1996; 21:768-71
27. Kopylov P, Runnqvist K, Jonsson K, et al. Norian SRS versus external fixation in redisplaced distal radial fractures. A randomized study in 40 patients. *Acta Orthop Scand.* 1999; 70:1-5.
28. Hoffmann KC, Kuhn JJ, Strasnick. N. Bone Cements as Adjuvant Techniques for Ossicular Chain Reconstruction. *Otol & Neurotol.* 2003; 24: 24-8.
29. McDowell MP, Kuhn JJ, Strasnick B. Incudostapedial Joint Reconstruction Using Dahllite Bone Cement in a Chinchilla Model. *Otolaryngol Head Neck Surg.* 133 Supplement 1:83-4.