

ORIGINAL ARTICLE

Could Bone Cement Cause Ototoxicity?

Orhan Kemal Kahveci, Ahmet Cangal, Murat Cem Miman, Erdogan Okur, Ali Altuntas

Afyon Kocatepe University, Faculty of Medicine, Department of Otolaryngology, Afyon, Turkey..

Objective: The aim of the study was to find out the possible ototoxic effect of glass ionomer bone cement.

Materials and Methods: In the study, twenty ears of the ten New Zealand white rabbits were used. The left ears of the rabbits were used as study group and injected intratympanically only 0.1 gram glass powder component of the bone cement which solved in isotonic solution. The right ears of the rabbits were used as control group and injected intratympanically only isotonic solution. Cochlear functions were measured before and after injections with distortion product otoacoustic emission (DPOAE) testing.

Results: The first day after intratympanic injections, the DPOAE amplitudes of the left ears were worse than right ears. After one week and one month there was no significant difference between right and left ears.

Conclusion: Our study supports that glass powder component of the bone cement is not ototoxic.

Submitted : 28 February 2010

Revised: 11 August 2010

Accepted : 24 August 2010

Introduction

For many years, otologists have been tried to find the best way to reconstruct the ossicular chain which was eroded by inflammation of middle ear. Many prosthesis, materials and techniques such as resculpturing of the eroded bones, were used for reconstruction for better hearing results.

First generation glass ionomer bone cement was introduced by Wilson and Kent in 1970s and used in dental procedures ^[1]. In 1989 Hehl et al. reported their experiences of fixing incudostapedial joint with glass ionomer cement ^[2]. After this study many authors have presented their glass ionomer bone cement ossiculoplasty series ^[3,5]. They showed that very satisfactory hearing improvements can be obtained by using this material.

In vivo, in vitro and clinical biocompatibility studies of glass-ionomer cement were done and reviewed by Hatton et al. in 2006 ^[6]. Fluoride ions, aluminium ions and low pH have been suggested as a cause of cytotoxicity and neurotoxicity. In addition release of free glass particles from unset cement in contact with

soft tissue was thought to be cause of inflammatory reaction observed in adjacent soft tissues. It is well known that while mixing glass powder with liquid, there is a minimally exothermic reaction which causes low pH and release of ions from glass powder. For this reason otologists mix the bone cement on a metal plate which is distant from ear, to protect from these cytotoxic and neurotoxic components. Glass ionomer bone cement becomes stable and very minimally soluble after hardening.

There is no information about ototoxicity of glass ionomer bone cement. In this study we aimed to find out possible ototoxic effect of glass ionomer bone cement powder.

Materials and Methods

The study assessed in Afyon Kocatepe University Faculty of Medicine. The experimental protocols for studies on rabbits were approved by the animal ethics committee of the Afyon Kocatepe University. During both adaptation and experiment periods, the animals were treated in compliance with the principles of the Declaration of Helsinki.

Corresponding address:

Orhan Kemal Kahveci
AKU Arastirma Hast. KBB AD. Izmir yolu 8.km Afyonkarahisar, TURKEY
Postal Code: 03200
Phone: +90 505 2184236 • Fax: +90 272 2133066
E-mail: orhangs75@hotmail.com

Copyright 2005 © The Mediterranean Society of Otolaryngology and Audiology

The study was performed on 20 ears of the 10 healthy adult New Zealand white rabbits weighing between 2.7 and 3.4 kg. Left ears of the rabbits (10 ears) were used as study group (LE) and right ears of the rabbits (10 ears) were used as control group (RE). All animals were anesthetized both during examinations and experiments via intramuscular injection of 15 mg/kg xylazine hydrochloride (Alfazyne, 20 mg/ml, Alfasan, Holland) and 35 mg/kg ketamine hydrochloride (Alfamane, 100mg/ml, Alfasan, Holland). Eye-blink reflexes and respiratory rhythms were followed during the experiments and no repeated doses of anesthetics were needed. Before otoacoustic measurements, ear examination of the rabbits was managed by otoscope and any foreign body, if present, was removed from the external auditory canal by curette. 0.2 gram of glass ionomer bone cement (Ketac Cem Radiopaque, ESPE, Dental products D-82229 Seedeld, Germany) was solved in 2 cc of 9% NaCl isotonic solution. This amount of glass ionomer is nearly the same as used during an average ossicle reconstruction procedure. After anesthesia 1cc of this solution was administered intratympanically to the left ears of the rabbits under microscopic view and with the aid of a spinal needle (Terumo Spinal Needle 20G x 2 3/4", Terumo Medical, USA). Right ears of the rabbits were used as a control ears and only 1 cc 9% NaCl isotonic solutions were administered intratympanically to these ears with the same procedures.

DPOAE is generated in 20 ears by ILO 288 USB II (Otodynamics Ltd., Clinical OAE System, England) cochlear emission analyzer. The acoustic stimulus consisted of two simultaneous continuous pure tones at different frequencies; F1 and F2 (F2/F1: 1.22). Intensities, L1 and L2, are expressed as 65 dB and 55dB sound pressure level (SPL) respectively. The recordings were performed in an isolated quiet environment and the rabbits were followed to be totally sedated and motionless condition with regular spontaneous breathing, in order to minimize the noise contamination originating from the environment or the muscular activity of the animals. The pediatric probes were used for exact fitting to the ear canal of the rabbits. DPOAE responses recorded on the 0th day before administration (BA), 1st day after administration (AA1D), 1st week after administration (AA1W) and 1st month after administration (AA1M).

Data were statistically analyzed by using SPSS software, version 9 (SSPS Inc., Chicago, IL, USA). Kolmogorov-Smirnov test was used to determine the distribution, where Levene test for the analysis of the equalization of the variations of the groups. Paired t-test was used for the comparison of the data collected after intratympanic administrations with the pre-administration one. All the data obtained from both ears during the consecutive measurements thorough the study was compared using the independent samples t-test. Values for $p < 0.05$ were considered as the level of statistically significance.

Results

In general the rabbits tolerated intratympanic administration of 9% NaCl isotonic solution and glass ionomer bone cement powder well. But one of the rabbits died because of an unknown reason on 20th day and another one died on 28th day after administration. None of the rabbits showed any signs of hair loss, seizure activity, lethargy, poor feeding, or other behavioral changes at any time during the study.

No middle ear infection, no tympanic membrane perforation nor the ear discharge was observed in otoscopic examinations of rabbits before each DPOAE tests. Also the rabbits which died on 20th and 28th days were examined and no signs of any ear infections were observed.

DPOAE tests which were done before injections showed statistically there was no difference in cochlear functions between left ears and right ears ($p > 0.05$ for all frequencies).

The first day after transtympanic injections, DPOAE results showed significant decrease in DPOAE amplitudes of the left ears ($p = 0.007$ for 2,000Hz, $p = 0.001$ for 3,000 Hz, $p = 0.008$ for 4,000 Hz, $p = 0.007$ for 6,000 Hz and $p = 0.001$ for 8,000Hz).

After one week, differentiation in DPOAEs of left and right ears was dissolved and became statistically insignificant ($p > 0.05$ for all frequencies)

After one month statistically there was no difference again between DPOAEs of left and right ears ($p > 0.05$ for all frequencies)

Figures 1-4 demonstrate DPOAE amplitudes of both ears at 2,000, 3,000, 4,000, 6,000 and 8,000 Hz before injection and one day, one week and one month after injections to the middle ear.

Repeated DPOAE measurements of left ear before and after injections showed no significance. Figures 5 and 6 demonstrate repeated measurements of left ear and right ear respectively.

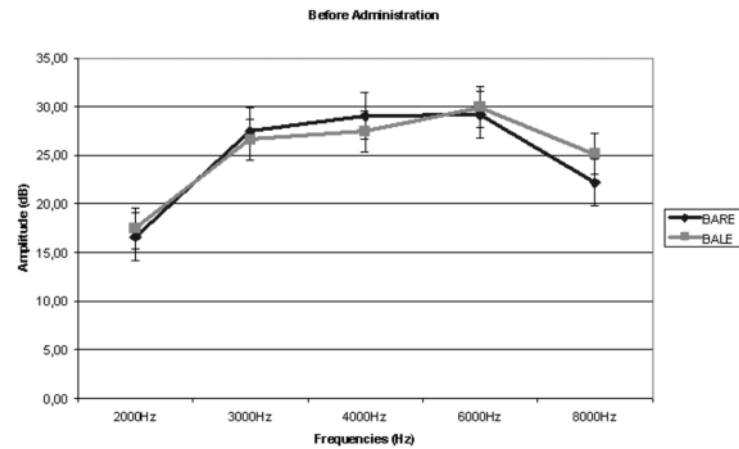


Figure 1. BARE: Mean DPOAE amplitudes of right ears before administration, BALE: Mean DPOAE amplitudes of left ears before administration

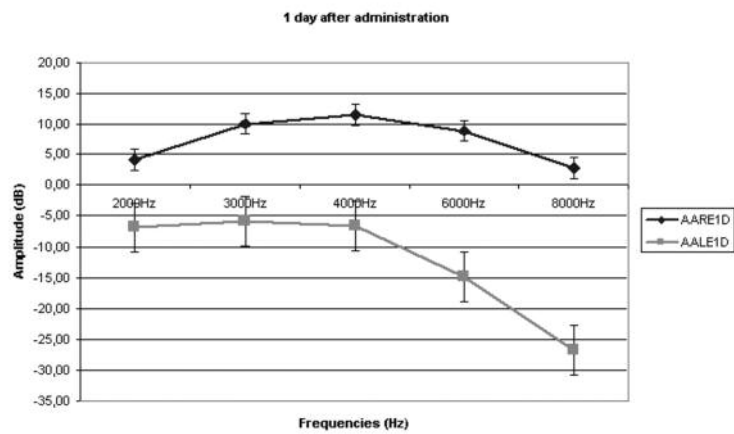


Figure 2. AARE1D: Mean DPOAE amplitudes of right ears after first day, AALE1D: Mean DPOAE amplitudes of left ears after first day

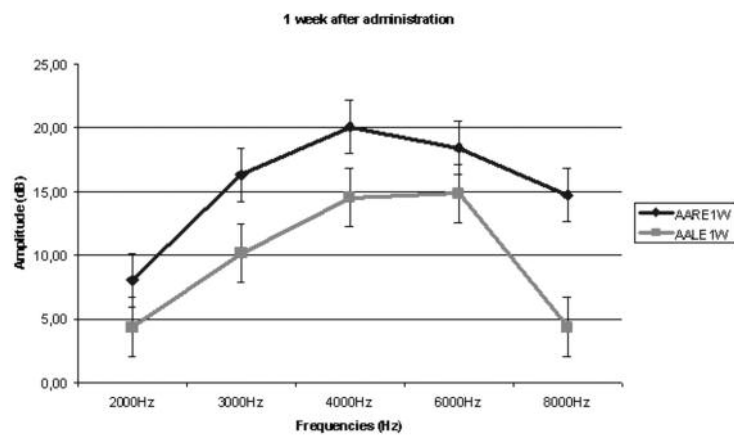


Figure 3. AARE1W: Mean DPOAE amplitudes of right ears after one week, AALE1W: Mean DPOAE amplitudes of left ears after one week

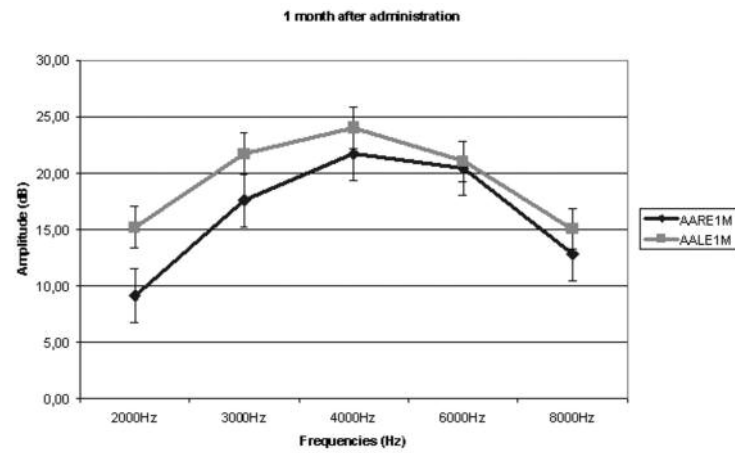


Figure 4. AARE1M: Mean DPOAE amplitudes of right ears after one month, AALE1M: Mean DPOAE amplitudes of left ears after one month

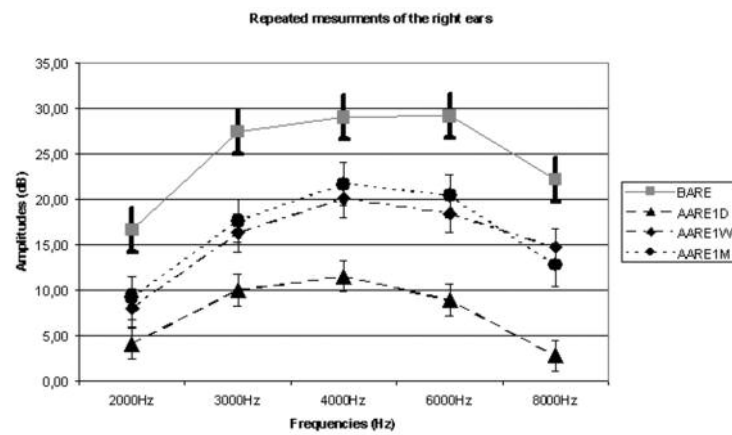


Figure 5. BARE: Mean DPOAE amplitudes of right ears before administration, AARE1D: Mean DPOAE amplitudes of right ears after first day, AARE1W: Mean DPOAE amplitudes of right ears after one week, AARE1M: Mean DPOAE amplitudes of right ears after one month

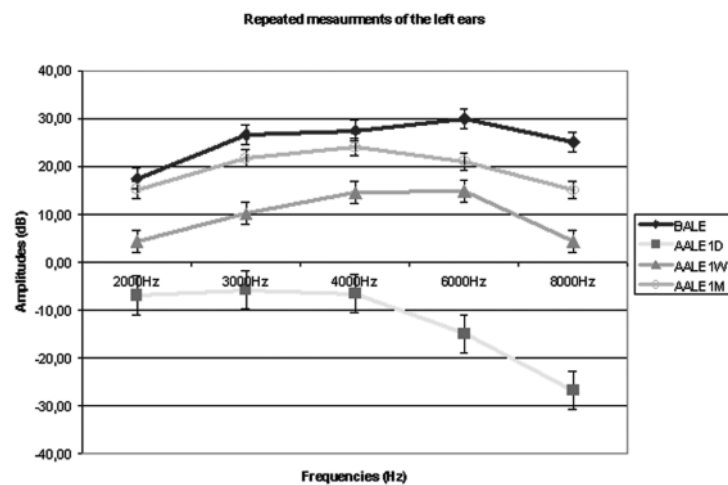


Figure 6. BALE: Mean DPOAE amplitudes of left ears before administration, AALE1D: Mean DPOAE amplitudes of left ears after first day, AALE1W: Mean DPOAE amplitudes of left ears after one week, AALE1M: Mean DPOAE amplitudes of left ears after one month

Discussion

Glass ionomer bone cements are composed of glass powder and polyacrylic acid. Mixture of these components cause a reaction and mixture become a hardened material. Glass-ionomer cements (GIC) have been extensively used in dentistry for over 30 years [6]. Because of GIC's excellent use in dentistry, it was thought as a perfect candidate for other surgeries such as reconstruction of middle ear and ossicles, mastoid obliteration and arthroplasty. Many studies were done for these new indications of GICs. While some authors reported excellent outcomes with GICs, some authors reported poor outcomes and more side effects. Successful results in reconstruction of incus erosion during revision stapedectomies were reported by Chen et al in 2003 [1]. Ozer et al reports of 15 patients, 9 achieved a successful hearing result (an air-bone gap within 20 dB) with incudostapedial rebridging ossiculoplasty with GIC [4]. Kupperman and Tange used the GIC to obliterate the mastoid cavity and the closure of tegmen of their 23 cases. The bone cement extruded in 9 cases. Of these 9 cases 3 were extruded spontaneously, 6 were extruded by a second operation due to middle ear infection and abundant otorrhea. [7]. Engelbrecht and co-workers described 45 revision arthroplasty cases between 1991 and 1994.

Most of the reported complications of glass ionomer were related to neurotoxicity and cytotoxicity. Fluoride ion release has been suggested as a cause of cytotoxicity. Metal ions have also been suggested as a possible cytotoxic factor. Especially aluminium ion was found in cells cultured on the surface of set glass ionomers. Low pH of the cements while setting and maturing has been also suggested as a cause of cytotoxicity and neurotoxicity [6]. Above mentioned toxic properties are seen while setting reaction. Also Hatton pointed the importance of release of free glass particles from unset cement in contact with soft tissues. The adverse effect of water on the glassionomer setting reaction is well known and glass particle release is the most likely cause of the inflammatory reaction observed in adjacent soft tissues [6]. Kupperman and Tange showed granulation and infection could occur after glass ionomer cement obliteration in their rat experimental study [8].

Otolaryngologists mix the bone cement far away from the ear to prevent cytotoxic and neurotoxic effects of setting reaction. They take the mixture with a small pick and use it for fixing ossicles before cement hardens. At this stage otolaryngologists pay much more attention not to drop any bone cement to the middle ear and mucosa. If it drops early cleaning of the mucosa from bone cement with isotonic solution is recommended [3].

Ototoxic property of the bone cement is still unknown. There are few difficulties to access this information and to start an animal experimental study about this problem; I. Difficulty in injecting bone cement mixture to the middle ear without a tympanoplasty operation. II. Difficulty to observe DPOAE amplitudes, if the one fills the whole middle ear with bone cement mixture. III. Difficulty to decide for dropping area, if we simulate otologic operation in animal's ear, (round window, oval window, hypotympanum or mezotympanum). Dropping on oval window or ossicles could cause unwanted conduction type hearing losses and affect the DPOAE results. Therefore we used only powder component of the bone cement which was solved in 2 cc of 9% NaCl isotonic solution to test toxic effects.

In this study, it was aimed to figure out the cytotoxic and ototoxic effects of glass powder. Glass particle release can occur by a contact with isotonic solution and ototoxic effects of glass particles can be obtained with DPOAE. We used 0.1 gram of bone cement powder, because this amount is enough to fix any incudostapedial joint deformity. Our study showed that glass powder has no ototoxicity and showed no cytotoxicity in early postoperative phase. One month could be accepted as an early postoperative phase when we discuss about cytotoxicity because Kupperman and Tange reported middle ear infection and otorrhea occurred after 10 to 18 month after bone cement obliteration [7].

DPOAE studies showed that cochlea was not affected from glass powder. Only amplitudes of the left ears were lower than right ears at first day after injections. The possible cause could be explained by the different densities of the solutions injected to the middle ears. High density of glass powder mixture solution could make a mass effect in the middle ear and mask the

DPOAE results. After absorption and cleaning out of the solutions from middle ear by Eustachian tube and mucosa, the mass effect was disappeared and DPOAE amplitudes returned to their pre-injection rates. So the DPOAE results were became statistically normal after one week.

Another theory can be that glass powder caused a short time hearing loss and it recovered in a week. Repeated doses might have cause a permanent hearing loss. This theory seems questionable because most ototoxic drugs cause a permanent hearing loss not temporary hearing loss. Even the second theory is right, we do not use bone cement more than few grams nor the repeated doses in reconstructions of middle ears. Few milligrams of powder and few drops of dissolving liquid are enough to rebridge the incudostapedial joint^[4]. So it does not hinder our use of bone cement in otologic surgery.

Conclusion

Glass powder which is one of the two components of the glass ionomer bone cement seems not ototoxic and cytotoxic for middle ear and cochlea. Considering prior studies glass ionomer bone cement has cytotoxic and neurotoxic effects. The second component of bone cement which is liquid (containing tartaric acid, water and conservation agents) or the setting reaction could be responsible of these toxic effects. Further studies should be done for ototoxic properties of liquid part of glass ionomer bone cement and the setting reaction.

References

1. Chen DA, Arriaga MA. Technical refinements and precautions during ionomeric cement reconstruction of incus erosion during revision stapedectomy. *Laryngoscope*. 2003; 113:848-52
2. Hehl K, Schumann K, Beck C, Schöttle W. Use of glass ionomer cement in surgery of the incus-stapedial joint. An initial report of experiences. *Laryngorhinootologie* 1989; 68:490-2
3. Bayazit YA, Ozer E, Kanlikama M, et al. Bone cement ossiculoplasty: incus to stapes versus malleus to stapes cement bridge. *Otol Neurotol* 2005; 26: 364-7.
4. Ozer E, Bayazit YA, Kanlikama M, et al. Incudostapedial rebridging ossiculoplasty with bone cement. *Otol Neurotol* 2002; 23:643-6.
5. Ráth G, Bauer M, Pytel J, Vóna I, et al. Ionomer cement for reconstruction of the long process of the incus: the Pécs experience. *Clin Otolaryngol* 2008; 33:116-20
6. Hatton PV, Hurrell-Gillingham K, Brook IM. Biocompatibility of glass-ionomer bone cements. *J Dent* 2006; 34:598-601.
7. Kupperman D, Tange RA. Ionomeric cement in the human middle ear cavity: long-term results of 23 cases. *Laryngoscope* 2001; 111:306-9.
8. Kupperman D, Tange RA. Long-term results of glass ionomer cement, Ionocem, in the middle ear of the rat. *Acta Otorhinolaryngol Belg* 1997; 51:27-30.