

CASE REPORT

Secondary Endolymphatic Hydrops Following Sudden Deafness Detected by MRI after Intratympanic Administration of Gadolinium

Arata Horii, Junji Miyabe, Yasuhiro Osaki, Tadashi Kitahara, Takao Imai, Atsuhiko Uno, Suetaka Nishiike, Norihiko Fujita, Hidenori Inohara

Department of Otolaryngology, Suita Municipal Hospital (AH)

Department of Otorhinolaryngology-Head and Neck Surgery, Osaka University Graduate School of Medicine (AH, TI, AU, SN, HI)

Department of Otolaryngology, Higashiosaka City General Hospital (JM)

Department of Otolaryngology, Faculty of Medicine, Kagawa University (YO)

Department of Otolaryngology, Osaka Rosai Hospital (TK)

Department of Radiology, Osaka University Graduate School of Medicine (NF)

Objective of this report is to alert the existence of secondary endolymphatic hydrops at the beginning of the era for diagnosing the hydrops by image analyses. A 64 years-old female who showed partial recovery of hearing disturbance two months after the onset of sudden deafness underwent inner ear MRI in combination with intratympanic injection of gadolinium. Two-dimensional fluid-attenuated inversion recovery (2D-FLAIR) sequences taken by 3 tesla MR unit showed endolymphatic hydrops in the cochlea. Electrocochleogram could not be performed due to high tone hearing loss. At present, inner ear MRI in combination with intratympanic injection of gadolinium has been mainly used for Meniere's patients to detect endolymphatic hydrops. However, this tool cannot distinguish the secondary hydrops as seen in our case from Meniere's disease and thus should be used with careful attention if used as a routine test for inner ear diseases.

Submitted : 25 February 2011

Accepted : 15 June 2011

Introduction

Endolymphatic hydrops is believed to be a pathophysiology of Meniere's disease [1-3]. However, recent cadaver studies revealed the existence of endolymphatic hydrops in temporal bones from non-Meniere's patients without any audio-vestibular symptoms (asymptomatic hydrops) as well as patients with a history of inner ear insults such as middle ear surgery or head trauma but with no Meniere's symptoms (secondary hydrops) [4]. Asymptomatic hydrops might not be a problem in clinical settings, however, this paper suggested that the endolymphatic hydrops does not directly imply the Meniere's disease

but we should be aware of the secondary hydrops following inner ear insults [4].

Electrocochleogram (ECoG) has been used for the detection of endolymphatic hydrops, while its usefulness for the detection of hydrops is still controversial. ECoG cannot be performed for patients with profound hearing loss. Recent advances in magnetic resonance imaging (MRI) coupled with intratympanic administration of gadolinium enabled us to visualize the endolymphatic hydrops in a living patient [5-9]. It would be expected that the number of chances we diagnose endolymphatic hydrops by images will be increased in future. However, as

Corresponding address:

Arata Horii

Department of Otolaryngology Suita Municipal Hospital

2-13-20 Katayama-Cho, Suita, OSAKA 564-0082 Japan

Phone: 81-6-6387-3311 • Fax: 81-6-6380-5825

E-mail: ahorii@ent.med.osaka-u.ac.jp

Copyright 2005 © The Mediterranean Society of Otolaryngology and Audiology

mentioned above, we should distinguish the secondary hydrops from Meniere's disease in the diagnosis and treatment of inner ear diseases, because secondary endolymphatic hydrops is just a result of previous inner ear insults but does not have a causal relation to the latest symptoms of the patient [4]. In the current report, we present a patient with secondary endolymphatic hydrops revealed by 3 tesla (T) MRI in combination with intratympanic gadolinium injection after partial recovery of sudden deafness in whom ECoG could not be performed due to high tone hearing loss.

Case Report

A 64 years-old female patient visited our hospital with complaint of sudden hearing disturbance and tinnitus of the left ear with slight dizziness from two days ago. Pure tone audiogram showed a sensorineural hearing loss involved with all frequencies (Figure 1A). Ear drums were normal and tympanogram showed bilateral type A. She was diagnosed as having left sudden deafness. Combination of intravenous injection of steroid and batroxobin induced partial recovery of patient's hearing disturbance mainly in low frequency (Figure 1B).

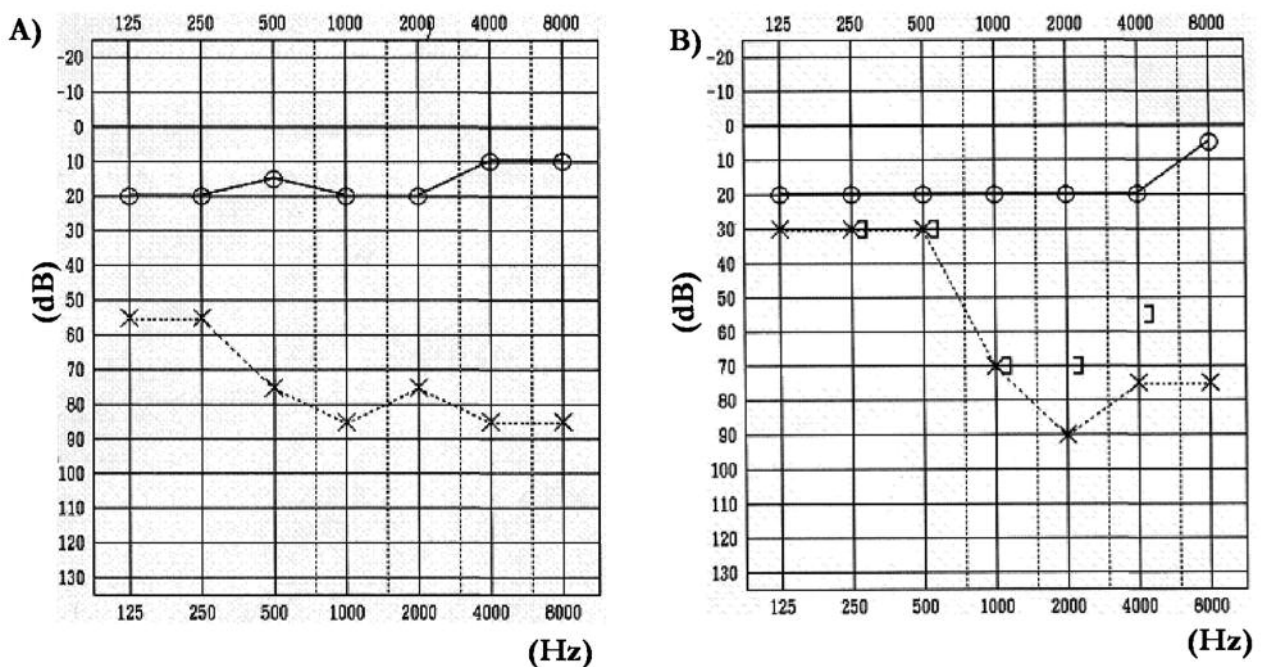


Figure 1. Pure tone audiogram at the time of first visit (A) and just before inner ear MRI two months after the onset of sudden deafness (B). The patient showed profound hearing loss at the first visit (A) and partial recovery of hearing loss was obtained mainly at the low frequency just before the inner ear MRI (B).

Two months after the onset of sudden deafness, she still had a wish for more recovery of hearing and tinnitus suppression. For this purpose, she received an intratympanic injection of steroid. One day before this intervention, endolymphatic image analysis was performed using inner ear MRI with intratympanic injection of gadolinium. The protocol for inner ear MRI in combination with intratympanic injection of

gadolinium was approved by Osaka University Hospital (IRB# 08223). Gadodiamide hydrate (Omniscan®) diluted eightfold with saline was injected intratympanically using a 23 gauge needle and syringe. Twenty four hours after the injection, axial images were taken by 3T General Electric (GE) MR unit with fast imaging employing steady state acquisition (FIESTA) and two-dimensional fluid-

attenuated inversion recovery (2D-FLAIR) sequences. As images taken with FIESTA sequence were quite similar to those taken with constructive interference in the steady state (CISS) sequence used by previous studies ^[4-7], FIESTA images are referred to as CISS images in this study. CISS images are suitable for the detection of the outline of the whole inner ear, because CISS is a heavily T2 weighted images and thus can be sensitive to both the endolymph and the perilymph. Intratympanically injected gadolinium can enter only into the perilymphatic space, leaving the endolymph with no or faint gadolinium enhancement, which explains the good contrast between the perilymph and endolymph in FLAIR sequences ^[5]. As shown in Fig. 2B, FLAIR images demonstrated that enlarged scala media was shown as low signal intensity area surrounded by perilymphatic space with gadolinium enhancement (arrow). Figure 2A shows a hydrops-negative cochlea in control patient, in which no

enlargement of low signal intensity area was shown.

Electrocochleogram showed normal -summing potential/action potential (-SP/AP) for the right ear (-SP/AP=0.37), however, it was impossible to perform for the left ear due to high tone hearing loss. Bithermal caloric test showed left caloric weakness (CP%=60%). Unfortunately, intratympanic injection of steroid had no remarkable effects on her hearing (data not shown). Until the last follow up, she had no fluctuating hearing loss or recurrent vertigo for 22 months.

Discussion

FLAIR images after intratympanic injection of gadolinium showed endolymphatic hydrops in the cochlea, which was shown as low signal intensity area surrounded by perilymphatic space with gadolinium enhancement (Figure 2B, arrow). According to the grading system of endolymphatic hydrops proposed by Nakashima et al. ^[9], cochlea had a mild hydrops.

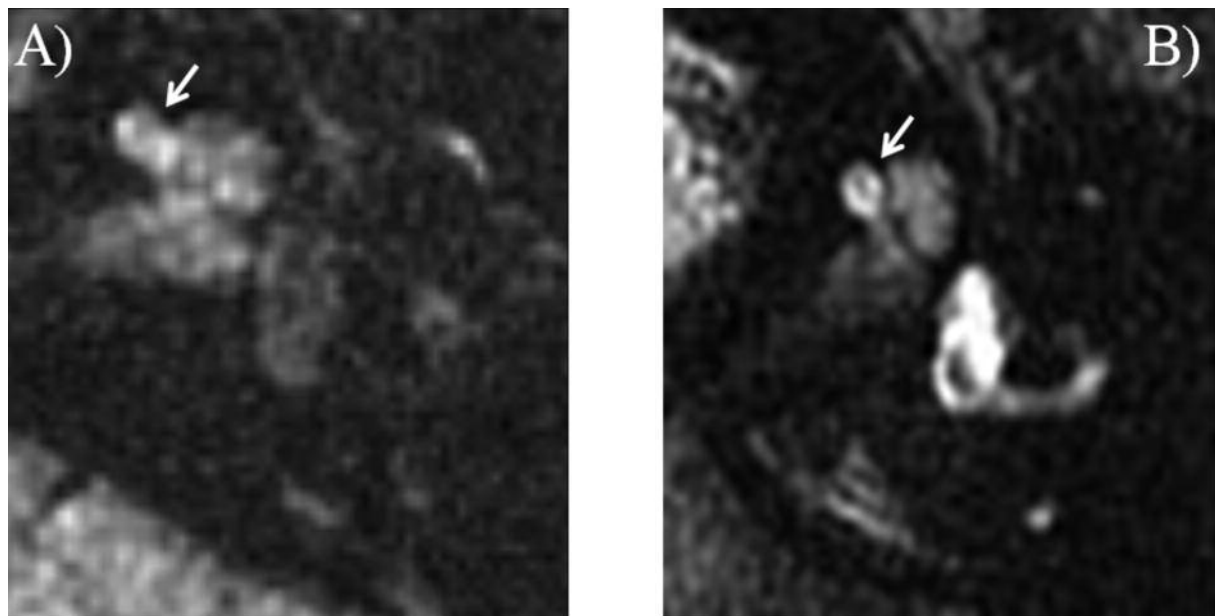


Figure 2. Fig. 2A shows a hydrops-negative cochlea from control patient, in which no enlargement of low signal intensity area was shown. 2D-FLAIR images of the inner ear (Fig. 2B), endolymphatic hydrops were seen at the cochlea as low signal intensity area surrounded by perilymphatic space with gadolinium enhancement.

MRI was taken after partial recovery of hearing loss two months after the onset of sudden deafness (See Fig. 1B, audiogram at the time of MRI). It was not clear whether these hydrops existed from the early onset of sudden deafness or it developed after the partial recovery from sudden deafness, because inner ear MRIs were not taken at the onset of sudden deafness. However, in any case, these hydrops were not causally related to the pathogenesis of sudden deafness of these patients. If endolymphatic hydrops had been the primary cause of sudden deafness of these patients, the hydrops would have disappeared after partial recovery from hearing loss, which was not evident in these patients. Therefore, it was suggested that these were the secondary hydrops cases. There still remains possibility that the patient showed spontaneous recovery rather than the medication-induced hearing recovery, however, in any case, this was suggested to be the secondary hydrops.

In this case, ECoG could not be performed due to high tone hearing loss. It is indicated that as one of merits of image analysis, this method can demonstrate endolymphatic hydrops even in patients with high tone hearing loss in whom ECoG cannot be performed. If endolymphatic images had not been performed, this patient would have never been diagnosed as having endolymphatic hydrops. Although images revealed endolymphatic hydrops, treatment for endolymphatic hydrops such as endolymphatic sac surgery for this patient at this stage was nonsense and should be avoided.

Recently, inner ear MRI with intratympanic gadolinium injection becomes popular radiological test for detecting endolymphatic hydrops [5-9]. To date, it has been performed mainly for Meniere's patients to confirm the existence of endolymphatic hydrops [5-9]. However, if endolymphatic images will be used as one of routine tests in future, we should pay much attention to the secondary endolymphatic hydrops. As Merchant et al. reported, cadaver studies revealed that endolymphatic hydrops were demonstrated in temporal bones not only from Meniere's patients but also from patients with many kind of inner ear insults

who had no Meniere's symptoms [4]. It would be expected that substantial portion of inner ear diseases could cause secondary hydrops following initial manifestation of inner ear dysfunction. Including the current case, we reported that two of eight patients with sudden deafness developed secondary hydrops after partial recovery of hearing disturbance several months after the onset of sudden deafness [10]. However, treatment for endolymphatic hydrops at that time point may be nonsense for recovering from the resultant symptoms by the primary pathology as in the current case.

In conclusion, era for diagnosing endolymphatic hydrops by image analyses has started. This method is useful even in patients with profound hearing loss in whom ECoG cannot be performed. However, this tool of course cannot discriminate the secondary hydrops from Meniere's disease and should be used with careful attention in the diagnosis and treatment of inner ear diseases.

Acknowledgement

Part of this study was presented at the American Neurotology Society 45th Annual Spring Meeting in Las Vegas.

References

1. Yamakawa K. Uber die pathologisch Veranderung bei einem Meniere-Kranken. J Otorhinolaryngol Soc Jpn 1938; 4: 2310-2.
2. Hallpike CS, Cairns H. Observation on the pathology of Meniere's syndrome. J Laryngol Otol 1938; 53: 625-55.
3. Kamakura T, Kitahara T, Horii A, Inohara H. Delayed facial nerve palsy after endolymphatic sac surgery. Int Adv Otol 2011; 7: 130-133.
4. Merchant SN, Adams JC, Nadol JB Jr. Pathophysiology of Meniere's syndrome: are symptoms caused by endolymphatic hydrops? Otol Neurotol 2005; 26: 74-81.
5. Nakashima T, Naganawa S, Sugiura M, Teranishi M, Sone M, Hayashi H et al. Visualization of endolymphatic hydrops in patients with Meniere's disease. Laryngoscope 2007; 117: 415-20.

6. Naganawa S, Sugiura M, Kawamura M, Fukatsu H, Sone M, Nakashima T. Imaging of endolymphatic and perilymphatic fluid at 3T after intratympanic administration of gadolinium-diethylene-triamine pentaacetic acid. *AJNR Am J Neuroradiol* 2008; 29: 724-6.
7. Naganawa S, Nakashima T. Cutting edge of inner ear MRI. *Acta Otolaryngol Suppl* 2009; 560: 15-21.
8. Fukuoka H, Tsukada K, Miyagawa M, Oguchi T, Takumi Y, Sugiura M et al. Semi-quantitative evaluation of endolymphatic hydrops by bilateral intratympanic gadolinium-based contrast agent (GBCA) administration with MRI for Meniere's disease. *Acta Otolaryngol* 2010; 130: 10-6.
9. Nakashima T, Naganawa S, Pykko I, Gibson W. P. R., Sone M, Nakata S. Grading of endolymphatic hydrops using magnetic resonance imaging. *Acta Otolaryngol Suppl* 2009; 560: 5-8.
10. Horii A, Osaki Y, Kitahara T, Imai T, Uno A, Nishiike S et al. Endolymphatic hydrops in Meniere's disease detected by MRI after intratympanic administration of gadolinium: in comparison with sudden deafness. *Acta Otolaryngol* 131: 602-609, 2011