

## ORIGINAL ARTICLE

# Superior Semicircular Canal Dehiscence: A Missed Finding in Temporal Bone Multidetector CT Scans in Symptomatic Patients Presenting with Vertigo

Ahmed Fathy Abdel Ghany, Noha Mohamed Osman

Department of Radiodiagnostics, Ain Shams University (AFAG, NMO)

**Objective:** To determine the use of multi-detector row computed tomography (CT) in the diagnostic interpretation of superior semicircular canal dehiscence (SSCD) in patients with unapparent aetiology of vertigo thus aiding pre-surgical planning.

**Materials and Methods:** Retrospective temporal bone multidetector CT scans with 0.5 mm image interval including coronal and oblique sagittal and oblique coronal views were obtained and reviewed for the presence of canal dehiscence and dehiscence sizes were recorded in positive cases out of 28 patients who had formerly performed routine CT temporal bone at 1 mm image interval with only coronal and axial views and were reported as normal studies..

**Results:** The study revealed that 8 patients out of 28 were positive for superior canal dehiscence. Five cases were left sided, 2 cases were right sided, whereas 1 case was bilaterally dehiscent. All dehiscences were detected at the apex of bony covering of superior semicircular canal, dehiscence size ranged from 2.1 mm to 5.2 mm with a mean of 3.9 mm. In all positive cases, dehiscence was evident at the coronal and oblique planes with 0.5 mm image interval, while only in 1 patient the dehiscence was poorly visualized in coronal images at 1 mm image interval.

**Conclusion:** Good clinical assessment is mandatory for raising the suspicion of SSCD in patients suffering from vertigo, consequent imaging using multidetector row CT scan with 0.5 mm image interval and auxiliary oblique reformatted planes are required for confirming the diagnosis.

Submitted : 01 March 2011

Accepted : 15 April 2011

## Introduction

Superior semicircular canal dehiscence (SSCD) is an exciting and a recently described disorder in the field of otology <sup>[1]</sup>, since its initial description by Minor et al. in 1998 <sup>[2]</sup>, SSCD has rapidly become an accepted diagnosis in the evaluation of vertigo. The diagnosis of superior semicircular canal dehiscence syndrome depends on the demonstration of a very small defect in the bony wall of the superior semicircular canal (SCC) at the dural interface in the floor of the middle cranial fossa. Patients most frequently experience vertigo induced by loud noises or pressure changes, together with vertical-torsional eye movements that align with the plane of the affected SSC evoked by these stimuli (Tullio phenomenon) <sup>[3]</sup>. A defect in the osseous semicircular canal can also cause apparent conductive hearing loss, hyperacusis for bone conducted sounds and autophony. Patients can experience symptoms such as hearing their pulse or hearing their eye movements <sup>[4]</sup>. Some patients have exclusively

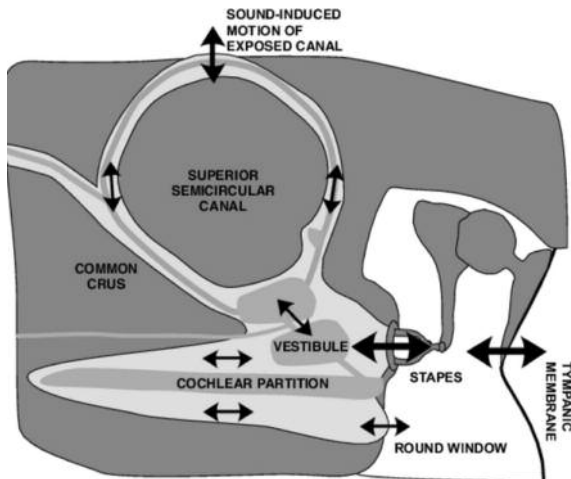
vestibular symptoms and signs, while some have both vestibular and auditory manifestations and still other patients have only auditory complaints <sup>[5]</sup>. The auditory and vestibular manifestations of superior canal dehiscence can be understood in terms of the creation of a third mobile window by the dehiscence into the inner ear (Fig.1), exposing the membranous semicircular canal to the middle cranial fossa. This creates abnormal sound pathways and allows abnormal flow of endolymph in the superior canal in response to positive or negative pressures <sup>[3]</sup>.

The Tullio phenomenon has been described in many different conditions affecting the middle and inner portions of the ear, including syphilis, congenital deafness, Meniere's disease, perilymph fistulas, trauma, and Lyme disease. Patients with some of these same abnormalities have also been reported to have vestibular symptoms and possibly eye movements evoked by stimuli that result in changes in middle ear or intracranial pressure. Furthermore symptoms of

### Corresponding address:

Ahmed Fathy Abdel Ghany  
81 Mohy Eldeen Abdel Hameed, 8<sup>th</sup> district, Nasr City, Cairo, Egypt.  
Phone: (+2)0172964223  
ahmedfathyalmasmar@yahoo.com

sound- and/or pressure-induced vertigo can be seen in a variety of disorders affecting the vestibular system, including autoimmune inner ear disease, perilymphatic fistula, and vestibular migraine, in addition to SSCD [6].



**Figure 1.** The hypothetical response of inner ear fluid motion to air conducted sound in an ear with a dehiscant canal. The solid black arrows show the proposed directions of motion, where arrow size is proportional to magnitude of motion. The endolymph (grey), perilymph (light grey), and bony capsule (dark grey) are illustrated, along with a dehiscence at the apex of the superior semicircular canal. Air-conducted sound causes a stapes volume velocity, which is partially shunted through the superior semicircular canal when there is a dehiscence. This shunting leads to a decrease in the stimulus to the cochlea and diminishes the round window velocity (Quoted from Rosowski et al., 2004).

In many cases, SSCD can mimic a wide range of otological disorders, in particular otosclerosis that exploratory tympanotomy and even stapedectomy has been performed on some of these patients without benefit to the hearing [7].

No specific laboratory studies confirm the diagnosis of superior canal dehiscence syndrome, few laboratory tests may be helpful as the vestibular evoked myogenic potential (VEMP) and audiometric testing. Patients with superior canal dehiscence syndrome have a lower than normal threshold for eliciting the VEMP response in the affected ear. Comprehensive audiometric evaluation is indicated in any patient with vestibular symptoms. Patients with SSCD may have conductive hearing loss; the air-bone gaps are typically greatest at frequencies below 1 kHz (4).

Superior semicircular canal dehiscence is considered a treatable cause of vertigo. Its clinical suspicion bears, at least, the advantage of causing the avoidance of inadequate diagnostic or therapeutic measures [8].

The management is either conservative, with ear plug use and avoidance of provoking stimuli, or surgical, if the symptoms are uncontrollable. Surgical correction varies from middle fossa craniotomy and covering of the defect with bone wax, cement, or fascia to less invasive approaches involving reinforcement of the oval and round windows to decrease their movement [9].

The purpose of this study, therefore, was to determine the use of multi-detector row CT in the diagnosis of SSCD and to localize the site and size of dehiscence its size in patients with unapparent aetiology of vertigo or dizziness thus aiding pre-surgical planning.

## Materials and Methods

### Patients:

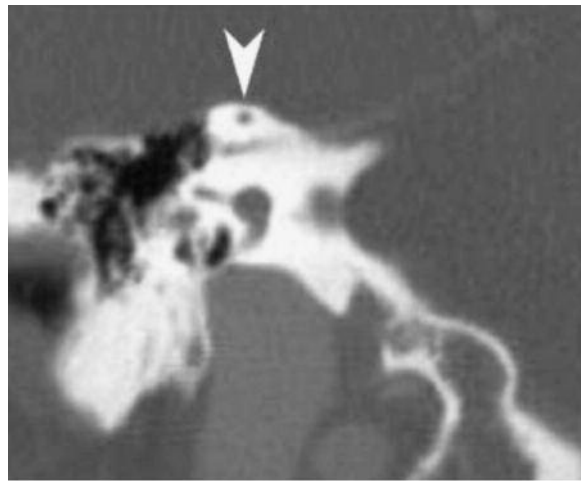
From June 2010 to December 2010, we retrospectively evaluated through the electronic medical record system previously interpreted temporal bone multi-detector row CT scans of 28 patients (56 temporal bones) with clinical suspicion of SSCD, CT temporal bone scans were previously reported as normal studies. Our patients included 19 men and 9 women; their ages ranged from 23 to 67 years with an average of 40 years, those patients were primarily referred with various vestibular symptoms commonly vertigo associated with the presence or absence of auditory manifestations in some patients. Our re-evaluation for CT temporal bones of such patients was requested from the side of the otolaryngology specialists who clinically suspected SSCD based on patient's symptoms, clinical examination as well as the clinical audio-vestibular tests.

### CT protocol:

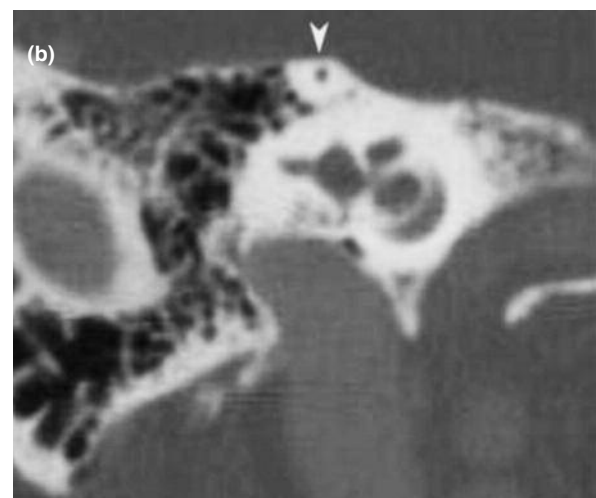

All patients underwent contrast multidetector row temporal bone CT scans with 16- section multidetector row CT scanner (Bright Speed; GE medical systems, Milwaukee, USA) with injection of non ionic contrast material 1 ml/kg using manual injection in Misr Radiology Center, Cairo, Egypt. The original row helical scans of those patients were acquired with a section thickness of 0.5 mm and a spacing of 0.3 mm (kV, 120; mA, 360; helical pitch, 0.562:1; rotation

time, 0.8 second). Our patients were primarily referred to our center for CT temporal bone scans for depiction of the cause of clinical presentation which was commonly vertigo, so patients underwent contrast CT temporal bone scans as a routine work up. After their CT scans were requested for reviewing for SSCD as an existing clinical suspicion, we retrospectively transferred the original raw data transverse images of all our selected CT temporal bone scans of the patients under study to ADW4.0 workstation (GE Medical Systems, USA) where coronal reformations at 0.5 mm

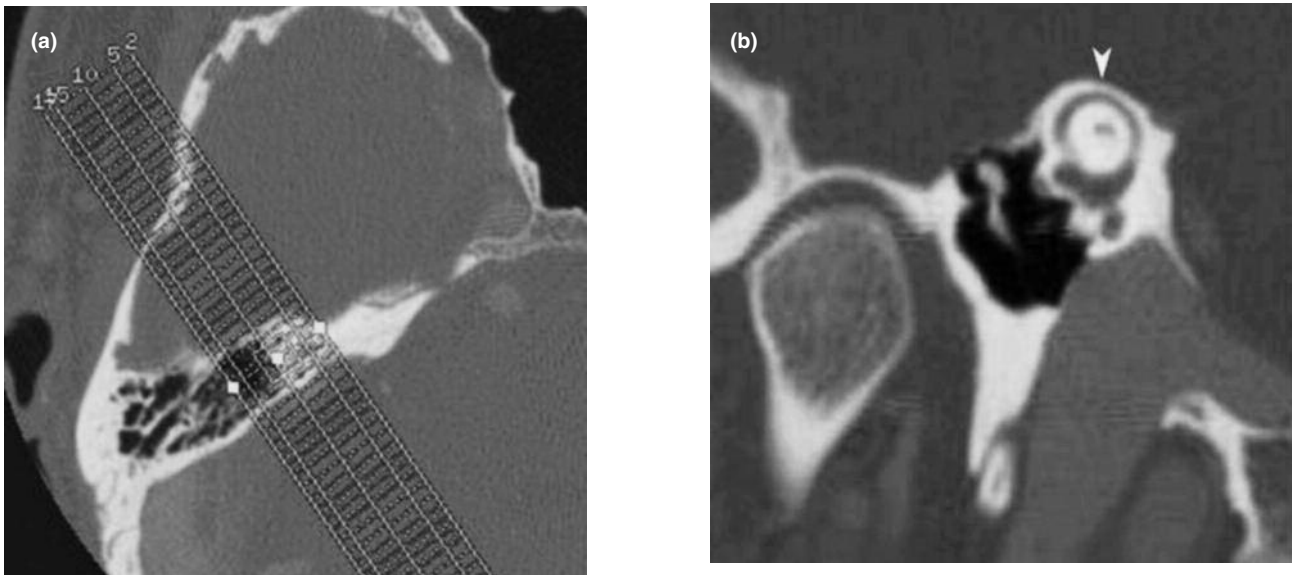
image interval were created (Fig. 2) instead of 1.0 mm interval as were performed formerly in the primary CT films, additional reconstructions at 0.5 mm image interval were also performed in the plane of Stenver or oblique sagittal plane (parallel to the plane of the superior semicircular canal) (Fig. 3a, b), and in the plane of Pöschl or oblique coronal plane (perpendicular to the course of the superior semicircular canal) (Fig. 4a, b), those additional planes were not acquired in the primary CT studies.



**Figure 2.** SSCD: Coronal reformatted image from thin-section transverse CT examination shows bony covering of superior semicircular canal is intact (Quoted from Branstetter et al., 2006).



**Figure 3.** Plane of Stenver (oblique sagittal): **(a):** angle of reformation demonstrated on transverse scout image. **(b):** Intact superior semicircular canal (arrowhead) (Quoted from Branstetter et al., 2006).



**Figure 4.** Plane of Pöschl (oblique coronal): **(a):** angle of reformation demonstrated on transverse scout image. **(b):** Intact superior semicircular canal (arrowhead) (Quoted from Branstetter et al., 2006 ).

### Normal CT appearance of SCC:

#### Image review:

CT temporal bone scans of our 28 studied patients (56 temporal bones) were reinterpreted to search for SSCD as a hidden cause for patient's clinical manifestations after reconstruction of the CT examinations to include the standard coronal views of temporal bones and the auxiliary reformatted oblique coronal and oblique sagittal temporal views, with all the images spaced at 0.5 mm interval.

The determination of dehiscence is made by visual inspection of the bony covering of the superior semicircular canal and on each review, the observer assigned a term of "dehiscent" (positive) or "intact" (negative) to the bony covering of the superior semicircular canal, the site of the dehiscence was determined and the exact measure was also recorded. Measurement of the canal dehiscence was carried out by applying a straight line subtending the arc of the dehiscent segment in the oblique coronal images (plane of Pöschl).

### Results

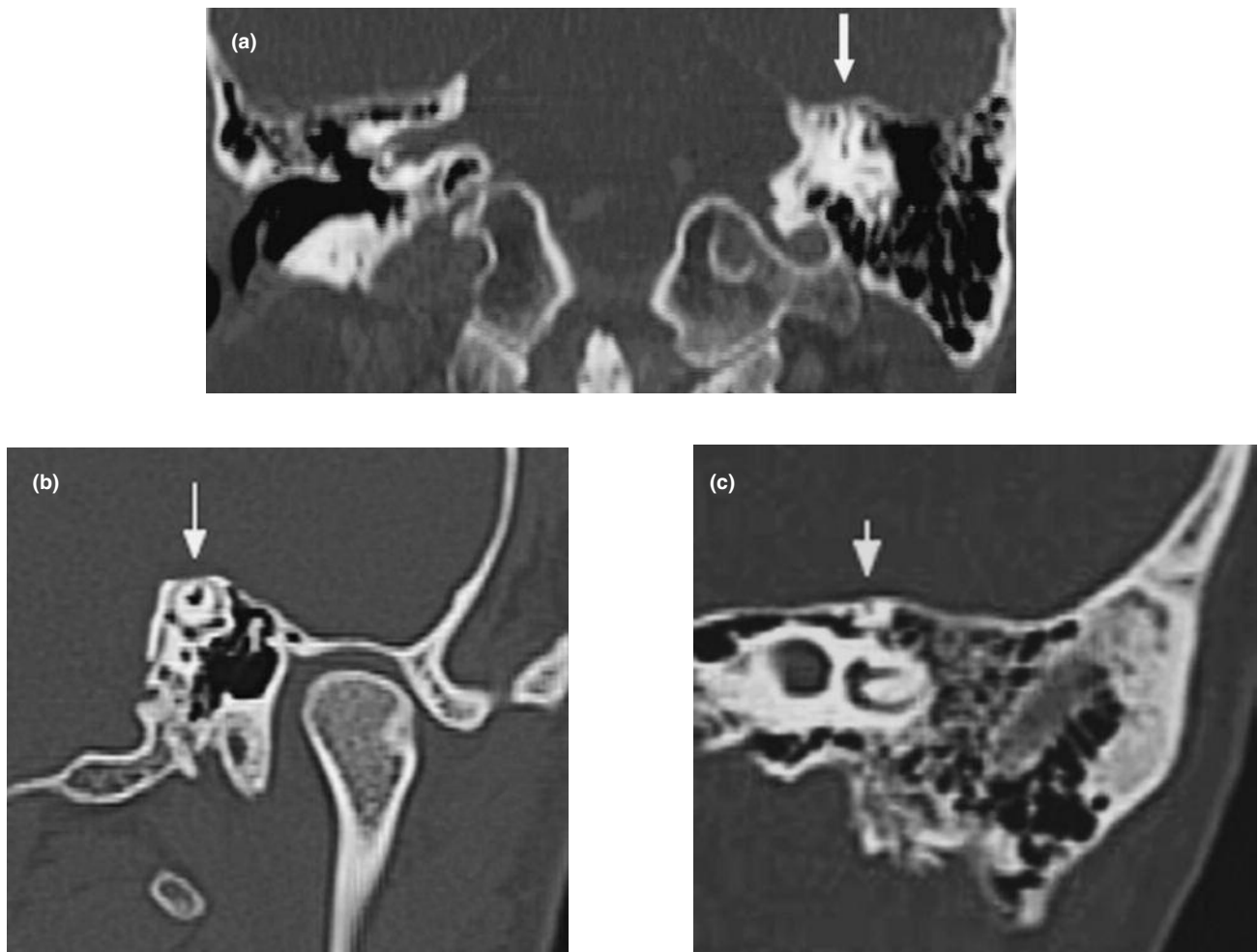
Review of CT temporal bones of selected 28 patients for the purpose of our study after reconstructing the coronal images of temporal bone scans at spacing 0.5

mm, together with addition of oblique coronal and oblique sagittal reconstructions to the standard coronal plane revealed that 8 out of 28 patients were positive for SSCD with 9 total dehiscences; 5 males and 3 females, their ages ranged from 32 to 60 years and the mean age was 44 years. Five cases were left sided (62.5%) (Fig.5), 2 cases (25%) were right sided whereas 1 case (12.5%) was bilaterally dehiscent (Fig.6). All dehiscences were detected at the apex of bony covering of SSC, bony dehiscence size ranged from 2.1 mm to 5.2 mm with a mean of 3.9 mm (Table 1).

In 6 out of 8 positive cases ( 7 out of 9 dehiscences), SSCD was clearly detected in the standard 0.5 mm spacing coronal images in addition to the oblique coronal and oblique sagittal images, whereas in the other 2 patients (2 dehiscences) coronal images were equivocal but the oblique views documented the presence of dehiscence.

On retrospective viewing of the primary standard coronal images of our 28 patients which were reconstructed at 1.0 mm interval with no additional oblique reformats, 1 case had query dehiscence on the left side for which the coronal view only was non conclusive, whereas in the remaining 7 cases SSCD was unidentified.

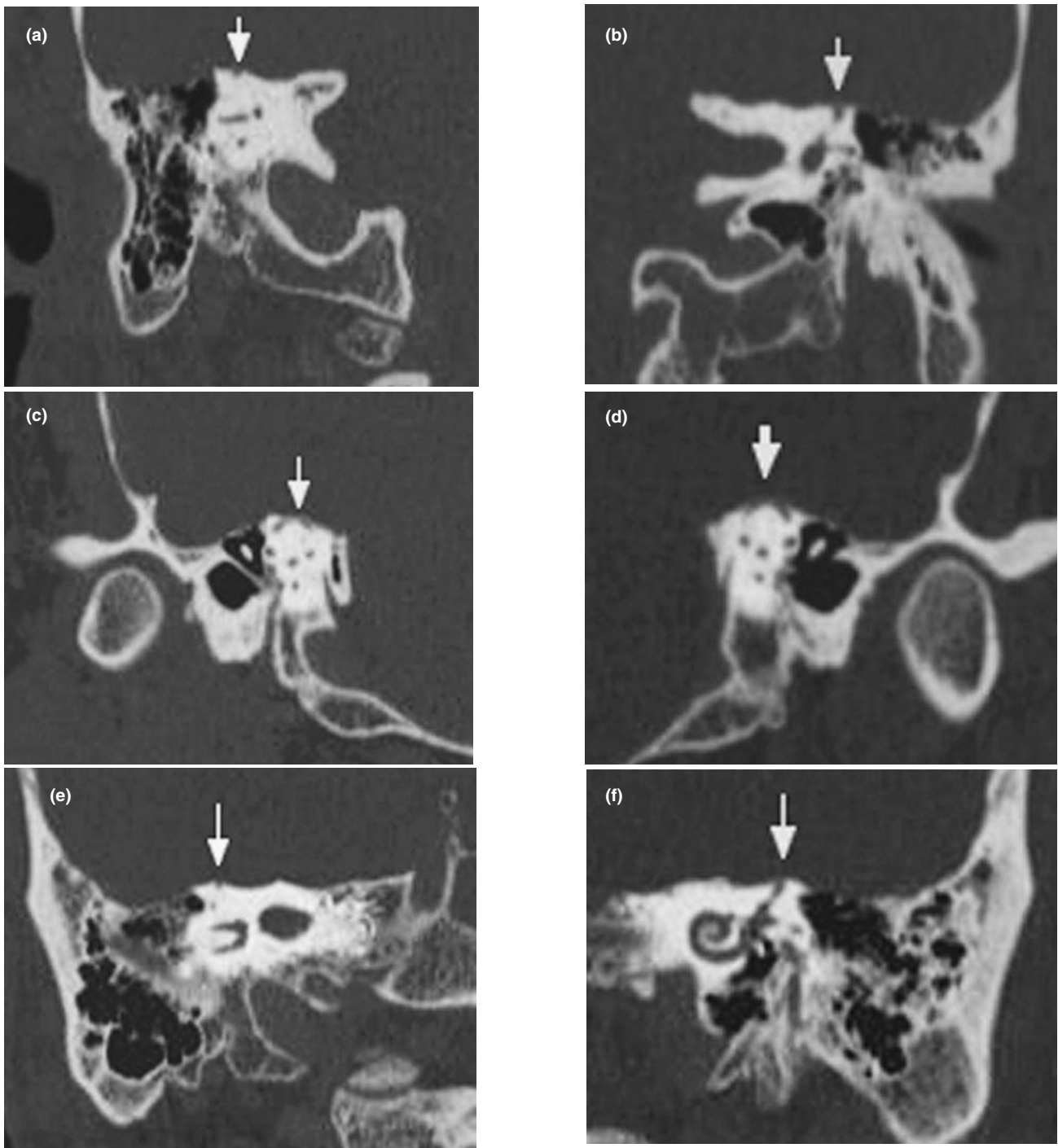




**Figure 5.** Male patient, 32 years old, complaining of vertigo (case 1 in table 1). CT temporal bone revealed: left sided SSCD which was seen in coronal images 5 mm interval (arrowed) **(a)**, oblique sagittal plane (dehiscence measure was 5.2 mm) (arrowed), **(b)** and oblique coronal plane (arrowed) **(c)**

**Table 1.** Summary of CT findings of SSCD of the 8 positive cases.

Case	Sex	Age	Dehiscence side	Size of dehiscence in oblique coronal plane (mm)
1	M	32	left	5.2
2	M	37	left	3.3
3	M	42	right	4.5
4	F	45	left	4.9
5	M	45	right	4.4
6	F	48	left	3.7
7	M	50	right	4.0
8	M	53	left	3.1
			left	2.1



**Figure 6.** Male patient, 45 years old, complaining of vertigo induced by valsalva (case 5 in table 1). CT temporal bones revealed: Bilateral SSCD which was detected in 5 mm interval coronal images **(a)** right side dehiscence (arrowed) and **(b)** left side dehiscence (arrowed). SSCD was also detected in oblique coronal planes on the right side (arrowed) **(c)** and it measured 4.4 mm and on the left side (arrowed) **(d)** and it measured 3.7 mm. The dehiscence is also shown bilaterally in the oblique sagittal plane (arrowed) **(e)** right side and **(f)** left side.

## Discussion

Superior semicircular canal dehiscence (SSCD) is a condition caused by the absence of bone over one or

both of the superior semicircular canals that leads to dysfunction of the vestibular end organ as a result of altered fluid flow mechanics <sup>[11]</sup>.

Superior semicircular canal dehiscence can result in a characteristic constellation of vestibular and auditory features, including autophony, oscillopsia, vertigo (Tullio phenomenon), and characteristic eye movements induced by sound and pressure changes. Patients with superior semicircular canal dehiscence also show lowered thresholds for vestibular-evoked myogenic potentials and can have conductive hearing loss and often show an air-bone gap at the low frequency on pure-tone audiometry testing <sup>[12]</sup>.

The results of our study showed that 8 patients out of 28 clinically suspected cases were positive for SSCD with total 9 dehiscences; positive cases were 5 males and 3 females, their ages ranged from 32 to 60 years and the mean age was 44 years. Ferreira and De Lima <sup>[13]</sup> stated that gender did not prove to be of statistical significance in none of the previous studies, and the age median of symptomatic patients was around 40 years for Minor <sup>[5]</sup>.

Five positive cases were left sided (62.5%), 2 cases (25%) were right sided whereas 1 case (12.5%) was bilaterally dehiscent. All dehiscences were detected at the apex of bony covering of SSC, bony dehiscence size ranged from 2.1 mm to 5.2 mm with a mean of 3.9 mm.

In a meta-analysis by Watters et al. (8), 53% of patients with SSCD who needed surgery had the condition on the left, 23% on the right, and 23% were bilateral.

Our study showed that the standard coronal temporal images at 1.0 mm interval were not efficient in detecting SSCD in 7 out of 8 positive patients detected later after reconstructing the coronal images at 0.5 mm interval, whereas, canal dehiscence was poorly visualized in the former in the remaining patient, thus, coronal views with 0.5 mm interval improved visualization of the dehiscence. Belden et al. <sup>[6]</sup> declared that conventional temporal bone CT scans that are performed with 1.0 mm collimation with images displayed in the axial and coronal planes have relatively low specificity in the identification of superior canal dehiscence, specificity is improved when 0.5 mm collimated helical CT scans are performed with reformation of the images in the plane of the superior canal. Zhang et al. <sup>[14]</sup> studied the clinical application of multi-planar reformation for the diagnosis of superior semicircular canal dehiscence syndrome. He concluded that the multi-planar reformation image is more useful in diagnosis of

superior semicircular canal dehiscence syndrome than that of the routine axial and coronal images.

In all positively dehiscent patients in our study (8 patients with total 9 dehiscences), SSCD was evident at both the oblique sagittal and oblique coronal views. In our study, auxiliary oblique views added to confirm the diagnosis the oblique coronal images aided to measure the dehiscence size. The study done by Branstetter et al. <sup>[10]</sup> supported the hypothesis that coronal reformatted images based on submillimeter helical CT acquisition data are sufficient for the radiologic evaluation of SSCD and that additional oblique reformatted images may be reserved for difficult or equivocal cases. However, this study didn't measure the size of dehiscence using any of the coronal or oblique CT temporal planes.

A study done by Pfammatter et al. <sup>[15]</sup> resulted that patients with large dehiscences have significantly increased vestibulo-cochlear symptoms and lower than normal VEMP thresholds. In our study, we didn't correlate the clinical presentations of our positive cases to the size of SSCD detected in CT examinations because we were not provided with the investigatory work up.

In conclusion, good clinical assessment is mandatory for raising the suspicion of SSCD in patients suffering from chronic dizziness, consequent imaging using thin section multidetector row CT scan with 0.5mm image interval and auxiliary oblique reformatted planes are required for confirming the diagnosis.

## References

- 1- Curtin HD. superior semicircular canal dehiscence syndrome and multi-detector row CT. Radiology. 2003; 226:312-314.
- 2- Minor LB, Solomon D, Zinreich JS, Zee DS. Sound and/or pressure-induced vertigo due to bone dehiscence of the superior semicircular canal. Arch Otolaryngol Head Neck Surg. 1998; 124:249-258.
- 3- Rosowski J, Songer J, Nakajima H, Brinsko KM, Merchant SN. Investigations of the effect of superior semicircular canal dehiscence on hearing mechanisms. Otol Neurotol. 2004; 25:323-332.
- 4- Watson SR, Halmagyi GM, Colebatch JG. Vestibular hypersensitivity to sound (Tullio phenomenon): Structural and functional assessment. Neurology. 2000; 54:722-728.

- 5- Minor LB. Clinical manifestations of superior semicircular canal dehiscence. *Laryngoscope*. 2005; 115:1717-1727.
- 6- Belden CJ, Weg N, Minor LB, Zinreich SJ. CT evaluation of bone dehiscence of the superior semicircular canal as a cause of sound and/or pressure-induced vertigo. *Radiology*. 2003; 226:337-343.
- 7- Halmagyi GM, Aw ST, McGarvie LA, Bradshaw A, Yavor RA, Fagan PA. Superior semicircular canal dehiscence simulating otosclerosis. *J Laryngol Otol*. 2003; 117:553-557.
- 8- Watters KF, Rosowski JJ, Sauter T, Lee DJ. Superior semicircular canal dehiscence presenting as postpartum vertigo. *Otol Neurotol*. 2006; 27:756-768.
- 9- Brantberg K, Bergenius J, Mendel L, Witt H, Tribukait A, Ygge J. Symptoms, findings and treatment in patients with dehiscence of the superior semicircular canal. *Acta Otolaryngol*. 2001; 121:68-75.
- 10- Branstetter BF, Harrigal C, Escott EJ, Witt H, Tribukait A, Ygge J.. Superior Semicircular Canal Dehiscence: Oblique Reformatted CT Images for Diagnosis. *Radiology*. 2006; 238:938-942.
- 11- Hillman TA, Kertesz TR, Hadley K, Shelton C. Reversible Peripheral Vestibulopathy: The treatment of superior canal dehiscence. *Otolaryngology–Head and Neck Surgery*. 2006; 134:431-436.
- 12- Yuen HW, Boeddinghaus R, Eikelboom RH, Atlas MD. The relationship between the air-bone gap and the size of superior semicircular canal dehiscence. *Otolaryngology–Head and Neck Surgery*. 2009; 141:689-694.
- 13- Ferreira SC, De Lima MM. Superior canal Dehiscence Syndrome. *Rev Bras Otorrinolaringol*. 2006; 72:414-8.
- 14- Zhang LC, Hong RJ, Dai CF, Chi FL, Sha Y. CT multiplanar reconstruction images of superior semicircular canal dehiscence syndrome. *Zhonghua Er Bi Yan Hou Tou Jing Wai Ke Za Zhi*. 2009; 44:736-8.
- 15- Pfammatter A, Darrouzet V, Gärtner M, Somers T, Van Dinther J, Trabalzini F, et al. A superior semicircular canal dehiscence syndrome multicenter study: is there an association between size and symptoms? *Otol Neurotol*. 2010; 31: 447-454.