

## ORIGINAL ARTICLE

### Bacterial Role for Post-Irradiation Otitis Media with Effusion in Nasopharyngeal Carcinoma

Huang-Pin Lin, Po-Wen Cheng, Chien-Han Tsao, Mao-Chang Su, Chung-Han Hsin

Department of Otolaryngology, Chung Shan Medical University Hospital, Taichung, Taiwan (HPL, CHT, MCS, CHH)

Department of Otolaryngology, Far Eastern Memorial Hospital, Taipei, Taiwan (PWV)

Department of Nursing, Oriental Institute of Technology, Taipei, Taiwan (PWC)

School of Medicine, Chung Shan Medical University, Taichung, Taiwan (CHT, MCS, CHH)

The author contributed equally to this work (HPL, PWC)

**Objective:** To examine the role of bacteria in the development of otitis media with effusion (OME) in nasopharyngeal carcinoma (NPC) patients following radiotherapy.

**Materials and Methods:** The study is comprised of a single cohort of NPC patients between January 2002 and December 2007. When an OME was diagnosed at follow-up, a tympanocentesis was performed to collect middle ear effusions for culture.

**Results:** Eighty eight NPC patients with a mean age of 45.8 years were enrolled in the study. Overall, 25 (28%) of these patients had OME and 22 underwent tympanocentesis and had documentation of ear effusion culture. Of the 22 samples, 8 had growth of one organism. Of these culture-positive ear effusions, 5 had growth of *Staphylococcus aureus* and 3 had coagulase-negative *Staphylococcus*.

**Conclusions:** Bacteria infections, which most likely ascend from the nasopharynx, may be implicated in the pathogenesis of post-irradiation OME in some NPC patients.

Submitted : 06 December 2010

Accepted : 22 March 2011

## Introduction

Nasopharyngeal carcinoma (NPC) is a common cancer in ethnic Chinese populations, and radiation therapy is by far the most effective modality of treatment.<sup>[1,2]</sup> Traditionally, external beam irradiation is delivered via two-dimensional radiotherapy to the nasopharynx and neck. The radiation, however, frequently damages adjacent tissues from the skull base to the neck, and leads to various adverse effects.<sup>[3]</sup> Frequent otologic complications include otitis media, sensorineural hearing loss, vestibular deficits, and temporal bone osteoradionecrosis.<sup>[4,7]</sup> Among them, post-irradiation otitis media with effusion (OME) is the most common middle ear complication, and its development is believed to attribute to eustachian tube dysfunction caused by tumor destruction and/or radiation insults.<sup>[4,8]</sup>

To decrease radiation dose in the adjacent tissues and reduce occurrence of adverse effects, modern planning schemes, such as intensity-modulated radiotherapy

(IMRT), have been introduced since 1990s.<sup>[9]</sup> Although studies demonstrated NPC patients treated by IMRT had fewer therapeutic side effects compared with those treated by conventional radiotherapy or three-dimensional conformal radiotherapy,<sup>[10,11]</sup> our clinical observation showed that the occurrence of post-irradiation OME can not be reduced by the use of IMRT. The finding suggests that the etiology and pathogenesis of OME in NPC patients following radiotherapy are still not fully understood. Since the occurrence of OME can also be enhanced by inflammatory reactions of the nasopharynx and paranasal sinuses both in individuals with or without radiotherapy,<sup>[4,12]</sup> ascending infection of bacteria may be implicated in the pathogenesis of OME in irradiated NPC patients. The literature, however, lacks data on the microbiology of post-irradiation OME in NPC patients. Therefore, the purpose of this study was to examine the role of bacteria in the development of OME in NPC patients following radiotherapy.

#### Corresponding address:

Chung-Han Hsin

Department of Otolaryngology, Chung Shan Medical University Hospital, and School of Medicine, Chung Shan Medical University

No.110, Sec.1, Chien-Kuo N. Road, Taichung, 402, Taiwan

Phone: + 886-4-24739595 ext 34812 • Fax: + 886-4-23248185

E-mail: hsin@csmu.edu.tw

Copyright 2005 © The Mediterranean Society of Otolaryngology and Audiology

## **Materials and Methods**

### *Patients*

A single cohort of consecutive NPC patients who had biopsy-proved disease and underwent radiotherapy at the Chung Shan Medical University Hospital between January 2002 and December 2007 was enrolled in the study. Patients who did not complete the full course of radiotherapy and who showed evidence of local recurrence at follow-up were excluded from the study. OME occurred in the first year after treatment was considered early effect of radiotherapy and was not included in the analysis. In addition, patients who had acute upper respiratory infections at the time of tympanocentesis were also excluded from the study. Institutional Review Board approval was obtained for a retrospective review of each patient's clinical chart with the extraction of demographic, clinical, and microbiological data.

### *External beam radiotherapy*

The IMRT was delivered to these patients via seven fixed-gantry angles with a linear accelerator. Plans of IMRT were prepared using the Helio inverse planning system. Gross target volume (GTV), clinical target volume (CTV), and planning target volume (PTV) were defined according to the International Commission on Radiation Units and Measurements, ICRU report 62 (Cox 1995), and were measured for each patient. The goal of radiotherapy was to deliver a minimum dose of 70 Gy to the GTV and 55–60 Gy to the CTV, with the respective fraction sizes of 2.12 and 1.7–1.8 Gy.

### *Collection of middle ear fluid*

All patients underwent otoscopic examinations before radiotherapy and at scheduled follow-up after radiotherapy. If otoscopic examination revealed any abnormalities of the middle ear, a conventional audiometry and tympanometry were conducted. Once an OME was diagnosed, tympanocentesis was performed to relieve symptoms and to collect the middle ear effusions for culture. Briefly, the external auditory canal was cleared of cerumen and disinfected with povidone-iodine solution. Under microscopic guide, the tympanic membrane was tapped with a sterile needle attached to a 1.0-ml syringe and the effusion was aspirated. Collected middle ear samples were immediately streaked on a culture and transport

system (Copan Italia, Brescia, Italy), and the specimen was delivered to the microbiology laboratory for aerobic and anaerobic bacteria within 10 minutes of collection.

The culture samplings were performed with the patients off antibiotics for at least 2 weeks. Only one culture was accepted for each patient, although some patients had multiple aspirations over the time period.

### *Laboratory methods*

In the microbiology laboratory, aerobic specimens were plated on blood agar plate, eosin methylene blue agar, and chocolate agar, cultured for 24 hours at 35°C in an incubator containing 5% CO<sub>2</sub>. Anaerobic cultivation was performed using a BAP agar and incubated anaerobically (10% CO<sub>2</sub> + 5%H<sub>2</sub> + 85%N<sub>2</sub>). The plates were examined for growth of bacterial colonies at 48 hours of incubation. Organisms that grew on culture were identified by standard techniques and reported semi-quantitatively as follows: growth at initial inoculum, first quadrant, “rare”; growth in the first and second quadrants, “light”; growth into third quadrant, “moderate”; and growth into fourth quadrant, “heavy”. Cultures that were devoid of bacterial growth after 48 hours were classified as negative. Because coagulase-negative *Staphylococcus* normally reside in the external ear and are nonpathogenic, recoveries of the organism were considered contamination and the cultures were classified as negative.<sup>[13]</sup>

## **Results**

Between January 2002 and December 2007, 88 NPC patients (69 males and 19 females) with a mean age of 45.8 years (range, 19 to 78 years) were included in the study. According to the American Joint Committee on Cancer (AJCC) staging system, 20 patients (23%) were in T1, 42 patients (48%) in T2, 12 patients (14%) in T3, and 14 patients (16%) in T4 lesions. All patients received otoscopic examinations for assessment of middle ear complications at the scheduled follow-up. Overall, 25 (28%) patients had OME and 7 (8%) had perforated tympanic membrane. The remaining patients were free of middle ear abnormalities. Among the 25 patients who had unilateral or bilateral OME, 22 underwent tympanocentesis and had documentation of ear effusion culture. The demographic, clinical, and culture results for these patients were shown in Table 1.

**Table 1.** Demographic And Culture Results

Patient No.	Age (year)	Sex	T staging	Postirradiation (year)	Laterality of OME	Organism recovered from middle ear
1	43	F	T2	2	Right	Staphylococcus aureus (light)
2	56	F	T2	2	Bilateral	( - )
3	48	M	T2	6	Right	Coagulase-negative Staphylococcus (rare)
4	39	F	T2	2	Bilateral	Staphylococcus aureus (rare)
5	55	M	T4	1	Right	( - )
6	57	M	T2	2	Left	( - )
7	58	M	T2	5	Right	Staphylococcus aureus (rare)
8	26	F	T2	1	Right	( - )
9	55	M	T2	2	Left	( - )
10	39	M	T3	1	Bilateral	( - )
11	43	M	T2	5	Left	Staphylococcus aureus (light)
12	47	F	T2	1	Bilateral	Coagulase-negative Staphylococcus (rare)
13	36	M	T1	5	Left	( - )
14	41	M	T2	3	Left	( - )
15	40	F	T1	3	Bilateral	( - )
16	43	M	T2	6	Left	Staphylococcus aureus (rare)
17	61	M	T2	5	Left	( - )
18	59	M	T1	7	Left	( - )
19	45	M	T4	1	Right	Coagulase-negative Staphylococcus (rare)
20	40	M	T4	1	Left	( - )
21	53	M	T2	3	Bilateral	( - )
22	30	F	T1	7	Left	( - )

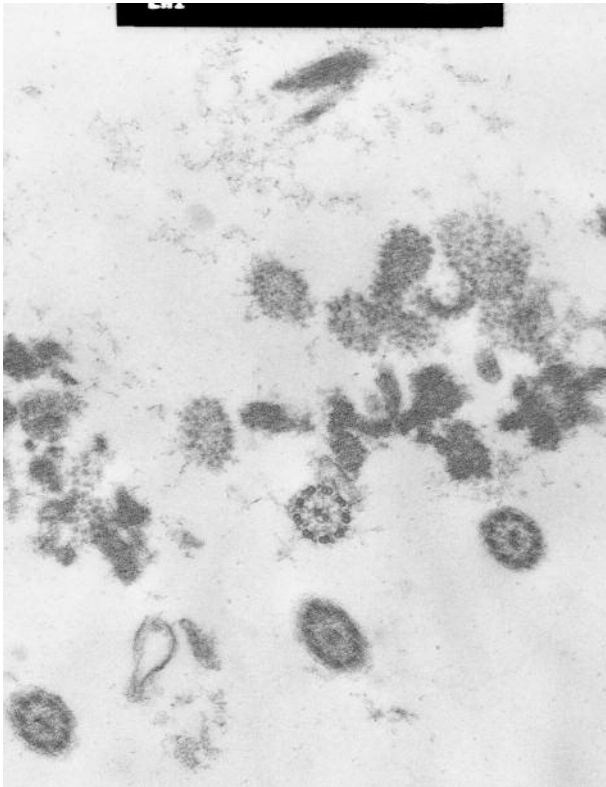
F = female; M = male; ( - ) = no growth of aerobic and anaerobic bacteria

Of the 22 samples, 8 had growth of one organism while 14 did not show any growth. Of the 8 culture-positive ear effusions, 5 had growth of *Staphylococcus aureus* and 3 had coagulase-negative *Staphylococcus*. Other organisms commonly isolated from the OME in normal individuals, such as *Haemophilus influenzae* and *Streptococcus pneumoniae*, were not identified in this analysis. Since recoveries of coagulase-negative *Staphylococcus* were considered contamination, the culture rate of potential pathogens was 23% (5/22).

## Discussion

Otitis media with effusion is one of the most common otologic complications in irradiated NPC patients, with an occurrence rate in the range of 9% to 26%.<sup>[14,15]</sup> The current study demonstrated that 28% of NPC patients treated by IMRT developed recurrent OME, confirming previous observation that the occurrence of post-irradiation OME can not be further reduced by the use of IMRT. In general, the pathogenesis of post-irradiation OME in NPC patients is considered to be an

impaired eustachian tube function due to tumor destruction prior treatment and/or radiation insults of the tube.<sup>4,8</sup> Young et al. also found that tubal patency and clearance function of the eustachian tube deteriorated if irradiation dosage increased.<sup>[16]</sup> To decrease dosage of the radiation in the adjoining structures and reduce adverse effects of radiotherapy, three-dimensional planning schemes have been utilized more than one decade.<sup>[9]</sup> Reduction of irradiation in the temporal bone by modern radiotherapy techniques was evidenced by the electromicroscopic findings of the middle ear mucosa (Fig. 1), as well as clinical studies which demonstrated NPC patients treated by IMRT had lower opportunities developing common otologic complications.<sup>[10,11]</sup> Our study, however, failed to show a decreased incidence of OME in NPC patients treated by IMRT, suggesting that factors other than eustachian tube dysfunction might also be involved in the development of post-irradiation OME.



**Figure 1.** Electromicroscopic study of the middle ear mucosa in an NPC patient treated by intensity-modulated radiotherapy 3 years ago. Cross section of the cilia reveals a highly ordered configuration of 9 peripheral microtubules surrounding a central microtubular doublet. Note absence of delayed irradiation effects on the epithelium, including compound cilia and supernumerary single microtubules. Bar –200 nm.

The literature lacks analysis on the microbiology of post-irradiation OME in NPC patients, except one study described limited data on one dozen of effusion ears.<sup>[16]</sup> To the best of our knowledge, the current study is the only study designed to examine the bacteriological profile of post-irradiation OME in NPC patients. Moreover, our analysis examined the issue in patients treated by IMRT, a therapeutic modality supposedly delivering less radiation to the middle ear. Our data revealed that more than 75% of the samples obtained from post-irradiation OME in NPC patients were sterile, suggesting that impaired eustachian tube indeed is the main mechanism underlying genesis of post-irradiation OME. There were, however, roughly one quarter of middle ear specimens had isolation of potential pathogens. Since rhinosinusitis and

nasopharyngitis are common adverse effects in irradiated NPC patients,<sup>[17,18]</sup> ascending infections of the bacteria from the sinonasal mucosa to the middle ear can be the scenario for development of post-irradiation OME in these patients.

Our data also revealed that all of the pathogens isolated from post-irradiation OME are *Staphylococcus aureus*, indicating this organism is the major bacteria involved in the ascending infection in irradiated NPC patients. This finding is also consistent with results of previous studies which demonstrated *Staphylococcus aureus* is among the most common organism responsible for rhinosinusitis in irradiated NPC patients.<sup>[19,20]</sup>

Because post-irradiation OME can cause hearing impairment, aural fullness, tinnitus, and even dizziness, the problem should be handled to improve the quality of life in NPC survivors. Controversy, however, exists as to whether to perform insertion of ventilating tube or to adopt repeated tympanocentesis. Xu et al. recently compared 3 methods of treatment and suggested a step-wise approach for the management of NPC patients with post-irradiation OME.<sup>[21]</sup> However, since both previous and our studies demonstrated that ascending infections may cause or exacerbate post-irradiation OME, a simultaneous control of sinonasal inflammations is also essential in addition to draining and ventilating the middle ear cavity. In general, adequate antimicrobial therapy and daily nasal irrigation with saline are both beneficial in the managements of sinonasal inflammations following radiotherapy.<sup>[18]</sup>

Limitation to the current study was the low growth density of ear effusion cultures. It may represent recovery of commenal flora in the middle ear instead of identification of organisms responsible for post-irradiation OME. A recent study using modern microbiological techniques, however, revealed that the middle ear cavity is a normally sterile site,<sup>[22]</sup> suggesting that any bacterial growth out of middle ear effusions is noteworthy in the pathogenesis of ear inflammations.

## **Conclusion**

Although dysfunctions of the eustachian tube play a major role in the development of post-irradiation OME in NPC patients, bacterial infections, probably



ascending from the sinonasal mucosa, may also be implicated in the pathogenesis. Therefore, an adequate treatment of the post-irradiation rhinosinusitis is important in the management of OME in NPC patients following radiotherapy.

### **Acknowledgement**

Our sincere thanks to Prof. Ko-Kaung Liao for assisting the electromicroscopic study.

### **References**

1. Huang SC, Lui LT, Lynn TC. Nasopharyngeal cancer: study III. A review of 1206 patients treated with combined modalities. *Int J Radiat Oncol Biol Phys* 1985; 11:1789-93.
2. Chan AT, Teo PM, Huang DP. Pathogenesis and treatment of nasopharyngeal carcinoma. *Semin Oncol* 2004;31:794-801.
3. Talmi YP, Horowitz Z, Bedrin L, Wolf M, Chaushu G, Kronenberg J et al. Quality of life of nasopharyngeal carcinoma patients. *Cancer* 2002; 94:1012-7.
4. Young YH, Lin KL, Ko JY. Otitis media with effusion in patients with nasopharyngeal carcinoma, post-irradiation. *Arch Otolaryngol Head Neck Surg* 1995; 212:765-8.
5. Kwong DL, Wei WI, Sham JS, Ho WK, Yuen PW, Chua DT et al. Sensorineural hearing loss in patients treated for nasopharyngeal carcinoma: a prospective study of the effect of radiation and cisplatin treatment. *Int J Radiat Oncol Biol Phys* 1996; 36:281-9.
6. Gabriele P, Orecchia R, Magnano M, Albera R, Sannazzari GL. Vestibular apparatus disorders after external radiation therapy for head and neck cancers. *Radiother Oncol* 1992; 25:25-30.
7. Chen PR, Hsu LP, Tu CE, Young YH. Radiation-induced oscillopsia in nasopharyngeal carcinoma patients. *Int J Radiat Oncol Biol Phys* 2005; 61:466-70.
8. Low WK, Fong KW. Long-term post-irradiation middle ear effusion in nasopharyngeal carcinoma. *Auris Nasus Larynx* 1998; 25:319-21.
9. Teo PM, Ma BB, Chan AT. Radiotherapy for nasopharyngeal carcinoma--transition from two-dimensional to three-dimensional methods. *Radiother Oncol* 2004; 73:163-72.
10. Wolden SL, Chen WC, Pfister DG, Kraus DH, Berry SL, Zelefsky MJ. Intensity-modulated radiation therapy (IMRT) for nasopharynx cancer: update of the Memorial Sloan-Kettering experience. *Int J Radiat Oncol Biol Phys* 2006; 64:57-62.
11. Fang FM, Chien CY, Tsai WL, Chen HC, Hsu HC, Lui CC et al. Quality of life and survival outcome for patients with nasopharyngeal carcinoma receiving three-dimensional conformal radiotherapy vs. intensity-modulated radiotherapy-a longitudinal study. *Int J Radiat Oncol Biol Phys* 2008; 72:356-64.
12. Otten FW, Grote JJ. Otitis media with effusion and chronic upper respiratory tract infection in children: a randomized, placebo-controlled clinical study. *Laryngoscope* 1990; 100:627-33.
13. Dibb WL. The normal microbial flora of the outer ear canal in healthy Norwegian individuals. *NIPH Ann* 1990; 13:11-6.
14. Chao WY, Wang CF, Chang SJ. Ventilation tube in adults with middle-ear effusion. *J Otolaryngol* 1999; 28:278-81.
15. Young YH, Lu YC. Mechanism of hearing loss in irradiated ears: a long-term longitudinal study. *Ann Otol Rhinol Laryngol* 2001; 110:904-6.
16. Young YH, Sheen TS. Preservation of tubal function in patients with nasopharyngeal carcinoma, post-irradiation. *Acta Otolaryngol* 1998; 118:280-3.
17. Zubizarreta PA, D'Antonio G, Raslawski E, Gallo G, Preciado MV, Casak SJ et al. Nasopharyngeal carcinoma in childhood and adolescence: a single-institution experience with combined therapy. *Cancer* 2000; 89:690-5.
18. Liang KL, Kao TC, Lin JC, Tseng HC, Su MC, Hsin CH et al. Nasal irrigation reduces postirradiation rhinosinusitis in patients with nasopharyngeal carcinoma. *Am J Rhinol* 2008; 22:258-62.
19. Hsin CH, Tsao CH, Su MC, Chou MC, Liu CM. Bacteriology of acute rhinosinusitis in nasopharyngeal carcinoma survivors: a result of maxillary sinus punctures. *Eur Arch Otorhinolaryngol* 2007; 264:1157-62.

20. Deng ZY, Tang AZ. Bacteriology of postradiotherapy chronic rhinosinusitis in nasopharyngeal carcinoma patients and chronic rhinosinusitis. *Eur Arch Otorhinolaryngol* 2009; 266:1403-7.
21. Xu YD, Ou YK, Zheng YQ, Chen Y, Ji SF. The treatment for postirradiation otitis media with effusion: a study of three methods. *Laryngoscope* 2008; 118:2040-3.
22. Westerberg BD, Kozak FK, Thomas EE, Blondel-Hill E, Brunstein JD, Patrick DM. Is the healthy middle ear a normally sterile site? *Otol Neurotol* 2009; 30:174-7.