

CASE REPORT

Acute Bilateral Sensorineural Hearing Loss Following Mycoplasmal Pneumonia

Taisuke Kobayashi, Kiyofumi Gyo, Masahiro Okada, Yuichi Tomidokoro

Department of Otolaryngology, Kochi Medical School, Nankoku, Kochi, Japan (TK)

Department of Otolaryngology, Ehime University School of Medicine, To-on, Ehime, Japan (KG, MO, YT)

A case of acute bilateral hearing loss that occurred as a complication of *Mycoplasma pneumoniae* infection is reported. A 22-year-old man developed bilateral acute otitis media following mycoplasmal pneumonia. Since his hearing loss did not recover with conventional treatment, he was referred to our clinic. The tympanic membrane looked normal. Pure tone audiometry showed bilateral low-tone sensorineural hearing loss: 40.0 dB in the right ear and 45.0 dB in the left ear. Despite intravenous administration of prednisolone, his hearing did not recover. *M. pneumoniae* might be considered a causative agent of acute sensorineural hearing loss when it occurs during or after mycoplasmal pneumonia. This is more likely when the audiogram shows low tone loss type hearing loss, or when both ears are involved. Since mycoplasmal infection does not always manifest with pathognomonic signs or symptoms, it is sometimes misdiagnosed as a common cold. Sensorineural hearing loss as a complication of mycoplasmal infection may be more common than was previously thought.

Submitted : 17 May 2011

Accepted : 18 January 2011

Introduction

Mycoplasma pneumoniae is a causative bacterium of primary atypical pneumonia or mycoplasmal pneumonia. Recently, it has been reported to cause acute sensorineural hearing loss (ASHL), though its incidence is rare. Since the first report by Van Dishoeck ^[1] in 1963, evidence indicating that *M. pneumoniae* infection can be a cause of acute sensorineural hearing loss (ASHL) has been presented in the literature. In 1973, Maassab ^[2] isolated *M. pneumoniae* from nasopharyngeal swabs in 7 of 47 patients with ASHL. Garcia Berrocal et al. ^[3] showed elevated IgM antibody titers in 2 of 24 patients with ASHL. At present, the pathophysiological mechanisms of cochlear involvement by *M. pneumoniae* remain unclear.

This paper reports a case of acute bilateral low-tone sensorineural hearing loss that occurred as a

complication of mycoplasmal pneumonia. In addition, the pathogenesis, clinical features, and treatment of this disease are discussed by reviewing the cases of 12 patients (involving 17 ears) reported in the literature.

Case report

A 22-year-old man attended a local otolaryngologist complaining of bilateral ear fullness in February 2007 during a trip. With a diagnosis of secretory otitis media, myringotomy was performed for his left ear. Since he had suffered from persistent cough, he was referred to a physician who diagnosed mycoplasmal pneumonia. Thus, he was admitted to a local hospital and was treated with antibiotics. At the time of admission, he complained of bilateral hearing loss and dizziness. Myringotomy was performed bilaterally for removal of middle ear effusion. The dizzy sensation soon disappeared, but bilateral hearing impairments remained, even after complete recovery from the

Corresponding address:

Taisuke Kobayashi

Department of Otolaryngology, Kochi Medical School, Nankoku, Kochi, 783-8505, Japan

Phone: +81-88-880-2393, Fax: +81-88-880-2395

E-mail: tkobayashi@kochi-u.ac.jp

Copyright 2005 © The Mediterranean Society of Otolaryngology and Audiology

mycoplasmal pneumonia. He was referred to our clinic two months later because of bilateral sensorineural hearing loss.

Otolaryngological examination revealed normal tympanic membranes in both ears. Air conduction hearing was 40.0 dB in the right ear and 45.0 dB in the left for the average of 3 frequencies (0.5, 1, and 2 kHz) with no air-bone gap, indicating bilateral low-tone sensorineural hearing loss (Figure 1). Distortion product otoacoustic emission was evoked except in the middle frequencies for both ears (Figure 2). The speech reception threshold was 37 dB in the right ear and 33 dB in the left ear. The speech discrimination score was 90% in the right ear and 80% in the left ear. The short increment sensitivity index (SISI) was 30% in the right ear and 50% in the left ear at 1000 Hz. Spontaneous or positional nystagmus was not observed. Computed tomography (CT) of the temporal bone revealed slightly hypertrophic mucosa of the mastoid air cells. Magnetic resonance imaging (MRI) showed no abnormalities in the cerebellopontine angle or the internal auditory canal.

The patient was treated by intravenous prednisolone (starting at 60 mg/day, and then tapered), but his

hearing did not show substantial improvement. Air conduction hearing on July 27 was 35.0 dB in the right ear and 40.0 dB in the left ear (Figure 1). He began to wear canal-type hearing aids bilaterally..

Discussion

M. pneumoniae is an extremely small bacterium that lacks a peptidoglycan cell wall; instead, it has a cell membrane incorporating sterol compounds. Therefore, it is resistant to penicillins and other beta-lactam antibiotics that act as bactericidal agents by disrupting the bacterial cell wall. *M. pneumoniae* spreads through respiratory droplet transmission and attaches to the upper and lower respiratory tract epithelium, inducing pharyngitis, bronchitis, and pneumonia. Mycoplasmal pneumonia usually occurs in children or young adults under the age of 30 years. The prognosis of the pneumonia is usually favorable, but it sometimes causes severe central nervous system complications, such as encephalitis, Guillain-Barré syndrome, and polyneuropathy. Other complications can be cardiovascular (myocarditis and pericarditis), hematological (hemolytic anemia and thrombocytopenia), and dermatological (Stevens-Johnson syndrome and erythema multiforme). In the

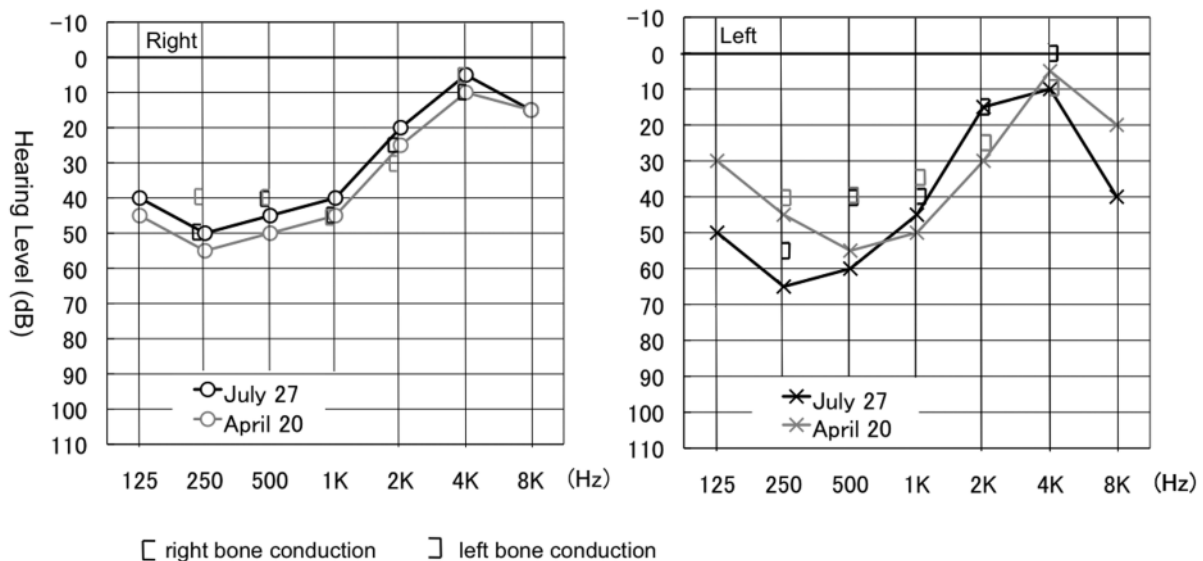


Figure 1. Audiogram at the initial visit (black line) and after treatment (gray line)

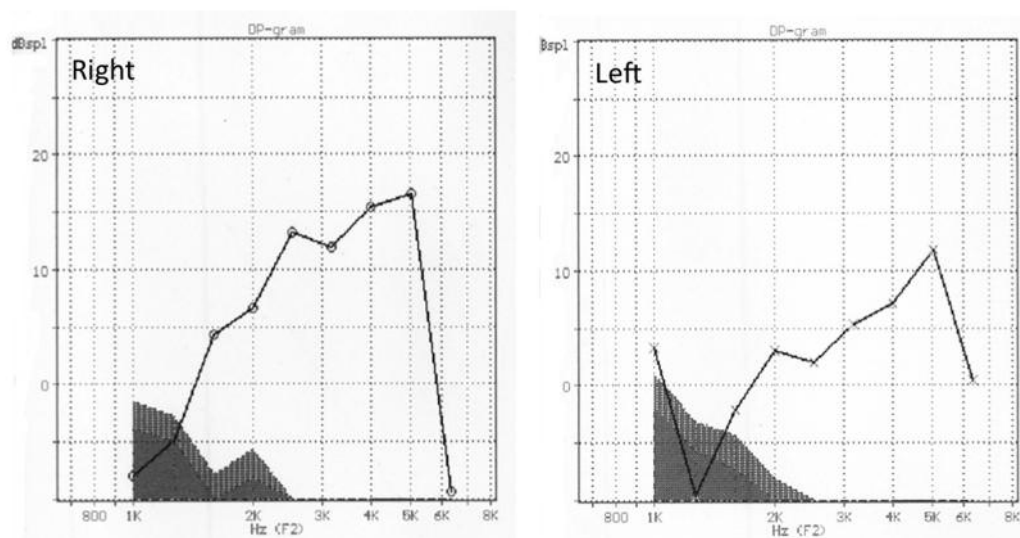


Figure 2. Distortion product otoacoustic emissions (DP-OAE) at the initial visit

otolaryngological field, myringitis and acute otitis media are known as major complications of mycoplasmal pneumonia.

Recently, the incidence of sensorineural hearing loss has been discussed as a complication of *M. pneumoniae* infection, because the bacterium can be a causative agent of idiopathic sudden sensorineural hearing loss (ISSHL). In 1963, Van Dishoeck ^[1] reported a patient with unilateral ISSHL after atypical pneumonia. In this case, hearing loss occurred without acute otitis media. In 1980, Feinmesser et al. ^[4] reported a case of bilateral acute otitis media with bullous myringitis that occurred following mycoplasmal pneumonia. The patient had mixed hearing loss in both ears. They speculated that the bacterium might enter the cochlea during the course of mycoplasmal otitis media and devastate the inner ear structures.

The pathogenesis of sensorineural hearing loss due to *M. pneumoniae* infection is still unclear. Since the incidence of acute otitis media is high in this disease, direct spread of *M. pneumoniae* through the round window is the most likely mechanism. Toxic agents and immunologic mediators might also spread into the cochlea through the same route. Since antibodies

against *M. pneumoniae* are highly cross-reactive, which has already been demonstrated for myocardial and brain tissue ^[5], they might also affect inner ear tissue, resulting in hearing impairment. According to the literature (Table 1), however, no one of 17 ears showed high-tone hearing loss, while other 6 ears showed low-tone hearing loss, indicating that the lesion should be located at the second and apical turns of the cochlea. The conjecture cannot explain why high-tone hearing loss is rare in this disease, since the bacteria or toxic agents must first enter the basal turn by this pathogenesis. Therefore, another possibility should be considered as a cause of sensorineural hearing loss. Nishioka et al. ^[6] suggested three other possible routes to explain how *M. pneumoniae* infection involves the inner ear: 1. spread of concomitant meningeal infection into the inner ear; 2. auditory nerve involvement as a symptom of polyneuritis; and 3. hematogenous spread. Trad et al. ^[7] reported a case of bilateral nuclear facial palsy following mycoplasmal pneumonia whose MRI showed T2-weighted hyperintense lesions in the pons. This might suggest that direct involvement of the auditory nerve is a possible cause of sensorineural hearing loss, though *M. pneumoniae* is rarely isolated from the cerebrospinal fluid.

Table 1. Reported 12 cases of acute sensorineural hearing loss (involving 17 ears) as a complication of mycoplasmal pneumonia

Author (Year)	Case No.	Age	Sex	Side loss	Type of hearing loss	Otitis media Audiogram	Type of (dB) b	Hearing Level Recruitment	Treatment	Hearing Outcomec
Van Dishoeck ^[1] (1963)	1	55	F	L	?	No	Flat?	more than 70	?	?
Feinmesser et al. ^[4] (1980)	2	22	F	Bil	Mixed	Yes	Flat	56.3 (R), 57.5 (L)	erythromycine, steroid	Slight improvement
Shanon et al. ^[8] (1982)	3	11	F	L	SN	Yes	Flat	93.3	doxycycline	Remarkable improvement
Matsuo T et al. ^[9] (1986)	4	31	F	L	SN	Yes	L	63	positive	Slight improvement
Nishioka et al. ^[6] (1987)	5	11	F	Bil	Mixed	Yes	L	33 (R), 31 (L)	?	No change
	6	7	F	Bil	Mixed	Yes	Flat	49 (R), 40 (L)	erythromycine, steroid, HO	No change
	7	33	M	Bil	Mixed	Yes	Flat	49 (R), 39 (L)	minocycline, steroid	Slight improvement
Okada et al. ^[10] (1996)	8	39	F	L	SN	?	L	17	negative	Complete recovery
	9	45	F	R	SN	?	Flat	73.3	?	Complete recovery
	10	34	F	R	SN	?	Flat	63.3	?	Remarkable improvement
	11	68	F	L	SN	Yes?	Flat	86.7	clarithromycin, steroid	Remarkable improvement
Present case	12	21	M	Bil	SN	Yes	L	37 (Bil)	steroid	No change

a: Type of audiogram was defined according to Sheehy Classification^[12].

b: Hearing level was defined as the average of five frequencies (0.25kHz, 0.5kHz, 1kHz, 2kHz and 4 kHz) of bone conduction thresholds.

c: Hearing outcome was established by Acute Profound Deafness Committee of Japanese Ministry of Welfare^[13].

Table 1 summarizes the clinical features of 17 ears in 12 patients who suffered from ASHL as a complication of mycoplasmal pneumonia reported in the English literature [1, 4, 6, 8, 9, 10]. The patients consisted of 2 males and 10 females, ranging in age from 7 to 68 years (mean, 31.4 years). The mean age was relatively low compared to that of ISSHL patients, with a peak at 50 to 54 years [11]. The affected side was the right side in 2 cases, the left in 5 cases, and bilateral in 5 cases. Note the fairly high incidence of bilateral involvement in this disease compared to that of ISSHL, in which bilateral involvement is very rare. The time interval between pneumonia and the onset of hearing loss varied from 0 (simultaneous onset) to 18 days. Otitis media was present in 13 of 17 ears, including 5 ears that had already healed at the initial visit to the otolaryngologist. Audiograms showed mixed hearing loss in 8 ears and sensorineural hearing loss in 8 ears. The audiogram was classified as flat loss type in 11 ears, low-tone loss type in 6 ears according to the Sheehy Classification [12]. The bone conduction thresholds varied, with the mean value of 48.9 dB for the average of 5 frequencies (0.25 kHz, 0.5 kHz, 1 kHz, 2 kHz, and 4 kHz), which was milder than in ISSHL [13]. Complications involving the vestibular system were considered infrequent. Vertigo or a dizzy sensation was noted in case 2 and case 12 (present case). Nystagmus was observed in case 3, who did not complain of vertigo or a dizzy sensation.

Treatment of ASHL caused by *M. pneumoniae* has not been established. In the literature, most cases were treated with steroids and/or antibiotics. According to the criteria proposed by the Acute Profound Deafness Committee of the Japanese Ministry of Welfare [13], complete recovery of hearing was noted in 2 ears (12.5%), marked improvement in 3 ears (18.8%), slight improvement in 5 ears (31.3%), and no change in 6 ears (39.8%). Only 5 of 17 ears (29.4%) showed significant recovery (complete or significant recovery), which rate was worse than spontaneous recovery rate of ISSHL. We believe that further studies will be necessary to clarify the pathological background of this rare disease and to develop better treatment.

Conclusion

When we see a patient with ASHL after mycoplasmal infection, which may present as a common cold, *M. pneumoniae* should be suspected as a possible causative agent. A history of otitis media, upper respiratory infection, pneumonia, or intractable cough before the onset of acute hearing loss may suggest this disease. Particularly when the audiogram shows a low-tone or flat loss type hearing loss, or both ears are involved, serum *M. pneumoniae* titers should be measured. Sensorineural hearing loss as a complication of mycoplasmal pneumonia may be more common than was previously thought.

References

1. Van Dishoeck HA. Viral infection in two cases of sudden perceptive deafness. *Acta Otolaryngol* (Stockh) 1963; Suppl 183: 30-33.
2. Maassab HF. The role of viruses in sudden deafness. *Adv. Oto-Rhino-Laryng* 1973; 20: 229-235.
3. Garcia Berrocal JR, Ramirez-Camacho R, Porteo F, Vargas JA. Role of viral and *Mycoplasma pneumoniae* infection in idiopathic sudden sensorineural hearing loss. *Acta Otolaryngol* 2000; 120: 835-839.
4. Feinmesser R, Weissel MJ, Levi H, Weiss S. Bullous myringitis: its relation to sensorineural hearing loss. *J. Laryngol. Otol.* 1980; 94: 643-7.
5. Antti Pönkä. Carditis associated with *Mycoplasma Pneumoniae* infection. *Acta Med Scand* 1979; 206: 77-86.
6. Nishioka K, Masuda Y, Okada S, Takata N, Tasaka S, Ogura Y. Bilateral sensorineural hearing loss associated with *Mycoplasma pneumoniae* infection. *Laryngoscope* 1987; 97: 1203-06.
7. Trad S, Ghosn J, Dormont D, Stankoff B, Bricaire F, Caumes E. Nuclear bilateral Bell's palsy and ageusia associated with *Mycoplasma Pneumoniae* pulmonary infection. *J Medical Microbiology* 2005; 54: 417-9.
8. Shanon E, Zikk D, Redianu C, Eylan, E. Sudden deafness due to infection by *Mycoplasma pneumoniae*. *Ann Otol* 1982; 91: 163-165.

9. Matsuo T, Sekitani T. Sudden hearing loss accompanied by mycoplasmal infection. *Bull Yamaguchi Med Sch* 1986; 33: 39-44.
10. Okada T, Kato I, Miho H, Minami S, Kinoshita H, Akao I, et al. Acute sensorineural hearing loss caused by *Mycoplasma pneumoniae*. *Acta Otolaryngol (Stockh)* 1996; Suppl 522: 22-25.
11. Nakashima T, Yanagita N, Ohno Y, Kanzaki J, Shitara T. Comparative study on sudden deafness by two nationwide epidemiological survey in Japan. *Acta Otolaryngol (Stockh)* 1994; Suppl 514: 14-16.
12. Sheery JL. Vasodilator therapy in sensory-neural hearing loss. *Laryngoscope* 1960; 70: 885-914.
13. Yanagita N, Nakashima T, Ohno Y, Kanzaki J, Shitara T. Estimated annual number of patients Treated for sensorineural hearing loss in Japan. *Acta Otolaryngol (Stockh)* 1994; Suppl 514: 9-13.