

## ORIGINAL ARTICLE

### Transmeatal Procurement of Allograft Tympano-Ossicular Systems: Preliminary Report (Alternative to the intracranial bone plug technique by Schuknecht)

Vincent van Rompaey, Joost van Dinther, Thomas Somers, Luc Vanhoof, Maggie Maes, Isabelle Schatteman, Erwin Offeciers

European Institute For Otorhinolaryngology - Head & Neck Surgery, Sint Augustinus Hospital, Antwerp (VR, JD, TS, LV, MM, IS, EO)

#### Abstract

When running an allograft tympano-ossicular systems tissue bank, compliance with national and European Union regulations on traceability, quality assurance and safety procedures to reduce the risk of transmitting disease is critical. The intracranial bone plug technique described by Schuknecht is an established approach to procure allograft tympano-ossicular systems. However, this technique entails separate removal of the allograft tympano-ossicular systems from the bone plug, the dura mater is encountered and it is esthetically invasive to the donor. The transmeatal technique is a feasible alternative, which is less time-consuming, avoids contact with the dura mater and is esthetically less invasive to the donor. The regulatory guidelines for graft procurement related to variant Creutzfeldt-Jakob's disease could be reconsidered when the transmeatal technique is used.

Submitted : 6 July 2011

Accepted : 19 September 2011

#### Introduction

The first successful clinical use of allogeneic tympano-ossicular systems for reconstruction of the middle ear in chronic otitis media was established by Jean Marquet in 1963.<sup>[1-4]</sup> Allograft tympano-ossicular systems (ATOS) were originally intended to restore the original anatomical and physiological situation of the middle ear, allowing extirpation of tissues affected by chronic otitis media with or without cholesteatoma. ATOS have demonstrated excellent biocompatibility, even in chronically infected environment. Its value was universally recognised and ATOS were widely used in the nineties.<sup>[5]</sup> However, concerns on safety regarding transmissible diseases, such as human immunodeficiency virus infection (HIV), limited its use. When the relationship between variant

Creutzfeldt-Jakob's disease (vCJD) and bovine spongiform encephalopathy (BSE) was elucidated, measures taken during the BSE endemy lead to the discontinuation of ATOS in many countries.<sup>[6]</sup> In our department, ATOS are still the preferred material for reconstruction of the tympanic membrane and ossicular chain. Meanwhile, new European Union (EU) regulations on tissues and cells endeavour quality assurance, traceability and safety procedures to reduce the risk of transmitting disease. Recently, Van Rompaey et al.<sup>[7]</sup> have demonstrated that running an ATOS tissue bank, complying with these EU regulations, is possible.

The intracranial bone plug technique (described by Schuknecht<sup>[8]</sup>) is an established approach to procure ATOS. However, this technique entails separate

#### Corresponding address:

Joost van Dinther  
European Institute For Otorhinolaryngology - Head & Neck Surgery  
Sint Augustinus Hospital  
Oosterveldlaan 24, 2610 Antwerp (Wilrijk)  
Phone: +32 3 443 36 04 • Fax: +32 3 443 36 11  
E-mail: joost.vandinther@gza.be

Copyright 2005 © The Mediterranean Society of Otolaryngology and Audiology

removal of the ATOS from the bone plug, the dura mater is encountered and it is esthetically invasive to the donor.

The goal of this preliminary report is to discuss the feasibility and surgical technique of the transmeatal approach in procuring ATOS.

## **Materials and Methods**

### *Tissue bank infrastructure*

The requirements of EU directives on tissues and cells, including traceability, quality assurance and safety procedures were rigorously applied to the activity, infrastructure, personnel, documentation and workflow protocols of the ATOS tissue bank. The workflow is similar to the one reported by Van Rompaey et al.<sup>[7]</sup> Transmeatal approach procurement was performed as an alternative to the intracranial bone plug procurement.

### *Surgical technique*

The procedure can be performed using a surgical microscope or binocular loupes (preferably 4x magnification) in a position similar to the operation room setup. Figure 1A-E demonstrates procurement, Figure 2A-C demonstrates the procured tympanic membrane and attached malleus, and the separately procured incus. All procedures were performed using a retroauricular flap incision to enable closure of the external auditory canal (EAC) after procurement (Figure 1A). The EAC skin is incised circumferentially with a scalpel or Berckmans decollator to define the bony canal. A Weitlaner self-retaining retractor is used to expose the EAC 360° (Figure 1B). The lateral (cartilaginous) part of the EAC is removed. The EAC cuff is incised 360° with a large Rosen knife at the start of the bone EAC. A tympanomeatal 360° cuff is produced in the subperiosteal plane. The EAC cuff is released circumferentially from the bony canal approaching the bony annulus by using a Marquet decollator or a small Rosen knife. The EAC cuff can be folded towards the tympanic membrane to improve visualisation. The fibrous annulus is raised out of the bony sulcus at the notch of Rivinus. Release the fibrous annulus carefully from the bony annulus with a microhook or Rosen knife (Figure 1C). The mucosa

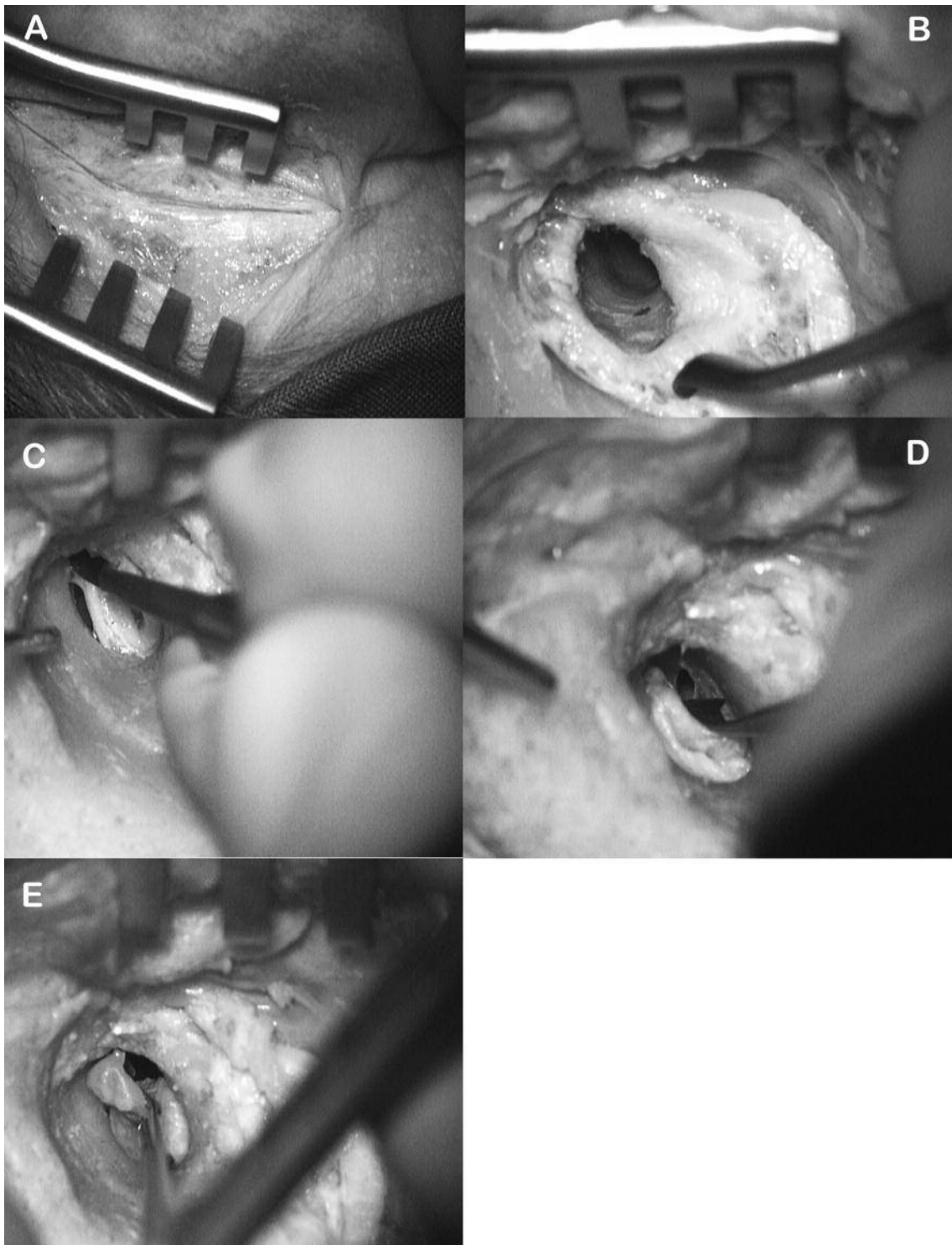can now be incised to reach the middle ear cavity. Avoid manipulating the tympanic membrane near the head of the malleus, which is still attached to all ligaments and muscles. From this point the incudostapedial joint can be cleaved and the incus can be procured. The fibrous annulus can be released from the bony annulus anterior to the lateral process of the malleus taking care to include the anterior malleal ligament (Figure 1D). The Marquet decollator can now be used to lift the fibrous annulus 360°. The tendon of the tensor tympani muscle is cut. The malleus head is released from mucosa and ligaments. Now the malleus neck can be mobilised with a bent or straight microforceps to remove and procure the entire tympano-malleal allograft (Figure 1E). Closure of the EAC is performed using non-absorbable sutures. The retroauricular incision is closed with subcutaneous and intracutaneous absorbable sutures.

The allograft is checked for integrity of the malleus, state of the tympanic membrane, EAC cuff characteristics and annulus integrity. If the procedure is performed as meticulously as during tympanoplasty in a live patient, graft quality is identical in the transmeatal and intracranial technique. It can be performed by a properly trained and accredited technician.

## **Results and Discussion**

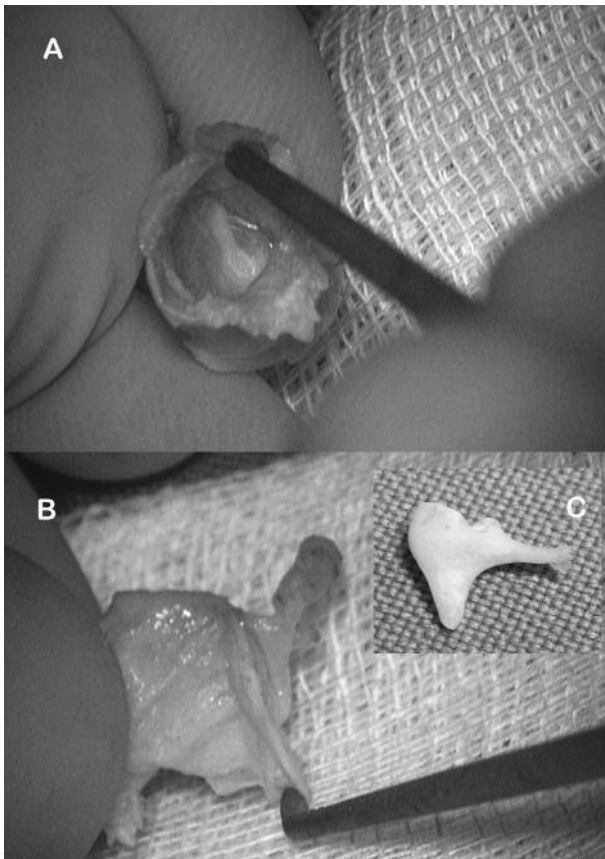
Recently, Van Rompaey et al.<sup>[7]</sup> have demonstrated that running an ATOS tissue bank, complying with national and EU regulations on traceability, quality assurance and safety procedures to reduce the risk of transmitting disease is possible. This report allows for the reintroduction of this valuable reconstructive technique in all EU countries.

The contraindications to ATOS procurement are quite extensive, with well-known examples such as malignancies, HIV, vCJD, etc. Nevertheless, the evidence for transmission of these diseases in ATOS is lacking and no cases have been reported in literature or observed in our department in nearly 50 years of use. It is to be acknowledged that vCJD is a clear contraindication, since it can be transmitted through dura mater, which is handled during the intracranial procurement technique.



**Figure 1.** Graft procurement.

**A**, a retroauricular skin incision is used. **B**, the external auditory canal skin is incised circumferentially with a scalpel or Berckmans decollator to define the bony canal. **C-D**, the external auditory canal cuff is released circumferentially from the bony canal approaching the bony annulus by using a Marquet decollator or a small Rosen knife. **E**, the malleus neck can be mobilised with a bent or straight microforceps to remove and procure the entire tympano-malleal allograft.



**Figure 2.** Procured tympanic membrane with attached malleus and separate incus. **A**, view to the lateral part of the tympanic membrane and manubrium mallei. **B**, sagittal view of the tympanic membrane, manubrium mallei, head and neck of the malleus. **C**, view on the procured incus.

By using the transmeatal approach for ATOS procurement, however, contact with the dura mater is avoided. Thus, the regulatory guidelines for graft procurement related to variant Creutzfeldt-Jakob's disease can be reconsidered when the transmeatal approach becomes the standard approach. Additionally, this technique combines procurement and processing in a single procedure, which is less time-consuming and it esthetically less invasive than the intracranial technique.

## Conclusion

Running an ATOS tissue bank, complying with national and EU regulations on traceability, quality

assurance and safety procedures to reduce the risk of transmitting disease is critical. The transmeatal procurement technique is a feasible alternative to the intracranial bone plug technique described by Schuknecht. Additionally, the transmeatal technique is less time-consuming, avoids contact with the dura mater and is esthetically less invasive to the donor. By avoiding contact with the dura mater, contraindication of vCJD can be reconsidered when the transmeatal approach becomes the standard approach.

## References

1. Marquet J. Reconstructive micro-surgery of the eardrum by means of a tympanic membrane homograft. Preliminary report. *Acta Otolaryngol.* 1966; 62:459-464.
2. Marquet J. Myringoplasty by eardrum transplantation. *Laryngoscope.* 1968; 78:1329-1336.
3. Marquet J. Reconstructive surgery of the middle ear by homografts. *Acta Otorhinolaryngol Belg.* 1970; 24:568-574.
4. Marquet J. Tympano-ossicular homografts in the surgical treatment of agenesis of the ear. Preliminary report. *Acta Otorhinolaryngol Belg.* 1971; 25:885-897.
5. Coulie PG, Ars B. The puzzling success of allograft tympanoplasty. Possible immunological explanations. *Acta Otorhinolaryngol Belg.* 1990; 44:3-5.
6. Janssens de Varebeke S, Goubau P, Beuselinck HK, Somers T, Offeciers FE, Govaerts PJ. Tympano-ossicular allografts and HIV transmission. *Am J Otol.* 1998; 19:704-708.
7. Van Rompaey V, Vandamme W, Muylle L, Van de Heyning PH. Temporal bone bank: complying with European union directives on human tissue and cells. *Cell Tissue Bank.* Epub Ahead of Print Mar 19.
8. Merchant SN, Nadol JB, Jr. *Schuknecht's Pathology of the Ear.* Ontario, Canada: McGraw-Hill; 2010.