

## CASE REPORT

# Surgical Removal of Diffuse-Type Neurofibroma Involving the Auditory External Canal in a Patient with Neurofibromatosis Type 1

Ryosei Minoda, Momoko Ise, Daizo Murakami, Yoshihiko Kumai, Eiji Yumoto

Department of Otolaryngology-Head and Neck Surgery, Kumamoto University School of Medicine, Japan (RM, MI, DM, YK, EY)

Diffuse-type neurofibroma (DN) associated with neurofibromatosis type 1 (NF1) involving the external auditory canal (EAC) is uncommon. In DN, it is generally difficult to remove tumors without destroying normal anatomical structures because of the infiltrative and hypervascularized nature of these tumors. A 38-year-old male with NF1 visited our department because of slowly progressive hearing loss on the right side. His EAC was obstructed with a soft borderless mass around the external ear. We performed ultrasonic surgical aspirator skin to just below the surface and also into the surrounding soft tissues without clear borders. An intraoperative rapid diagnosis of neurofibroma was made. We used an ultrasonic surgical aspirator to dissect the infiltrative tumor material. This was effective and caused no damage to the adjacent epidermis or to the auricular cartilage. Subsequently, we performed an M-meatoplasty to enlarge the entrance of the EAC. His hearing acuity recovered postoperatively to the normal range. The postoperative histological diagnosis was DN. At 5.5 years postoperatively, there has been no sign of re-growth. Thus, ultrasonic surgical aspirator resection and subsequent M-meatoplasty appears to be a good surgical approach for DN involving the EAC.

Submitted : 21 June 2012

Revised : 24 August 2012

Accepted : 07 September 2012

## Introduction

Neurofibromatosis type 1 (NF1), or von Recklinghausen's disease, occurs in 1 in 2200-4000 live births.<sup>[1]</sup> It is autosomally dominant with 70-80% penetrance; however, some cases of NF1 also result from spontaneous mutations. The National Institutes of Health (NIH) Consensus Development Conference formulated the current diagnostic criteria and proposed the name NF1.<sup>[2]</sup> The genetic defect has been linked to chromosome 17q11.2.<sup>[2]</sup>

Histologically, several types of neurofibromas are seen in NF1, including a localized type, a plexiform type, and a diffuse type.<sup>[3,4]</sup> Localized-type neurofibroma is the most common type encountered in NF1: typically, it is located in the dermis, but sometimes also extends to the

superficial subcutaneous fat. Localized-type neurofibroma has been recognized as a slowly growing, small subcutaneous tumor that occurs in small nerve branches.<sup>[3,4]</sup> Plexiform neurofibroma is virtually pathognomonic of NF1.<sup>[3]</sup> Plexiform neurofibromas start to develop in early childhood and present as large lesions that affect large segments of nerves, distorting and contorting them into deformed masses.<sup>[3]</sup> Plexiform neurofibromas are well circumscribed but are not encapsulated.<sup>[4]</sup> Diffuse-type neurofibroma (DN) presents as a plaque-like elevation of the skin, and often arises in the head and neck region<sup>[3]</sup>; however, it is uncommon in the external auditory canal.<sup>[1]</sup> This diffuse type of neurofibroma has ill-defined, infiltrative, cell-rich tumors that occupy the whole dermis and extend into the subcutaneous tissue. They envelope skin appendages

### Corresponding address:

Ryosei Minoda  
Department of Otolaryngology- Head and Neck Surgery,  
Kumamoto University School of Medicine, 1-1-1 Honjo, Kumamoto City, 860-8556, Japan.  
Tel: 81-96-373-5255  
Fax: 81-96-373-5256  
E-mail Address: minoda@gpo.kumamoto-u.ac.jp (R. Minoda)

Copyright 2005 © The Mediterranean Society of Otolology and Audiology

and subcutaneous fat without destroying them.<sup>[4]</sup> Such latent features of diffuse-type neurofibroma make it difficult to remove the tumor without destroying normal anatomical structures, resulting in functional losses.

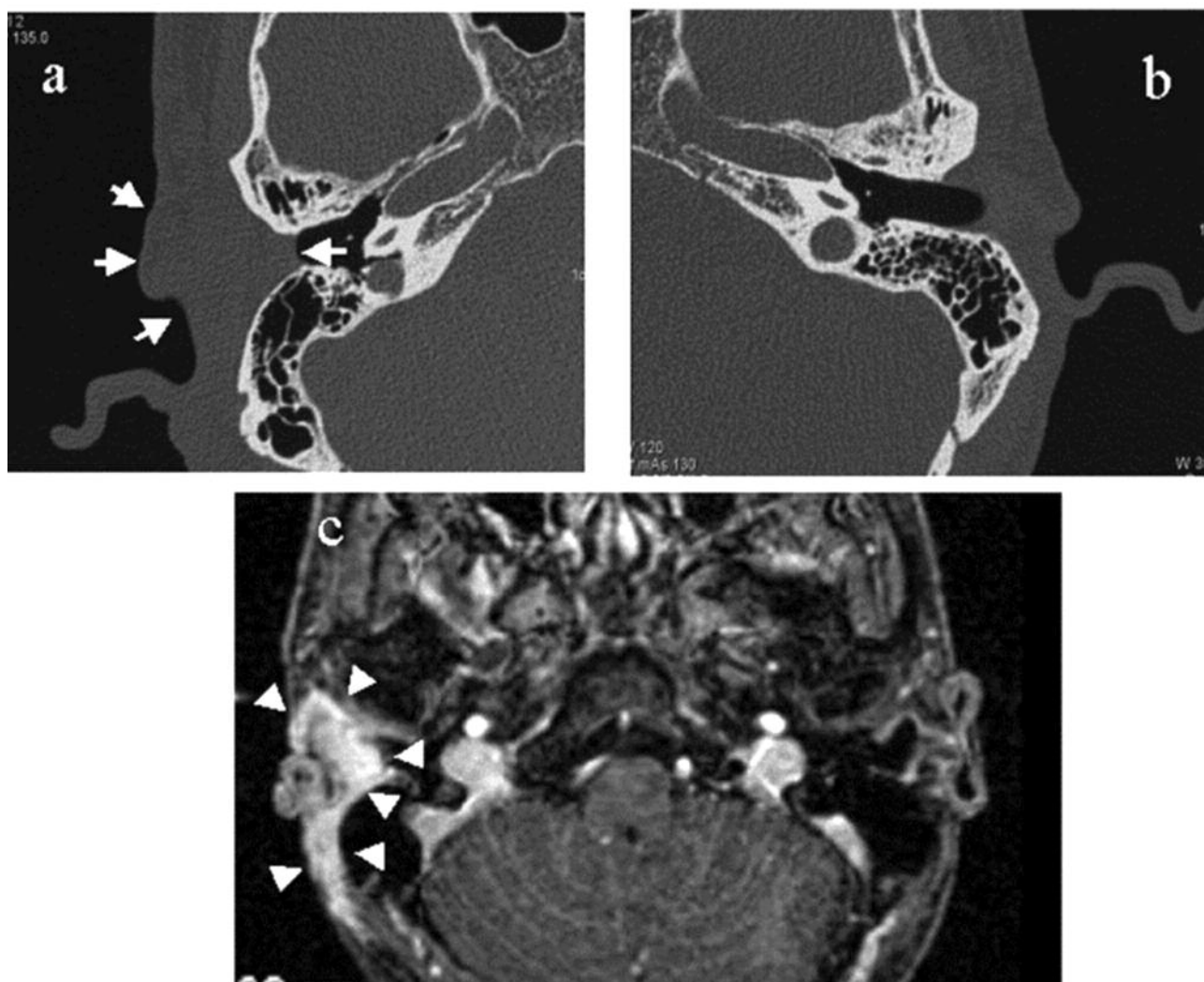
In this article, we present a case with NF1 who had a DN involving the external auditory canal, an uncommon site of NF1.

### **Case Report**

A 38-year-old male presented with slowly progressive right side hearing loss and a sensation of ear fullness. He had been diagnosed as having von Recklinghausen's disease since childhood. At 37 years of age, a 4-cm subcutaneous soft mass in the breast

had been removed by a dermatologist in our hospital; a postoperative histological diagnosis of the mass determined that it was neurofibroma.

A physical examination of the right ear revealed a soft borderless mass, involving the right external auditory canal (EAC) and the adjacent tissue. The right EAC was obstructed by the mass. Pure tone audiometry revealed an average conductive hearing loss of 40 dB on the right side. Neurological examinations were normal. A computed tomography (CT) scan of the temporal bone revealed obstruction of the right EAC, but there was no abnormal finding in the middle ear (Fig. 1a. b). Magnetic resonance imaging (MRI) showed a diffuse lesion with isointensity on a T1-

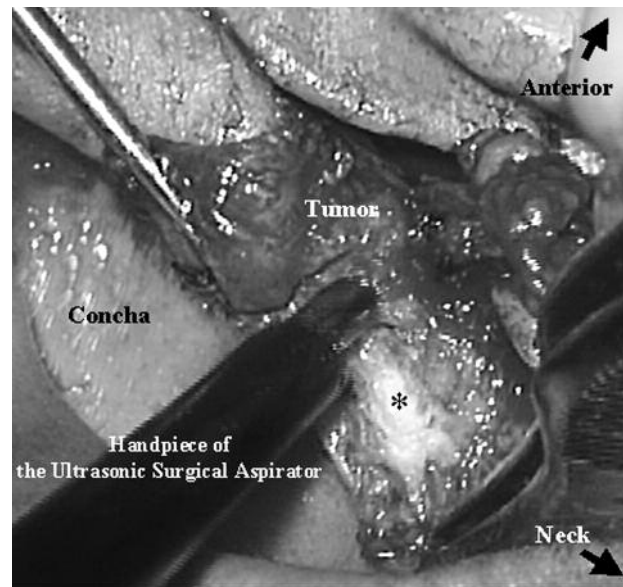


**Figure 1.** CT scan images showing that the entrance of the right EAC was obstructed by the tumor (arrows in 'a'), and that there was no abnormal finding in the left ear (b). Gd-3D MP-RAGE imaging on MRI demonstrated an enhanced distinct diffuse lesion area (arrowheads in 'c').

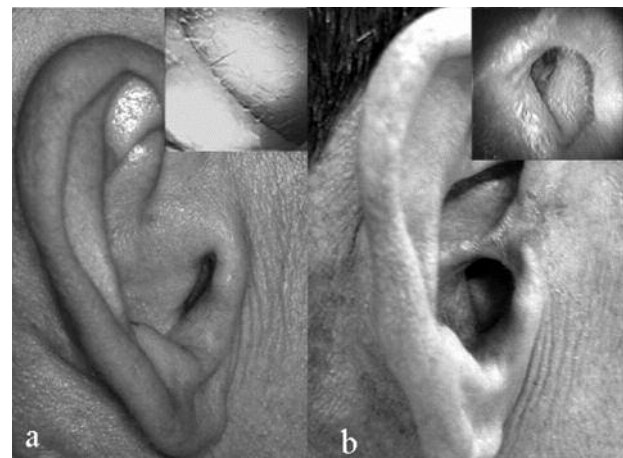
weighted image and low intensity on a T2-weighted image. Gadolinium-enhanced three-dimensional magnetization-prepared rapid gradient-echo (Gd-3D MP-RAGE) imaging showed distinct enhancement of the tumor (Fig. 1c). There was no abnormal finding in the central nervous system on MRI.

He underwent surgical resection of the tumor. After a retro-auricular skin incision, a yellowish-gray tumor was found just beneath the epidermis. The tumor was diagnosed as a neurofibroma via a pathological examination performed during the surgery. The tumor had diffusely spread into the dermis, subcutaneous tissue, adjacent fat and muscle extensively and invasively and bled easily. We removed the post-auricular tumor subtotally using electrocautery. Then, we endeavored to remove pre-auricular tumor infiltrating into the EAC skin and auricular cartilage using pre-auricular incisions for a subsequent M-meatoplasty.<sup>[5,6]</sup> At the beginning of the pre-auricular tumor removal, we used a pair of scissors to remove the tumor; however, it was difficult to control bleeding even with use of electrocautery. The ultrasonic surgical aspirator (Sonopet<sup>R</sup> UST-2000; M&M, Tokyo, Japan) was used to overcome the bleeding difficulties. The tumor was effectively and safely removed in an almost dry field by gentle repeat rubbing of the underside of the skin and the surface of the cartilage with an ultrasonic surgical aspirator hand piece, without causing damage to the cartilage or epidermis (Fig. 2). After tumor resection of the cartilaginous part of the EAC, the entrance of the EAC was enlarged using an M-meatoplasty after removal of part of the conchal cartilage.

Postoperatively, the histological diagnosis was confirmed as a DN. Postoperative wound healing was good. The diffuse swelling around the entrance of the EAC decreased significantly after the surgery; the tympanic membrane could be observed directly without use of an otoscope (Fig. 3). His hearing ability in the right ear improved to 13.3 dB, and the air-bone gap disappeared. There was no neurological deficit postoperatively. Gd-3D-MP-RAGE imaging demonstrated a significant decrease in the tumor (Fig. 4a). During 5½ years of follow-up, there has been no sign of constriction of the EAC, regrowth of the tumor (Fig. 4b), or deterioration of the right hearing threshold.



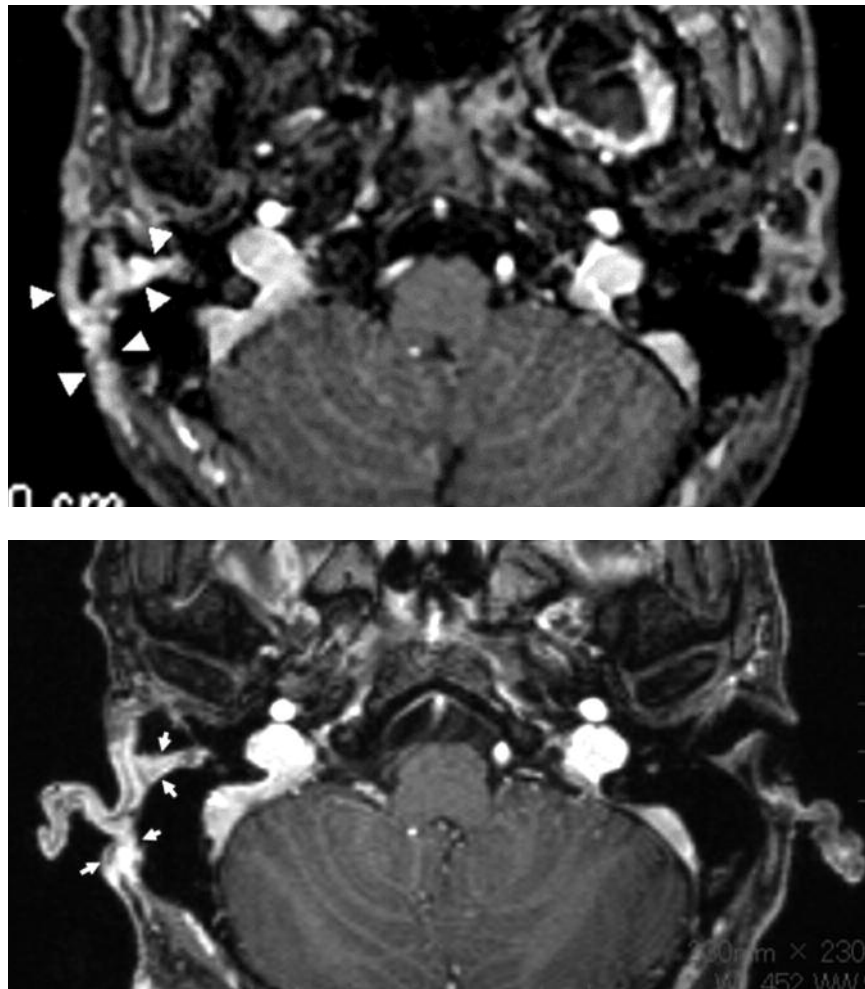
**Figure 2.** The tumor on the surface of the conchal cartilage and at the cartilaginous part of the EAC was excised using the ultrasonic surgical aspirator. The asterisk indicates the surface of the conchal cartilage from which the tumor has been removed using the ultrasonic surgical aspirator. Little bleeding is evident in the operation field.



**Figure 3.** The diffuse swelling around the entrance of the EAC that was present preoperatively decreased significantly after the surgery (preoperative: 'a'; postoperative: 'b'). The endoscopic images in the right corners show the entrance of the EAC.

## Discussion

Surgical management is the only viable therapy when a neurofibroma causes disability, intractable pain, or disfigurement.<sup>[7]</sup> However, as previous authors have mentioned,<sup>[8,9]</sup> complete surgical resection of diffuse neurofibromas is difficult because of the nature of the



**Figure 4.** Postoperative Gd-3D-MP-RAGE imaging on MRI at 6 months demonstrated a significant decrease in the tumor (arrowheads) (a). Postoperative Gd-3D-MP-RAGE imaging on MRI at 5½ years demonstrated no significant regrowth of the remaining tumor (arrows) (b).

infiltrative growth, the severity of the hemorrhagic problems associated with their excision, and the general anatomical situation. The most challenging surgical aspect of these tumors is their infiltrative nature.<sup>[7]</sup> The surgical management of neurofibromas generally entails a concern: the extent of resection with respect to the probability of recurrence and loss of function.<sup>[7]</sup> In child NF-1 patients, complete or near-complete excision of the neurofibromas ensures recurrence rates of less than 20 and 40%, respectively, whereas subtotal resection (removal of 90% or less) leads to a recurrence rate of >60%.<sup>[10]</sup> Neurofibromas develop throughout life, but periods of hormonal activity in puberty and pregnancy are marked by the development of new tumors and acceleration of the

growth of old ones.<sup>[7]</sup> Thus, in adulthood subtotal removal of the tumor probably has a lower recurrence rate than that in children. To minimize the postoperative recurrence rate, it is important to resect the tumor to the greatest extent possible without causing postoperative functional loss. The most intricate surgical aspect in this patient was the infiltration of the tumors into the dermis and subcutaneous tissue involving the EAC. The ideal dissector for minimization of the remaining tumor in this patient would be adjustable, enable cutting, and be able to cauterize. The ultrasonic surgical aspirator is an effective dissecting tool that has the ability to selectively dissect and is used widely in neurosurgery,<sup>[11]</sup> general surgery,<sup>[12]</sup> and plastic



surgery.<sup>[13]</sup> The titanium tip of the device handpiece vibrates with an ultrasonic frequency of 25,000 per second, the tip is hollow, and broken pieces of tumor are aspirated with saline solution through the hand piece. The ultrasonic surgical aspirator has been reported to cause little edema or neuronal loss. The energy of the device reaches as far as 50  $\mu$ m from the cutting edge.<sup>[14]</sup> An alternative instrument for resection of DNs is a high-frequency radio-wave electrosurgical device;<sup>[15]</sup> it has the advantage of a sharp handpiece tip that allows more precise resection, but the disadvantage that it has no aspiration function and requires more precise determination of the resection layer of the skin, so as not to damage the epidermis, while an ultrasonic surgical aspirator resection of the tumor just beneath the skin does not require precise determination of the resection layer; just gentle repeated rubbing of the underside of the skin. On the other hand, regular electrocautery is apt to cause damage to the epidermis due to stray energy. Reflection or stray application of energy injures tissue even beyond the point of dissection. Together, the ultrasonic surgical aspirator appears to be useful for the efficient and safe resection of a tumor just beneath the skin.

In a patient with DN where the EAC is obstructed, to prevent EAC reobstruction by the tumor, it is preferable to make the external auditory canal as wide as possible; however, generally it is best to avoid removing the posterior wall of the EAC because of the possibility of recurrence of the tumor in the EAC. If a tumor were to recur, extending into the middle ear, then it could involve important surrounding structures, such as the facial, dura, and ossicles. If there is hard bony wall material between the recurred tumor and the middle ear, we believe it creates a block, in effect blocking invasion to the middle ear. Therefore, we did not remove the bony part of the EAC. We removed only part of the conchal cartilage and then performed an M-meatoplasty after tumor excision. Several authors have reported M-meatoplasty to be a reliable and easy surgical method of enlargement of the entrance of the EAC.<sup>[5,6]</sup> M-meatoplasty is performed solely in such patients as recurrent external otitis patients or earwax plugging patients<sup>[5,6]</sup>. Also M-meatoplasty is performed along with the other surgical

procedures or as a revision surgery for resolving wet radical cavities.<sup>[5]</sup> They reported good clinical results. We adopted this novel surgical method in this case after removing the tumor using an ultrasonic surgical aspirator. Subsequently, a wide EAC was maintained during a 5½ year follow-up.

## Conclusions

We used the ultrasonic surgical aspirator to excise a DN involving the EAC and performed an M-meatoplasty to enlarge the entrance of the EAC. The ultrasonic surgical aspirator enabled us to dissect the infiltrative tumor without causing damage to the adjacent epidermis or the auricular cartilage. After subtotal removal of the tumor, an enlarged EAC was maintained during his postoperative clinical course. ultrasonic surgical aspirator resection and subsequent M-meatoplasty appears to be a good surgical approach for DNs involving the EAC.

There are no conflicts of interest.

## References

1. Lustig LR, Jackler RK. Neurofibromatosis type I involving the external auditory canal. *Otolaryngol Head Neck Surg.* 1996; 114:299-307.
2. Ferner RE. Neurofibromatosis 1 and neurofibromatosis 2: a twenty first century perspective. *Lancet Neurol.* 2007; 6:340-51.
3. Enzinger FM WS. *Soft tissue tumors.* 3rd ed. St Louis, Missouri: Mosby Elsevier; 1995.
4. Megahed M. Histopathological variants of neurofibroma. A study of 114 lesions. *Am J Dermatopathol.* 1994; 16:486-95.
5. Mirck PG. The M-meatoplasty of the external auditory canal. *Laryngoscope.* 1996; 106:367-9.
6. Rombout J, van Rijn PM. M-meatoplasty: results and patient satisfaction in 125 patients (199 ears). *Otol Neurotol.* 2001; 22:457-60.
7. Manolidis S, Higuera S, Boyd V, Hollier LH. Single-stage total and near-total resection of massive pediatric head and neck neurofibromas. *J Craniofac Surg.* 2006; 17:506-10.
8. Coakley D, Atlas MD. Diffuse neurofibroma obstructing the external auditory meatus. *J Laryngol Otol.* 1997; 111:145-7.

9. Rapado F, Simo R, Small M. Neurofibromatosis type 1 of the head and neck: dilemmas in management. *J Laryngol Otol.* 2001; 115:151-4.
10. Needle MN, Cnaan A, Dattilo J, Chatten J, Phillips PC, Shochat S, et al. Prognostic signs in the surgical management of plexiform neurofibroma: the Children's Hospital of Philadelphia experience, 1974-1994. *The Journal of pediatrics.* 1997; 131:678-82.
11. Day JD, Fukushima T. Suction control of ultrasonic aspirators. *J Neurosurg.* 1993; 78:688-9.
12. Little JM, Hollands MJ. Impact of the CUSA and operative ultrasound on hepatic resection. *HPB Surg.* 1991; 3:271-7.
13. Yoo WM, Pae NS, Lee SJ, Roh TS, Chung S, Tark KC. Endoscopy-assisted ultrasonic surgical aspiration of axillary osmidrosis: a retrospective review of 896 consecutive patients from 1998 to 2004. *J Plast Reconstr Aesthet Surg.* 2006; 59:978-82.
14. Margaret A. Thompson MDA, Michael A. Jozefczyk, Denis A. Coble, Lydia M. Kaufman. Structural and functional integrity of ovarian tumor tissue obtained by ultrasonic aspiration. *Cancer.* 1991; 67:1326-31.
15. Youm DJ, Kim JM, Choi CY. Simple surgical approach with high-frequency radio-wave electrosurgery for conjunctivochalasis. *Ophthalmology.* 2010; 117:2129-33.