

CASE REPORT

Rare Cases of Facial Nerve Tumors

Iseri Pervin, Keskin Gurkan, Kuru Fatma Demir, Oran Abdulkadir, Derin Serhan, Erdogan Selvet, Iseri Mete

Department of Neurology, Kocaeli University Medical Faculty, Kocaeli, Turkey. (IP)

Department of Otorhinolaryngology, Kocaeli University Medical Faculty, Kocaeli, Turkey. (KG, KFD, OA, DS, ES, IM)

Primary facial nerve tumors are usually misdiagnosed due to the variety of their clinical manifestations. The most commonly seen pathology is a schwannoma. However, because of their rarity, only a small group of clinicians have experience of the surgical management of these tumors. The treatment is complete surgical resection. However, in patients with normal preoperative facial nerve function, periodic clinical and radiological follow-up may also be recommended. Two schwannomas that originated from different segments of the facial nerve, one hemangioma, and a plexiform neurofibroma case originating from the sensorial auricular branch – not previously reported, to our knowledge – that were treated and followed in our clinic between 2007 and 2011 are presented.

Submitted : 16 November 2011

Revised : 03 January 2013

Accepted : 07 January 2013

Introduction

Facial nerve tumors are rare lesions. The presentation of these lesions varies with their site of origin. Facial paresis and hearing loss are the most frequent symptoms. Only approximately 5-10% of facial palsy is caused by a neoplasm^[1]. Despite the rarity of facial nerve tumors, the presence of a progressive, persistent, or recurrent facial nerve function deficit should always arouse suspicion of a facial nerve lesion. On physical examination, a mass may also be seen in the parotid gland, behind the tympanic membrane, or in the external ear canal^[2-3,4]. When a facial nerve tumor has been diagnosed, different therapeutic options have to be discussed with the patient, taking into consideration preoperative facial nerve function, tumor size and location, hearing level, and the patient's age. We report four cases of facial nerve tumor involving different

portions of the facial nerve and exhibiting different pathologies.

Case Series

Case 1:

A 45-year-old female patient presented with progressive left side facial paralysis for 3 months. She had experienced episodes of sudden left facial palsy and been treated for Bell's palsy with steroids at another clinic 1 year before her first visit to our hospital. After the steroid treatment, the patient had facial move rehabilitation, although her facial palsy progressed. She complained of left-sided hearing loss and pulsatile tinnitus.

On initial examination, she had House-Brackmann (HB) grade 4 weakness. Microscopic examination of the tympanic membrane showed bulging on the left

Corresponding Author

Abdulkadir Oran
Department of Otorhinolaryngology, Kocaeli University Medical Faculty, Kocaeli, Turkey.
Phone: +905057557016
E-mail: droran@gmail.com

Copyright 2005 © The Mediterranean Society of Otolaryngology and Audiology

side, like that of secretory otitis media. Audiometry documented a 48-dB mild conductive hearing loss in the left ear. The stapedial reflex was absent on the left (ipsi- and contra-stimulation) and was present on the right (ipsi- and contra-stimulation). A flat (type B) tympanogram was produced in the left ear.

High-resolution computed tomography (HRCT) demonstrated a soft tissue mass of the left temporal bone involving the geniculate ganglion and a partial bone defect of the fallopian canal (Fig. 1). Magnetic resonance imaging (MRI) demonstrated a lesion involving the left tympanic segment of the facial nerve with irregular projections and significant contrast enhancement (Fig. 2).

The patient underwent excision of the mass through a left transmastoid approach. At the time of surgery, a dark, blue vascular mass centered on the geniculate portion of the facial nerve was identified (Fig. 3). The tumor appeared to arise from the epineurium of the facial nerve and was removed totally, preserving the facial nerve. The lenticular process of the incus was eroded. The stapes could not be separated from the tumor, and had to be removed together with the vascular tumor. Histopathologic evaluation showed that the lesion was a hemangioma of the facial nerve (Fig. 4).

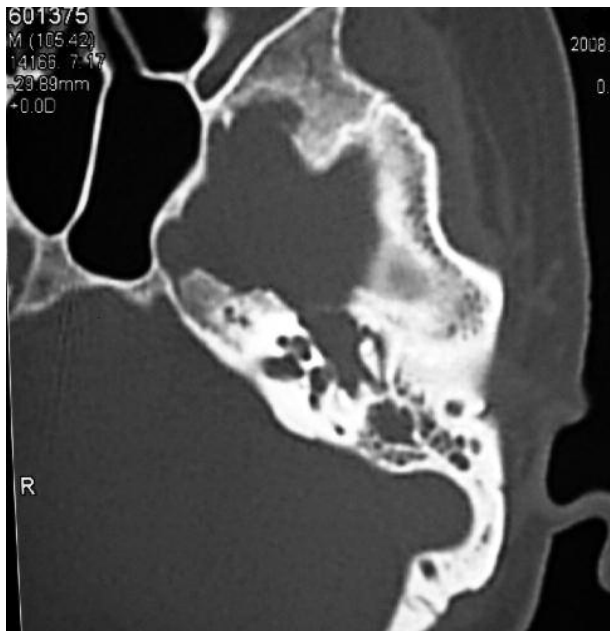

Figure 1. Axial section CT of case 1 reveals the soft-tissue mass on the left side that involves the area of the geniculate ganglion of the facial nerve.

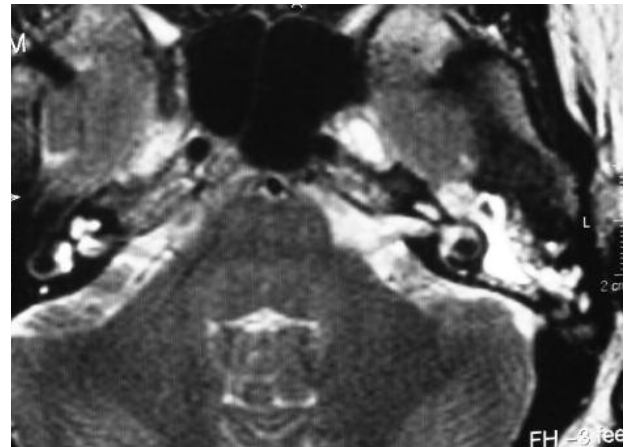

Figure 2. Axial gadolinium-enhanced magnetic resonance image of the left temporal bone, showing a hyperintense, enhancing mass that involves the geniculate ganglion and the tympanic segment of the facial nerve.

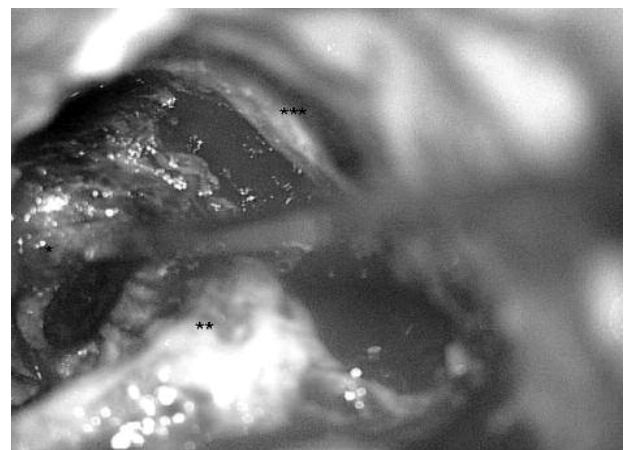


Figure 3. Excision of the mass through a left transmastoid approach *Mass, **Facial canal, ***Tegmen tympani

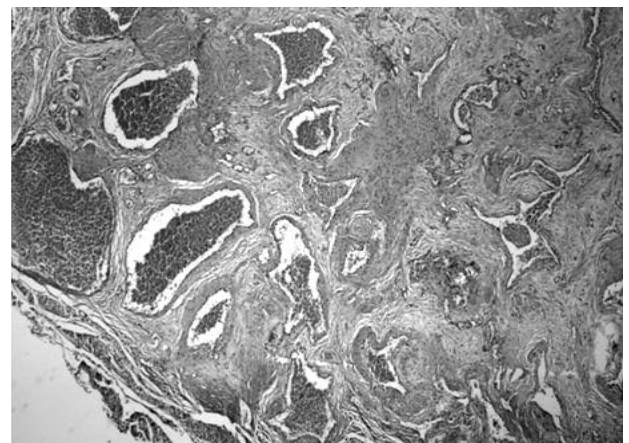


Figure 4. Histopathologic examination of case 1 showing dilated thin-walled vascular spaces with intervening hypocellular collagenous stroma. (H&E; original magnification X40.)

Postoperatively, the patient's facial nerve function was HB grade 5 and her hearing was preserved. Three years after surgery, the patient has a HB grade 3 facial nerve function. There was no recurrence on MRI at 3 years from surgery.

Case 2:

A 42-year-old female patient presented with a slowly growing, asymptomatic, left sided infra-auricular mass for 6 years. In the few weeks prior to presentation, the patient had complained of pain and enlargement of the mass. Facial nerve function was normal and there was no history of facial weakness. On examination, the mass was mobile and firm. It measured 3×2 cm and was localized behind the posterior margin of the left mandibular ramus. Her otolaryngologic and general physical examination were completely normal.

Fine-needle aspiration cytology (FNAC) was performed and showed inflammatory changes compatible with chronic sialadenitis. MRI scans showed a well-circumscribed, inhomogeneous mass, that measured $3 \times 2 \times 2$ cm in the deep lobe of the left parotid gland (Fig. 5). Pleomorphic adenoma was considered in the differential diagnosis.

A superficial parotidectomy was planned, accompanied by frozen section examination. During the surgery a 3-cm, well-circumscribed, firm mass was located on the main trunk of the facial nerve (Fig. 6). Frozen section analysis from an incisional biopsy revealed a schwannoma (Fig. 7). Because of the patient's preoperatively normal facial nerve function, it was decided not to resect the tumor. The patient's facial nerve function was normal at the follow-up 3 years after surgery. A subsequent MRI, 3 years after surgery, showed very little tumor regression.

Case 3:

A 34-year-old male patient presented to another hospital with an initially asymptomatic, slowly enlarging mass in his left parotid gland 2 years earlier. A superficial parotidectomy was initiated and postoperative histopathological examination of the specimen revealed a pleomorphic adenoma. On follow-up using ultrasonography (USG), tumor recurrence in the left pre-auricular region was encountered 2 years after the initial surgery. On examination, a mobile, firm mass of 1 cm was

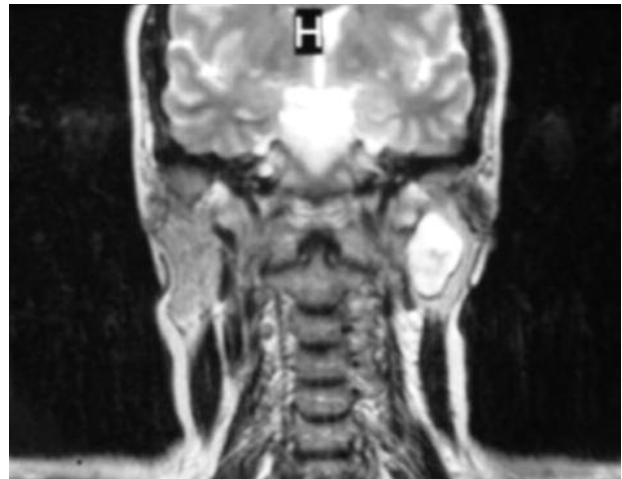

Figure 5. Coronal T2-weighted MR image of case 2 reveals a tumor in the deep lobe left of parotid gland.

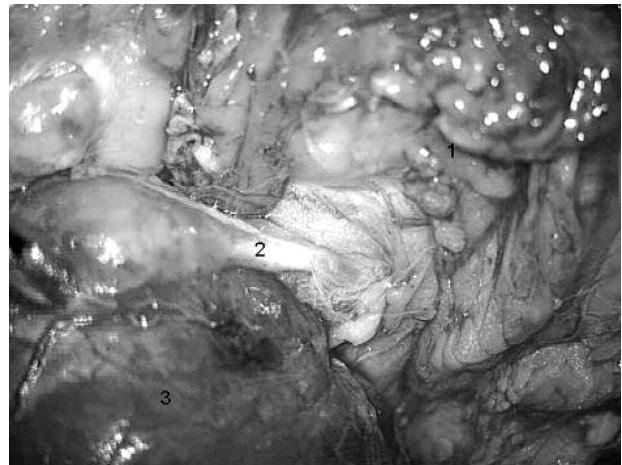


Figure 6. Schwannoma arising from the main trunk of left facial nerve. 1. Superficial lobe of parotid, 2. Main trunk of facial nerve, 3. Mass

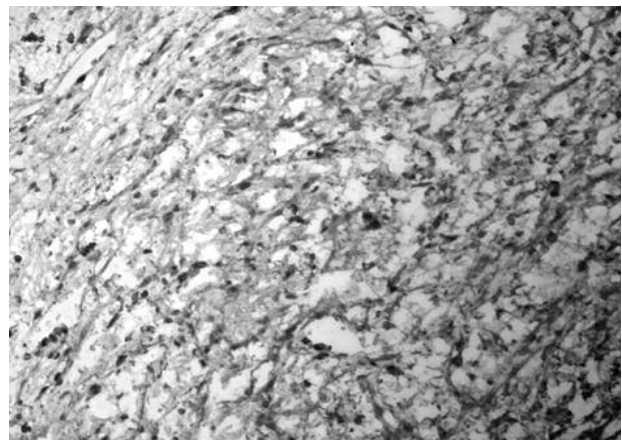


Figure 7. The final pathology report identifies the tumor as a facial nerve schwannoma. Spindle cells are irregularly scattered in a loose myxoid stroma. (H&E, original magnification X200)

palpable. A MRI scan demonstrated a well-circumscribed inhomogeneous mass in the superficial and deep lobe of the parotid gland, measuring 14×9 mm (Fig. 8). It was decided to resect the tumor. During the supplementary parotidectomy procedure, a well-circumscribed, firm mass measuring 1×1.5 cm was identified between the buccal and marginal mandibular branches of the facial nerve. Histological analysis of the mass was compatible with a schwannoma. Postoperatively, the patient's facial nerve function was normal.

Case 4:

A 39-year-old female patient was admitted to our clinic with fullness, hearing loss, and pain in her right ear for 3 months. Microscopic examination showed a polypoid mass in the posterosuperior part of the left external ear canal. The patient's facial nerve function was normal. Pure tone audiometry revealed a 42-dB conductive hearing loss in the right ear. HRCT demonstrated a 15×10 -mm hypodense lesion at the right external ear canal that expanded the mastoid bone (Fig. 9). Intraoperatively, a 2×1 -cm mass was observed to obliterate the external ear canal (Fig. 10). The mass had eroded the posteroinferior part of the mastoid bone and extended to the tympanic cavity. The lesion arose from the sensory auricular branch of the

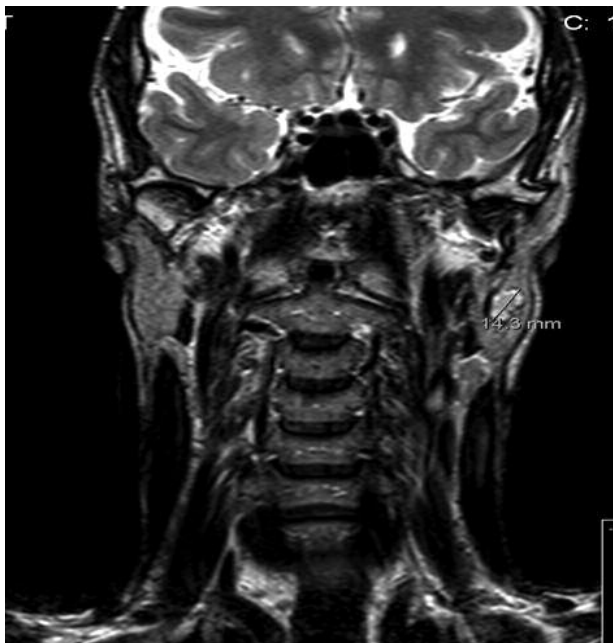

Figure 8. Coronal T2-weighted MR image of case 3 shows a hyperintense well-defined mass (arrow) in the left parotid gland.

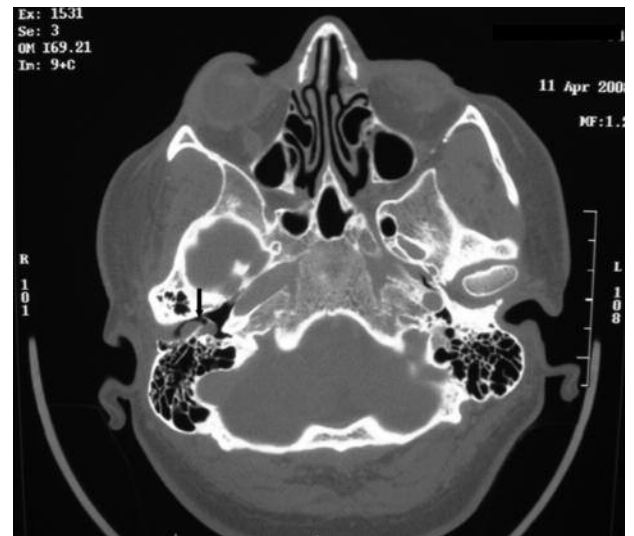


Figure 9. Axial section CT of case 4 reveals the soft-tissue mass on the right external ear canal.

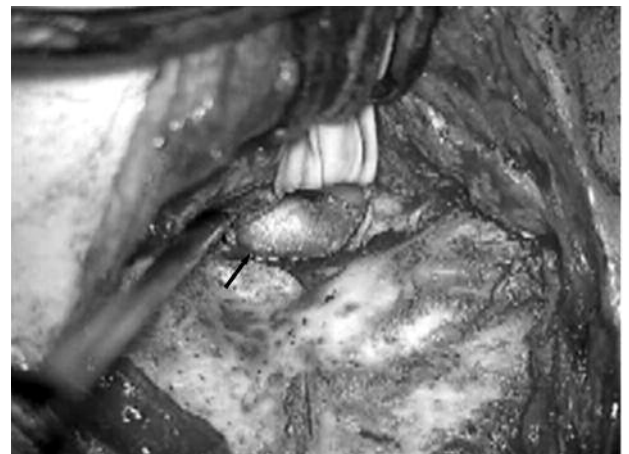

Figure 10. The mass obliterated the right external ear canal.

facial nerve. It was decided to resect the tumor. Histopathological examination of the specimen revealed a plexiform neurofibroma (Fig. 11). In the postoperative period, the patient's facial nerve function and hearing level were normal and the pain resolved. Postoperatively, the patient was evaluated for neurofibromatosis syndrome (NF1) but there was no sign of NF1.

Discussion

Facial nerve tumors are rare and thus represent an uncommon cause of facial palsy. Schwannomas are the most commonly identified histopathologically, followed by hemangiomas, neurofibromas, and meningiomas. Approximately 700 schwannoma and

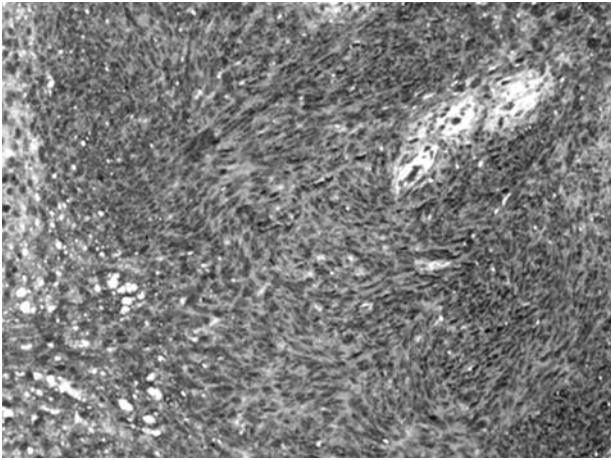


Figure 11. Histopathologic examination of case 4 showing spindle cells stained positively with S100. (S100, original magnification X200)

100 hemangioma cases originating from the facial nerve have been reported in the international literature. About 60 reported schwannomas had intraparotid locations [5-6,7]. Schwannomas and neurofibromas are benign tumors, originating from nerve sheaths. It is challenging to distinguish them histopathologically. A schwannoma is typically a well-bounded and encapsulated mass. Neurofibromas, however, are nerve sheath tumors, enlarging diffusely, which are not well-bounded, and are usually associated with NF1 (von Recklinghausen's disease). Plexiform neurofibroma is a rare variant of the neurofibroma [8]. Facial nerve hemangiomas are extra-neural benign vascular tumors arising from extensive vascular plexuses distributed along the course of the facial nerve and cause symptoms by compression [7]. Of the cases we presented, two were diagnosed as schwannomas, one was a hemangioma, and one was a plexiform neurofibroma.

Facial nerve tumors can arise from any segment of the facial nerve and are usually located in a multisegment manner, intratemporally and particularly in the geniculate ganglion. The number of cases with isolated intraparotid locations is limited [5]. Two of our cases had isolated intraparotid locations. Although its function was known, the anatomical location of the sensory auricular branch of the facial nerve, within the temporal bone, was described recently by Eshraghi and colleagues [9]. A tumor originating from that branch of the facial nerve was detected in one of our patients.

Although symptoms vary according to tumor localization, facial paralysis is observed most commonly [10]. Facial paralysis usually has a progressive course [11]. However, attacks of recurrent partial or complete facial paralysis may be observed in some cases [12]. In intraparotid tumors, facial nerve function may totally be normal while in those with intratemporal localizations, facial paralysis is observed frequently. Facial paralysis may be observed in 20% of facial nerve tumors with intraparotid localization [13]. In two cases with intraparotid localization and one with an origin in the sensorial auricular branch of facial nerve, facial paralysis was not observed, whereas HB grade 5 facial paralysis was observed in a case at the geniculate ganglion. This case had a history of previous facial paralysis on the same side 1 year earlier.

Hearing loss is the second most common symptom. In tumors of the internal acoustic canal (IAC), it is the most common symptom [14]. Conductive, sensorineural, or mixed-type hearing loss may be seen with regard to the localization of the tumor. Conductive hearing loss is usually seen in cases at the geniculate ganglion or tympanic segment, whereas sensorineural hearing loss is observed mainly in cases at the IAC (10). Moderate conductive hearing loss was detected in two cases of our series with geniculate ganglion and the sensorial auricular branch of the facial nerve localizations. An improvement in postoperative hearing ability was noted in both cases.

A mass in the external auditory tract, behind the tympanic membrane, or within the parotid may be detected on physical examination. Asymptomatic intraparotid masses were palpated in two cases, while a polypoid mass obliterating the external auditory tract was detected in one case (case 4).

Preoperative diagnosis of facial nerve tumors may not be possible. The diagnosis is usually made during exploration, due to a parotid tumor, particularly in intraparotid masses [4]. Similarly, in our series the diagnosis was established via surgical exploration in two cases with intraparotid localization. One of them (case 4) had a history of a previous parotidectomy due to a pleomorphic adenoma. Relapsing pleomorphic adenoma was considered to be the diagnosis in the patient and a complementary surgery was scheduled. However, a facial schwannoma was detected postoperatively.

Early diagnosis and treatment is the most important factor for saving postoperative facial nerve function and the sense of hearing. In cases where a facial nerve tumor is suspected, gadolinium-enhanced MRI and temporal CT are useful for the determination of lesion localization. HRCT of temporal bone is superior to MRI, particularly in detecting the integrity of the fallopian canal in intratemporal lesions. Anatomical variation in widening at the level of the geniculate ganglion should be kept in mind if facial nerve function is normal^[15]. A bilateral comparison is also important in these cases.

Specific radiological findings are not usually present in facial nerve tumors. In facial nerve hemangiomas, however, a honey-comb appearance on HRCT is characteristic as a result of temporal bone erosion and calcification^[16]. Nevertheless, this characteristic appearance was not observed in the facial hemangioma case we present.

In schwannoma cases with intraparotid localization, FNAC is usually not helpful in diagnosis because it is hard to obtain diagnostic cells and extracellular materials, including Verocay bodies, via FNAC^[17]. Similarly, no diagnosis was established in our case (case 2) using preoperative FNAC.

Facial nerve tumors are treated primarily by surgical excision. A transmastoid approach, a middle cranial fossa approach, or a superficial parotidectomy can be used depending on the localization of the tumor^[4,5,18]. Tumor excision was performed in two of our cases via a transmastoid approach and a superficial parotidectomy in one. In most cases, excision of the involved facial nerve segment may also be required for total tumor resection. In this case, reconstruction with a nerve graft is also required, and despite this, postoperative facial nerve function is not better than HB Grade 3^[10]. In three of our cases who underwent complete surgical resection, nerve integrity was saved and no reconstruction was required.

Preoperative facial nerve function is the most important factor determining the treatment approach. Because facial nerve tumors are usually slow-growing and benign, periodic clinical and radiological follow-up are recommended for patients with normal nerve function. Given that preoperative facial nerve function was normal in our case with an intraparotid facial schwannoma (case 2), the tumor was not resected. During 3 years of follow-up, minimal reduction in tumor size was observed.

The most important factor determining postoperative facial nerve function is the grade and duration of facial nerve paralysis before surgery^[3]. The chances of improving facial nerve function decreases in patients who do not undergo surgery within 1 year of development of facial paralysis^[10]. At the 3-year follow-up of the geniculate ganglion hemangioma case, suffering from HB grade 5 facial nerve paralysis for 3 months preoperatively, an improvement in facial nerve function was noted (HB grade 3).

Conclusions

In conclusion, facial nerve tumors are benign, slowly enlarging, and rare lesions. Despite the fact that it is a rare cause of facial paralysis, the presence of a facial tumor should be suspected, especially in recurrent and progressive paralysis. Early diagnosis is important for saving postoperative facial nerve function and the sense of hearing. Age, tumor localization, tumor size, preoperative facial nerve function, and hearing level decide the treatment of choice.

References

1. Jackson CG, Glasscock ME, Hughes F, et al. Facial paralysis of neoplastic origin, diagnosis and management. *Laryngoscope* 1980; 90:1581-95.
2. Saliba I, Fayad JN. Facial nerve hemangioma of the middle ear. *ENT Journal* 2009; 88: 822-823.
3. Chao WC, Liu TC, Ng SH, Wu CM. Facial nerve schwannoma. *Otolaryngology–Head and Neck Surgery* 2009; 141:146-147.
4. Kreeft A, Schellekens PPA, Leverstein H. Intraparotid facial nerve schwannoma. What to do? *Clinical Otolaryngology*, 2007; 32, 120–135.
5. Caughey RJ, May M, Schaitkin BM. Intraparotid facial nerve schwannoma: Diagnosis and management. *Otolaryngol Head Neck Surg* 2004; 130:586-92.
6. Alicandri-Ciufelli M, Marchioni D, Mattioli F, Trani M, Presutti L. Critical literature review on the management of intraparotid facial nerve schwannoma and proposed decision-making algorithm. *Eur Arch Otolaryngol* 2009; 266: 475–9.
7. Friedman O, Neff BA, Willcox TO, Kenyon LC, Sataloff RT. Temporal Bone Hemangiomas Involving the Facial Nerve. *Otology & Neurotology* 2002; 23:760-766.

8. Marocchio LS, Oliveira DT, Pereira MC, Soares CT, Fleury RN. Sporadic and multipl neurofibromas in the head and neck region: a retrospective study of 33 years. *Clin Oral Invest* 2007; 11:165-169.
9. Eshraghi AA, Buchman CA, Telischi FF Sensory auricular branch of the facial nerve. *Otol Neurotol*. 2002; 23(3):393-6.
10. Falcioni M, Russo A, Taibah A, Sanna M. Facial nerve tumors. *Otol Neurotol* 2003; 24:942–7.
11. Shirazi MA, Leonetti JP, Marzo SJ, Anderson DE. Surgical Management of Facial Neuromas: Lessons Learned. *Otology & Neurotology* 2007; 28:958-963.
12. Pulec JL. Facial nerve neuroma. *Ear Nose Throat J* 1994; 73: 721-52.
13. Bretlau P, Melchior H, Krogdahl A. Intraparotid neurilemmoma. *Acta Otolaryngol* 1983; 95:382-4.
14. Isaacson B, Telian SA, McKeever PE, Arts HA. Hemangiomas of the Geniculate Ganglion. *Otol Neurotol* 2005; 26:796-802.
15. Swartz JD, Harnsberger HR. Imaging of the temporal bone. Third edition. New York/Stuttgart: Thieme; 1998.
16. Palacios E, Kaplan J, Gordillo H, Rojas R. Facial nerve hemangioma. *ENT Journal* 2003; 83:836-37.
17. Back L, Heikkila T, Santos FP, Saat R, Leivo I, Makitie AA. Management of facial nerve schwannoma: a single institution experience. *Acta Oto-Laryngologica*, 2010; Early Online, 1–6.
18. Miyashita T, Hoshikawa H, Kagawa M, Mori N. A case report of facial nerve hemangioma. *Auris Nasus Larynx* 34 (2007) 519–522.