

CASE REPORT

A Case of Acute Mastoiditis and a Perilymph Fistula with Fracture of the Stapes Following Blowing the Nose

Kazuhisa Yamamoto, Yuichiro Yaguchi, Yasuhiro Tanaka, Hiromi Kojima

Department of Otorhinolaryngology, The Jikei University School of Medicine, Tokyo (KY, YY, HK)
Department of Otorhinolaryngology, The Dokkyo University School of Medicine (YT)

We present a rare case of severe sensorineural hearing loss with fracture of the posterior crus of the stapes following blowing the nose.

A 50-year-old man visited us on the 6th day of having otalgia, hearing loss and dizziness in his right ear, which began after blowing his nose. The right tympanic membrane could not be observed because of marked swelling of the external auditory canal, but persistent otorrhea was noted. Pure tone audiometry showed total deafness in the right ear. A computed tomography scan of the temporal bone showed pneumolabyrinth and soft tissue densities in the tympanic cavity and the mastoid. Suspecting a perilymph fistula and acute mastoiditis, exploratory tympanotomy and mastoidectomy were performed and revealed a longitudinal fracture of the posterior crus of the stapes.

It is rare that an indirect injury such as blowing the nose leads to fracture of the stapes. The combination of a perilymph fistula and acute mastoiditis is also rare.

Submitted : 04 September 2012

Accepted : 08 October 2012

Introduction

Stapes fractures are usually seen in association with tympanic membrane rupture as a result of direct injury or with major skull trauma. However, barotrauma such as blowing the nose is a rare cause of stapes fractures. Furthermore, fracture of the posterior crus is extremely rare. To our knowledge, the combination of a perilymph fistula and acute mastoiditis has not been previously reported. We experienced a rare case in which blowing the nose led to otitis media, acute mastoiditis and a perilymph fistula, with fracture of the posterior crus of the stapes. The details of this case are presented together with the review of the literature and some discussion.

Case Report

A 50-year-old man was seen on the 6th day of having otalgia, hearing loss and dizziness in his right ear, which began after blowing his nose. He had been diagnosed and treated for acute otitis media at a different clinic before he visited us. He had no history of ear disease, nor was there any other relevant medical history. In particular, his hearing had been normal, and he had never suffered from dizziness. He did not regularly take any medications.

On examination, the right tympanic membrane could not be seen because of marked swelling of the external auditory canal, but persistent otorrhea was noted (Fig.

Corresponding address:

Kazuhisa Yamamoto
Department of Otorhinolaryngology, Jikei University School of Medicine, Tokyo, Japan
3-25-8 Nishi-shimbashi, Minato-ku, Tokyo 105-8461, Japan
Phone: +81-3-3433-1111 ext 3601
Fax: +81-3-5400-1250;
E-mail: kazu1109@jikei.ac.jp

Copyright 2005 © The Mediterranean Society of Otolary and Audiology

1). Spontaneous and gaze nystagmus tests revealed right-beating nystagmus. The fistula test was negative. Laboratory tests showed a white blood cell count of 6,500/ μ L and a C-reactive protein level of 8.28 mg/dL.

Pure tone audiometry revealed total deafness in the right ear and normal in the left ear.

A computed tomography scans of the temporal bone showed soft tissue densities in the tympanic cavity and the mastoid. It also showed air bubbles trapped in the cochlea and the vestibule (Fig. 2). These CT findings suggested both a perilymph fistula and acute mastoiditis.

Exploratory tympanotomy and canal wall up mastoidectomy were performed on the day following admission, 7 days after the onset of symptoms. The mastoid was filled with severe granulation tissue and pus. A microbiological swab of the pus showed *Streptococcus pyogenes*. We cleaned and irrigated the mastoid as possible. The tympanic membrane was markedly thickened, and the tympanic cavity was filled with severe granulation tissue. There was a longitudinal fracture of the posterior crus of the stapes. The stapes was leaning toward the promontory, and the footplate was dorsally invaginated into the vestibule (Fig. 3). The fracture line of the posterior crus was clearer when the incus was lifted up. No perilymph leakage was actually seen from the region of the stapes footplate or round window because it was filled with severe granulation

tissue. A free temporal fascia graft was used to seal both the round window and the footplate in the oval window. The ossicular chain was intact. A ventilation tube was inserted into the tympanic cavity. Postoperatively, two courses of 5-day tapered systemic steroid were administered, and antibiotic chemotherapy consisted of flomoxef sodium. Postoperatively, there was no recovery of his hearing, but his vestibular symptoms resolved.

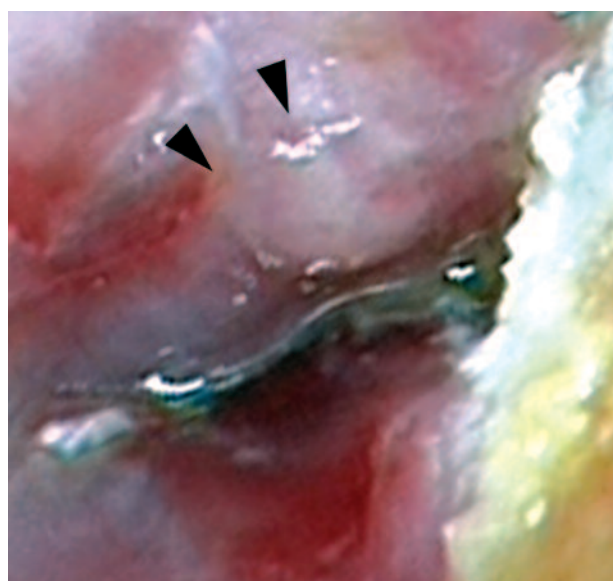


Figure 1. Preoperative right external auditory canal finding. The external auditory canal was markedly swollen (arrowheads). The tympanic membranes could not be seen.

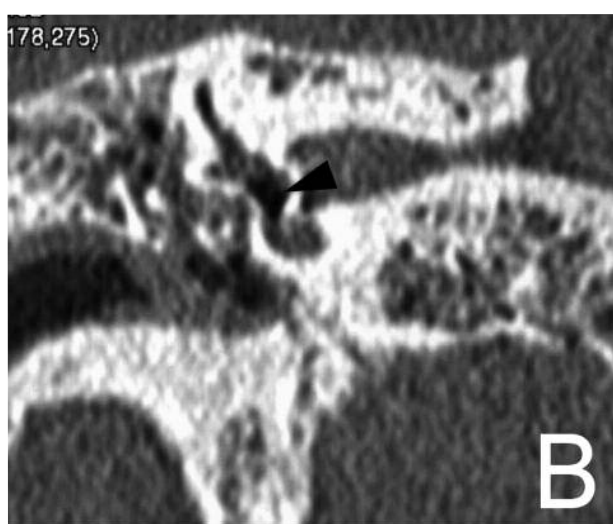
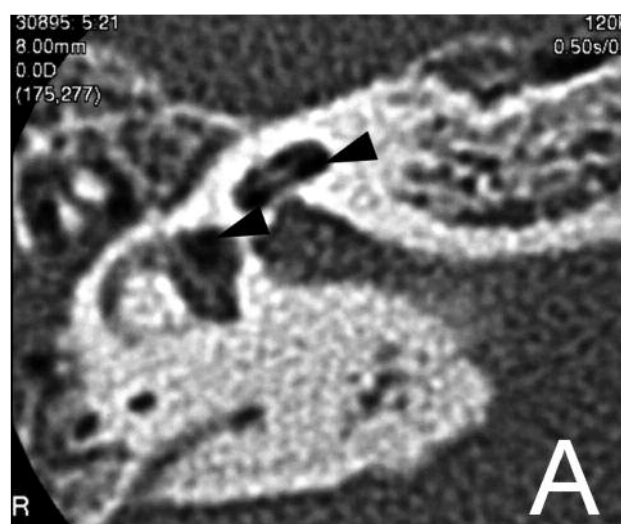


Figure 2. Preoperative computed tomography of the right temporal bone. Right axial view of computed tomography of the temporal bone shows air bubbles (arrowheads) trapped in the vestibule and the cochlea (**A**). Right coronal view of computed tomography of the temporal bone shows an air bubble (arrowhead) trapped in the vestibule (**B**).

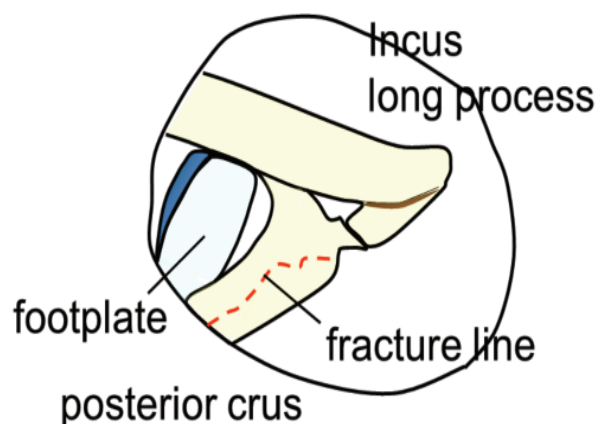
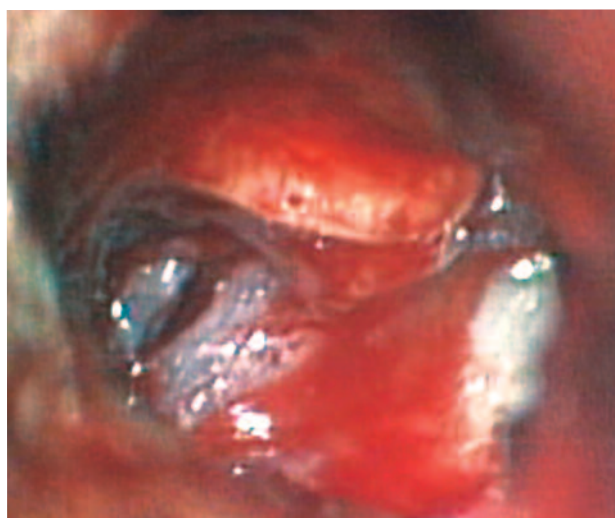

Figure 3. Operative view. There was a longitudinal fracture of the posterior crus of the stapes.

Discussion

In this case, no perilymph leakage was actually seen from the region of the stapes footplate or the round window because of the presence of the severe granulation tissue, but the CT finding of pneumolabyrinth was suggestive of a perilymph fistula. Perilymph fistula is a well-recognised result of barotrauma due to such as sneezing, straining, blowing the nose and diving, as well as direct injury via the external auditory canal or major skull trauma. Simmons^[1] hypothesized the double-membrane break syndrome, one at the oval or round window and one further inside the cochlea. The combination of endolymph and perilymph due to the intracochlear membrane breaks might cause sudden sensorineural hearing loss. Goodhill^[2] hypothesized that the mechanism of rupture of the oval or round window could involve an explosive or implosive route. The explosive route means that an increase in the cerebrospinal fluid pressure in the cochlear aqueduct leads to a round window rupture. Transmission of the pressure through the modiolus would cause an oval window break. The explosive route can be triggered by lifting, sneezing, coughing or straining. The implosive route means that an increased middle ear pressure leads to rupture of the round window membrane and tearing of the annular ligament of the oval window. The implosive route can be triggered by barometric

pressure changes, compression trauma of the ear or Valsalva's maneuver. We surmised that the implosive route was the cause of the perilymph fistula in our patient.

During tympanotomy we observed that the fracture was in a longitudinal direction along the posterior crus of the stapes, a location which does not appear to have been reported previously. Only six other cases of the combination of stapes fracture and a perilymph fistula due to barotrauma have been reported in the literature (Table1)^[3-6]. Only we had the case of fracture of the posterior crus. We surmise that this longitudinal fracture of the posterior crus means that an avulsion fracture. A sudden increase in the middle ear pressure following blowing the nose, we postulate, may therefore have caused invagination of the stapes footplate in our case. And a powerful sound during blowing the nose may have caused strong contraction of the stapedius. As a result of such invagination of the stapes footplate and strong contraction of the stapedius, an avulsion fracture of stapedius origin must have occurred in the posterior crus. Ishida et al.^[3] and Kuruma et al.^[6] speculated that the stapes footplate is fragile in histology and structure. Also in our case, there is some possibility that the stapes superstructure was fragile.

Only in Winney et al.'s^[4] case did surgical repair result in hearing recovery. They reported that early

Table 1. Reported cases with fracture of the stapes and a perilymph fistula due to an indirect injury.

Author	Age(yr)	Sex	Cause	Duration prior to surgery	Fracture of stapes	Hearing result
Ishida et al 1992	50	F	blowing the nose	113days	footplate, longitudinal	no change
Whinney et al 1996	43	M	diving	11days	footplate, transversarial	improved
E Whitehead 1999	28	M	sneezing	21days	footplate, longitudinal	no change
	40	F	sneezing	28days	footplate, longitudinal	no change
	50	F	parturition	16years	footplate, longitudinal	no change
Kuruma et al 2003	69	F	washing hair	63days	footplate, transversarial	no change
Present case	50	M	blowing the nose	7days	posterior crus, longitudinal	no change

exploration and repair of a suspected perilymph fistula led to hearing recovery. Goodhill et al.^[7] reported performing 47 exploratory tympanotomies and that the hearing was markedly improved in 12 patients who underwent the procedure within 13 days after the onset of hearing loss. Early exploratory tympanotomy is recommended for patients who show aggravation of vestibular symptoms and hearing loss.

We performed a tympanotomy 7 days after the onset of symptoms in our patient (i.e., on the day following admission). We considered the timing of the operation to have been appropriate. However, there was no postoperative improvement in hearing. Our patient also had labyrinthitis due to inflammation of the middle ear and mastoid that extended through an oval window fistula. We surmise that the perilymph fistula and labyrinthitis caused the severe sensorineural hearing loss. The combination of a perilymph fistula and labyrinthitis was presumably one of the reasons that the early exploratory tympanotomy did not result in any recovery of hearing. However, although there was no improvement in hearing, the patient has no further vestibular symptoms after the surgery.

Seltzer and McCabe^[8] reported that vestibular symptoms were eliminated or improved in 94% of

patients after closure of a perilymph fistula. Potter and Conner^[9] reported vestibular symptoms were cured in 80%, and Healy et al.^[10] reported a 93% cure rate. In general, it is thought that the improvement rate for vestibular symptoms after closure of a perilymph fistula is higher than the improvement rate for the hearing. As noted above, the vestibular symptoms were eliminated in our patient.

The tympanotomy to seal both the round window and the oval window was effective in improving the defenses against labyrinthitis. A view of the published literature indicates that the combination of a perilymph fistula and acute mastoiditis is rare.

Perilymph fistulas are difficult to diagnosis, because—as in our case—perilymph leakage is not always actually seen from the region of the stapes footplate or round window. Seltzer and McCabe^[8] reported that 106 primary fistulas were found in 214 exploratory tympanotomies. Shelton and Simmons^[11] reported a 51% positive incidence for perilymph leakage in exploratory tympanotomy. Pneumolabyrinth associated with a perilymph fistula was first reported by Fee^[12] in 1968. It can occur as a result of barotrauma, iatrogenic injury, head trauma, cholesteatoma or neoplasm of the middle ear. As our

case report demonstrates, pneumolabyrinth, which can be detected on CT, is a significant radiologic finding that should lead one to suspect a perilymph fistula. In such cases, CT should be performed as soon as possible.

References

1. Simmons FB. The double-membrane break syndrome in sudden hearing loss. *Laryngoscope* 1979; 89: 59-66.
2. Goodhill V. Leaking labyrinth lesion, deafness, tinnitus and dizziness. *Ann Otol Rhinol Laryngol* 1981; 90: 99-106.
3. Ishida N, Matsui K, Hayashi Y, Matsuura Y, Suzuki I, Hshino T et al. Perilymphatic Leakage from a Stapedial Footplate Fracture. *Practica Oto-Rhino-Laryngologica* 1992; Suppl.60: 141-145.
4. Whinney DJD, Parikh AA, Brookes GB. Barotraumatic Fracture of the Stapes Footplate. *Am J Otol* 1996; 17: 697-9.
5. E Whitehead. Sudden sensorineural hearing loss with fracture of the stapes footplate following sneezing and parturition. *Clin Otolaryngology* 1999; 24: 462-464.
6. Kuruma T, Nakayama M, Inahuku S, Wu M, Takimoto I. A Case of Sudden Sensorineural Hearing Loss with Fracture of the Stapes Footplate. *Practica Oto-Rhino-Laryngologica* 2003; 96: 529-533.
7. Goodhill V, Harris I. Sudden hearing loss syndrome. *Ear Diseases, Deafness, and Dizziness* (ed by Goodhill, V.) 1979: 664-681.
8. Seltzer S, McCabe BF. Perilymph fistula: the Iowa experience. *Laryngoscope* 1986; 28: 68-72.
9. Potter CR, Conner GH. Hydrops following perilymph fistula repair. *Laryngoscope* 1983; 93: 810-2.
10. Healy G, Friedman JM, Strong MS. Vestibular and audiotory findings of perilymph fistula: a review of 40 cases. *Trans Am Acad Ophthalmol Otolaryngol* 1976; 82: 44-9.
11. Shelton C, Simmons FB. Perilymph fistula: the standard experience. *Ann Otol Rhinol Laryngol* 1988; 97: 105-8.
12. Fee GA. Traumatic perilymphatic fistula. *Arch Otolaryngol* 1968; 88: 447-480.